

11

Access Cavity and Endodontic Anatomy

ARNALDO CASTELLUCCI, M.D., D.D.S.

It is well-recognized and universally accepted that a successful outcome in endodontic treatment essentially depends on three factors:

- 1) cleaning and shaping
- 2) disinfection
- 3) three-dimensional obturation of the root canal system.

Although it is impossible to determine which of the three factors is the most important, it is obvious that greater importance should be given to the first; an old axiom in endodontics states that what you remove from the root canal is more important than what you place inside.⁷⁷ Proper cleaning and shaping establish the necessary conditions for the success of the next two factors. It would be mistaken to try to disinfect and three-dimensionally obturate a root canal that had not been previously cleaned and shaped.

However, there is one other step that precedes these three. It affects all three and therefore should absolutely not be undervalued or neglected. An error in this preliminary step would compromise all subsequent work.

This preliminary step is the preparation of the access cavity, the opening in the dental crown that permits localization, cleaning, shaping, disinfection, and three-dimensional obturation of the root canal system.

The success of the endodontic treatment depends entirely on precise, proper execution of this step. An access cavity that has been prepared improperly in terms of position, depth, or extent will hamper the achievement of optimal results.⁹²

REQUIREMENTS OF THE ACCESS CAVITY

The access cavity must make the succeeding steps easier and safer. It must therefore meet the following requirements:^{60,76}

1) Permit the removal of all the chamber contents

As stated above, one of the first steps for a favorable outcome in Endodontics is proper cleaning of the endodontic space, which comprises not only the root canal, but also the pulp chamber and its pulp horns. Cleaning should be as thorough as possible.

Good endodontic cleaning, therefore, begins with the removal of the endodontic contents from the pulp chamber and its horns.

To accomplish this, it is necessary to completely remove the chamber roof. This allows the removal of all the pulp tissue, any calcifications, and all residue or traces of old filling material.

If the chamber roof is not completely removed, it will not be possible to perform proper cleaning of the pulp horns. There are two consequences:

- contamination or infection of the endodontic space that the dentist is trying to clean.
- discoloration of the endodontically-treated tooth (especially the front teeth).

To ensure adequate removal of the roof above the pulp horns, one can use a small, curve probe, such as a # 17 (Fig. 11.1A), as Lasfargues et al.⁵⁸ suggest. It is used to probe the walls of the access cavity for the presence of overhangings. Ardines' probes³ (Fig. 11.1B) are also useful for this purpose.

2) Permit complete, direct vision of the floor of the pulp chamber and canal openings

The entire extent of the floor must be visualized, as its landmarks help in identifying the canal openings. This applies particularly to the posterior teeth: the floor frequently has natural grooves, at the end of which the canal orifices are located (Fig. 11.2).

To meet this second requirement, the access cavi-

ty must sometimes be slightly modified to give it the so-called “convenient shape”. Following complete removal of the roof, it is necessary to orient the cavity slightly toward the dentist, particularly when dealing with the molars and patients with limited mouth opening. This gives the walls a slight anterior inclination that facilitates inspection of the floor and thus localization of the canal openings⁶⁰ (Fig. 11.3).

Inspection and localization are facilitated by the use of the endodontic probe (Fig. 11.4), which is to the endodontist what the periodontal probe is to the periodontist.¹⁷ By reaching, feeling, and frequently moving the hard tissue, this probe functions as an extension of the dentist’s fingers.

The natural anatomy of the floor frequently indicates the site of the orifices. Sometimes, however, restorations, dentinal neoformations, or dystrophic calcifications may alter the original configuration and hide the root canal orifices. Using the endodontic probe to explore the chamber floor, one can enter the canal openings and sometimes displace calcific deposits that obstruct them.

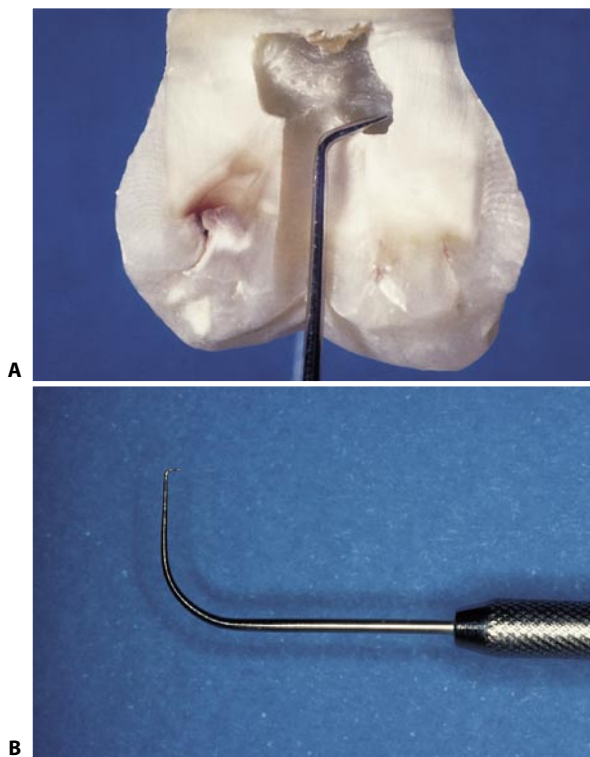


Fig. 11.1. **A.** With a small, angled probe, such as a # 17, it is easy to confirm complete removal of the pulp chamber roof. **B.** Detail of Ardines’ probe, which may be used for the same purpose.

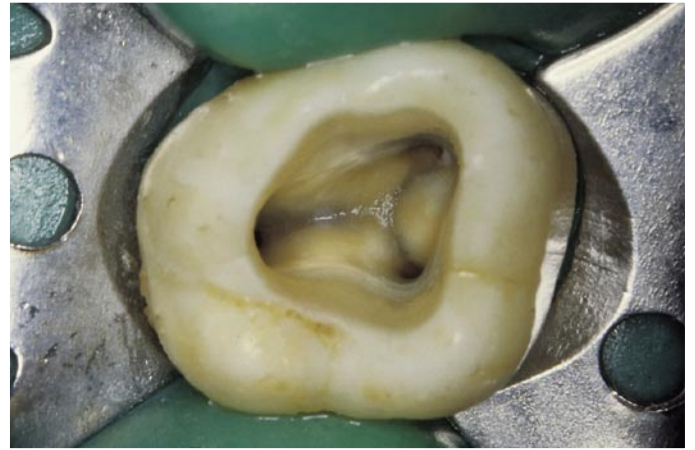


Fig. 11.2. Access cavity of an upper right second molar. Note the grooves in the floor of the pulp chamber, which are excellent natural guides to the canal openings.

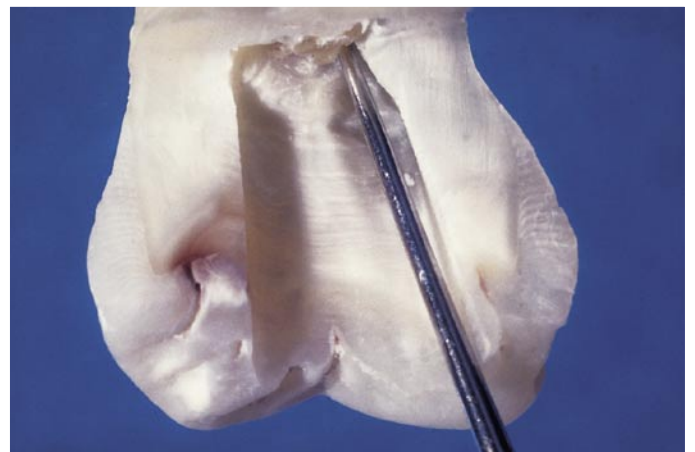

Fig. 11.3. Convenient access cavity shape. The aperture has been enlarged at the expense of the mesial wall.

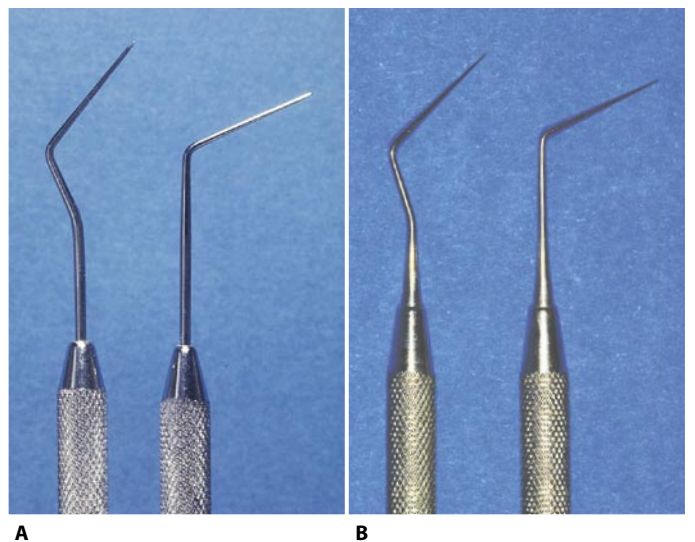


Fig. 11.4. **A.** Hu-Friedy DG-16 endodontic probes. **B.** The new endodontic probes JW-17 (C K Dental Specialties) designed by John West are very sharp.

Lastly, the endodontic probe can be used to determine the angle between the root canals and the floor of the pulp chamber.

3) Facilitate the introduction of canal instruments into the root canal openings

As stated above, the pulp chamber floor of the posterior teeth frequently has grooves that serve as guides, not only to find the orifices of the root canals, but also to the introduction of endodontic instruments within them.

The floor is also frequently convex and forms an acute angle with the chamber walls. It seems as though Nature had considered the work that the endodontist would have to do. Thus, if the access cavity has been well made and, especially, if the chamber floor has not been affected by the cutting action of the bur, the instruments will enter the canals easily without encountering any obstacles. It suffices to slide the canal instrument along the wall at the point where the canal opening is located. The walls prepared by the endodontist and the floor created by Nature will guide the instrument toward the apex (Fig. 11.5).

If the anatomy of the floor has been modified, result-

ing in flattening or irregularities, each introduction of an instrument must be checked with a mirror with the pulp chamber free of any irrigating solution, to allow visualization of the canal orifice.

4) Provide access as direct as possible to the apical one third of the canal for both preparation instruments and canal filling instruments

Endodontic instruments should not be deflected by any obstruction in the crown. When working in the canal, they should move freely, particularly in the apical one third (Fig. 11.6).

For a variety of reasons, the endodontic instruments should never touch the walls of the pulp chamber:

- They must be able to work on the entire circumference of the canal. An access cavity that is too narrow will force the dentist to work on only one wall of the canal, while the other remains completely untouched (Fig. 11.7). Deformations of the apical foramen may result.^{39,50,60}
- The friction of the instrument's shaft against the coronal obstructions will have to be overcome. The force required to do so impairs the endodontist's ability to sense how much the working portion of

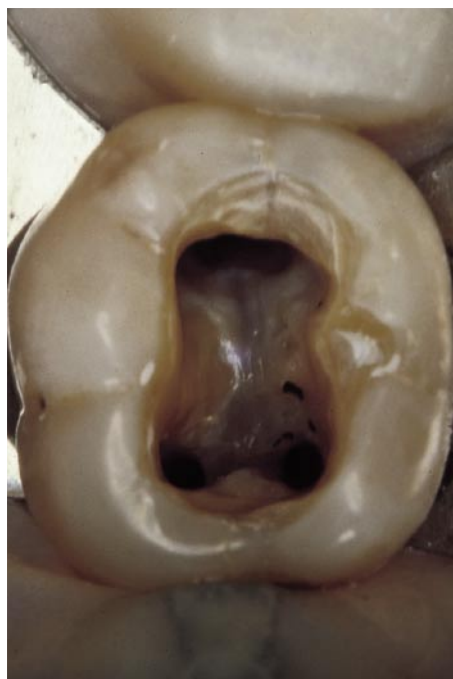

Fig. 11.5. Access cavity in a lower first molar. The convexity of the pulp chamber floor guides the endodontic instruments into the canal openings.

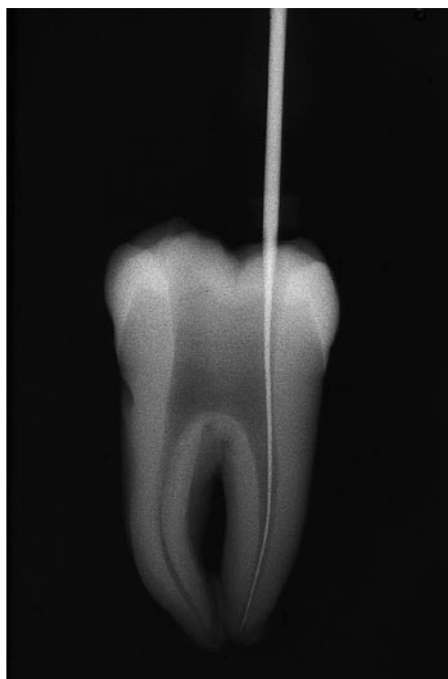


Fig. 11.6. The instrument descends freely into the root canal without encountering any coronal interference.

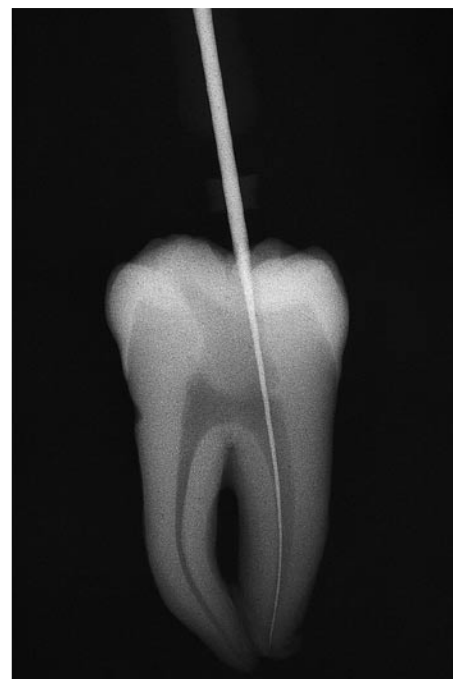

Fig. 11.7. The limited access cavity and incomplete removal of the chamber roof limits the instrument to working on the mesial wall of the distal canal. The opposite wall cannot be cleansed.

the instrument is engaged against the canal walls.⁶⁰ This could easily lead to fracturing of the instrument.

To avoid both of these complications, the access cavity must be wide enough to permit the endodontic instruments unhindered entry; there must not even be minimal contact with the walls of the access cavity. This is particularly important with the use of rotary Nickel Titanium instruments.

The cavity need not necessarily remain unaltered throughout treatment; rather, it should be considered subject to modification at any time, if the need arises. If any hindrance arises in mid-preparation because larger and more rigid instruments are called for, one should put down the canal instruments, pick up the high-speed handpiece, and enlarge the cavity as needed until the hindrance has been removed, even if this requires removing a cusp.

To prevent any fragments of dentin or, worse, amalgam or other filling material, from falling into the canal being prepared or into the neighboring canals that have already been cleaned and shaped, it suffices to place small cotton pellets into the canal openings (Fig. 11.8). One principle should never be forgotten: it is always advisable to prepare wide access cavities and generously remove old metallic restorations to avoid having to enlarge the cavity intraoperatively. Such enlargement carries the risk that the handpiece spray will obstruct the canals that have already been prepared or are in the preparation phase by forcing fragments into them.

In markedly curved canals, but particularly in the cur-

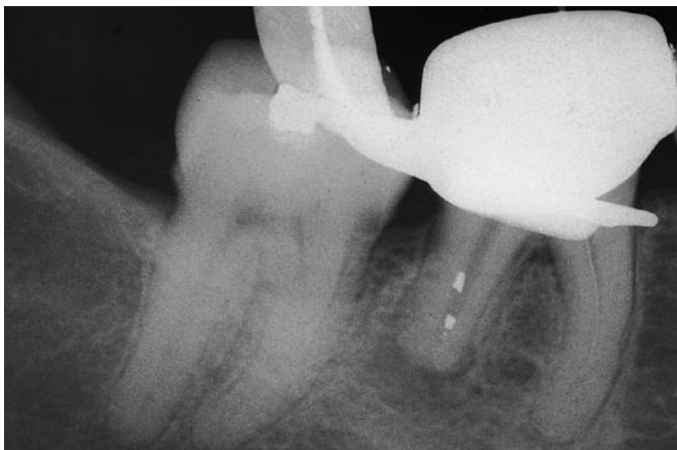

Fig. 11.8. An access cavity made through a prosthetic restoration has been enlarged mesially after the distal canal had already been prepared. The spray of the high speed handpiece has caused metallic filings to fall into the distal root canal.

ves of the coronal one third, obstructions that can reduce the tactile sensitivity of the instruments in the apical one third are encountered not only in the walls of the pulp chamber, but also in the coronal one third of the canal itself. Such curves must be prophylactically eliminated following the “anticurvature” filing method as suggested by Abou-Rass, Frank, and Glick.¹ Obviously, if the access to the apical one third is straight for instruments used in canal preparation, it is also so for materials and instruments used for obturation of the root canal system (Fig. 11.9).

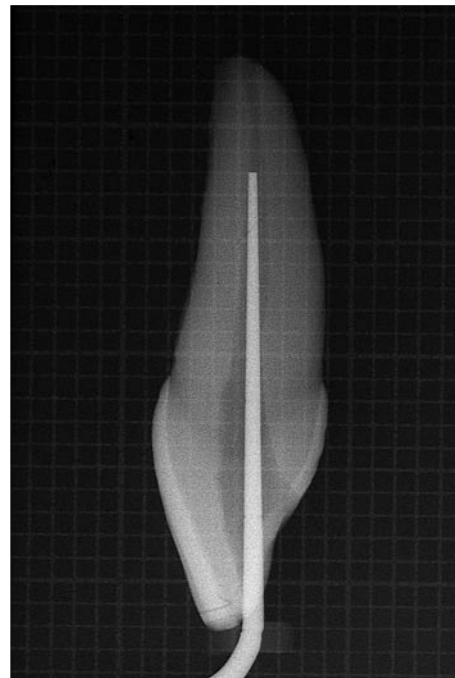


Fig. 11.9. A correctly-made access cavity permits straight-line access to the apical one third of the root canal, even to instruments necessary for canal filling.

5) Provide a positive support for temporary fillings

When the access cavity is temporarily obturated to seal a medication within, the temporary cement must form an hermetic seal to avoid contamination of the cavity. The cement must be unaltered for the entire period of time required (Fig. 11.10), and it must not collapse into the chamber (Fig. 11.11). To prevent this, the walls of the access cavity must be flared slightly in the shape of a funnel, so that the occlusal surface is slightly wider than the floor.

Clearly, this requirement only applies for the duration that the medication has to act; it is therefore useless to enlarge the access cavity too much, as this would pointlessly weaken the residual dental structure. To avoid needless mutilation, the enlarging should not begin at the floor of the chamber, but should affect only the most coronal part of the access cavity, where the temporary cement will be positioned (Fig. 11.12).

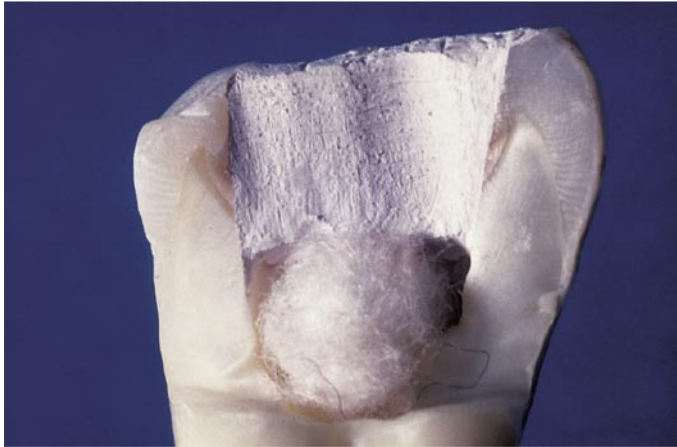

Fig. 11.10. Slight flaring of the walls of the access cavity is advantageous for the temporary filling that can thus stably seal the medication placed into the chamber.

If the walls of the cavity are parallel or, worse, if they diverge apically (Fig. 11.13), the temporary cement would be displaced by the force of mastication.

The shape of the access cavity is determined by these considerations. In practice, it should correspond to a slightly enlarged projection of the contour of the pulp chamber floor onto the occlusal surface of the tooth.

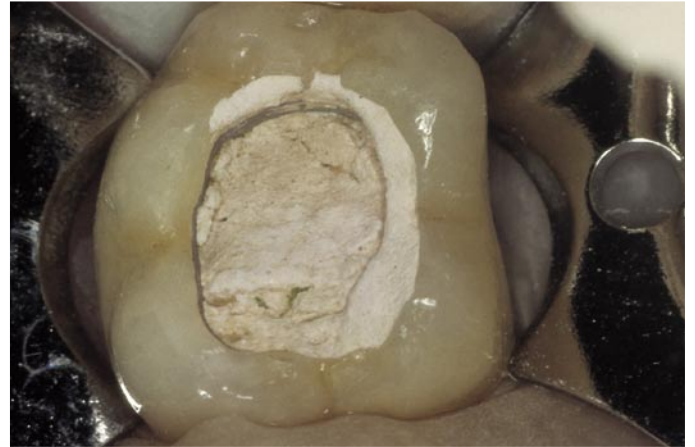

Fig. 11.11. Insufficient flaring of the walls of the access cavity has caused the temporary filling to sink into the chamber.

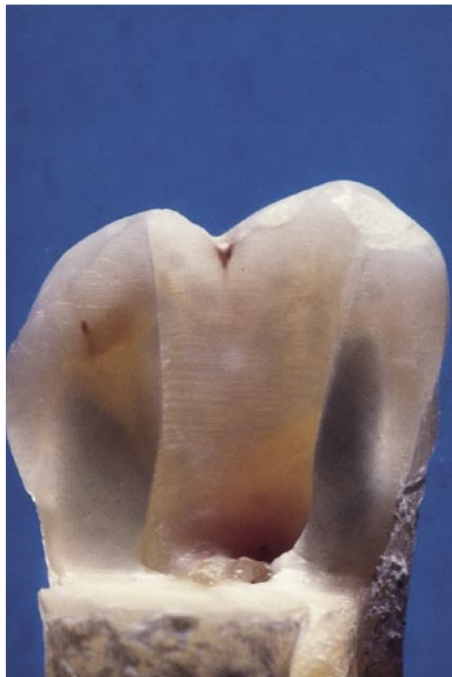

Fig. 11.12. The flaring of the walls should involve only the more coronal part of the access cavity.

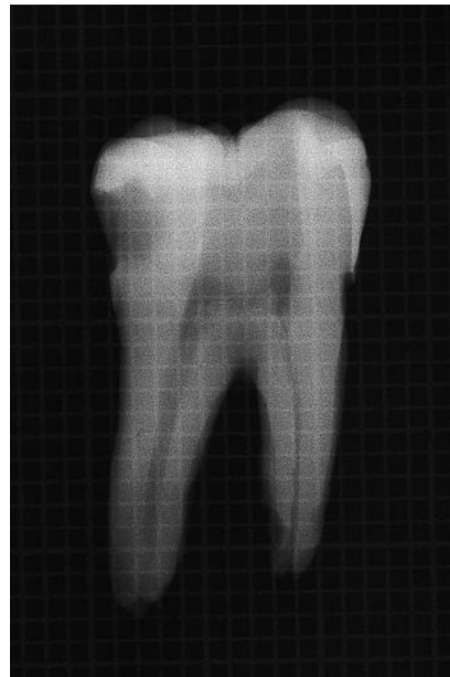

Fig. 11.13. The walls of this access cavity diverge apically rather than coronally. Dislocation of the temporary cement is inevitable.

6) *Always have four walls*

The four walls of the access cavity serve several purposes:

- correct positioning of the rubber dam so that the clamp is stable and the rubber dam isolates the field well,
- keeping the pulp chamber constantly flooded with as much irrigating solution as possible,
- defining easily recognizable, stable reference points for the rubber stops on the endodontic instruments,
- introducing the temporary medication without affecting the interproximal papillae, as would occur if one tried to use the temporary cement to fill a class II cavity.

When one or more walls of the access cavity are lacking because of previous carious destruction, it or they must be reconstructed with the help of copper bands,⁵⁹ orthodontic bands, or other methods (see Chapter 12).

RULES FOR THE PREPARATION OF AN ADEQUATE ACCESS CAVITY

The creation of an adequate access cavity presupposes that the following rules are applied:⁹²

1. In creating the access cavity, one must keep in mind not only the position of the canal orifices, but also the position and, more important, orientation of the apical foramen.

In markedly curved canals, the portion of the access cavity opposite to the curve of the root must be greatly extended (Fig. 11.14). This ensures that the instrument will encounter a lesser curvature than that of the original curve. This is analogous to entering the on-coming lane when approaching a hairpin curve in an automobile so as to increase the radius of the curve and avoid going off the road.

2. The shape of the access cavity differs from that used in restorative dentistry.

In preparing a cavity for amalgam, the lay out of

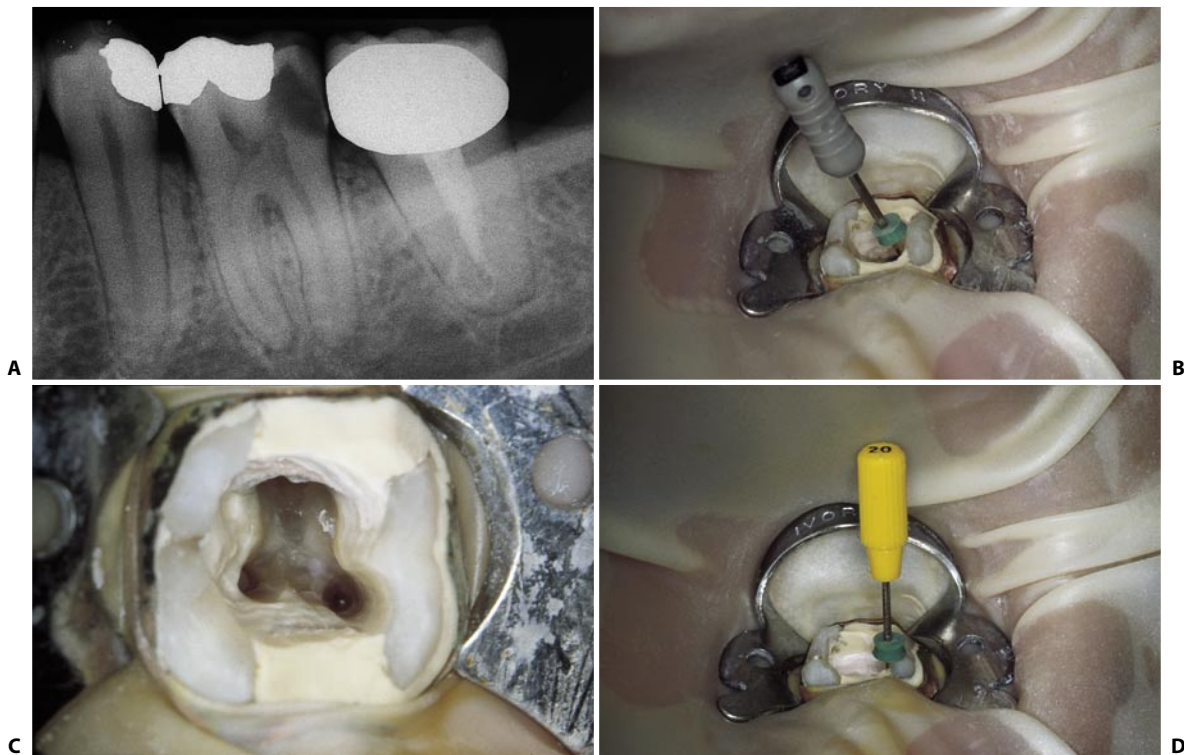


Fig. 11.14. **A.** Preoperative radiograph of the lower left first molar. Note the curvature of the coronal one third of the mesial root. **B.** The # 08 file, introduced in the mesiobuccal canal, indicates that the curvature is directed not only distally, as appreciated radiographically, but also lingually. **C.** The access cavity has been extended mesially and buccally, at the expense of the mesiobuccal cusp. **D.** This instrument, a # 20 file, has straight-line access to the apical one third of the root canal.

the occlusal sulci, fossae, and fissures are pertinent, and one must avoid the underlying pulp.

The access cavity must uncover the pulp; by eliminating the entire chamber roof, rectilinear access to the apical foramina can be obtained through the canals.⁹²

3. The access cavity must not assume a pre-determined, geometric shape.

It is not the endodontist, but rather the anatomy of the pulp chamber floor, which determines the shape of the access cavity in each tooth; it can be triangular, elliptical, or trapezoidal. Furthermore, the access cavity need not necessarily remain unaltered during treatment, but can be modified as needed by contingent circumstances.

4. One's familiarity with the anatomy of the tooth to be treated should be as complete as possible. Apart from clinical observation, such familiarity may be acquired from close examination of preoperative radiographs taken with at least two different views.

The endodontist must also be aware of the possible anatomical variants of each tooth, since his eye will recognize what his brain knows, and he will see what he wants to see, but he will not see what he does not know.

5. When the canals are very difficult to find, it is advisable to create the access cavity without using a rubber dam until one reaches the canal openings.⁴⁰

This can be especially useful when treating a tooth that has previously been malpositioned or prosthetically covered, or whose pulp has markedly calcified. The shape and inclination of the adjacent teeth, the gingival tissues, and the hard structures that cover the roots can be helpful in locating the root canals.

Once the access cavity has been made and the canals located, the rubber dam may be placed in position, and the entire treatment may be conducted beneath the rubber dam ⁹² (Fig. 3.15). If, on the other hand, one cannot do without the rubber dam yet wishes for an overview, *Weine* ⁹² suggests isolating an entire quadrant. *Frank et al.*⁴⁰ recommend removing the dam as necessary to get an idea of how the roots enter the alveolus and to obtain a radiograph without the superimposed shadow of a clamp.

6. The access cavity should always be created through the occlusal or lingual surface, never through the approximal or gingival surface, with the exception of very unusual and very particular cases. An ap-

proach other than the occlusal or lingual would cause significant bending of the instruments; as a consequence, cleaning and shaping of the canal would be inadequate and the apical foramen would be deformed.

GENERAL PRINCIPLES FOR THE PREPARATION OF THE ACCESS CAVITY

Regardless of the tooth, there are three phases in the preparation of the access cavity: penetration, enlarging, and finishing.

Penetration phase

This phase is performed using a round diamond bur mounted on a high-speed handpiece (Fig. 11.15). The objective of this phase is to "penetrate" the pulp chamber by breaking through the roof with the bur.

If the pulp chamber is wide enough, there is a sensation of "falling into a vacuum" when the roof is penetrated. If, however, the chamber is very narrow or completely absent because of the development of abundant calcifications, one should not expect this



Fig. 11.15. Round, diamond bur mounted on a high-speed handpiece. It is used in the penetration phase. The diameter of the bur required depends on the tooth being treated.

sensation. Rather, one has to scoop out the access cavity to free the canal openings of obstructions, just as Michelangelo unfettered the David of the marble covering it!

If, in drilling a tooth with a completely calcified chamber, one waits for the sensation of falling into a vacuum, it will be too late when it does occur: this would signify perforation.

During this phase, it may help to tilt the bur toward the pulp horn where the pulp chamber is wider.

To facilitate the removal of calcifications, ultrasonics with specific tips, like CPR and ProUltra, are very useful (Fig. 11.16).

Diamond burs are preferred to tungsten burs, because they cut more smoothly and therefore vibrate less and are better tolerated by patients. The diameter of the bur depends on the tooth and pulp chamber being treated.

The opening must not be straight and long; rather, for better visibility and orientation, it should be funnel-shaped, open toward the exterior. Thus, while the bur penetrates until it breaks through the roof, it should also be moved circularly to give the cavity a shape si-

milar to its final one. While the bur penetrates both the enamel and dentin, simultaneously works circumferentially; thus, the movement imparted to it is helical. As stated above, this phase concludes when the bur penetrates into the pulp chamber (Fig. 11.17).

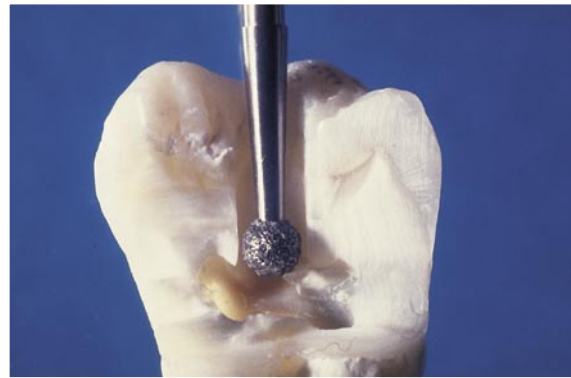


Fig. 11.17. The penetration phase is completed. The diamond bur has broken through the pulp chamber roof.

Enlargement phase

This phase is performed with a round bur mounted on a low-speed handpiece (Fig. 11.18). Its diameter should be slightly smaller than that of the preceding bur, and it should have a long shaft for improved penetration and visibility.



Fig. 11.18. Long-shafted round bur mounted on a low-speed handpiece. It is used for the enlargement phase. The diameter of the bur is always smaller than that of the round, diamond bur used in the preceding phase.

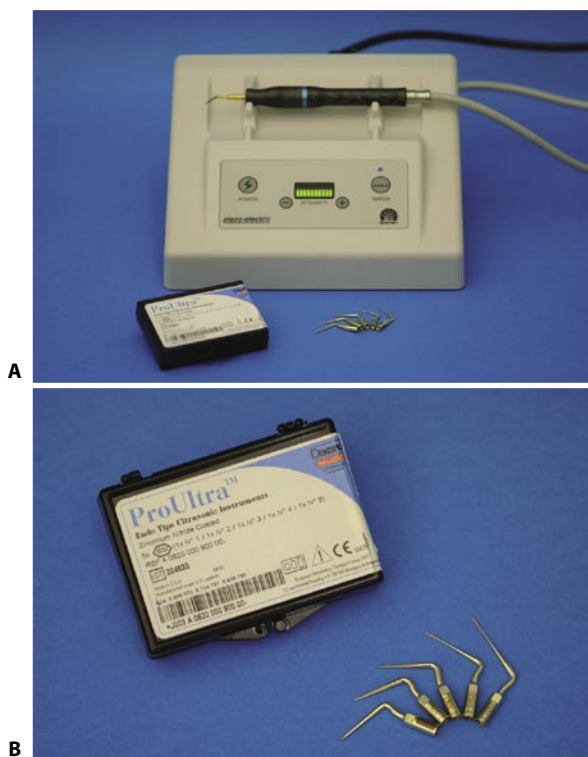


Fig. 11.16. **A.** The ultrasonic source Spartan. **B.** The ultrasonic tips CPR (Spartan Corporation, Fenton, MO) and the ProUltra (Dentsply, Maillefer, Ballaigues, Switzerland).

The opening created in the preceding phase is entered, and the action of the bur is applied “on the way out”.* It is turned on while exiting the pulp chamber, working on the dentinal walls with a brushing motion. In this way, all the overhangings of dentin left behind in the preceding phase are removed (Fig. 11.19). During this phase, the definitive form of the access cavity begins to emerge. It will be completed in the following phase.

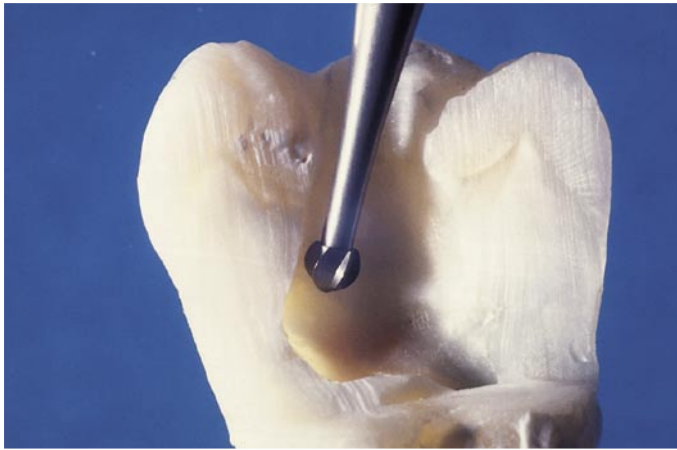

Fig. 11.19. The round bur enters the just-created opening in the chamber roof, is applied to the undercuts of dentin, and removes them on the way out.

Finishing and flaring phase

This phase requires a non-end-cutting diamond bur, also called self-guiding bur, or Batt's bur mounted on a high-speed handpiece (Fig. 11.20). It is used to finish off the work performed during the preceding two phases and to smooth the walls of the access cavity, so that the transition between the access cavity and the pulp chamber walls will be imperceptible to probing. With the appropriate angulation, the same bur is also useful for slightly flaring the most occlusal portion of the access cavity externally, so that it meets the fifth requirement listed above (Fig. 11.21).

The non-cutting head allows one to touch the chamber floor with the bur and at the same time precludes modification of its very important anatomy. The use of a diamond bur on a high-speed handpiece is recommended, as fissure burs at low speed (Fig. 11.22) cause intolerable vibrations when they contact enamel. In this phase, one works simultaneously on dentin and enamel. For this reason, it necessitates the use of a diamond bur at high speed.

Some authors prefer to skip the second phase and after penetrating the pulp chamber, they go directly to the use of a self-guiding bur, which simultaneously eliminates the dentin overhangings and smoothes and flares the walls, avoiding the need to change handpiece and bur.



Fig. 11.20. Non-end cutting diamond bur mounted on a high-speed handpiece, which is used for the finishing and flaring phase.

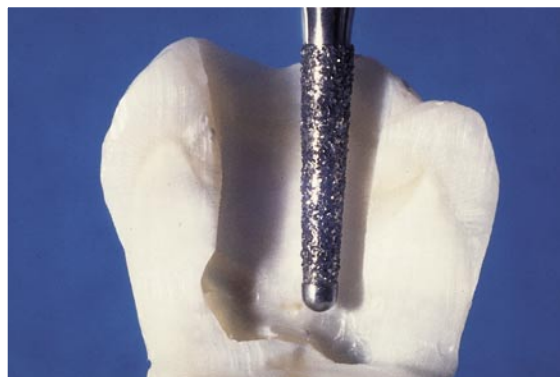


Fig. 11.21. The bur has finished the walls of the access cavity, giving them a slight coronal flare.

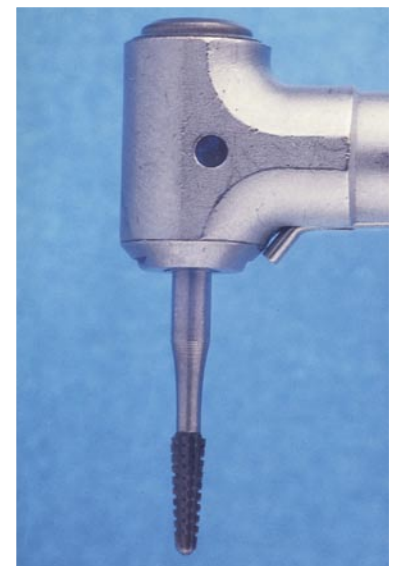


Fig. 11.22. A fissure bur with a non-cutting tip, for low-speed. Its use is not recommended, since it causes too much vibration.

(*) In Endodontics, all instruments *always* work “on the way out”, *never* “on the way in”.

This can be done if the pulp chamber is free of calcifications. However, if, as frequently happens, the pulp chamber roof has collapsed as far as the floor through the deposition of reparative dentin or if the chamber is full of calcifications, there is no space to work with this bur. In fact, a self-guiding bur would cause the dentin to scorch as a result of overheating created by the friction of its smooth portion against the pulp calcifications. The opening of the access cavity is still limited, and the spray of the handpiece therefore cannot reach the tip of the bur to cool it.

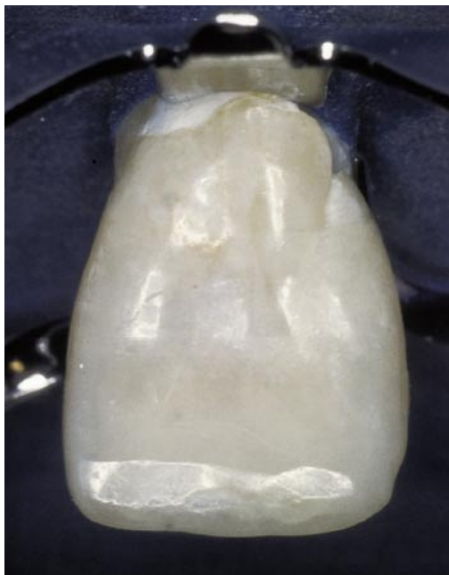

Fig. 11.23. Palatal aspect of the upper central incisor.

UPPER CENTRAL INCISOR

The access cavity is initiated by applying the bur occlusal to the cingulum (Fig. 11.23), almost perpendicular to the palatal surface (Fig. 11.24).

The cingulum is chosen as a starting point, because, in contrast to the gingival margin which can retract and the incisal margin which can abrade, this ridge remains constant throughout the patient's life.

Once the penetration phase is over (Fig. 11.25), the access cavity is still not complete, as it is still necessary

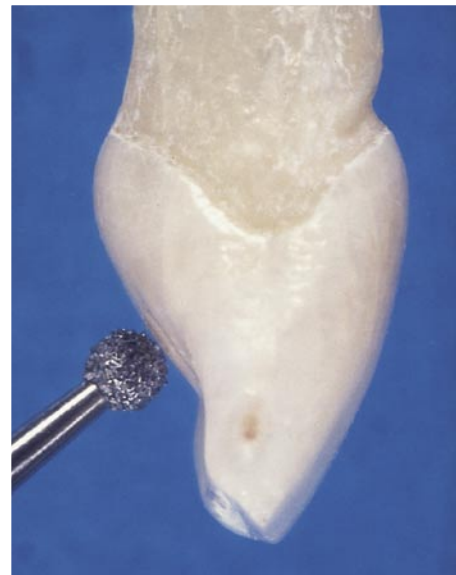

Fig. 11.24. The round, diamond bur begins the penetration phase occlusal to the cingulum at a roughly 90° angle to the palatal surface.

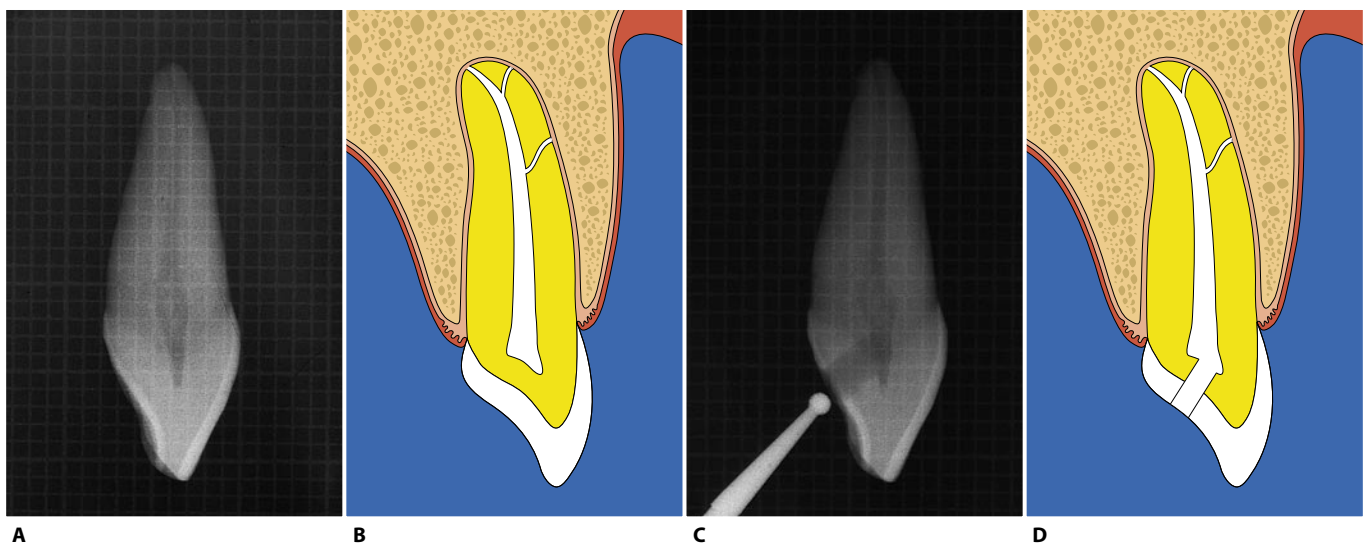


Fig. 11.25. **A.** Mesiodistal radiographic projection of an upper central incisor. **B.** Schematic representation of the preceding figure. **C.** The round, diamond bur has just completed the penetration phase. **D.** Schematic representation of the preceding figure.

to remove two ledges conventionally called “triangle # 1” and “triangle # 2” during the enlargement phase. The two triangles interfere with the introduction of endodontic instruments so much, that sometimes they may almost completely block the instruments (Fig. 11.26).

“Triangle # 1”, which is essentially constituted of ena-

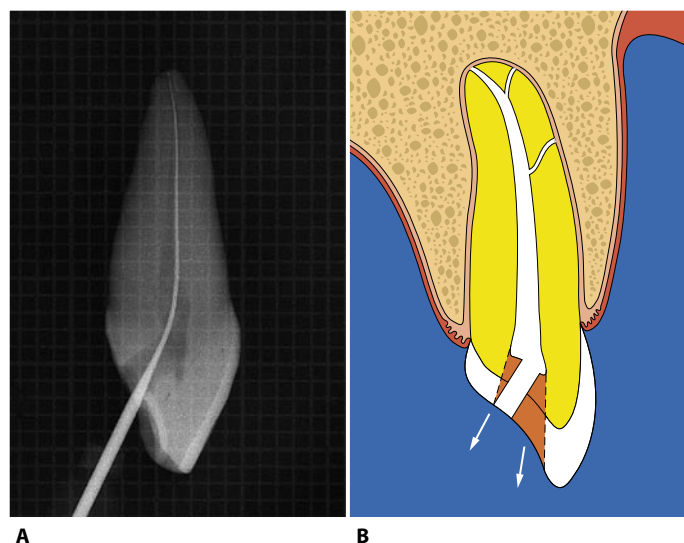


Fig. 11.26. **A.** Introduction of a small file after the penetration phase demonstrates the presence of two large coronal obstacles, which impede, if not completely obstruct, the introduction of instruments into the root canal. **B.** Schematic representation of the obstacles encountered by the instruments: the most coronal triangle is conventionally called “triangle # 1”, while the more apical one is called “triangle # 2”.

mel, is removed by the same bur used for penetration, though its angulation and mode of use are different. The bur must be held more parallel to the long axis of the tooth (Fig. 11.27). Furthermore, when exiting, the bur must be applied to the enamel edge, which it wears away gradually (Fig. 11.28).

A slight mesiodistal movement must be imparted simultaneously to the bur, so as to remove all of the roof associated with the pulp horns (Fig. 11.29).

“Triangle # 2”, which is predominantly constituted of dentin, is smoothed with a small, long-shafted round bur mounted on a low-speed handpiece (Fig. 11.30). The bur must be introduced into the just-opened aperture, applied to the palatal wall of the canal apically to the point of the triangle of dentin, and is activated on the way out so as to “peel” the small ledge little by little (Fig. 11.31). To finish off the cavity, one can use the self-guiding diamond bur. It must be quite long and thin, and one must ensure that the spray reaches its tip to cool it.

The access cavity achieves a roughly triangular shape with this preparation. This mirrors the anatomy of the pulp chamber, which has one mesial and one distal pulp horn (Fig. 11.32).

Generally, one can obtain straight-line access to the apical one third without having to involve the incisal margin (Fig. 11.33). Where possible, but specifically in teeth that require prosthetic treatment, it is also advisable to extend the access cavity to the incisal margin.

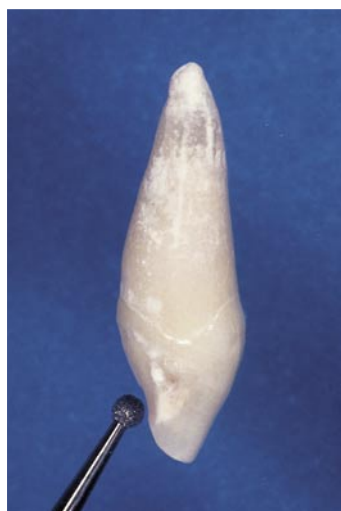

Fig. 11.27. Removal of triangle # 1 with the round, diamond bur, which is more inclined towards the parallel of the long axis of the tooth.

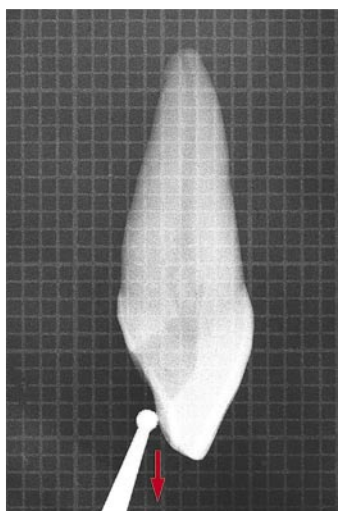


Fig. 11.28. The bur is applied to the enamel ledge, which it wears away on the way out.

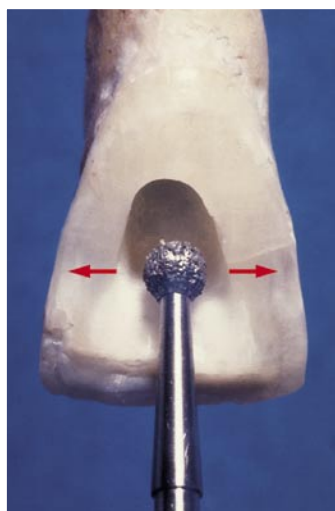


Fig. 11.29. The bur is also used to carry out a mesiodistal movement so as to involve the pulp horns.

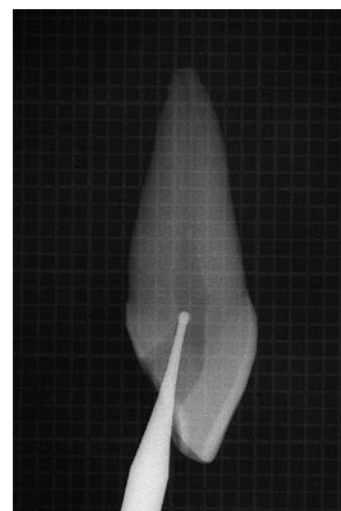


Fig. 11.30. The low-speed, long-shafted round bur is applied to the dentin ledge of “triangle # 2”. The bur is used on the way out, until the triangle is completely removed.

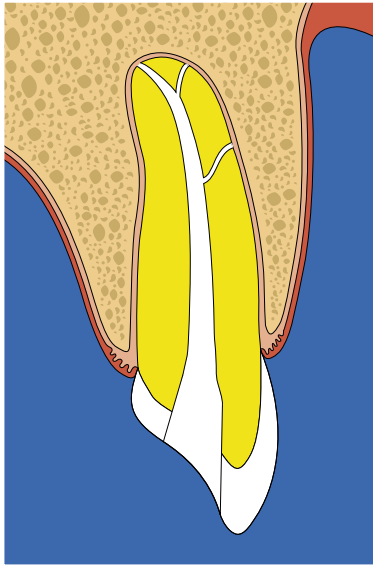


Fig. 11.31. Schematic representation of the access cavity after removal of the two triangles, seen in a mesiodistal projection.

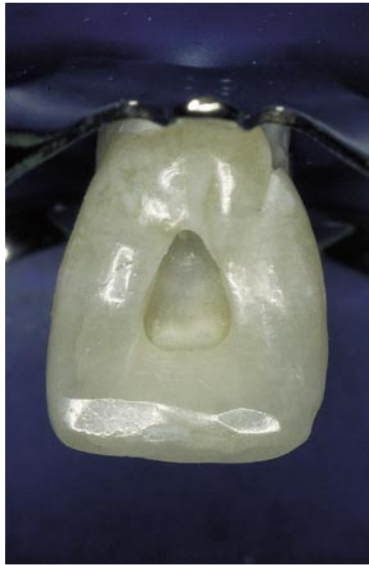

Fig. 11.32. Definitive shape of the access cavity. The involvement of the two horns automatically gives the cavity a more or less triangular shape.

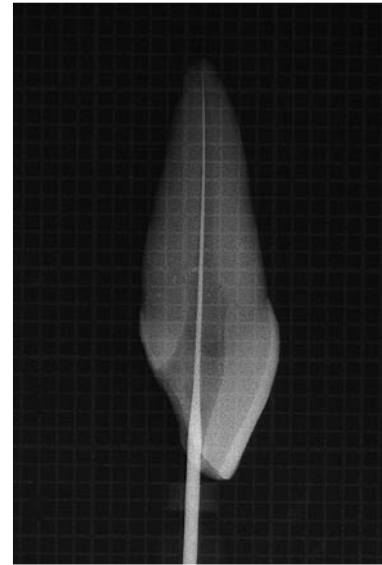


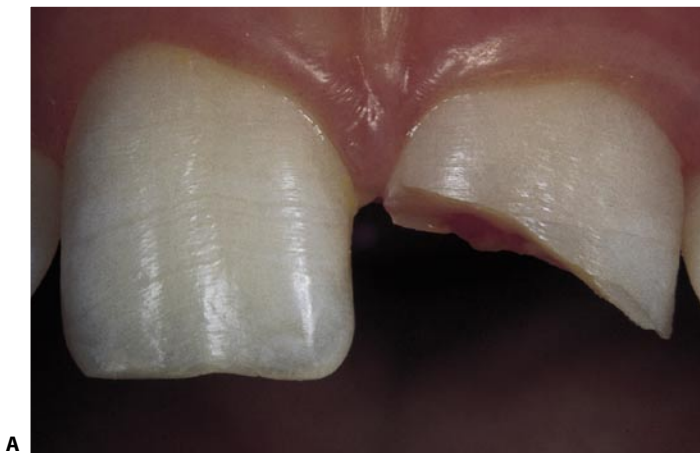Fig. 11.33. Once the access cavity has been completed, the instrument can be introduced into the apical one third of the root canal without encountering any coronal obstacles. Note that the access cavity has not involved the incisal margin.

This will not only facilitate the endodontist's task, but that of the prosthodontist too, if a post must be used. In a study of 198 extracted anterior teeth, La Turno et al.⁵⁷ have found that only 6% of the central incisors had a canal whose coronal projection was entirely palatal and could therefore be approached successfully with an entirely palatal access. In 22%, the projection also involved the incisal edge; in 30%, it straddled the incisal edge, so that it was partly palatal and partly buccal; in 32%, it involved the incisal edge but was completely displaced buccally, and in 10% it was exclusively buccal.

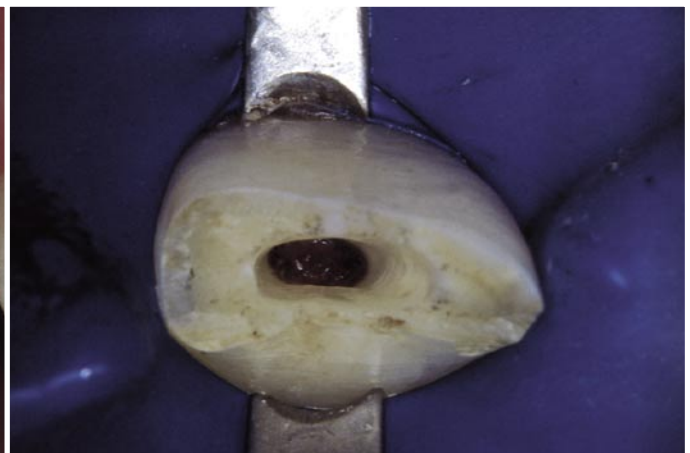In other words, one can avoid involvement of the incisal edge in only 6% of cases!

There are two situations in which one must necessarily involve the incisal margin: abraded or fractured teeth.

The more abraded a tooth, the more the incisal surface – at this point, one can no longer speak of a margin – will be affected by the preparation of the access cavity. In very abraded teeth or teeth with fractures of the middle one third of the crown, the cavity is prepared entirely on the incisal surface (Figs. 11.34 and 10.25).



A



B

Fig. 11.34. **A.** The upper left central incisor has been subjected to trauma, which has caused a fracture of the middle one third of the dental crown, with significant pulp involvement. **B.** In this case, the access cavity has been created entirely at the level of the fracture surface.

The finding of two canals within its root is very rare.¹⁷ However, the canal sometimes divides close to the apex into two very thin canals (Weine's type IV) (Fig. 11.35). The prevalence of lateral canals, which may be found at various root levels, is very high (Fig. 11.36 A, B). Frequently, there is a large lateral canal that

branches mesially off the principal canal at a 90° angle about halfway along its course (Figs. 11.36 C, D). Radiographically, the root may present with slight mesiodistal or buccolingual curvatures, though the latter may not be appreciated unless several views are obtained (Fig. 5.41).

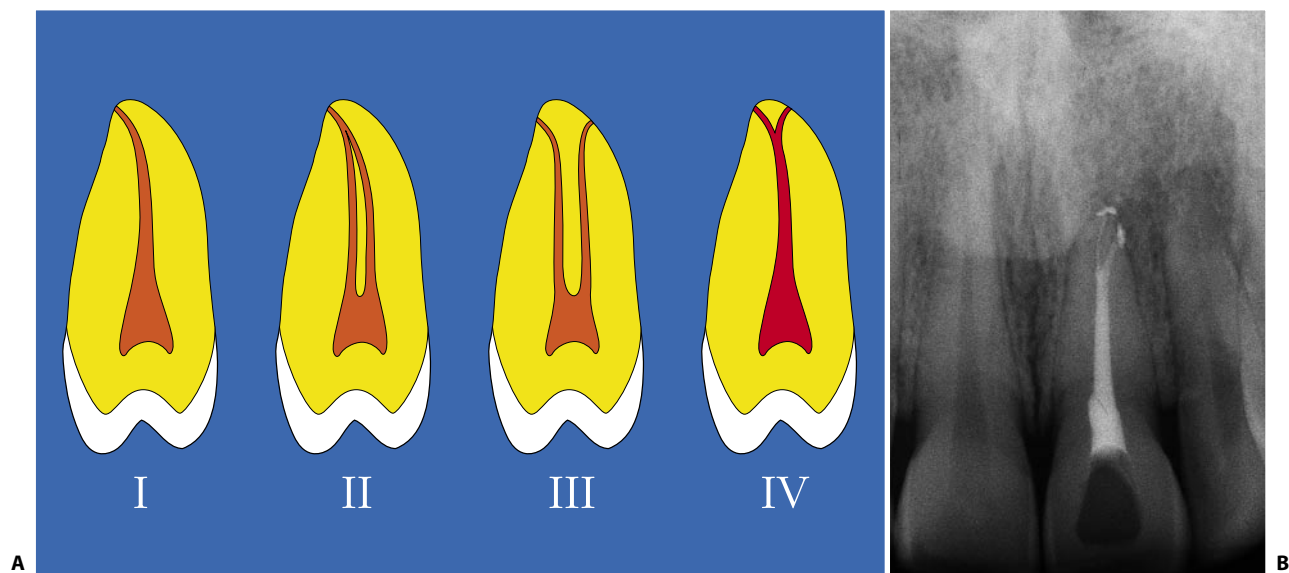


Fig. 11.35. **A.** Schematic representation of the four possible canal configurations which may be encountered in a root, as described by Weine. **B.** Upper left central incisor with a canal that divides into three thinner canals near the apex (Weine's type IV).

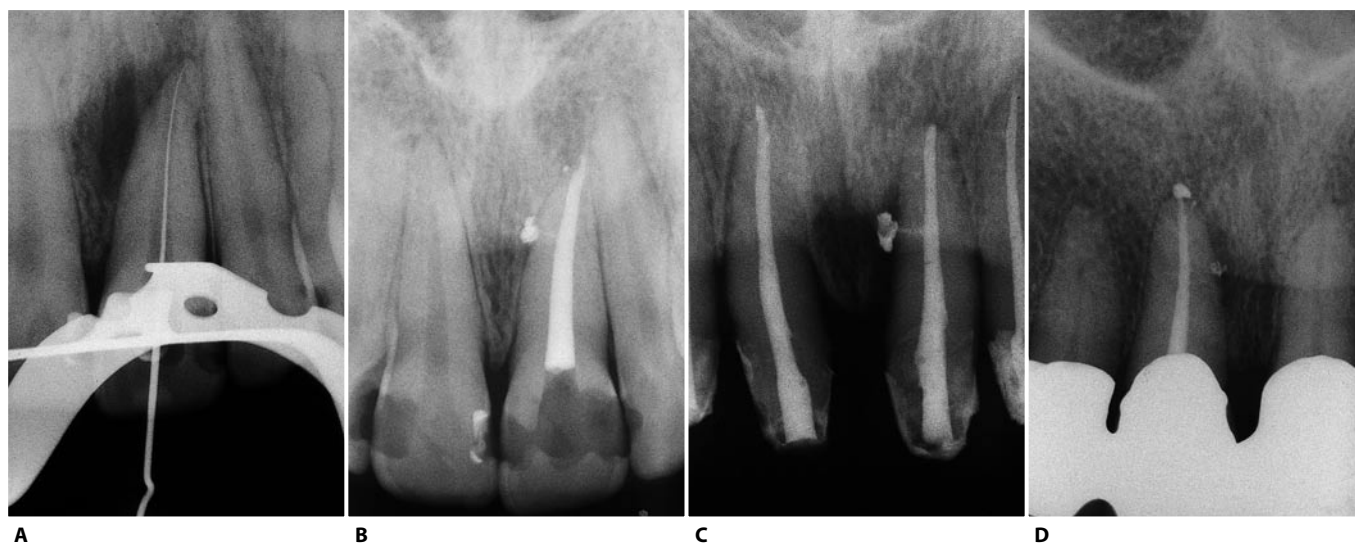


Fig. 11.36. **A.** Intraoperative radiograph of the upper left central incisor. Note the discrete radiolucency situated mesially to the root. This lesion suggests the presence of at least one lateral canal. **B.** Twelve months later. Note the healing of the lesion and three lateral canals filled, one near the apex and two at the level of the middle one third, both facing mesially. **C.** Upper left central incisor with a large lateral canal at the level of the middle one third. The lateral canal faces mesially and branches off from the main canal at a 90° angle. **D.** Upper right central incisor with a small lateral canal near the foramen and another bigger one in the middle one third, facing mesially at a 90° angle.

UPPER LATERAL INCISOR

In this tooth, the access cavity is created in the same way as in the central incisor. The only difference is the final shape of the cavity opening: that of the lateral incisor is ovoid, because the tooth has two closely-situated pulp horns or a single central horn (Fig. 11.37).

Rarely, one may find a canal that bifurcates in the most apical one third into two distinct canals with independent apices (Weine's type IV) (Fig. 11.38).

Very frequently, there is a distal or palatal curvature of the apical one third of the root. Obviously, the latter is not easily recognized radiographically (Fig. 11.39).

The presence of a palatal curvature explains why the lesions of endodontic origin of the lateral incisor quite often present in the palatal area (Figs. 8.21, 8.27).

Regarding the involvement of the incisal margin, Zillich and Jerome¹⁰⁰ have conducted a study similar

to that of La Turno on the central incisors. Their conclusions are more extreme. In their study of 131 extracted lateral incisors, only 0.8% had a canal whose coronal projection was entirely palatal and thus successfully approachable through an entirely palatal access without having to involve the incisal margin. In 6.9%, the projection was palatal but also involved the incisal margin; in 43.5%, it straddled the incisal margin, indicating that the access cavity would have to be started at the level of the incisal margin and extended equally palatally and buccally; in 32.9%, the projection involved the incisal margin, but was completely displaced buccally; and in 16%, it was exclusively buccal.

This explains why, with inadequate straight-line access to the apical one third of the canal, there is such a high failure rate in treating this tooth. It always requires an access cavity that involves the incisal margin, with prosthetic reconstruction of the tooth.²⁰

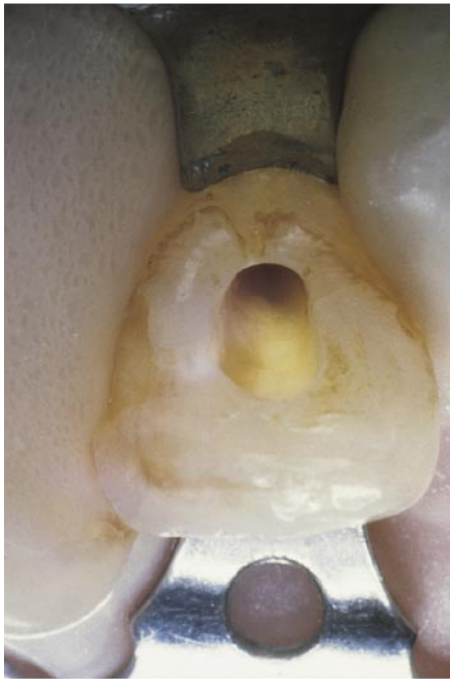

Fig. 11.37. The shape of the access cavity in this upper lateral incisor is ovoid.

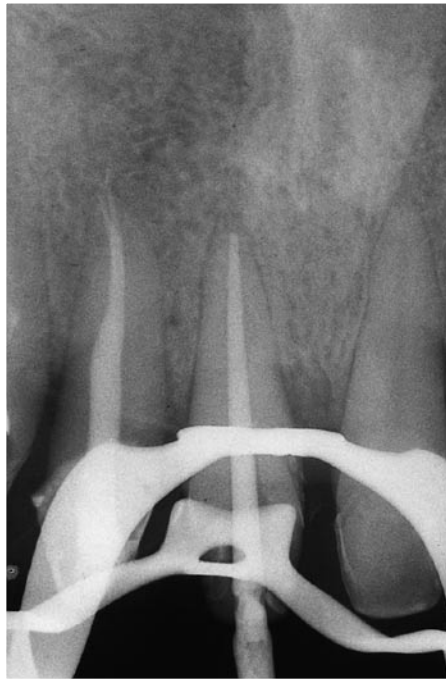

Fig. 11.38. This intraoperative radiograph of this central incisor demonstrates the true endodontic anatomy of the adjacent lateral incisor, which has already been treated endodontically. The angulated radiograph reveals a main canal bifurcating close to the terminus into two thinner canals, each with its own foramen, consistent with Weine type IV. Filling of the bifurcation has occurred automatically during filling of the main canal.

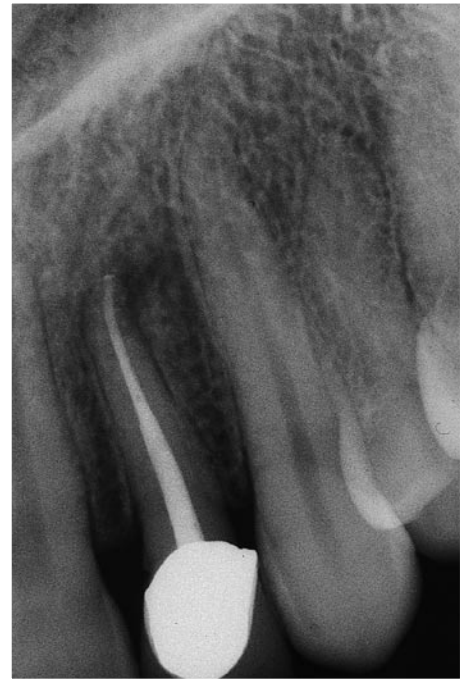

Fig. 11.39. Postoperative radiograph of an upper lateral incisor, with a distal curvature of the apical one third of the root.

UPPER CANINE

The longest tooth of the dental arch, the upper canine is extremely important from the occlusal point of view.

The access cavity begins about halfway up the crown on the palatal side. The same rules that apply to the central incisors are also valid here.

With an ovoid pulp chamber and a single horn, the access cavity is an oval whose larger diameter is apical-coronal (Fig. 11.40). In this case also, if the tooth is abraded or fractured, the incisal surface will be involved in the access cavity (Fig. 11.41).

The root canal is quite straight and long enough to often require the use of 30 mm instruments. In the most apical portion, the root – hence the canal – may present a curvature in any direction.

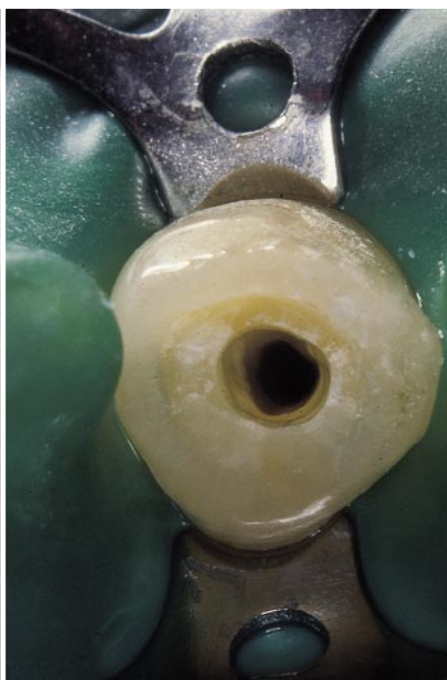
Less frequently than in the upper incisors, the canines may also have lateral canals. The finding of two canals is very rare (Fig. 11.42).

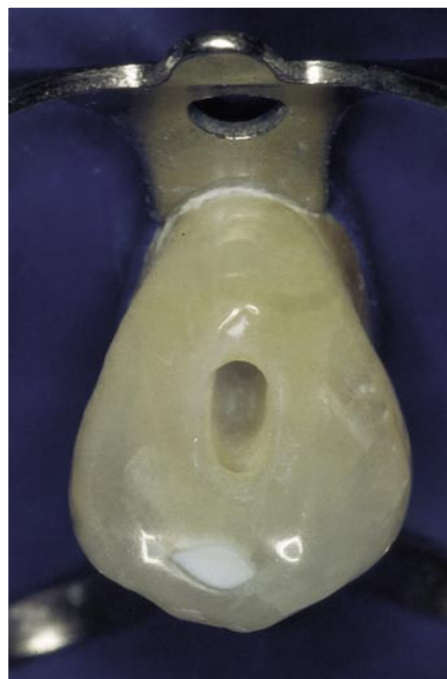
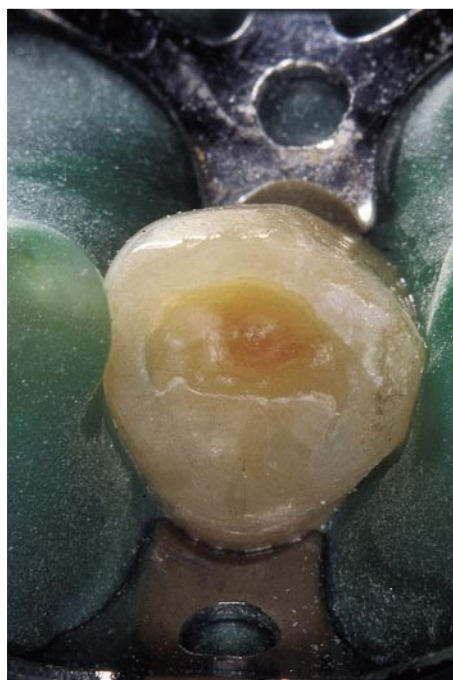
Fig. 11.40. Ovoid shape of the access cavity in an upper canine.



A



B

Fig. 11.41. **A.** The cusp of this upper canine appears very abraded. **B.** The access cavity has been created entirely at the level of the incisal surface.

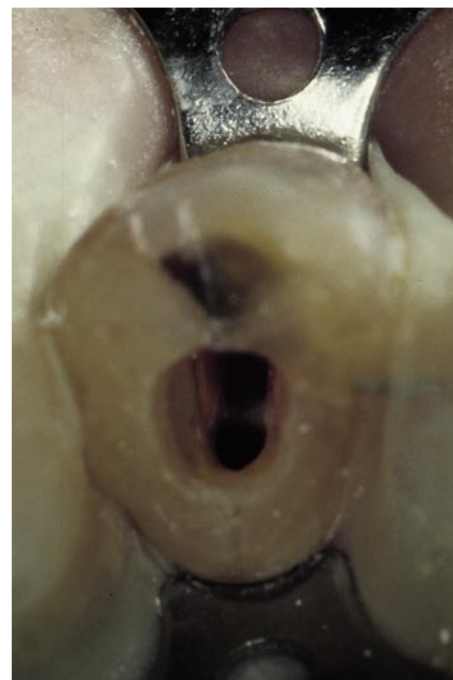

Fig. 11.42. Upper canine with two canals. Two openings can be seen within the access cavity, which has a typical gun-barrel appearance.

UPPER FIRST PREMOLAR

The pulp chamber of the upper first premolar is oriented bucco-lingually. In the great majority of cases, it has two horns – and thus two canals – beneath their respective cusps (Fig. 11.43). The orientation of the access cavity must therefore also be buccolingual, not

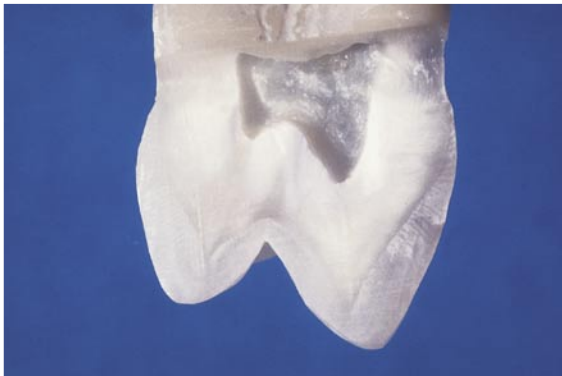

Fig. 11.43. Upper first premolar sectioned longitudinally. Beneath and within the respective cusps, one finds the pulp horns and canal openings.

mesiodistal, as with the cavity created in restorative dentistry.

The two horns are situated just within the peaks of their cusps. The orifices of the two canals are also slightly more within the horns. Thus, one can generally prepare a good access cavity without involving the cusps.

The point of entry of the bur is the middle of the central sulcus (Fig. 11.44 A), and penetration is achieved by drilling parallel to the long axis of the tooth (Figs. 10.44 B, C).

As one penetrates with the round, high-speed diamond bur, one simultaneously applies a bucco-palatal movement to the bur, so as to begin to outline the future occlusal contour of the access cavity. One must keep in mind that the bur used in the penetration phase should not create a parallel-walled tunnel; rather, drilling toward the dentin, it should create a funnel-shaped cavity using a slight helical motion.

Once the chamber is penetrated, a low-speed round bur is used on the way out, to “peel” the undercuts of dentin that remains after penetration (Figs. 10.44 D, E).

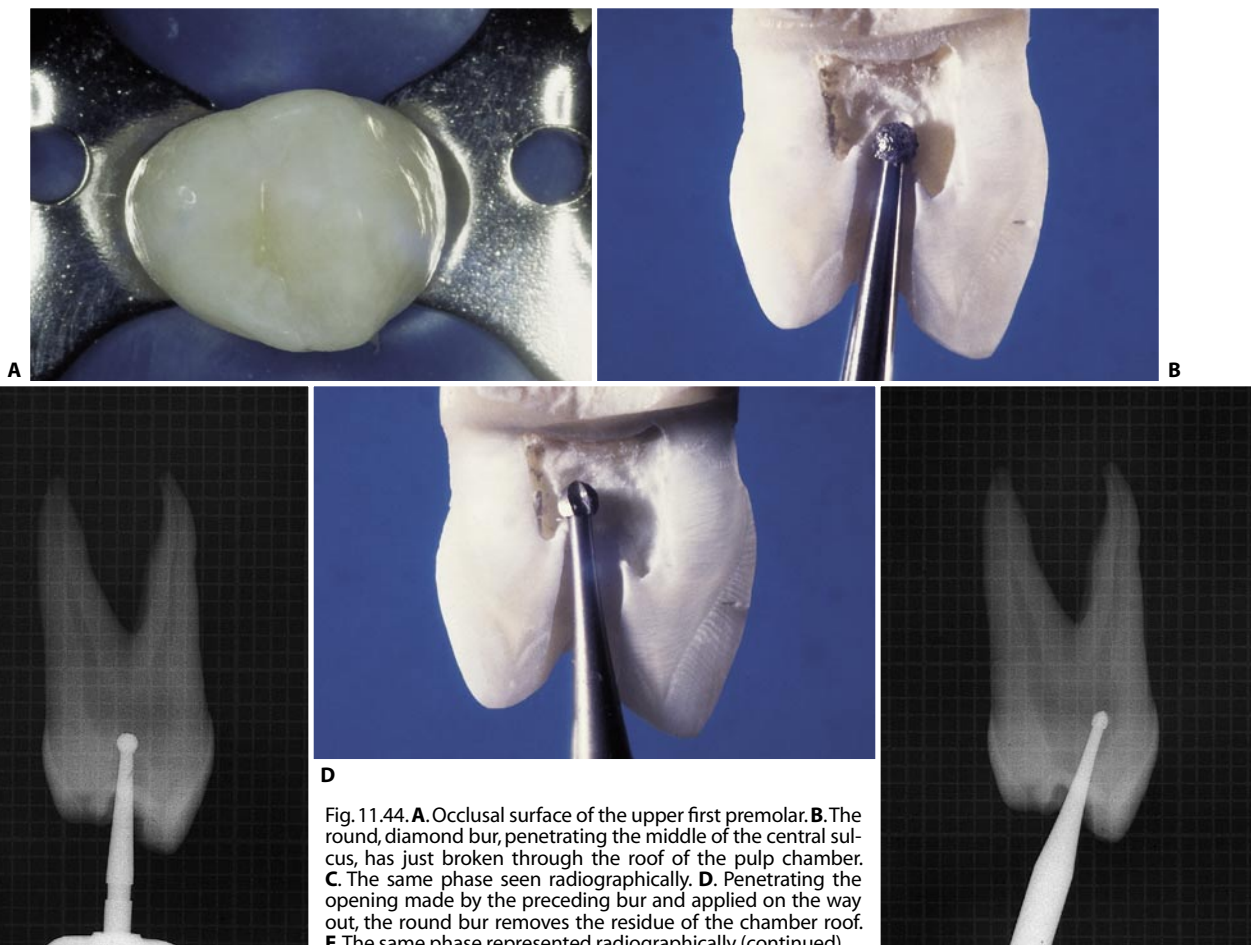


Fig. 11.44. **A.** Occlusal surface of the upper first premolar. **B.** The round, diamond bur, penetrating the middle of the central sulcus, has just broken through the roof of the pulp chamber. **C.** The same phase seen radiographically. **D.** Penetrating the opening made by the preceding bur and applied on the way out, the round bur removes the residue of the chamber roof. **E.** The same phase represented radiographically (continued).

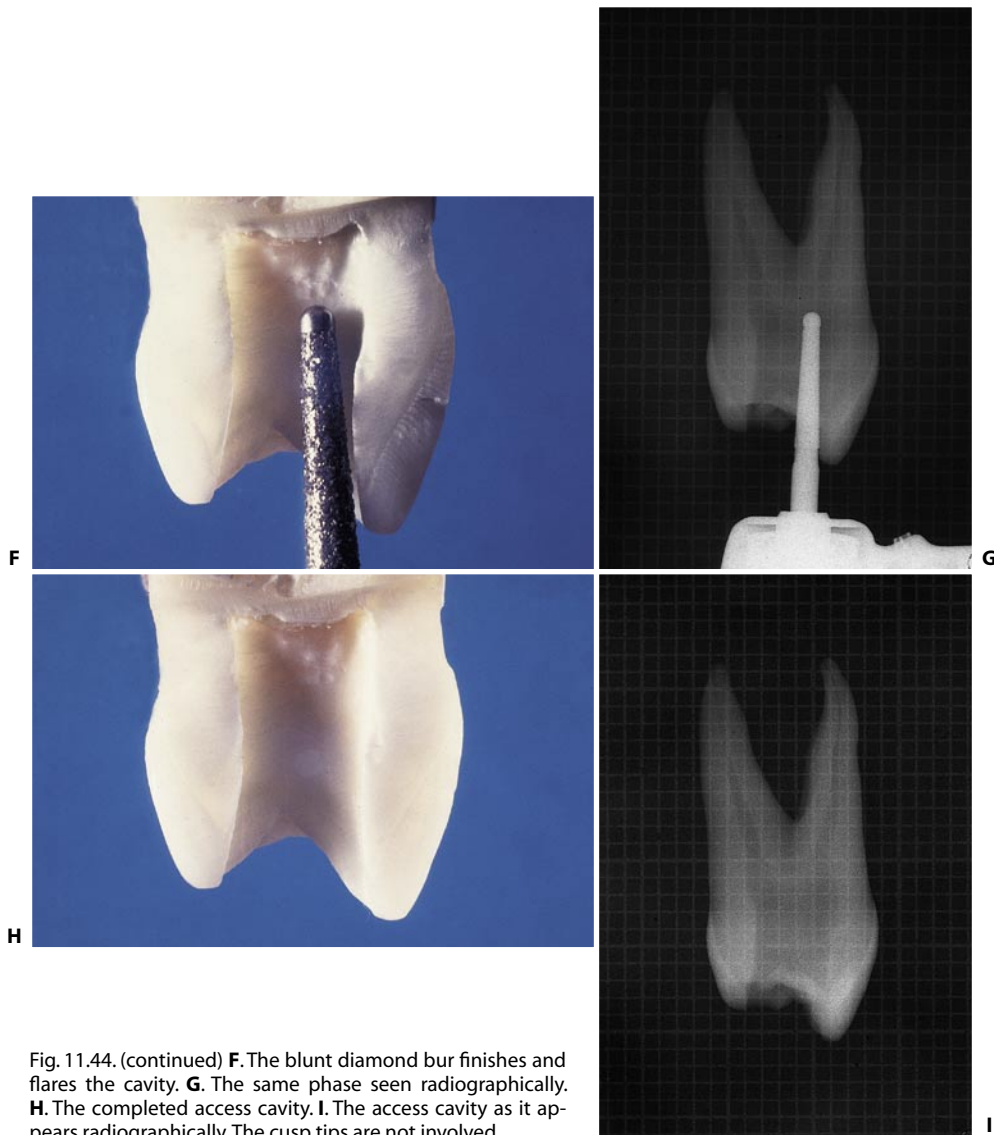


Fig. 11.44. (continued) **F.** The blunt diamond bur finishes and flares the cavity. **G.** The same phase seen radiographically. **H.** The completed access cavity. **I.** The access cavity as it appears radiographically. The cusp tips are not involved.

Then, with a non-end cutting, high-speed diamond bur, the cavity is finished and flared (Figs. 10.44 F, G). The final shape of the access cavity is ovoid. The larger diameter is oriented bucco-lingually, and it usually does not involve the cusp peaks (Fig. 10.44 H, I). Whether they are involved depends on the degree of divergence of the two roots, and therefore of the two canals. The more divergent they are, the more limited the cavity may be; on the other hand, the more parallel they are, the more likely are the cusps to be involved. The two canals, which are often joined by a shallow groove, may be located by careful examination of the pulp chamber floor (Fig. 11.45).

Anatomically, the upper first premolars may be quite variable. Bayonet curves of the apical one third of the root are typical of these teeth. Rarely, one may find

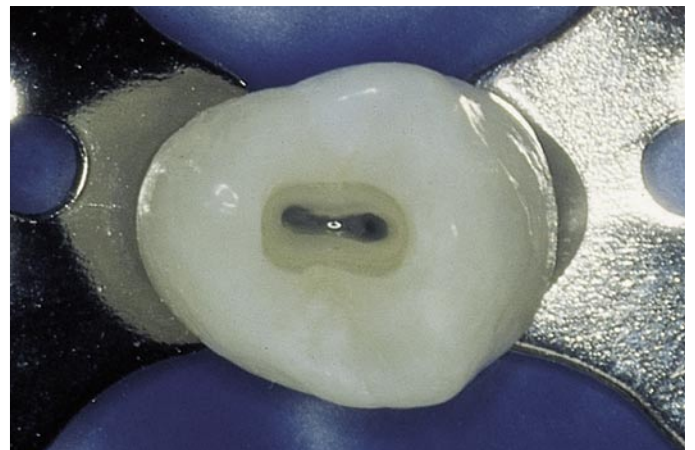


Fig. 11.45. The orifices of the two canals of the upper first premolar are often joined by a groove on the floor of the pulp chamber.

a single, elliptical canal in a single root; more often, one finds two canals with separate apical foramina in a single root, which may communicate in the middle one third (38%), or two canals, usually the same length, in two separate roots (60%).⁹² More rarely – in 6% according to Carns and Skidmore¹⁹ and in 5% ac-

cording to other authors⁸⁹ – one may find three roots containing three canals with independent apices. In these cases, the premolar has the appearance of a molar. One wider canal is situated palatally, and two thinner canals are in a buccal position, one mesial and one distal (Fig. 11.46).

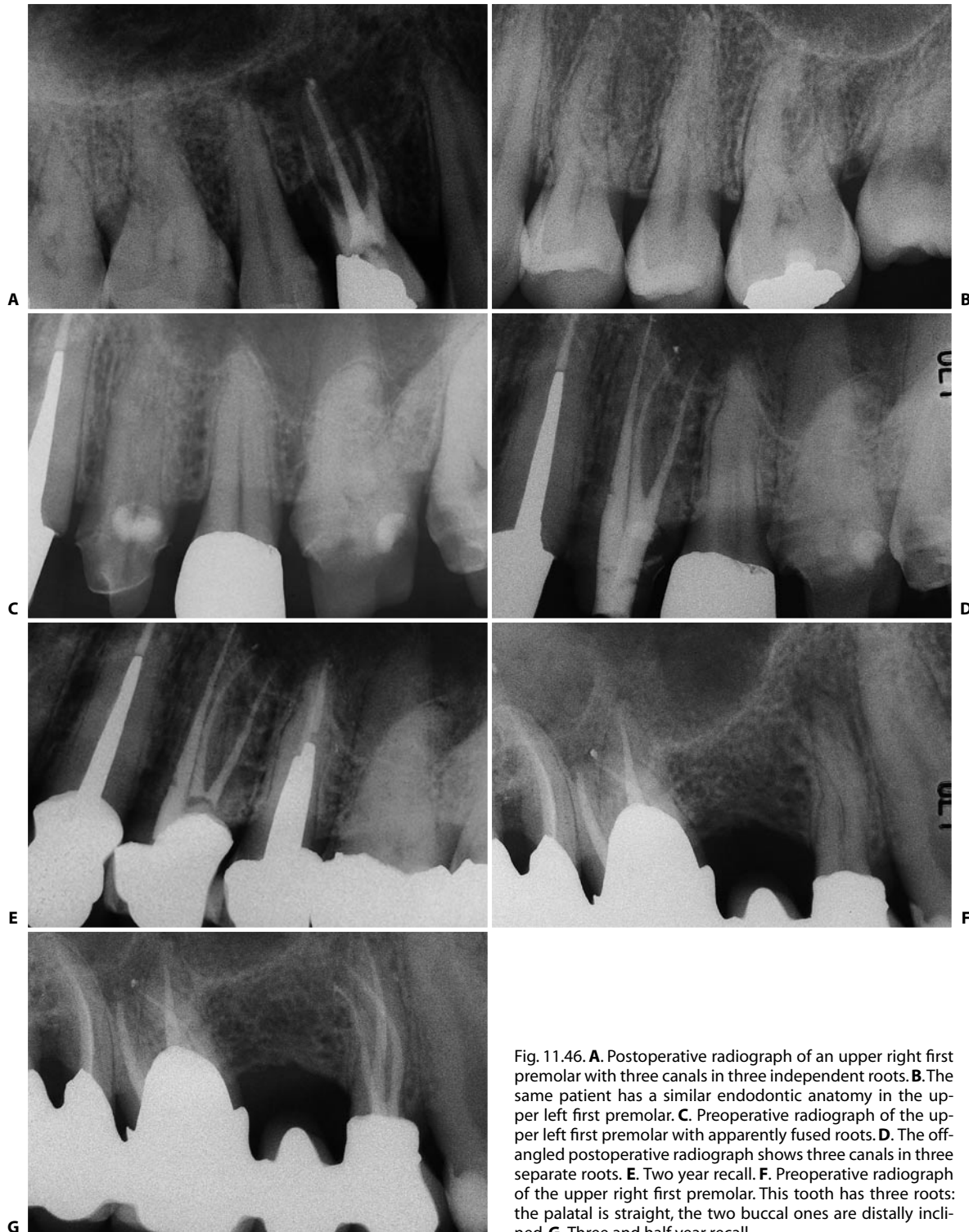


Fig. 11.46. **A.** Postoperative radiograph of an upper right first premolar with three canals in three independent roots. **B.** The same patient has a similar endodontic anatomy in the upper left first premolar. **C.** Preoperative radiograph of the upper left first premolar with apparently fused roots. **D.** The off-angled postoperative radiograph shows three canals in three separate roots. **E.** Two year recall. **F.** Preoperative radiograph of the upper right first premolar. This tooth has three roots: the palatal is straight, the two buccal ones are distally inclined. **G.** Three and half year recall.

As always, good endodontic treatment depends on the proper creation of an access cavity: upper premolars with three canals require a modified, “T”-shaped access cavity with a mesiodistal extension in the buccal portion of the traditional cavity. This modification permits good access to both buccal canals.⁷⁹ If the three roots are divergent, this can be picked up by careful examination of the preoperative radiograph.¹⁰ If they are very close together or fused (Fig. 11.47A), this may only be discovered intra-operatively. The dentist may suspect the presence of two buccal canals not just by the presence of two openings – which are often not recognizable as distinct – but by the orientation of the endodontic probe when it enters one of them or, better, by the course of the first canal which is negotiated and visualized by an intraoperative radiograph. If the instrument enters a root canal that ra-

diographically appears eccentric with respect to the profile of the root [e.g., completely displaced mesially (Fig. 11.47B)], one may harbor suspicions about the presence of a second buccal canal, whose course is more distal to the first one (Figg. 10.47C, D).

If the buccal bifurcation and therefore the presence of two roots remains undiagnosed, a perforation may occur during the preparation of a post space and the cementation of the post itself in what one might think to be the only buccal canal (Fig. 11.48).

For obvious reasons, it is always preferable to determine in advance the number of canals requiring treatment, even if only to plan better the treatment time required.

In the treatment of prosthetically-treated premolars, it can sometimes be difficult to determine whether the canal that one has found is the buccal or the palatal

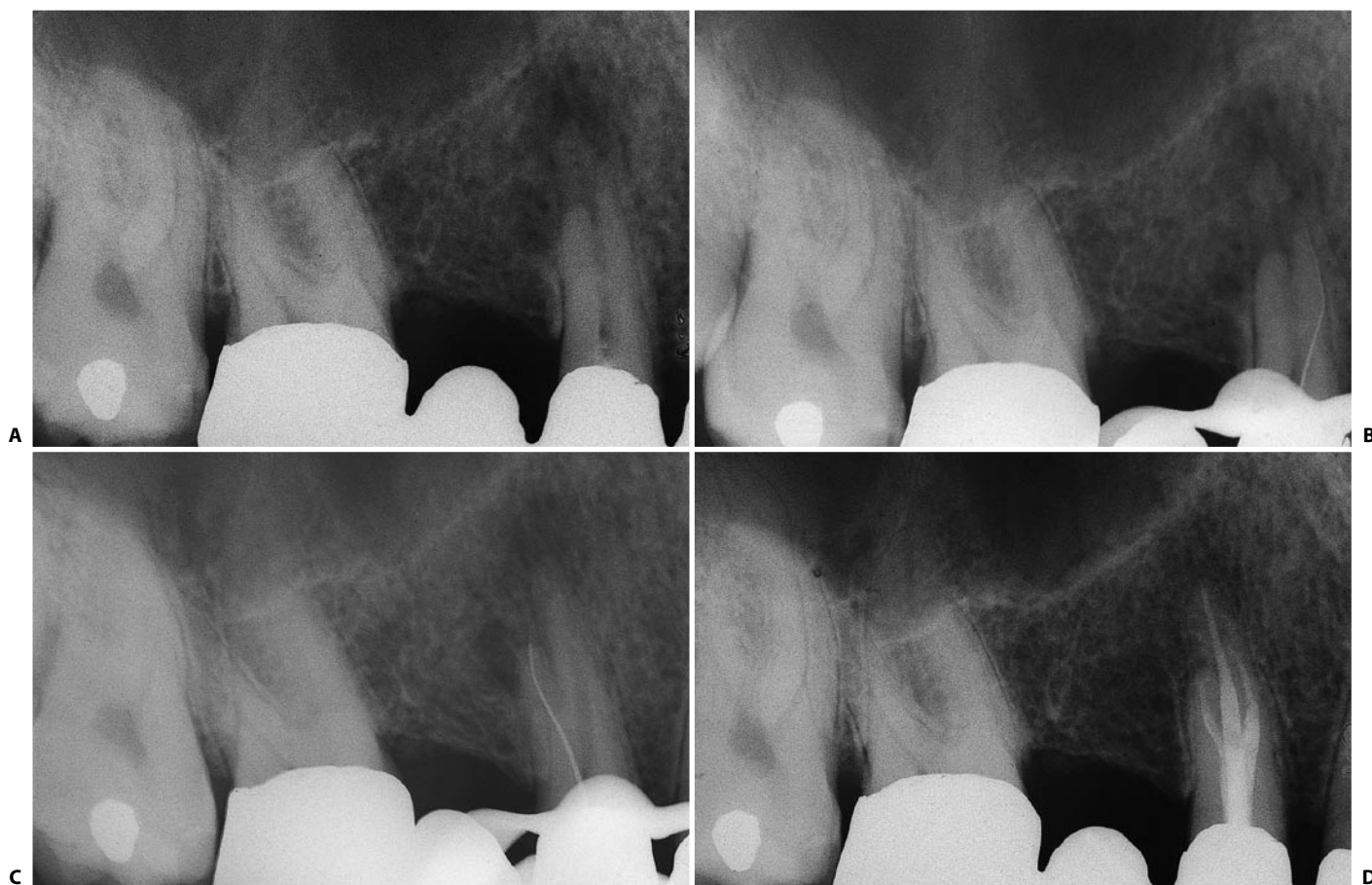


Fig. 11.47. **A.** Preoperative radiograph of an upper right first premolar. In the presence of fused roots, it may not be easy to detect the presence of three canals. **B.** The first instrument introduced in what seems to be the only buccal opening appears eccentric with respect to the shadow of the root. More precisely, it appears mesially displaced: the instrument has entered the mesiobuccal canal. **C.** Introduced into the same orifice with a distally-facing precurvature, the instrument automatically enters the distobuccal canal. **D.** Thirty-four months later, this radiograph shows the presence of three canals, as well as healing.

one. Looking for the other canal in the wrong direction is very dangerous and can lead to perforation. In these cases, the diagnosis is made very easily by examining a radiograph taken in another view and applying the buccal object rule (see Chapter 5).

Following endodontic treatment of these teeth, most endodontists are in agreement that prosthetic cusp protection should be provided to prevent vertical or crown-root fracture.¹⁷

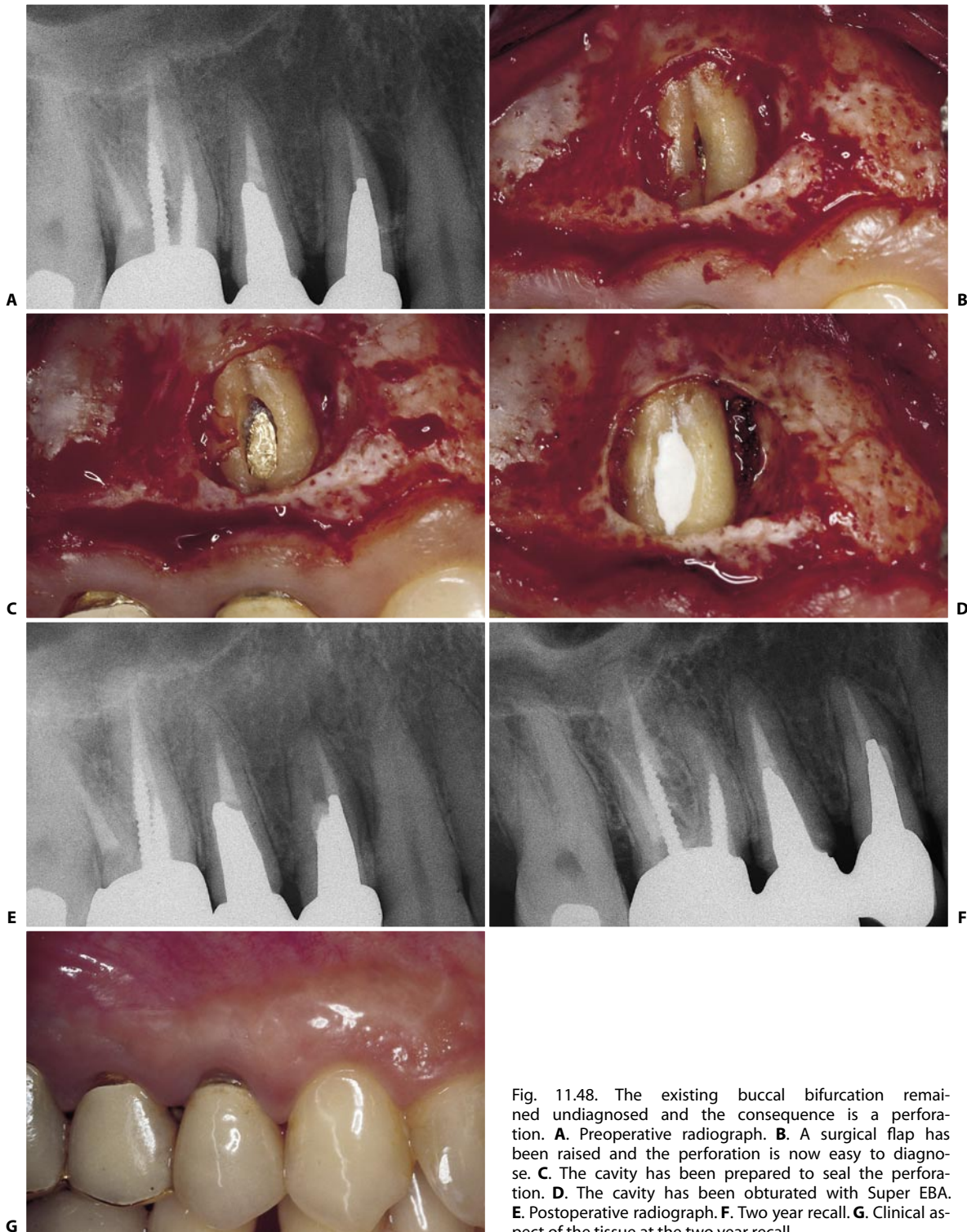


Fig. 11.48. The existing buccal bifurcation remained undiagnosed and the consequence is a perforation. **A.** Preoperative radiograph. **B.** A surgical flap has been raised and the perforation is now easy to diagnose. **C.** The cavity has been prepared to seal the perforation. **D.** The cavity has been obturated with Super EBA. **E.** Postoperative radiograph. **F.** Two year recall. **G.** Clinical aspect of the tissue at the two year recall.

UPPER SECOND PREMOLAR

The procedure for the creation of the access cavity in this tooth is the same as that for the first premolar. Weine⁹² states that the second premolar has a single root with a central, ovoid canal in 60% of cases. The canal is sometimes central, but is fissure-like; in which case, the canal is approached and prepared as though there were two, unless there is definitely only one.

The finding of a single, eccentric canal orifice (palatal, for instance) after the access cavity has been opened, indicates that there is another canal opposite to it (buccal, for instance).

In addition to presenting a single, ovoid canal, which is almost the rule, the second premolar can have two completely separate canals that run together into

a single foramen or two separate but interconnected canals.

Another possible configuration is a single canal that divides into two branches in the apical one third, one directed buccally, the other palatally (Weine classification type IV) (Fig. 11.49). If one of these two branches goes undetected (usually, the buccal one, which takes a more angulated course), this could lead to treatment failure.

If different radiographic views raise the suspicion of such a configuration, after preparing one canal one must scout the opposite wall with a small, pre-curved file. For example, after preparing the palatal aspect of the canal, one must scout with the precurvature facing buccally. If this small file binds, one has entered the buccal branch of the canal.

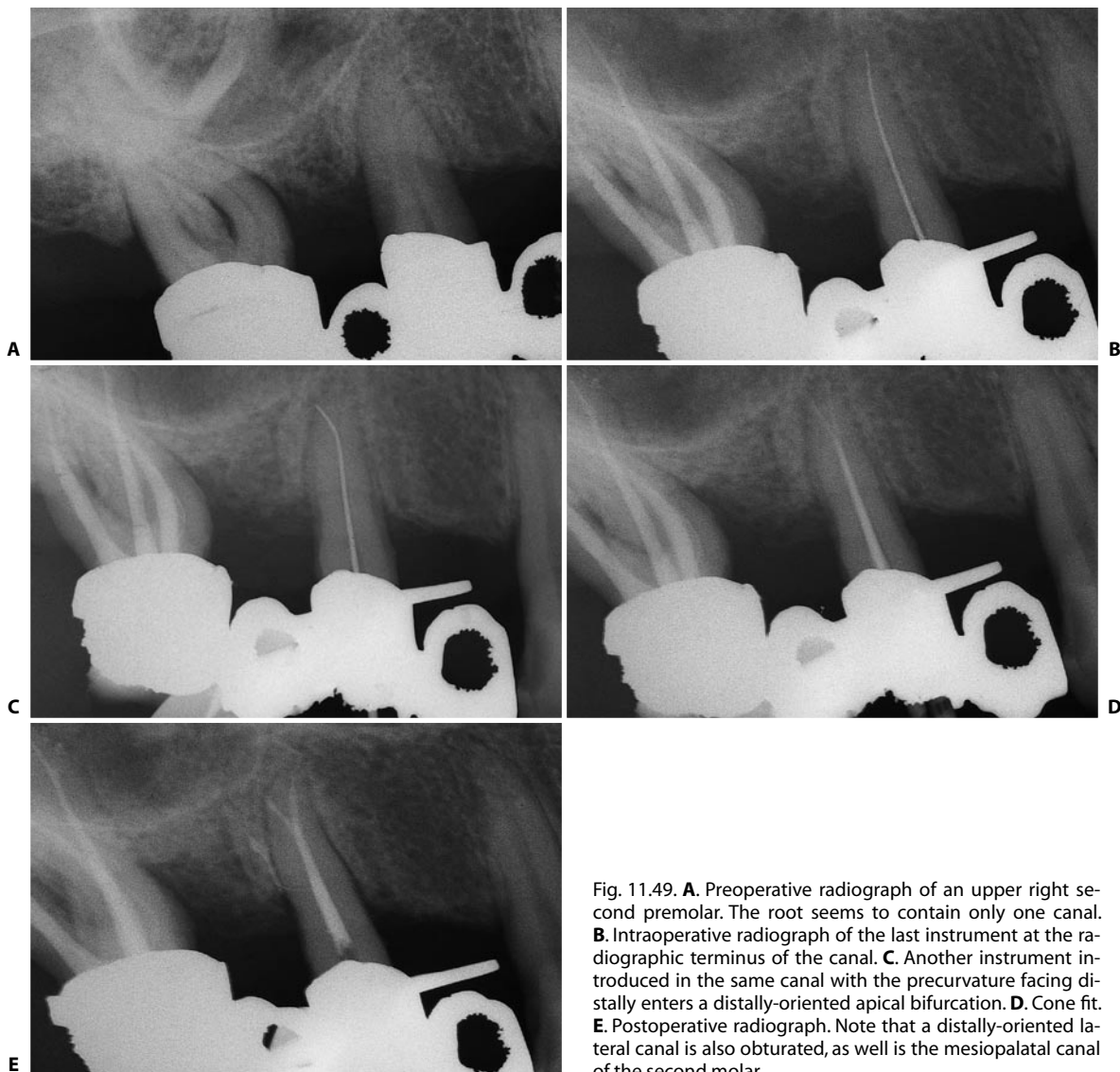


Fig. 11.49. **A.** Preoperative radiograph of an upper right second premolar. The root seems to contain only one canal. **B.** Intraoperative radiograph of the last instrument at the radiographic terminus of the canal. **C.** Another instrument introduced in the same canal with the precurvature facing distally enters a distally-oriented apical bifurcation. **D.** Cone fit. **E.** Postoperative radiograph. Note that a distally-oriented lateral canal is also obturated, as well is the mesiopalatal canal of the second molar.

The prevalence of lateral canals is quite high. The presence of three canals in three separate roots, as in a molar (Fig. 11.50), is quite rare. Weine⁹² states that it is rarer than in the first premolars. Vertucci et al.⁹⁰ claim that in only one per cent of cases do the upper second premolars have three canals. In the author's experience, the finding of three roots is more frequent in the second than the first premolars. A cer-

tain symmetry has also been noted, in that patients with such canal morphology in one premolar also have it in the contralateral premolar (Fig. 11.51).

The second premolar can also have a bayonet curvature (Fig. 11.52).

Following endodontic treatment, protection of the cusps is recommended.

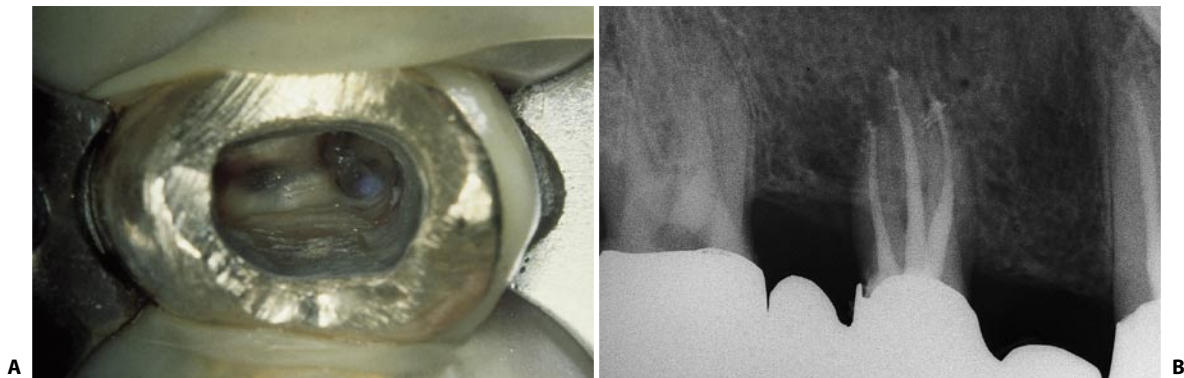


Fig. 11.50. **A.** Careful examination of the pulp chamber floor of this upper right second premolar reveals the presence of one palatal and two buccal orifices. **B.** This postoperative radiograph confirms the presence of three canals in three independent roots.

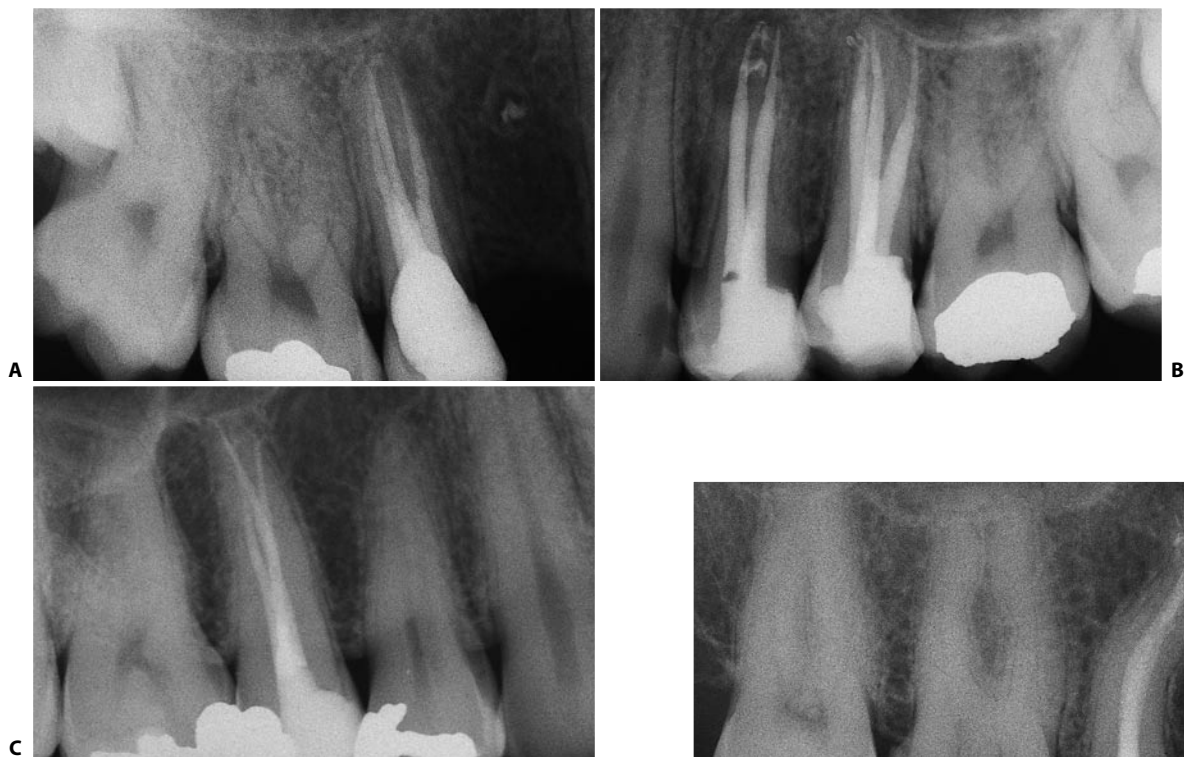

Fig. 11.51. **A.** Postoperative radiograph of an upper right second premolar. The tooth has fused roots but three canals. **B.** The same patient has the same endodontic anatomy in the upper left second premolar. The roots are slightly divergent here, and the three canals are more easily recognized. **C.** Another example of upper second premolar with three canals.

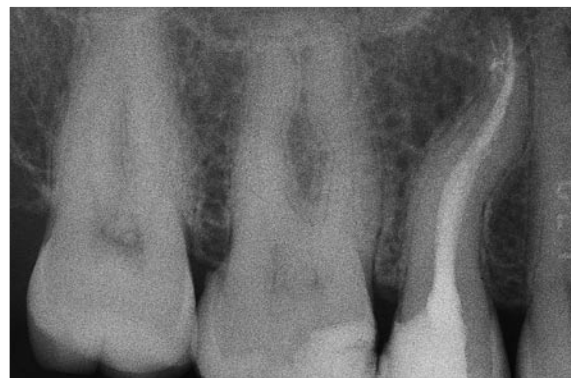

Fig. 11.52. Postoperative radiograph of an upper second premolar, with a bayonet curvature.

UPPER FIRST MOLAR

Together with the lower first molar, this is the tooth that most frequently requires endodontic therapy. It also most often conceals pitfalls or leads to failure.

In the great majority of cases, the tooth has three roots with independent canals. Rarely, there may be two roots with only two canals (Fig. 11.53). The palatal

root is the longest and round in cross-section. The distobuccal root is a little shorter, but also roundish in cross-section. The mesiobuccal root is more or less as long as the preceding one, but flatter mesiodistally.

The palatal root is very often curved buccally and this curvature is therefore not easily appreciated radiographically (Fig. 11.54 A). More apically, it is sometimes accompanied by a second, opposite curvature. In

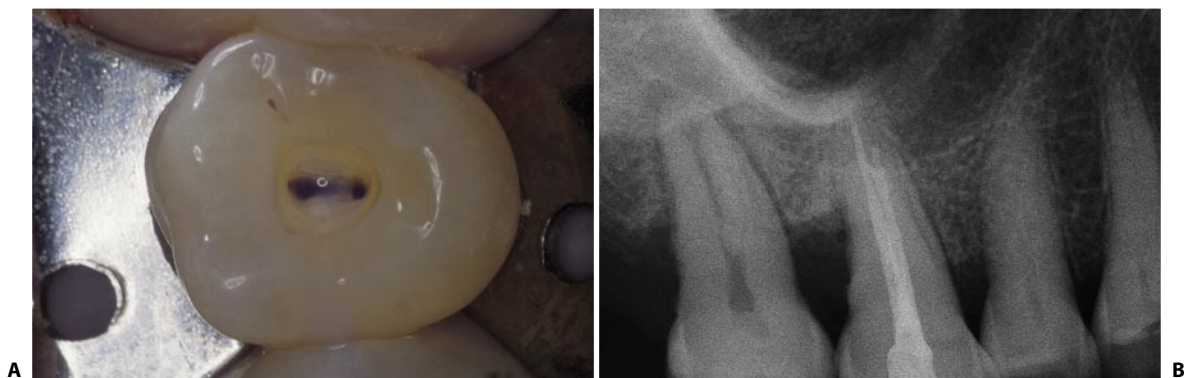


Fig. 11.53. **A.** The pulp chamber floor of this upper right first molar has two orifices, one palatal and one buccal. **B.** Postoperative radiograph of the same tooth. The longer palatal canal and a single buccal canal are visible. The latter has a small bifurcation in its apical one third.

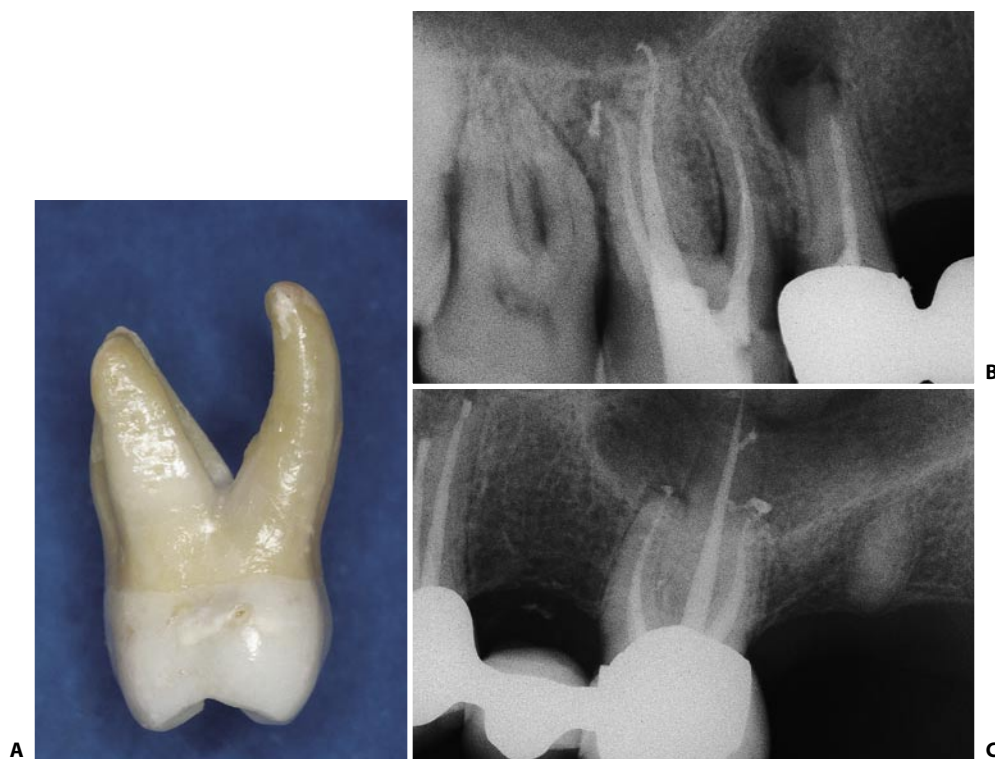


Fig. 11.54. **A.** Photograph of an upper right first molar, seen mesially. Note the curvature of the palatal root, which faces buccally. **B.** Postoperative radiograph of the upper right first molar. Note the sinuosity of the palatal canal. **C.** The palatal canal of this upper molar has a large lateral canal directed distally.

agreement with Pineda and Kuttler,⁷⁰ who have found curves in the palatal root of the upper first molars in 81% of cases, clinical experience confirms that this root should always be considered curved, until proven otherwise (Fig. 11.54 B). The orifice of the palatal canal is located beneath the mesiopalatal cusp. The root canal frequently has lateral canals, especially in its apical one third (Figs. 11.54 C, 11.55). More rarely, the palatal root contains two independent canals (Fig. 11.56). This occurs in less than two per cent of cases,⁸³ but it is equally important to be aware of this possibility. Careful examination of the pulp chamber floor may indicate that this unusual anatomy is present. Cases of upper first molars with two canals in two di-

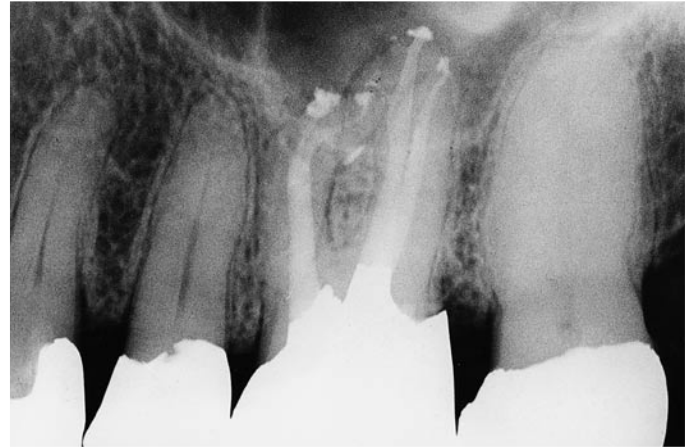


Fig. 11.55. Note the presence of numerous lateral canals in the palatal, as well as mesiobuccal, roots (Courtesy of Dr. C. J. Ruddle).

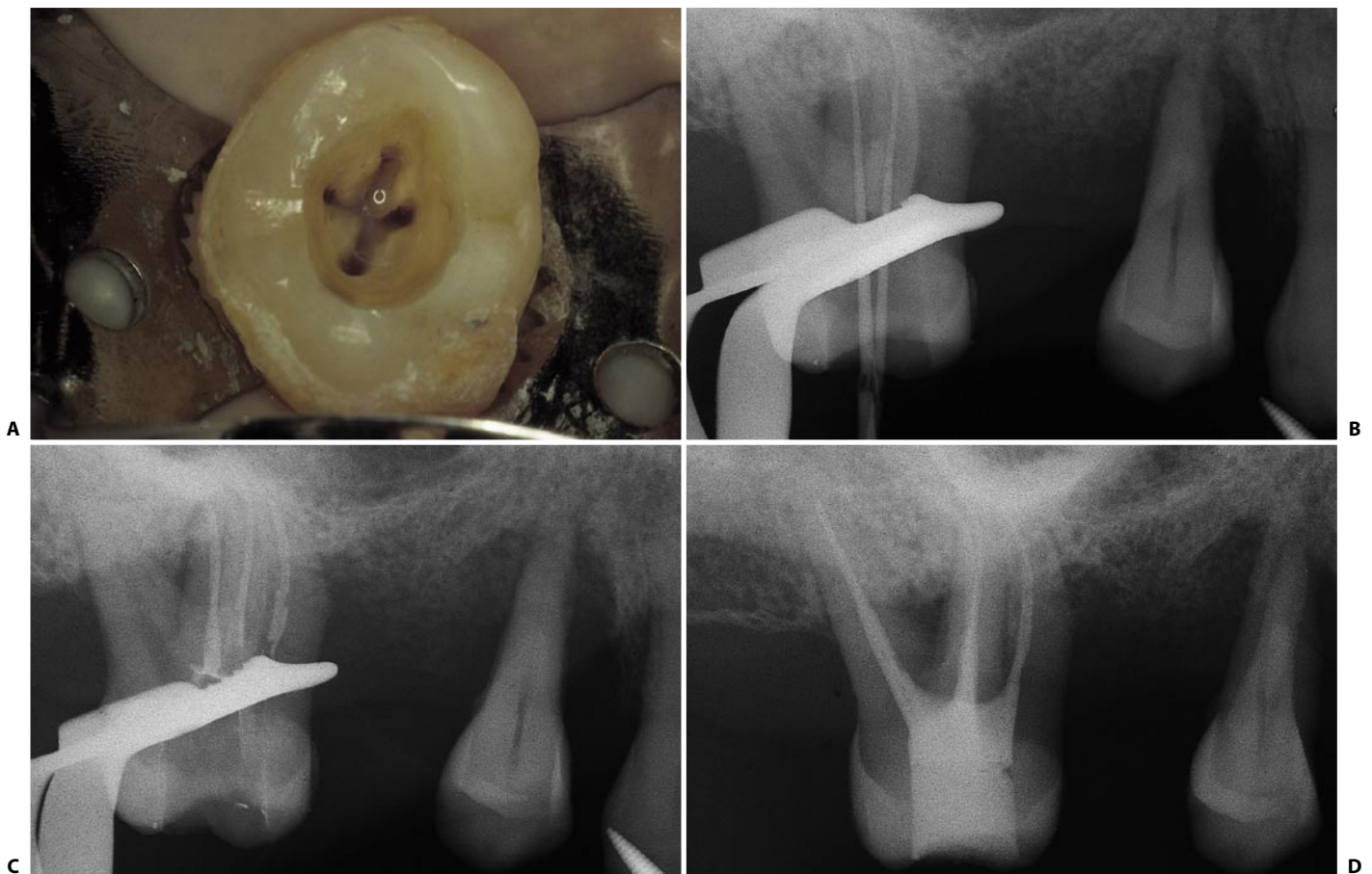


Fig. 11.56. **A.** Access cavity of the upper right first molar with two palatal canals. **B.** Intraoperative radiograph reveals two instruments within the two canals of the palatal root. **C.** Intraoperative radiograph: the two palatal canals and the mesiobuccal canal have been obturated. **D.** Postoperative radiograph.

stinct palatal roots^{30,31} (Fig. 11.57), two canals in the same root joining at a single foramen,⁸⁶ and two canals in the same root with independent foramina^{15,46} have been described.

The distobuccal root is usually quite straight, but it may be slightly curved either mesially or distally. The great majority contain one canal whose orifice is not directly related to its cusp but more palatally displaced. However, there are cases of upper molars whose distobuccal root contains two canals, the “extra” or distopalatal canal in a palatal position with respect to the main root canal (Fig. 11.58).

Of the three, the mesiobuccal root is associated with the highest degree of anatomical variability. It is quite flat mesiodistally. This is easily explained if one considers that it may contain a ribbonshape root canal or, much more often, two distinct root canals.

The percentages in which two root canals exist within this root vary according to the various authors, but they all agree on one fact: they may be present in more than half of cases [53% according to Hess,⁴⁸ 60.7%, according to Pineda and Kuttler,⁷⁰ 64% according to Smith⁸² and Nosonowitz and Brenner,⁶⁸ 69.4% according to Acosta Vigouroux and Trugeda Bosaans,² 84%,

according to Aydos and Milano,⁴ 93% according to Stropko⁸⁵ and 96,1% according to Kulid⁵⁶ (Tab. I).

Table I

“In vitro” and “in vivo” (*) frequency of mesio=palatal (MB2) canal in upper first molars (adapted from Marini et al. ⁶³)					
Author	year	number of teeth	% of MB”	1 apical foramen	2 apical foramina
Hess	1925	513	53,0%	-	-
Okamura	1927	-	53,0%	-	-
Weine	1969	208	51,5%	37,5%	14,0%
Pineda e coll.	1972	262	60,7%	12,2%	48,5%
Pineda	1973	245	54,3%	31,5%	22,8%
Aydos e coll.	1973	171	84%	59,0%	25,0%
Nosonowitz e coll.	1973	336	64,6%	54,8%	9,8%
Green	1973	100	36,0%	22,0%	14,0%
Seidberg e coll.	1973	100	62,0%	31,0%	31,0%
		*201	33,3%	-	-
Lane	1974	273	56,4%	19,4%	37,0%
Pomeranz e coll.	1974	100	69,0%	21,0%	48,0%
		*100	31%	-	-
Slowey	1974	103	50,4%	-	-
Vertucci	1974	100	55,0%	37,0%	18,0%
Vande Voorde	1975	97	50,0%	-	-
Smith	1977	50	64,0%	20,0%	44,0%
Acosta Vigouroux	1978	134	69,4%	-	-
Vertucci	1984	100	55,0%	37,0%	18,0%
Mondani	1984	100	21,0%	7,0%	14,0%
Neaverth e coll.	1987	*228	77,2%	15,4%	61,8%
Malagnino	1988	100	50,0%	23,0%	27,0%
Weller e coll.	1989	*835	39,0%	-	-
Lavagnoli e coll.	1989	50	39,6%	-	-
Kulid e coll.	1990	51	96,1%	54,2	45,8
Gilles e coll.	1990	21	90%	-	33,0
Fogel e coll.	1994	208	71,2	68,3	31,7
Stropko	1999	*80	93%	37,5%	62,5%

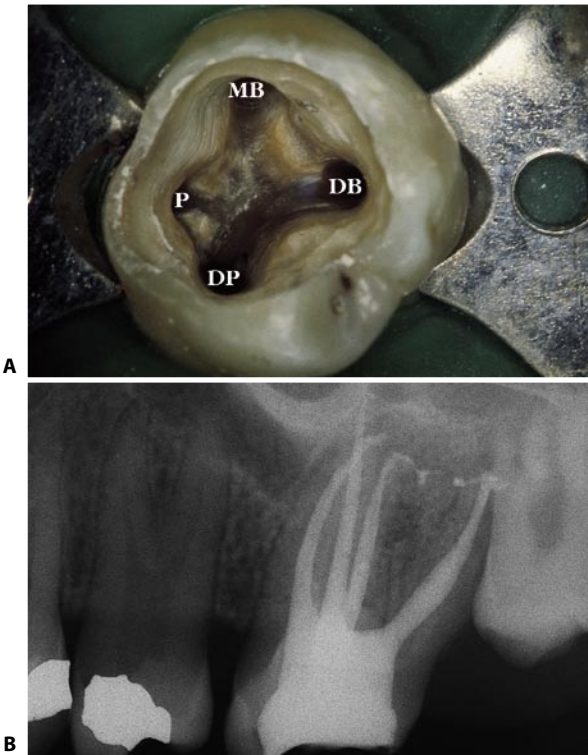


Fig. 11.57. A. Access cavity of an upper left first molar with two palatal canals in two distinct roots: P, palatal canal; MB, mesiobuccal canal; DB, distobuccal canal; DP, distopalatal canal. B. Postoperative radiograph of the same tooth.

From this table we can note, particularly in old studies, that discrepancies in the number of canals identified exist between in vitro and in vivo studies. This may be because clinicians encounter difficulty in negotiating some of these canals and, therefore, they don’t count them just because they are not treatable. With the use of new technology, several authors have more recently reported a higher success rate in the identification and treatment of these canals. The operating microscope, with its magnification and coaxial illumination, ultrasonic tips and methylene blue are

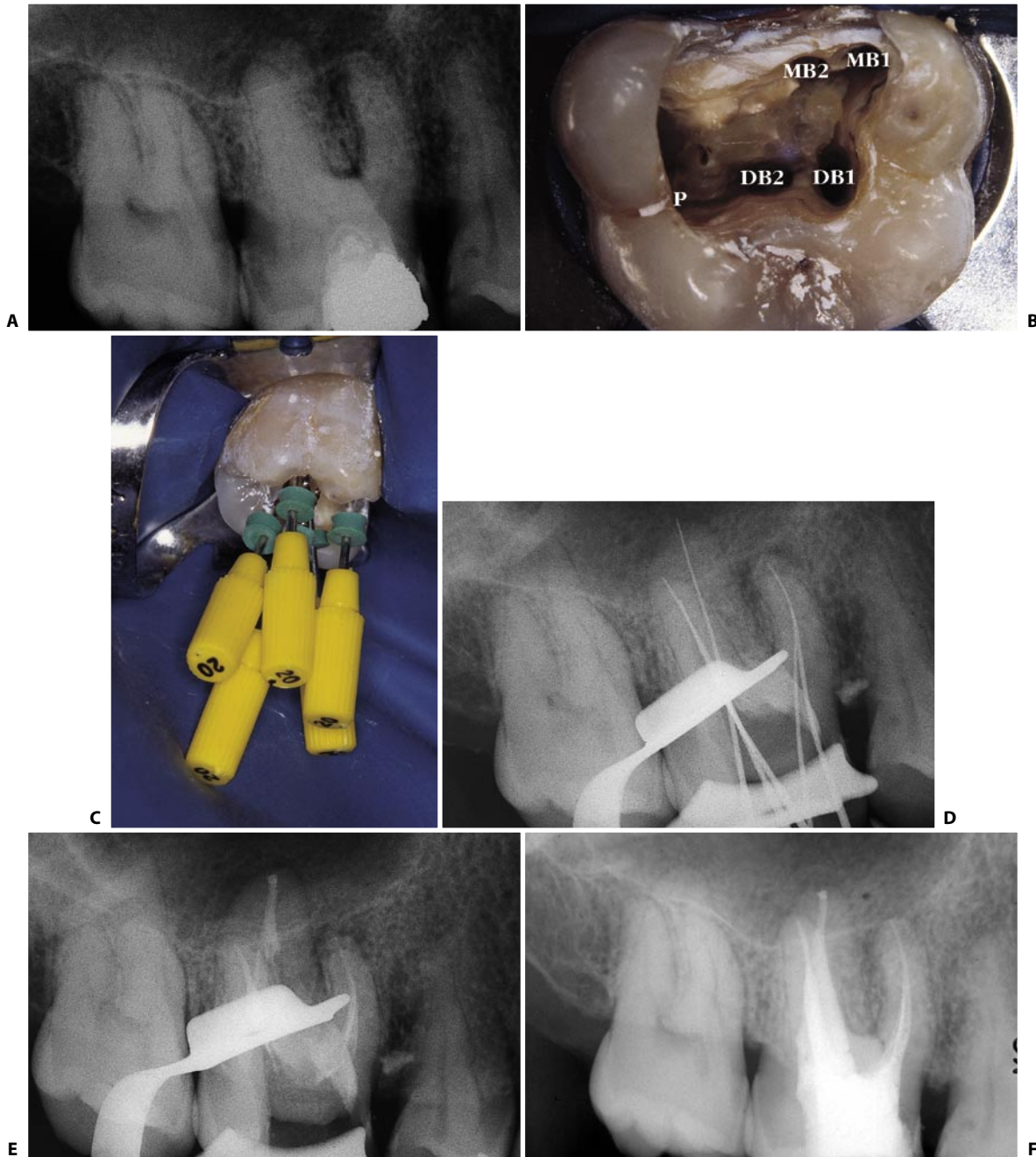


Fig. 11.58. **A.** Preoperative radiograph of an upper right first molar with five canals, two of which are in the distobuccal root. **B.** The access cavity reveals the five openings after the canals have been cleaned and shaped. **C.** Five instruments introduced into their respective five canals (the 5 instruments have been introduced in each canal only for documentation, and not to check 5 working lengths at the same time!). **D.** Intraoperative radiograph. **E.** Radiograph of the apical compaction. The five canals don't seem to have independent foramina. **F.** Postoperative radiograph.

only some of the factors, which contributed to increase those percentages.⁵²

This data also indicates that clinicians should *always* consider the presence of two canals in the mesiobuccal root of upper first molars, at least unless a careful examination has demonstrated the opposite. Clinicians must be convinced that MB2 does exist in

the mesiobuccal root of upper molars in 100% of cases and therefore these teeth must be considered having 4 root canals.

Particularly interesting is the recent study of John Stropko,⁸⁵ who demonstrated that the second canal of the mesiobuccal root is present “in vivo” in 93% of cases and it is negotiable to the apical foramen in 90% of

cases. Stropko in his article says that the high percentage he found was due to the utilization of the operating microscope and that in some instances, it would have been very difficult, if not impossible, to observe the MB2 orifice if the microscope was not being utilized. It was also of interest to note that studies utilizing microscopes have reported a significantly higher percentage of MB2 canal system occurrence^{42,56,75} than studies using other means of determination.^{38,48,78}

The orifice of the “MB2” – more appropriately named “mesiopalatal canal” – is located on the groove that joins the palatal and mesiobuccal canals at a variable distance from the latter (Figs. 11.59 A, B). In looking for it, it may be helpful to search for a small depression at the level of the above-mentioned groove, where the point of the endodontic probe is engaged. Sometimes, however, the probe cannot enter, because it encounters the mesial wall of the pulp chamber where it forms a very acute angle with the floor that hampers the visual and tactile detection of the canal opening (Fig. 11.59 C). The mesial wall of the pulp chamber has a dentinal shelf, which frequently hides the underlying MB2 orifice (Fig. 11.60 A).

Because of this angle, MB2 can be very difficult to negotiate. In the first 1-3 mm the root canal is sharply angled in a mesial direction, and this is the reason why sometimes the tip of the file doesn't progress apically more than a few millimeters and stops against the mesial wall. Therefore, before negotiating the canal, it is always necessary to open that angle, to remove from the mesial wall of the access cavity the shelf of dentin which is hiding the orifice of the canal, in order to get a straight-line access to the root canal itself. This can be done easily, safely and efficiently with ultrasonics and the specific tips, like CPR and ProUltra (Fig. 11.60 B). If the clinician removes the shelf of dentin with hand files instead of using ultrasonics, the orifice of MB2 appears like the one of figure 11.59 D.

There are a number of strategies that, when used in combination, greatly increase the identification of the MB2 orifice and system.⁷⁵ The most useful concepts and techniques include:

- First of all, strongly believe that MB2 is always present!
- Use of magnification, starting from loops and magnification glasses (2,5x – 4x) up to the operating microscope.

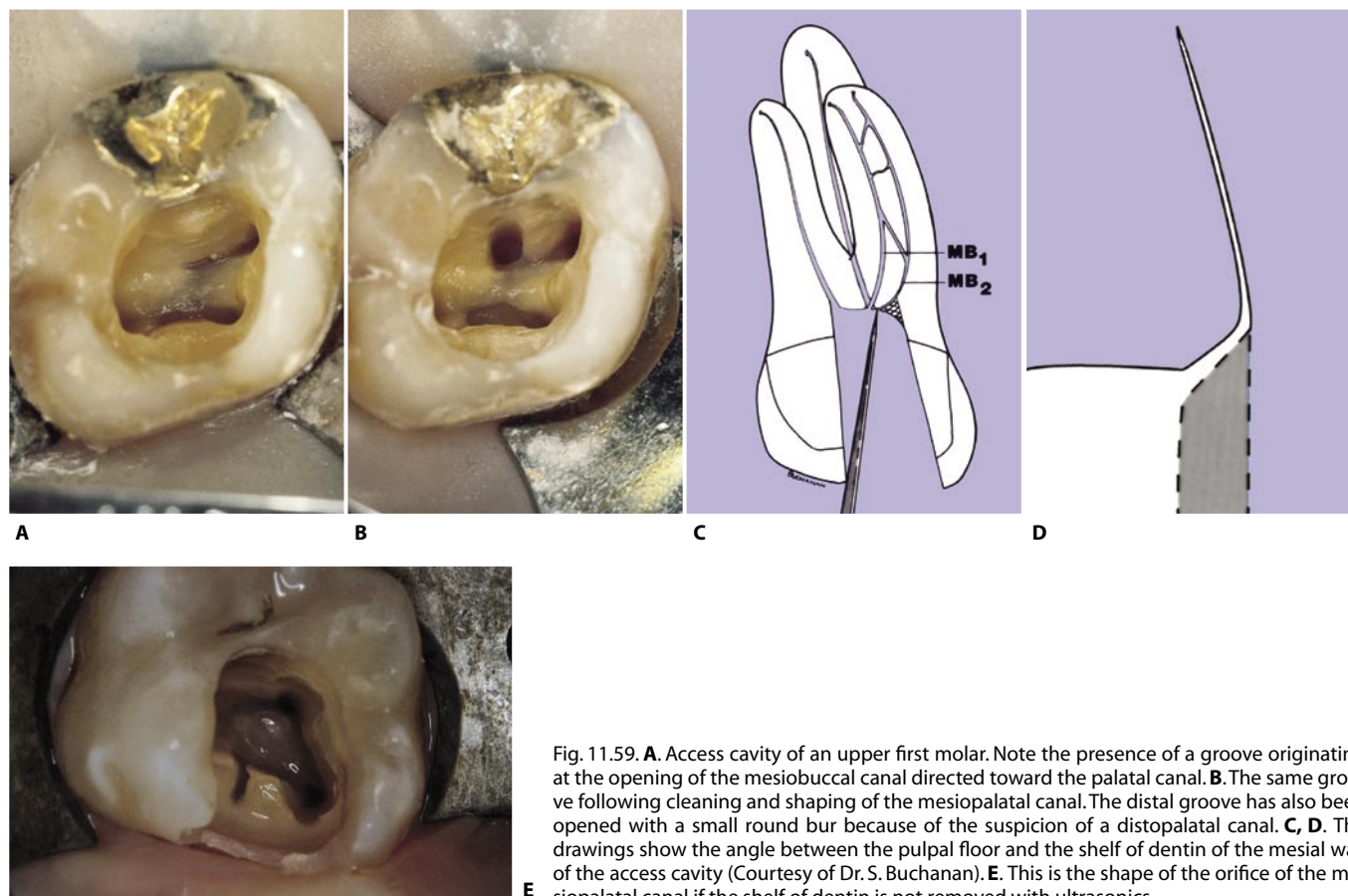


Fig. 11.59. **A.** Access cavity of an upper first molar. Note the presence of a groove originating at the opening of the mesiobuccal canal directed toward the palatal canal. **B.** The same groove following cleaning and shaping of the mesiopalatal canal. The distal groove has also been opened with a small round bur because of the suspicion of a distopalatal canal. **C, D.** The drawings show the angle between the pulp floor and the shelf of dentin of the mesial wall of the access cavity (Courtesy of Dr. S. Buchanan). **E.** This is the shape of the orifice of the mesiopalatal canal if the shelf of dentin is not removed with ultrasonics.

- c) Start looking for MB2 only after MB1 is completely cleaned and shaped and, in theory, is ready for obturation.
- d) Use a piezo-electric ultrasonic unit along with specially designed tips (CPR, ProUltra) to remove the dentinal shelf hiding the underlying orifice.
- e) Use of 1% solution of Methylene Blue dye, to road map the anatomy by penetrating into orifices.
- f) Flood the pulp chamber with a warm 5% solution of sodium hypochlorite to conduct the “champagne” or “bubble” test. The clinician can frequently visualize bubbles emanating from organic tissue, which is being digested in the extra canal, and rising towards the occlusal table.
- g) Irrigate with 17% EDTA to remove the smear layer, then with pure alcohol and then air-dry with a Stropko irrigator fitted with a 27-gauge notched endodontic irrigating needle.
- h) Use multiple obliquely angled radiographs (distomesial inclination in particular) both preoperatively and intraoperatively: the broader the root, the greater the likelihood of a second canal system.

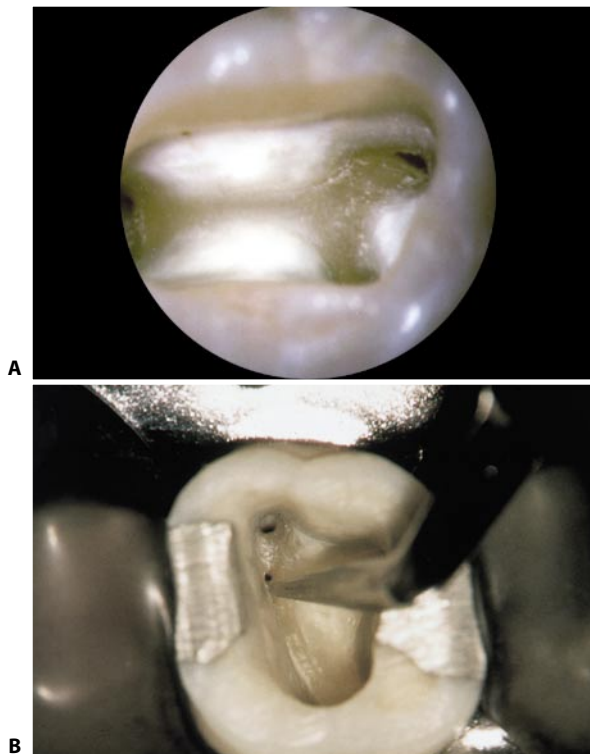


Fig. 11.60. **A.** A photograph taken at 12x reveals the orifice of the mesiobuccal canal and related groove. A dentinal shelf frequently hides the underlying orifice of the mesiopalatal canal. **B.** After establishing a straight-line access, an appropriately selected ultrasonic tip easily, rapidly and safely eliminated the dentine shelf and exposes the more palatal mesiopalatal orifice (Courtesy of Dr. C.J. Ruddle).

- i) Know the endodontic anatomy. The two canals do not always have separate foramina (Fig. 11.61); more often, they join together in a single foramen (Fig. 11.62). Awareness of the existence of such a communication is important in determining the degree of preparation of the mesiopalatal canal.²² If the two canals join in

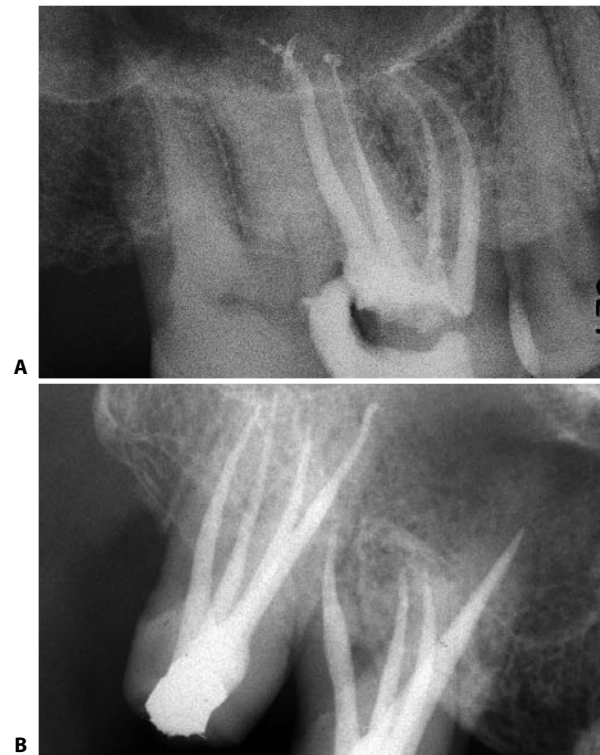


Fig. 11.61. **A.** Postoperative radiograph of the upper right first molar with a mesiopalatal canal with an independent foramen. **B.** In this patient, both the upper right first and second molars reveal a mesiopalatal canal with an independent foramen.

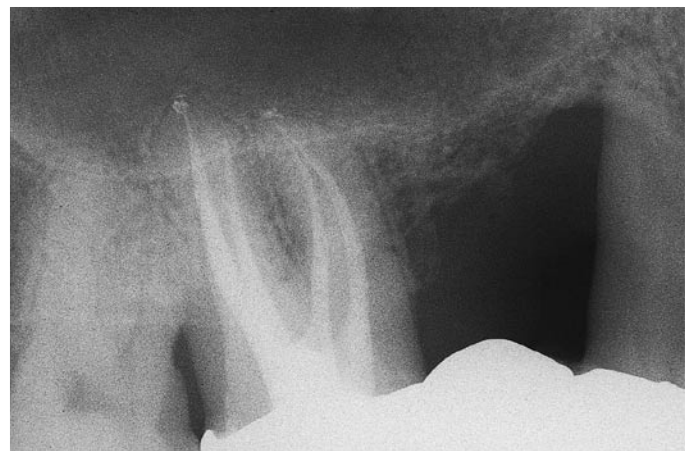


Fig. 11.62. Postoperative radiograph of an upper right first molar with mesiobuccal and mesiopalatal canals joining together at a common foramen.

a common foramen (Fig. 11.63), lesser instrumental preparation of this canal can be justified. A gutta-percha cone will later be condensed in the merging mesiopalatal canal so as to terminate against the cone inserted into the mesiobuccal canal, to which sealing of the common foramen is entrusted. With the aim of preventing excessive weakening of the root, which is quite thin and curved mesiodistally, and concave and thinner buccolingually (Fig. 11.64), this is done so as not to risk stripping of the root or subsequent fracture. As will be discussed in more detail in the next chapters, the introduction of files in the common portion of the root canal coming from MB2 could tear the foramen, brake the files, especially if the two canals join with a 90° angle, like in figure 11.63.

Cases with three canals in the mesiobuccal root have been described^{8,65} (Figs. 11.65-11.67).

The mesiobuccal root is often curved distally. The degree of curvature varies from case to case. One must keep this in mind during cleaning and shaping, since it will be necessary to modify the working length of the

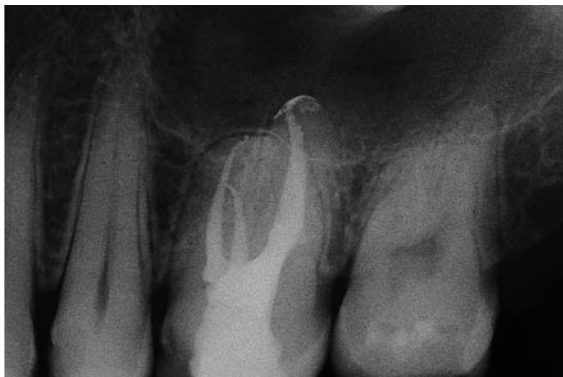

Fig. 11.63. The mesiopalatal canal is joining the mesiobuccal with a 90° angle. In such a case, to go to the same working length coming from the mesiopalatal canal is very dangerous and useless!

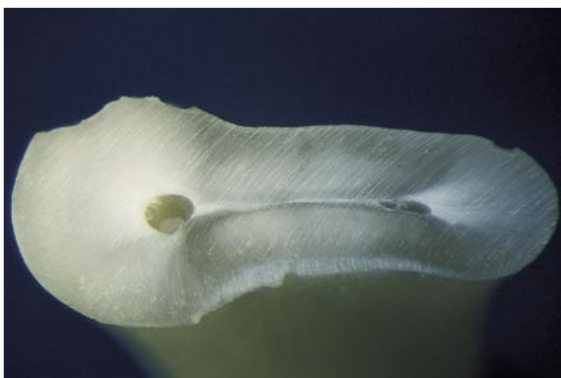

Fig. 11.64. Cross section of the mesiobuccal root of an upper first molar: the root is concave on the distal aspect, both canals are pretty close to the bifurcation, and the root is thinner in a palatal direction.

instruments and always use the “anticurvature” filing method described by Abou-Rass et al.¹ (Fig. 11.68).

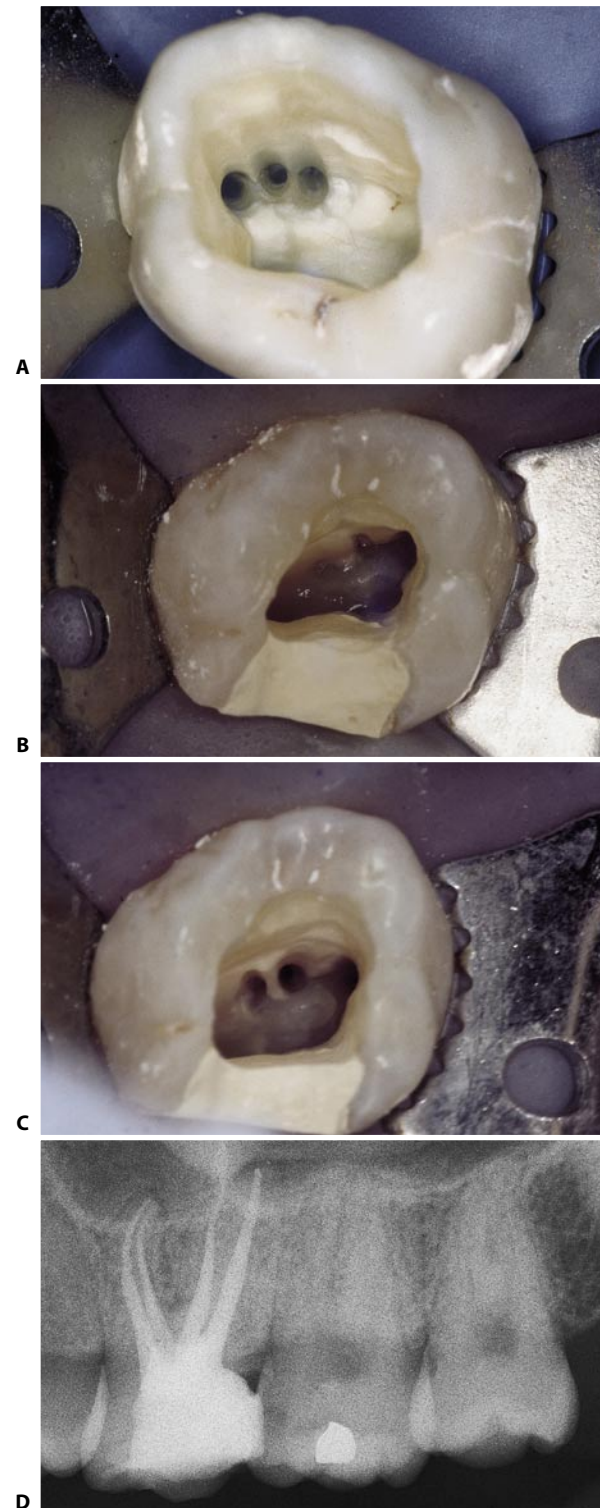


Fig. 11.65. **A.** The access cavity of this extracted molar shows three canals in the mesiobuccal root. **B.** Careful examination of the access cavity of this upper molar shows the presence of a third opening near the orifice of the mesiopalatal canal. **C.** The three canals have been cleaned and shaped. **D.** Postoperative radiograph: MB2 and MB3 were joining together.

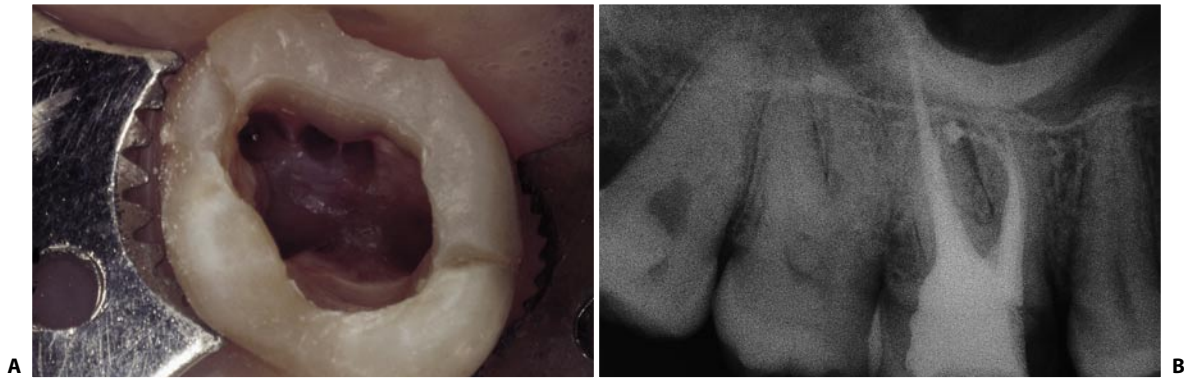

Fig. 11.66. **A.** Access cavity of an upper first molar. The mesiobuccal root has three canals. **B.** The postoperative radiograph shows three canals with independent foramina.

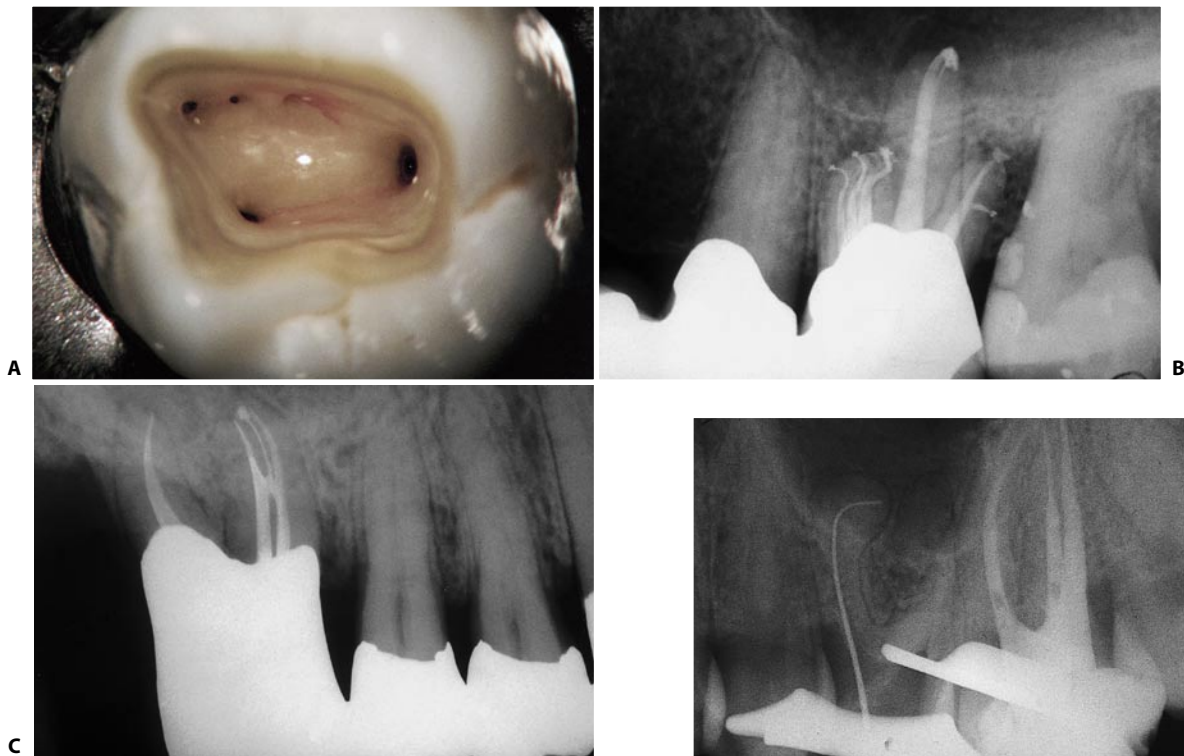

Fig. 11.67. **A.** The operating microscope offers excellent documentation and vision at 15x. Note the three orifices in the mesiobuccal root of this upper molar. **B.** The pack reveals three mesiobuccal systems with significant apical one-third recurvature, palatal bifidity, and a significant lateral canal off the distobuccal system. **C.** The most posterior abutment has had a palatal root amputation and the buccal roots were treated endodontically. Note the mesiobuccal root has three canals, one originating from the isthmus present between the other two (Courtesy of Dr. C. J. Ruddle).

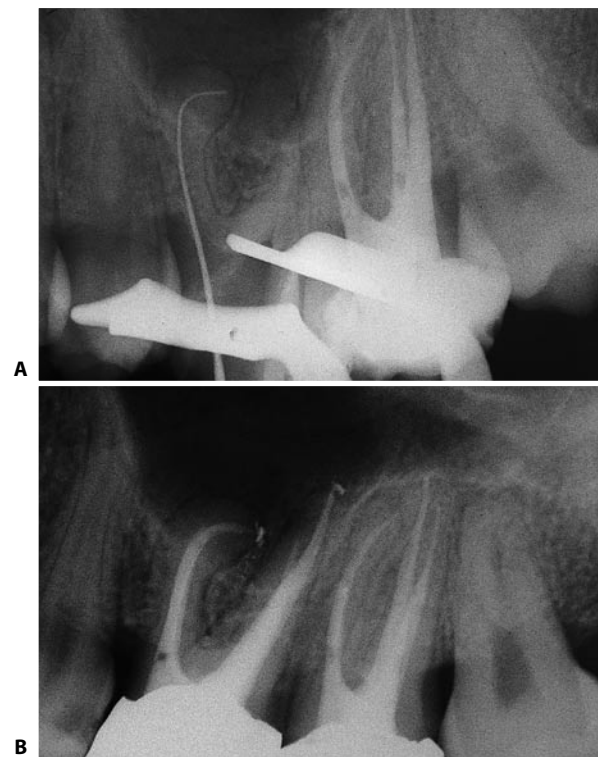


Fig. 11.68. **A.** Radiograph checking the working length of the mesiobuccal canal. Note the considerable degree of curvature of the canal. **B.** Two year recall.

The presence of two canals in the mesiobuccal root is also of great importance from the Surgical Endodontics point of view.

When the root is beveled, one must always look for a second orifice more palatal to the first. One must maintain the same level of suspicion as when one suspects the presence of a mesiopalatal canal in clinical Endodontics, which means *always*. Although the two canals often join in a single foramen, when surgery is undertaken two separate orifices are found, because beveling the apex eliminates the part of the canal that is common to both. Therefore, the surgical apical seal will require two retrofillings always joined together to form a figure “eight” (Fig. 11.69), because, as it will be described in the surgery chapter, between the two canals there is always an isthmus,⁹⁷ which must be included in the retroprep and sealed. Furthermore, the root is thinner palatally than buccally; as a consequence, the surgical bevel of the root must be lowered considerably to find sufficient dentin around the mesiopalatal canal to prepare within it the cavity for the retrofilling.

A transverse section at the level of the cervical zone of the upper first molar (Fig. 11.70) reveals that the pulp chamber floor takes the form of a quadrilateral with four unequal sides.⁹²

Most authors describe the access cavity of the upper and lower molars as a triangle whose opening is displaced into the most mesial portion of the crown⁵³ (Fig. 11.71 A-D). However, since the floor of these molars takes the shape of a quadrilateral, it is clear that the access cavity should also have a similar shape.

As already stated, the access cavity may be considered to be the projection of the pulp chamber floor onto the occlusal surface. It therefore must have a quadrilateral shape with rounded corners^{21,92,96} (Figs. 11.71 E-G). The shortest side of the quadrilateral is usually the palatal side; the next longest is the buccal side, which is slightly inclined palatally because the distobuccal canal is displaced in that direction; the next longest is the distal side; and the longest is the mesial side.

Regarding the position of the pulp chamber floor with respect to the lateral walls, Acosta Vigouroux and Trugeda Bosaans² have found in 134 extracted teeth that the floor was exactly in the center of the dental crown. One must keep this in mind during preparation of a correct access cavity.

Preparation of the access cavity begins with a round, diamond bur mounted on a high speed handpiece and applied at the level of the central fossa. It is incli-

ned toward the pulp horn that radiographically seems widest, generally the palatal one (Figs. 11.72 A-C). With the low-speed, long-shafted round bur, the dentin undercuts are removed, proceeding internally to externally (Figs. 11.72 D-E). Finally, the self-guiding diamond bur on high speed is used for the finishing and flaring (Figs. 11.72 F-I).

If one encounters difficulty in locating the canals, one should always begin by preparing the palatal canal, which is generally the widest, straightest, and thus easiest. Irrigation with sodium hypochlorite will help to orient one better in the search for the orifices of the other root canals.

Following endodontic therapy, protection of the cusps is advisable to avoid cusp or crown-root fractures.

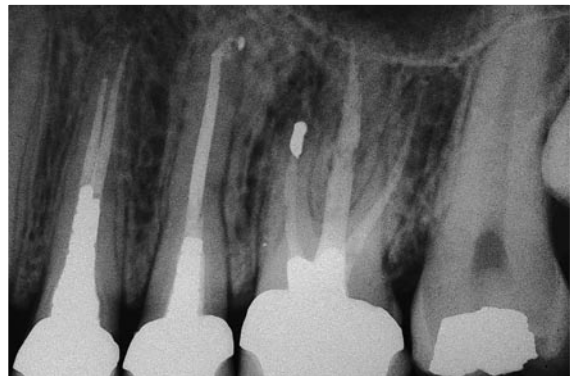

Fig. 11.69. Recall radiograph two years after apicectomy with retrofilling of the two canals of the mesiobuccal root. The two fillings are joined, since the two canals communicate with one another through a thin isthmus, which has been included in the cavity for the retrofilling.

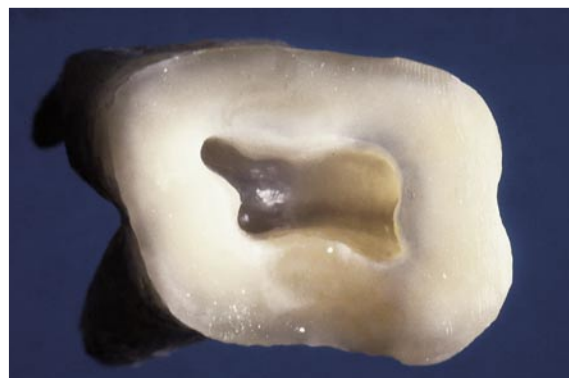

Fig. 11.70. Cross-section of an upper first molar, at the level of the cervical area. The shape of the pulp chamber floor is that of a scalene quadrilateral.

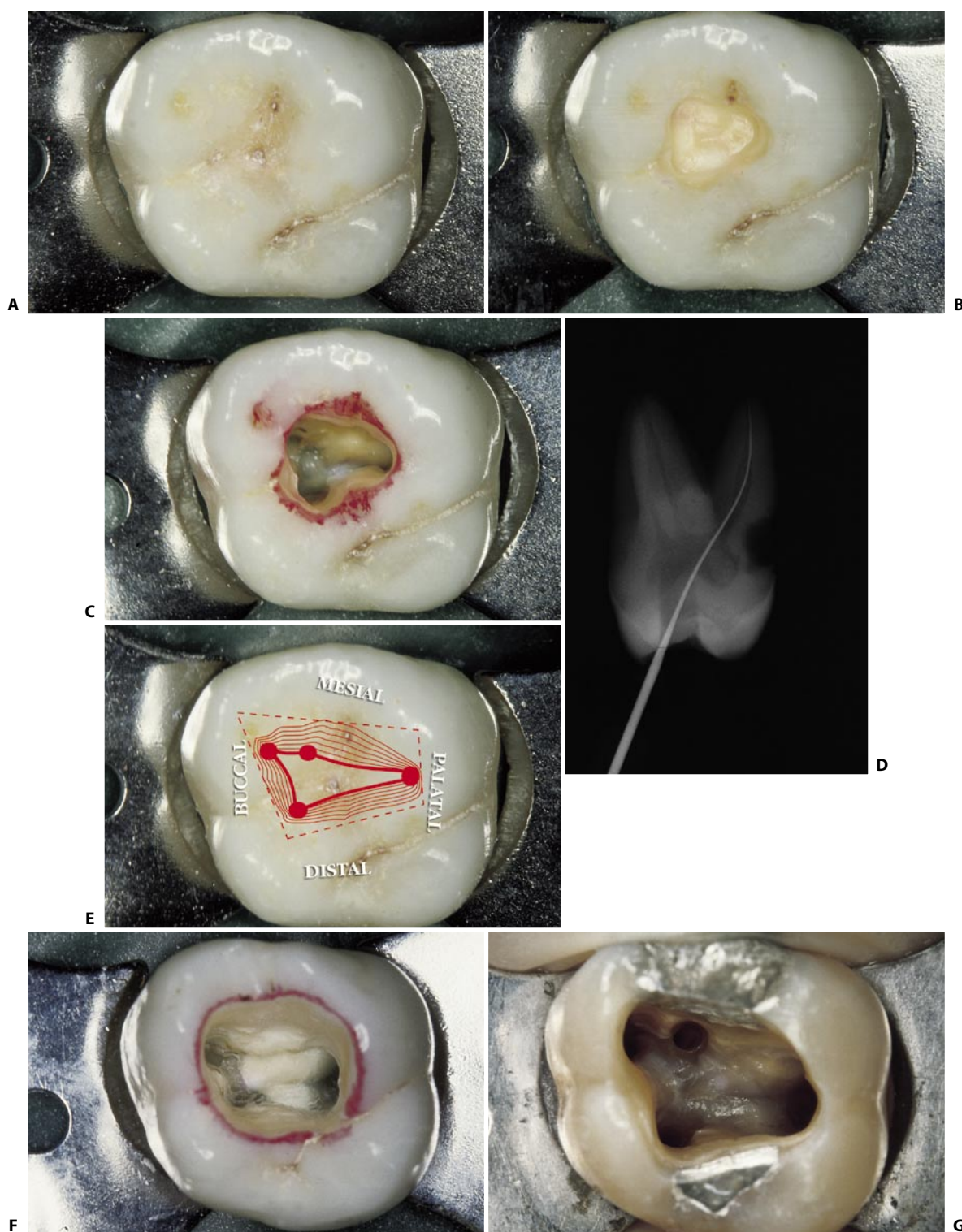


Fig. 11.71. **A.** Occlusal surface of an upper first molar. **B.** A triangular access cavity with a mesially displaced opening is made. **C.** Completed triangular access cavity. **D.** The instrument introduced in the palatal canal through the triangular cavity doesn't have a straight-line access to the apical one third, but meets several interferences of dentin. **E.** The access cavity should be the projection of the pulp chamber floor onto the occlusal surface. **F.** Properly completed access cavity. The definitive form is quadrangular with rounded corners. **G.** Properly created access cavity of a first molar. Note the scalene quadrilateral shape. The canals have already been cleaned and shaped.

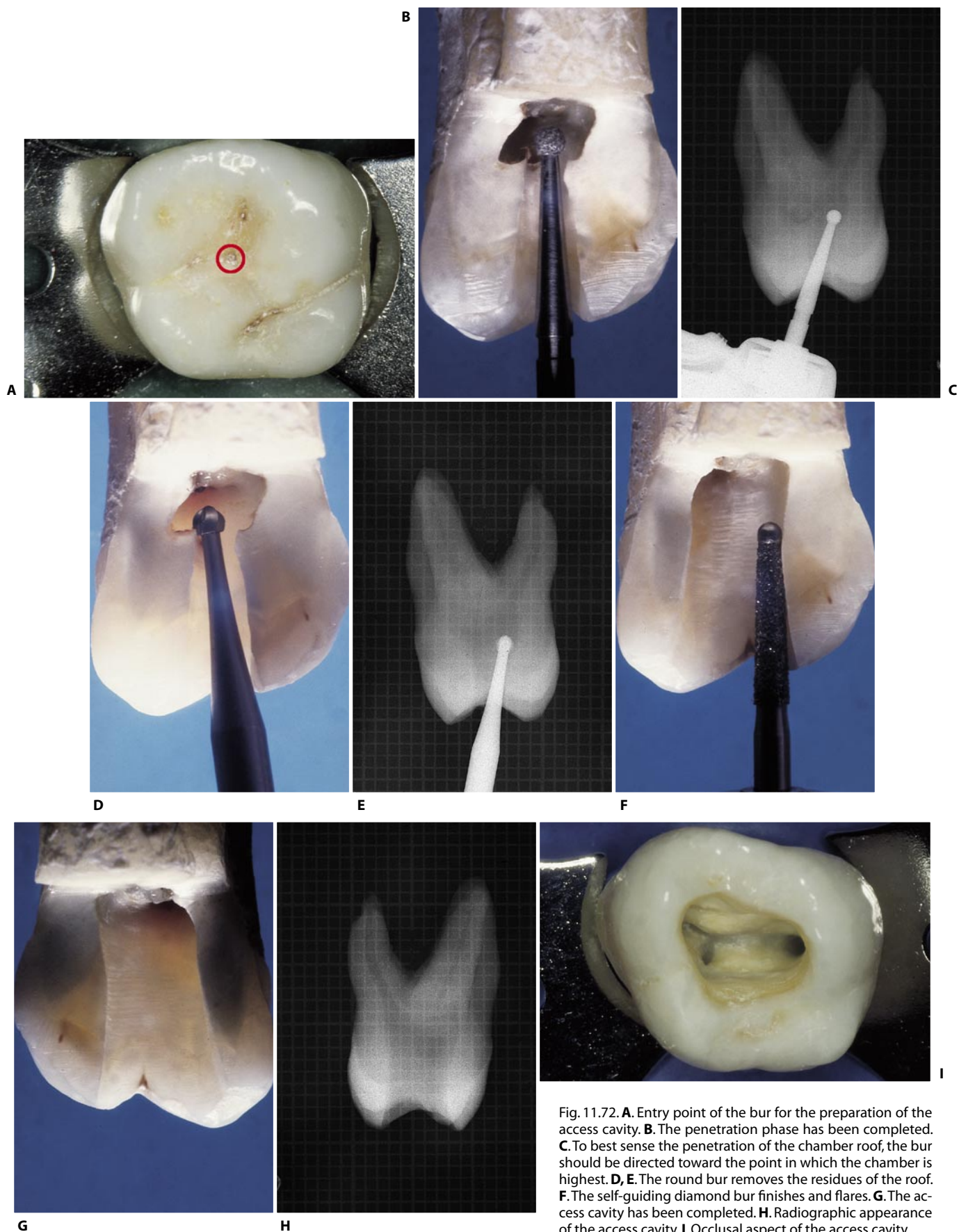


Fig. 11.72. **A.** Entry point of the bur for the preparation of the access cavity. **B.** The penetration phase has been completed. **C.** To best sense the penetration of the chamber roof, the bur should be directed toward the point in which the chamber is highest. **D, E.** The round bur removes the residues of the roof. **F.** The self-guiding diamond bur finishes and flares. **G.** The access cavity has been completed. **H.** Radiographic appearance of the access cavity. **I.** Occlusal aspect of the access cavity.

UPPER SECOND MOLAR

The anatomy of the upper second molar very much resembles that of the upper first molar.

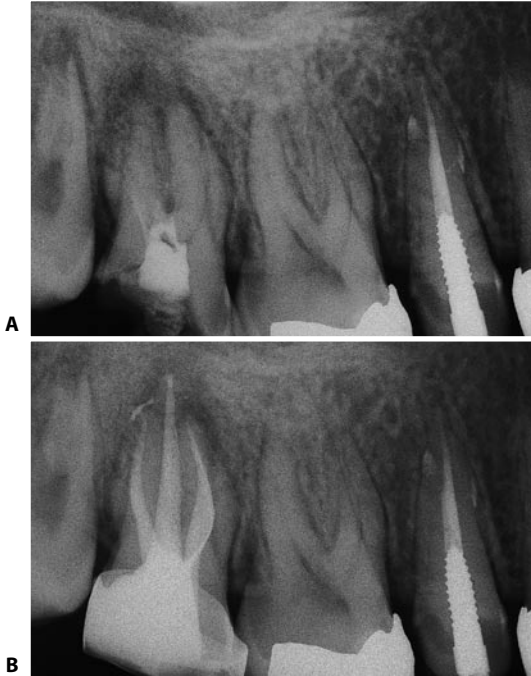


Fig. 11.73. **A.** Preoperative radiograph of an upper right second molar. **B.** Postoperative radiograph. The mesiopalatal canal has the appearance of a radiopaque loop superimposed on the image of the mesiobuccal canal into which it merged.

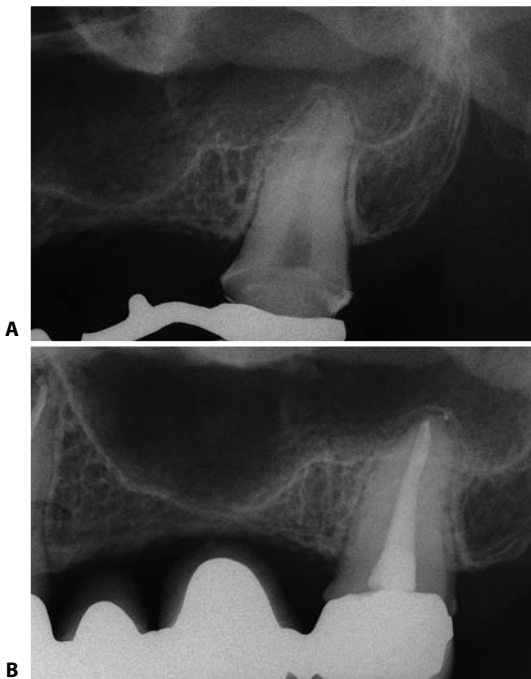


Fig. 11.75. **A.** Preoperative radiograph of an upper left second molar with a single canal in a single root. **B.** One year after endodontic therapy.

In comparison to the latter, it is slightly smaller, flatter mesiodistally, and slightly less frequently has a mesio-palatal canal (Fig. 11.73). Kulid and Peters⁵⁶ found the MB2 in 96,1% in upper first molars and in 93,7% in upper second molars. It sometimes has three fused roots. It may have only two canals, one buccal and one palatal in a single root, or two canals in separate roots (Fig. 11.74); it may have a single, wide canal that extends almost directly from the floor to the apex³⁷ (Fig. 11.75). Rarely, the upper second molar may have a more complicated anatomy, with two palatal canals in a single root (Fig. 11.76) or in two separate roots^{26,30,54} (Fig. 11.77).

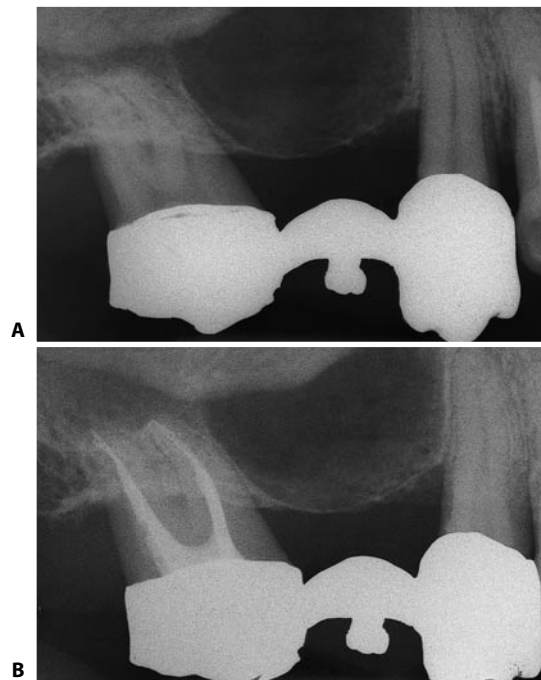


Fig. 11.74. **A.** Preoperative radiograph of an upper right second molar with two roots. **B.** Postoperative radiograph. Two canals in two separate roots are visible.

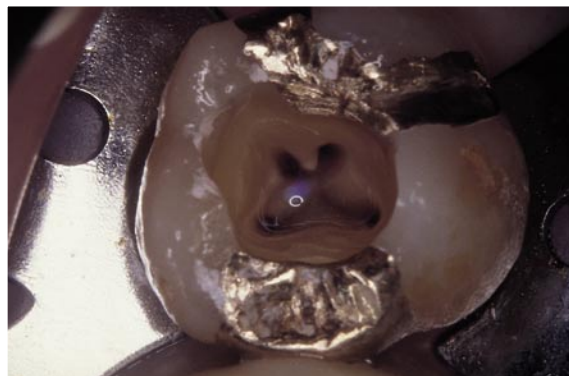

Fig. 11.76. Access cavity of an upper right second molar, with two confluent canals within the palatal root.

The access cavity is created following the same procedure and phases as in the upper first molar.

In comparison with the upper first molar, the pulp chamber floor of the upper second molar is flatter mesiodistally, and the distobuccal canal is found quite palatally displaced. It may even be found halfway between the palatal and the mesiobuccal canals (Fig.

11.78). If one mentally joins the canal openings with linear segments, one obtains a scalene triangle with an obtuse apex corresponding to the distobuccal canal. This triangle may become so flattened as to signify that the three canals practically lie on the same line, oriented buccopalatally.

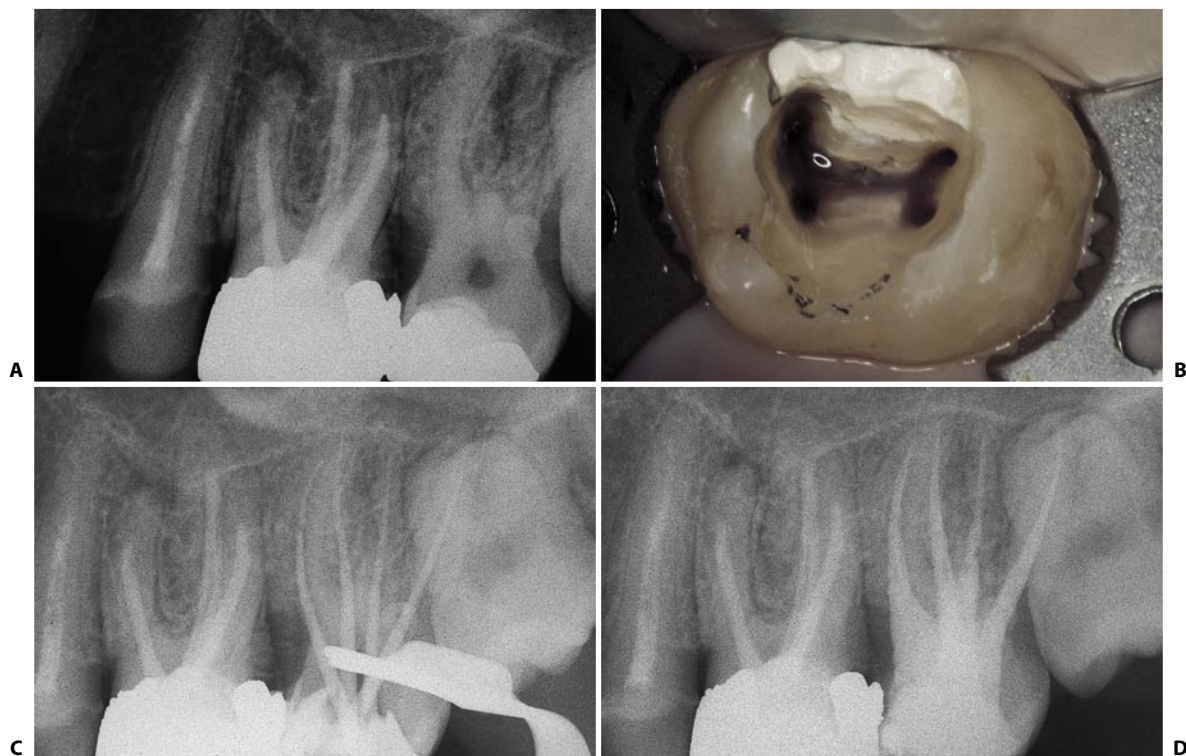


Fig. 11.77. An upper left second molar with two palatal canals in two separate roots. **A.** Preoperative radiograph. **B.** Access cavity. **C.** Intraoperative radiograph. **D.** Postoperative radiograph.

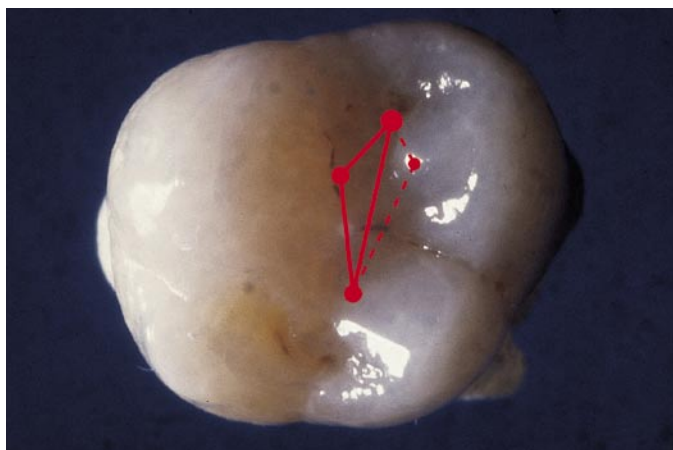

Fig. 11.78. Location of the canal orifices, with respect to the occlusal surface.

UPPER THIRD MOLAR

Loss of the first and second molars is often the reason for considering the third molar a strategic abutment. Because many third molars have well-developed roots, there is no reason they should not remain functional for a long time after endodontic treatment.¹⁸ Before initiating treatment and before promising the patient a successful outcome, a thorough examina-

tion of the root morphology is indicated, however, given that it may be among the most bizarre and unpredictable.

In some cases, the third molar has only one canal. In other cases, it has two, but in most there are three and, sometimes, four (Fig. 11.79).

The access cavity should be made according to the same rules prescribed for the other molars.

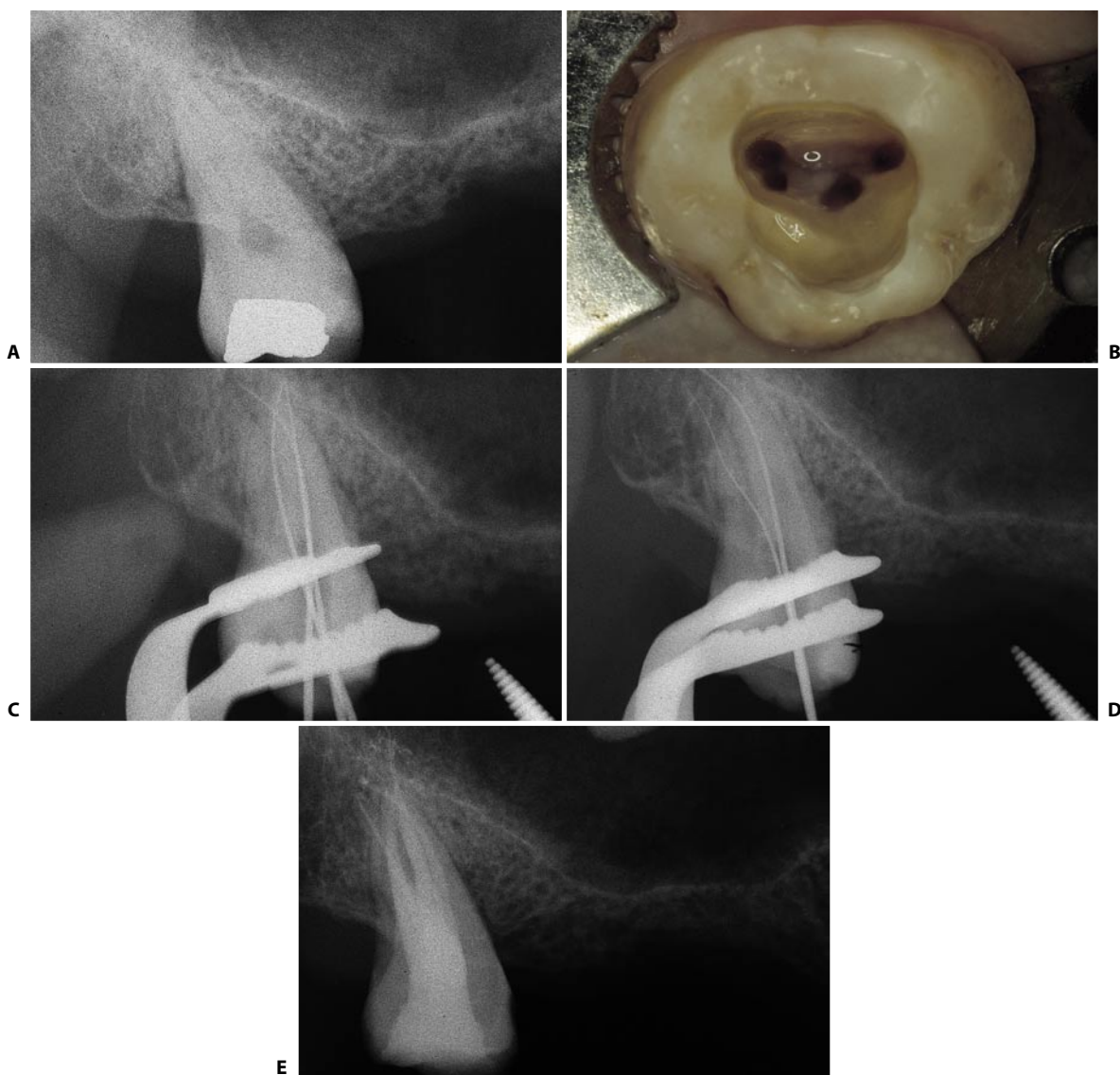


Fig. 11.79. **A.** Preoperative radiograph of the upper right third molar. **B.** The access cavity of the same tooth shows the presence of four canals. **C.** The two palatal canals have independent foramina. **D.** Two instruments have been introduced in the buccal canals. **E.** Postoperative radiograph.

LOWER CENTRAL INCISOR

The lower central, as well as the lower lateral incisor, is anything but easy to treat.⁶⁹ In a graduated scale of difficulty, Weine⁹² places it immediately after the molars and lower premolars with more than one canal.

The difficulties posed by this tooth are related to its mesiodistal thinness (Fig. 11.80 A), when compared to its buccolingual width (Fig. 11.80 B), which makes it very difficult, if not impossible, to widen the canal(s) completely in any direction.

The root, which is sometimes distally or lingually curved, often contains two canals (Fig. 11.81). Benjamin and Dawson¹¹ report that the lower central incisor has two canals in 41.4% of cases, with independent foramina in only 1.3% of cases. Weine⁹² states that a single, ribbon shape canal is found in 60%, two canals running into a single foramen in 35%, and two completely

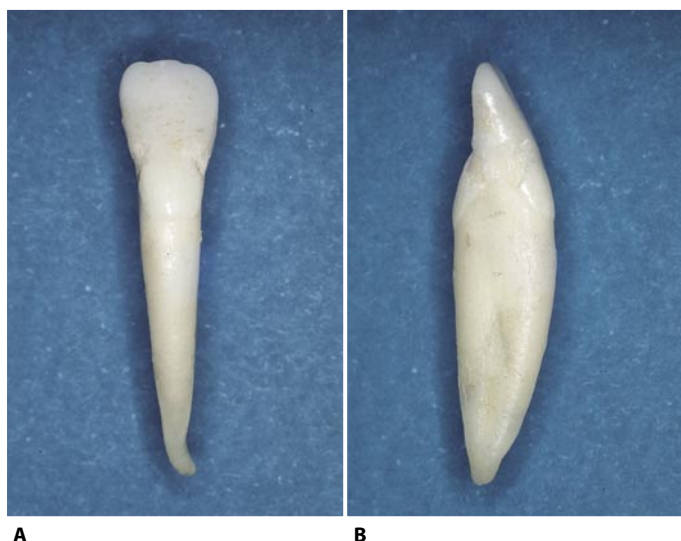


Fig. 11.80. **A.** A lower central incisor. Note the mesiodistal thinness of the root. **B.** The root of the same tooth is significantly wider buccolingually. Note also the concavity at the level of the middle one third.

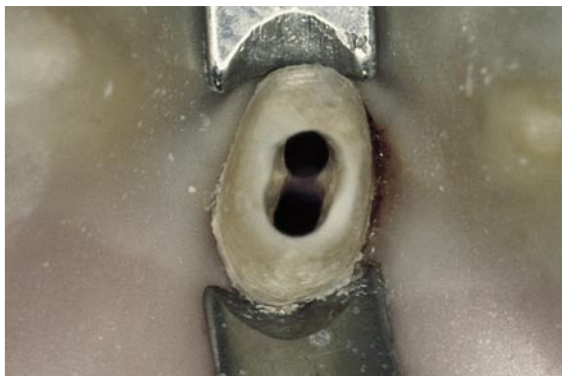

Fig. 11.81. Lower central incisor, with two canals.

independent canals in 5%. One may conclude that the lower central incisor should always be considered to have two canals, since even when there is only a single canal it has such an elongated buccolingual shape that for the purposes of the access cavity and preparation it must be treated as though it were two canals.

Because of the mesiodistal thinness of the root, one must pay particular attention to preparing the access cavity to avoid lateral perforations. Halfway along the root, there is a concavity on both sides; thus, excessive widening may cause stripping of the root.

The access cavity is initiated with a rather small, round diamond bur, and its final shape will be either ovoid or elliptical (Fig. 11.82).

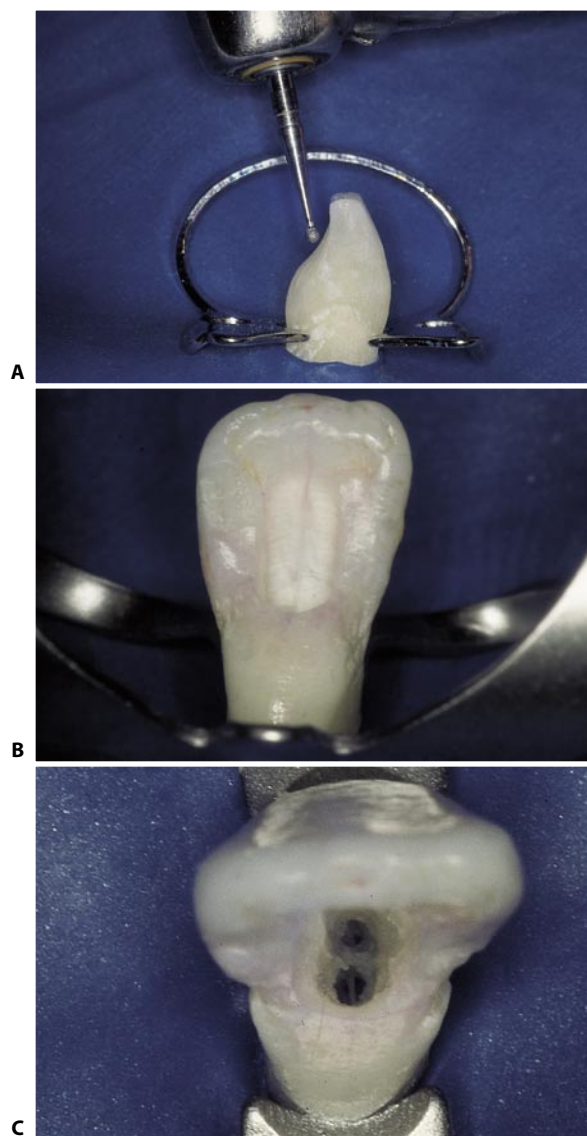


Fig. 11.82. **A.** The access cavity is initiated with a small, round diamond bur. **B.** The final shape of the access cavity is ovoid or elliptical. **C.** Only an adequate access cavity can demonstrate the presence of two canals.

One must be careful to completely remove the triangle # 2 to ensure a straight-line access to the lingual canal.⁶ An access cavity that is too limited may allow access to the buccal canal, but would preclude adequate probing and shaping of the lingual canal (Fig. 11.83). A proper access cavity must therefore extend almost from the incisal margin to the cingulum.⁶⁰ In abraded or fractured teeth, the cavity also or even solely involves the incisal margin⁶⁶ (Fig. 11.84).

Fortunately, the two canals have separate foramina only in a small percentage of cases (Fig. 11.85). This explains why overlooking one canal does not lead to failure, as it might seem.

Careful radiographic examination with a mesial or distal view can demonstrate the presence of the two canals (Fig. 11.86). Some authors suggest identifying the two orifices immediately, but in this author's opinion it is easier to identify the second canal after the first has been prepared, which enhances the tactile sensation from the entrance of the thin instrument into a second thin canal, which has yet to be prepared.

Precise manual instrumentation followed by numerous irrigations will prevent inadvertent blocking of the other canal, which has not yet been prepared.

It has been shown¹¹ that the confluence of the two canals toward a single foramen frequently occurs in the




Fig. 11.83. **A.** Radiographic appearance of the lower central incisor in a mesiodistal projection. **B.** A limited access cavity has been created. **C.** A # 08 file enters the buccal canal, though with considerable coronal interference. The presence of "triangle # 2" impedes the entrance of any instrument into the lingual canal. **D.** The low-speed round bur completely excises the dentinal triangle. **E.** Radiographic appearance of the completed access cavity. **F.** The # 08 file can now enter the lingual canal easily. **G.** The two instruments confirm the presence of two canals with a common apex.

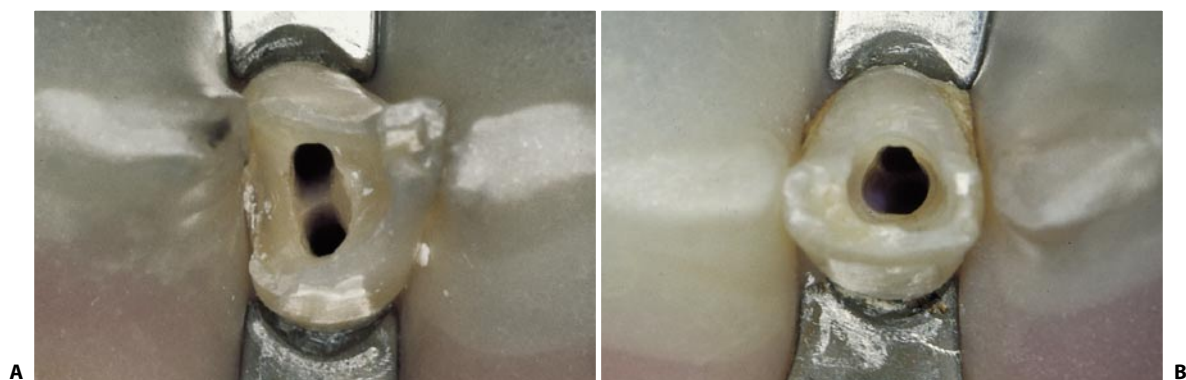

Fig. 11.84. **A, B.** Examples of access cavities in fractured and abraded lower central incisors. The access cavities also involve the incisal margin. In both cases, two canals were present.

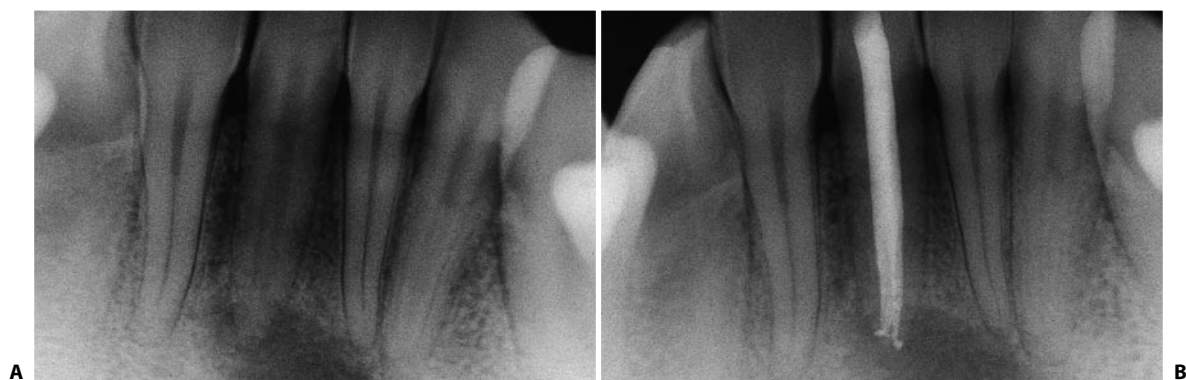

Fig. 11.85. A lower right central incisor, with two canals with independent apices. **A.** Preoperative radiograph. **B.** Postoperative radiograph.

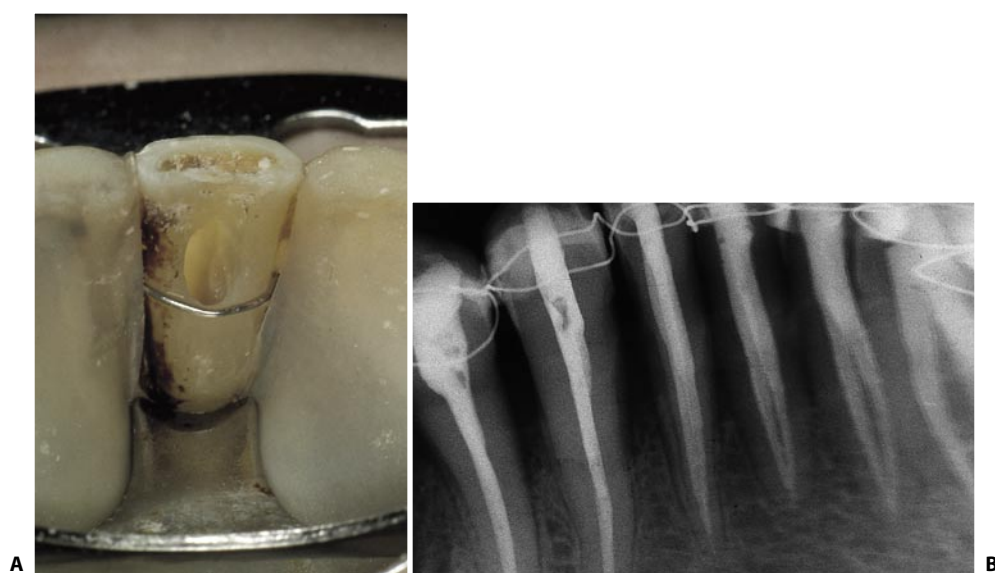


Fig. 11.86. The four lower incisors of this patient all have two canals. **A.** Elliptical access cavity. **B.** Postoperative radiograph. The presence of two canals is easily documented in the left incisors, which have been radiographed in a mesiodistal view.

last millimeter of the root canal. In such cases, obturating the root canal one millimeter short from the radiographic apex means that the common foramen is not

obturated. In such a case, neglecting the lingual canal thus necessarily leads to failure.²⁴ The finding of lateral canals is quite frequent (Fig. 11.87).

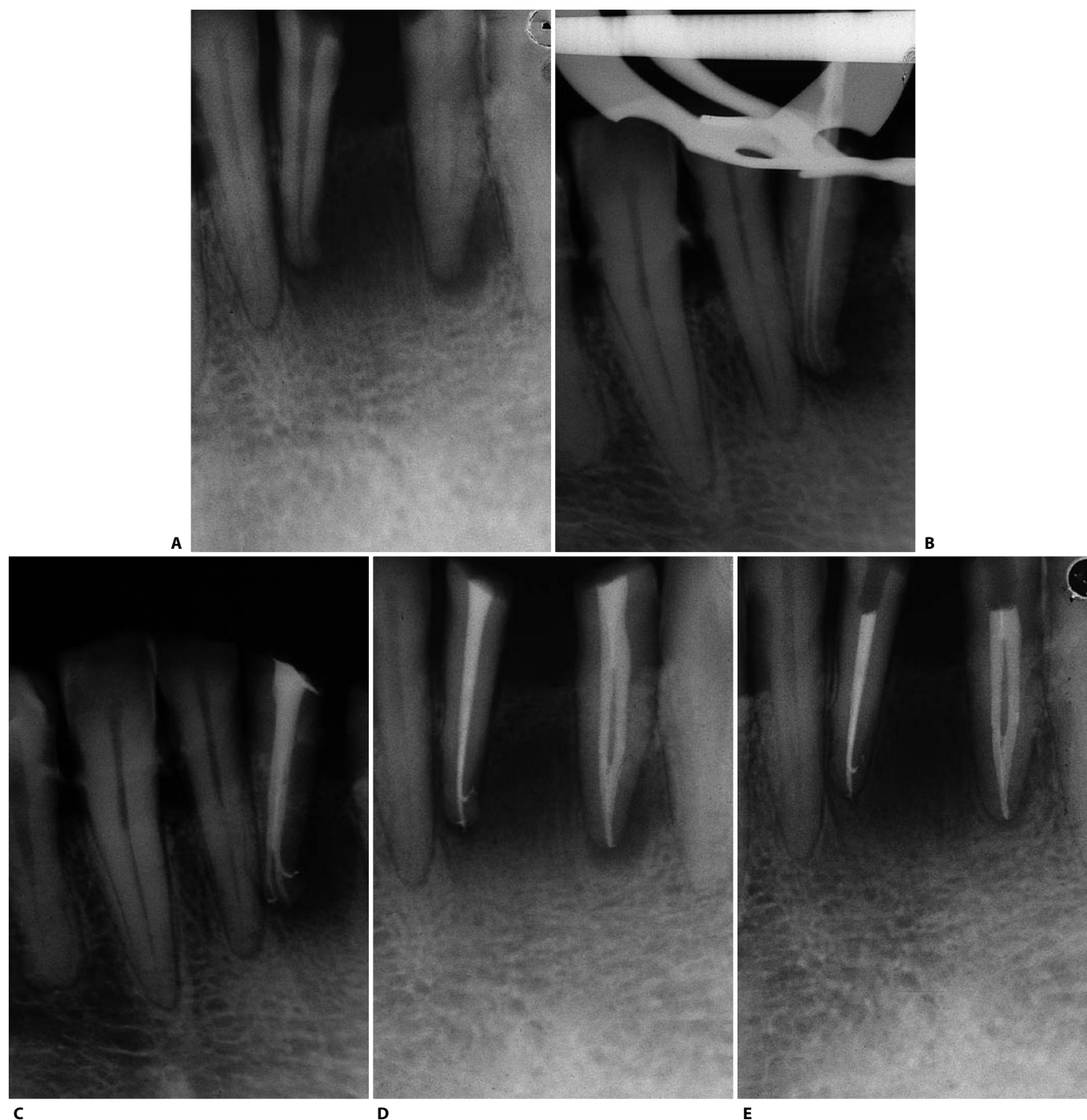


Fig. 11.87. The two anatomical variants of the lower incisor with two canals are present in the same patient. The right central incisor has two canals with independent foramina, while the left lateral incisor has two canals with a common apical foramen. **A.** Preoperative radiograph. **B.** Intraoperative radiograph confirms the presence of two independent canals. **C.** Postoperative radiograph. A lateral canal is also visible. **D.** Postoperative radiograph of the left lateral incisor: the two canals become confluent. **E.** Two year recall (Courtesy of Dr. R. Becciani).

LOWER LATERAL INCISOR

This tooth is identical to the central incisor, the only difference being that it is often slightly longer (Fig. 11.88 A, B).

It also can have two canals within the root with a cer-

tain symmetry. If the patient has two canals in the right lateral incisor, one can also expect two canals in the left; if a single canal is present in the right lateral incisor, one may also expect a single canal in the left (Fig. 11.88 C, D).

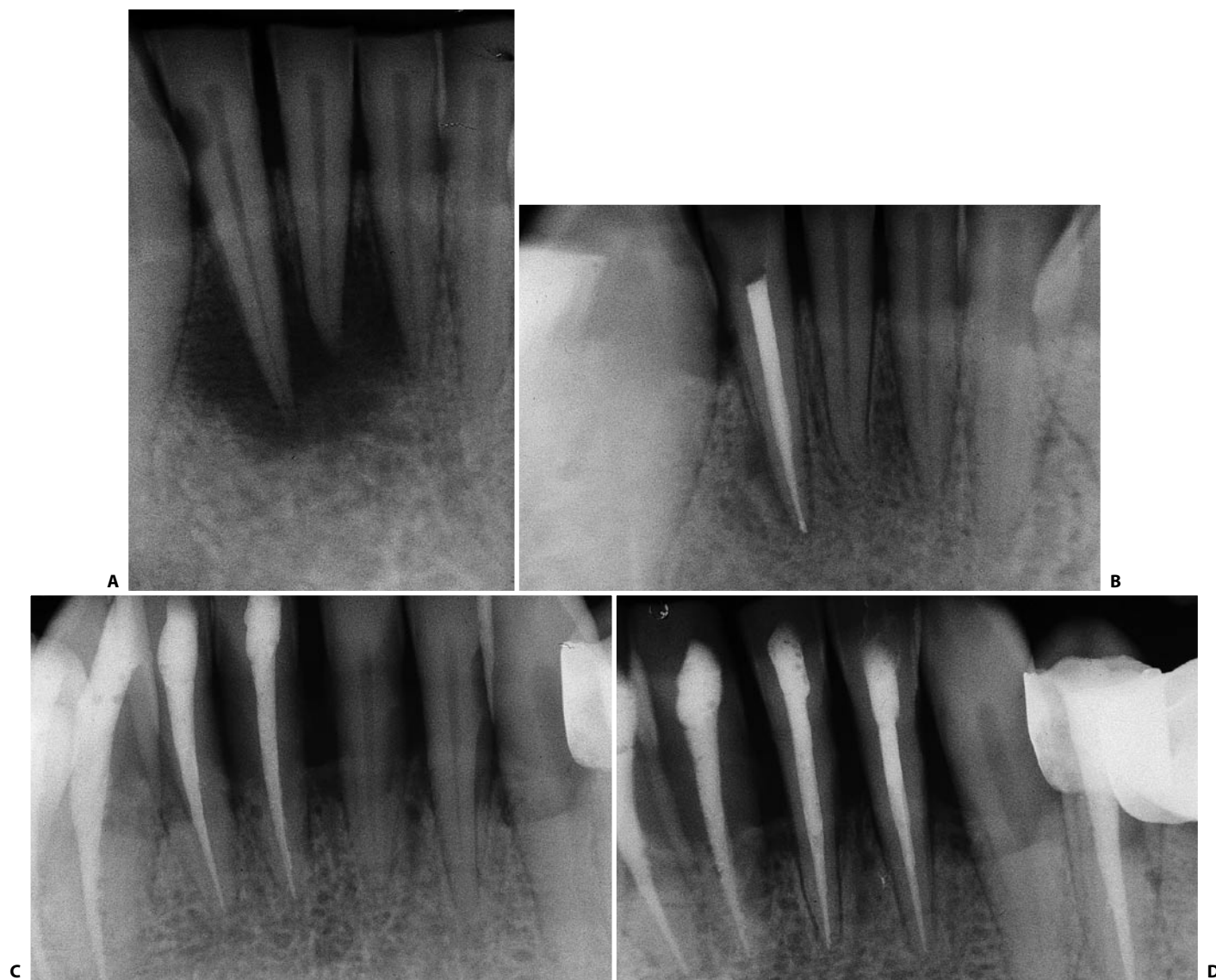


Fig. 11.88. **A.** Preoperative radiograph. The lateral incisor is several millimeters longer than the central incisor. **B.** Recall radiograph 3 years later. **C.** The right lateral incisor reveals a single canal. **D.** The left lateral incisor of the same patient also reveals a single canal.

LOWER CANINE

This tooth usually has one root containing a single canal (87%) (Fig. 11.89 A). In 10%, there are two canals that join at the apex (Fig. 11.89 B), and less commonly (3%) there are two completely independent canals.⁴⁴ Rarely, the tooth may have two roots (Fig. 11.90). Its length may vary, but very often the use of 30 mm instruments is necessary.

The access cavity is ovoid and must be extended buccolingually enough to also allow straight-line access to

the lingual canal or, in any case, the lingual wall of the root canal, which is quite elongated buccolingually.²⁸ In abraded teeth, the access cavity also (Fig. 11.91) or exclusively (Fig. 11.92) involves the occlusal surface. If there is a very extensive cervical abrasion, the access cavity can be made entirely from the buccal side (Fig. 11.93).

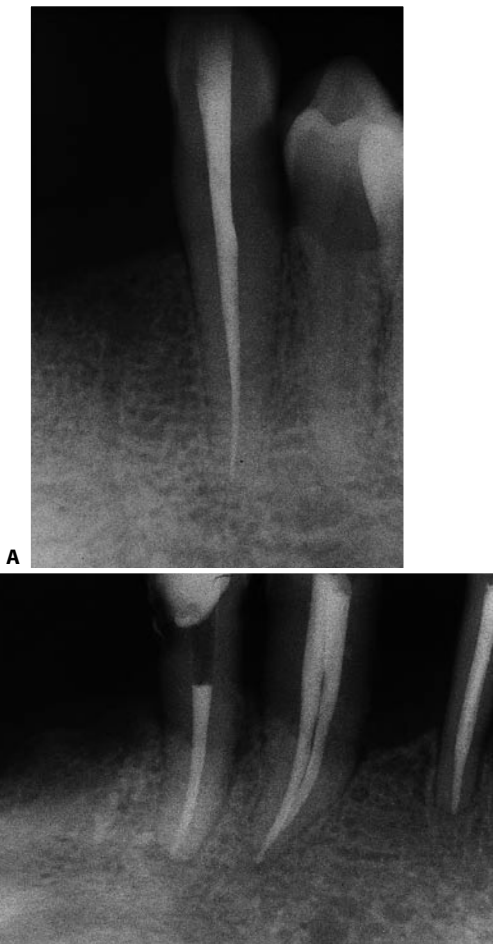


Fig. 11.89. **A.** Postoperative radiograph of a lower canine with a single canal. **B.** Postoperative radiograph of a lower canine with two canals joining at a common apex.

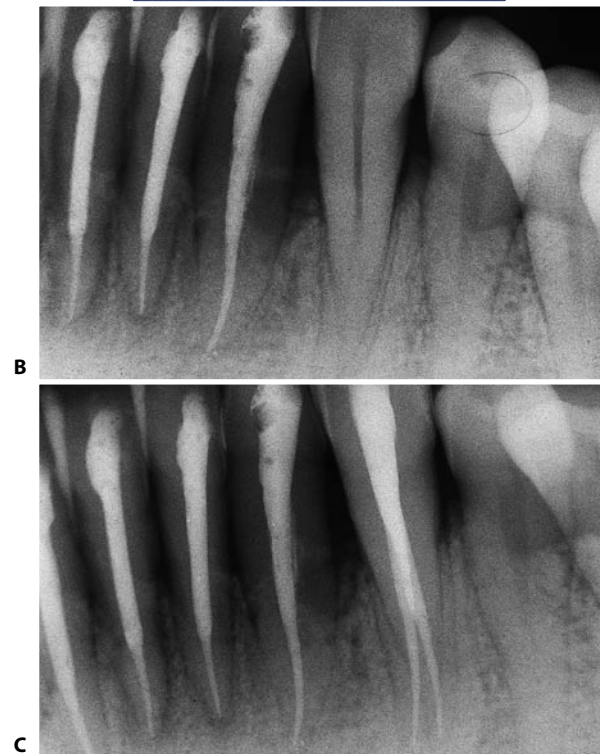
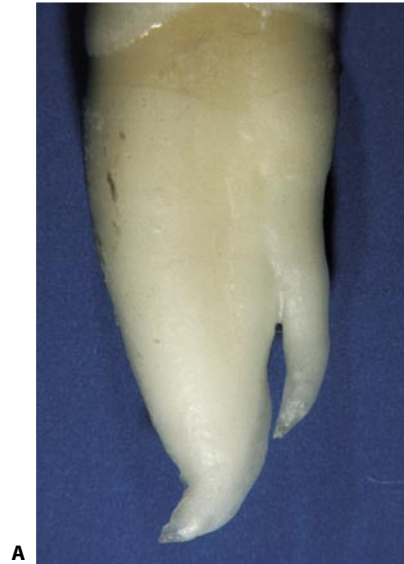

Fig. 11.90. A lower canine with two canals in two separate roots. **A, B.** Pre- and postoperative radiographs of a lower canine with two separate roots.



Fig. 11.91. Example of access cavity in a slightly abraded lower canine. **A.** The cavity necessarily also involves part of the incisal surface. **B.** The cavity must be extended occlusally, until the instrument has unhindered access.

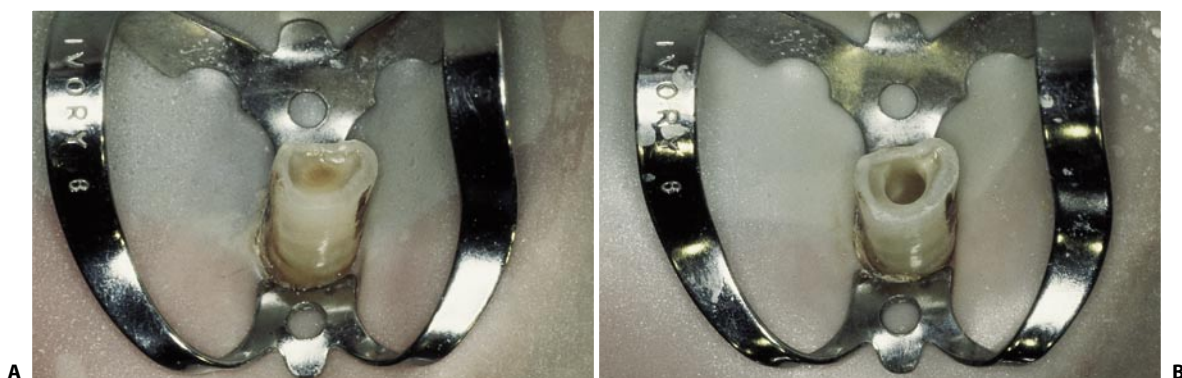

Fig. 11.92. Example of access cavity in a very abraded lower canine. **A.** The pulp chamber is exactly at the center of the abraded surface; therefore, it is there that one must open the tooth. **B.** The access cavity has been entirely created on the incisal surface.

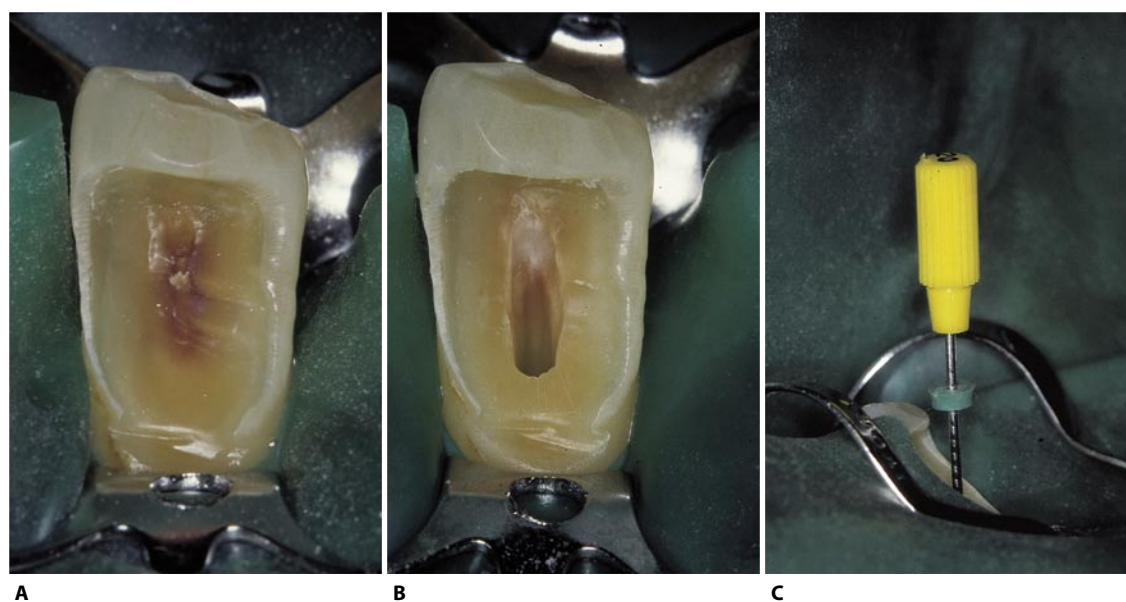


Fig. 11.93. Example of access cavity in a lower canine with a large cervical abrasion. **A.** The pulp chamber is completely below the thin layer of dentin at the center of the abrasion. **B.** The access cavity has been made entirely on the buccal side of the dental crown. **C.** Note the straight-line access of the instrument, which enters without any coronal interference.

LOWER FIRST PREMOLAR

Given its great anatomical variability, this tooth may be very challenging.

According to a study by Vertucci,⁸⁷ a single canal is found in 70% of cases, two canals joining at a common foramen in 4% (Fig. 11.94), two independent canals in 1.5% (Fig. 11.95), one canal that bifurcates at the apex into two branches in 24% (Fig. 11.96), and two separate canals in two independent roots in 0.5% (Fig. 11.97). The mandibular first premolar can be found with three root canals⁵⁰ and with a “C shaped” canal.⁵ The difficulty of performing proper treatment obviously depends on the anatomical situation, the most complex being that of the single canal that bifurcates in the apical one third of the root.

The dental crown of the lower first premolar is quite unusual, so much so that it is considered a transitional form between the canine and the second premolar (Fig. 11.98 A).

The two cusps of the tooth are quite asymmetric, the buccal one being more pronounced while the lingual cusp is just evident. It could almost be considered a canine with a large cingulum.

The pulp chamber, which is ovoid and directed buccolingually, lies almost entirely below the buccal cusp (Fig. 11.98 B); thus, 90% of the access ca-

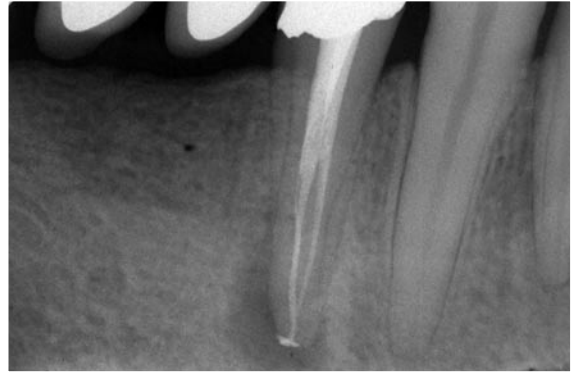


Fig. 11.94. Postoperative radiograph of a lower first premolar with two canals joining at a common foramen.

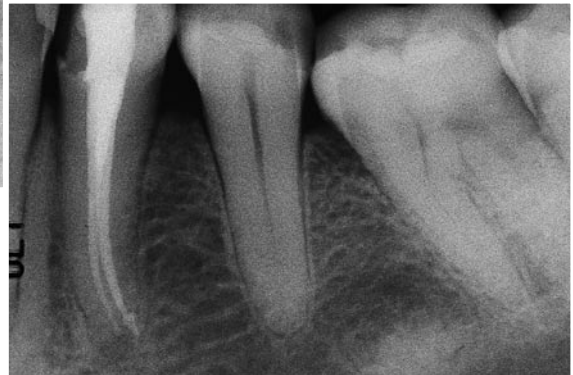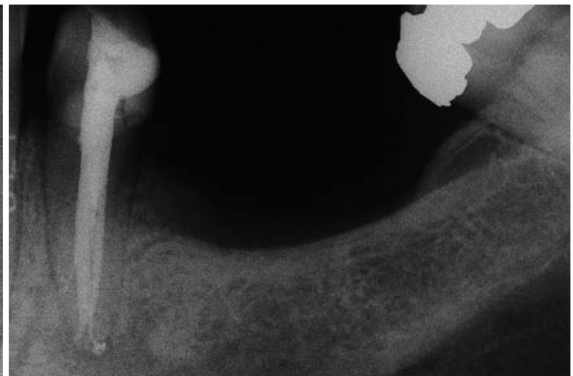

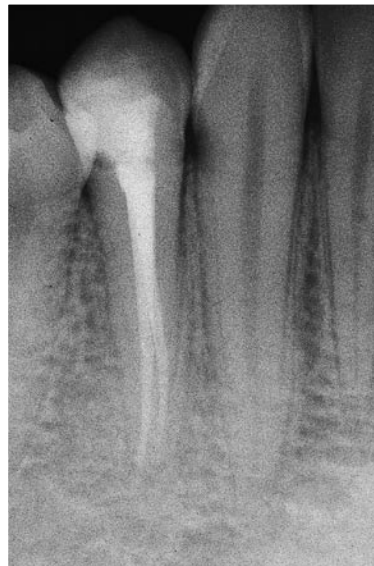
Fig. 11.95. **A–C.** Lower first premolars with two canals with independent foramina.

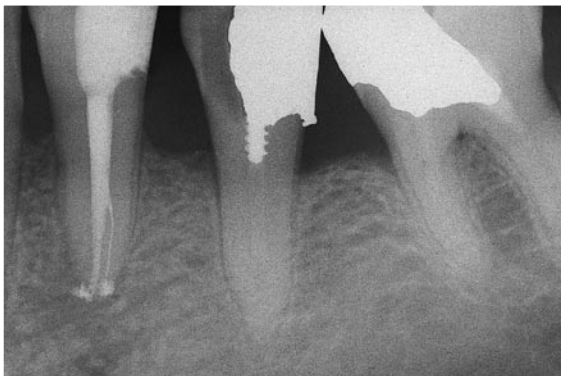

Fig. 11.96. A lower first premolar with a bifurcation in the apical one third.

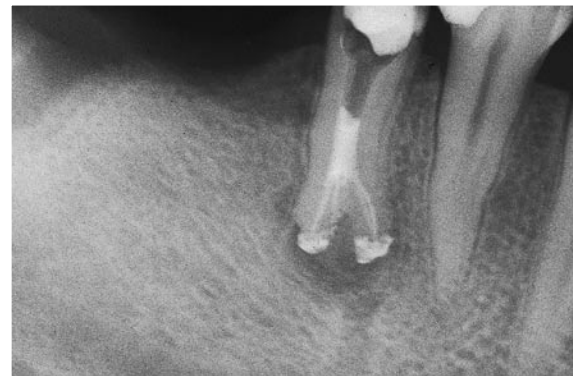


Fig. 11.97. A lower first premolar whose root bifurcates into two independent roots at the level of the apical one third.

vity, which is elliptical, must be created at the expense of the buccal cusp.

The entry point of the bur is in the middle of the central groove, the inclination directed toward the side of the buccal cusp (Fig. 11.98 C), which is eliminated al-

most at the peak (Figs. 11.98 D-L).

In contrast, the side of the lingual cusp is almost completely preserved. It would be incorrect to orient the bur parallel to the long axis of the tooth, because this could easily lead to a lingual perforation.

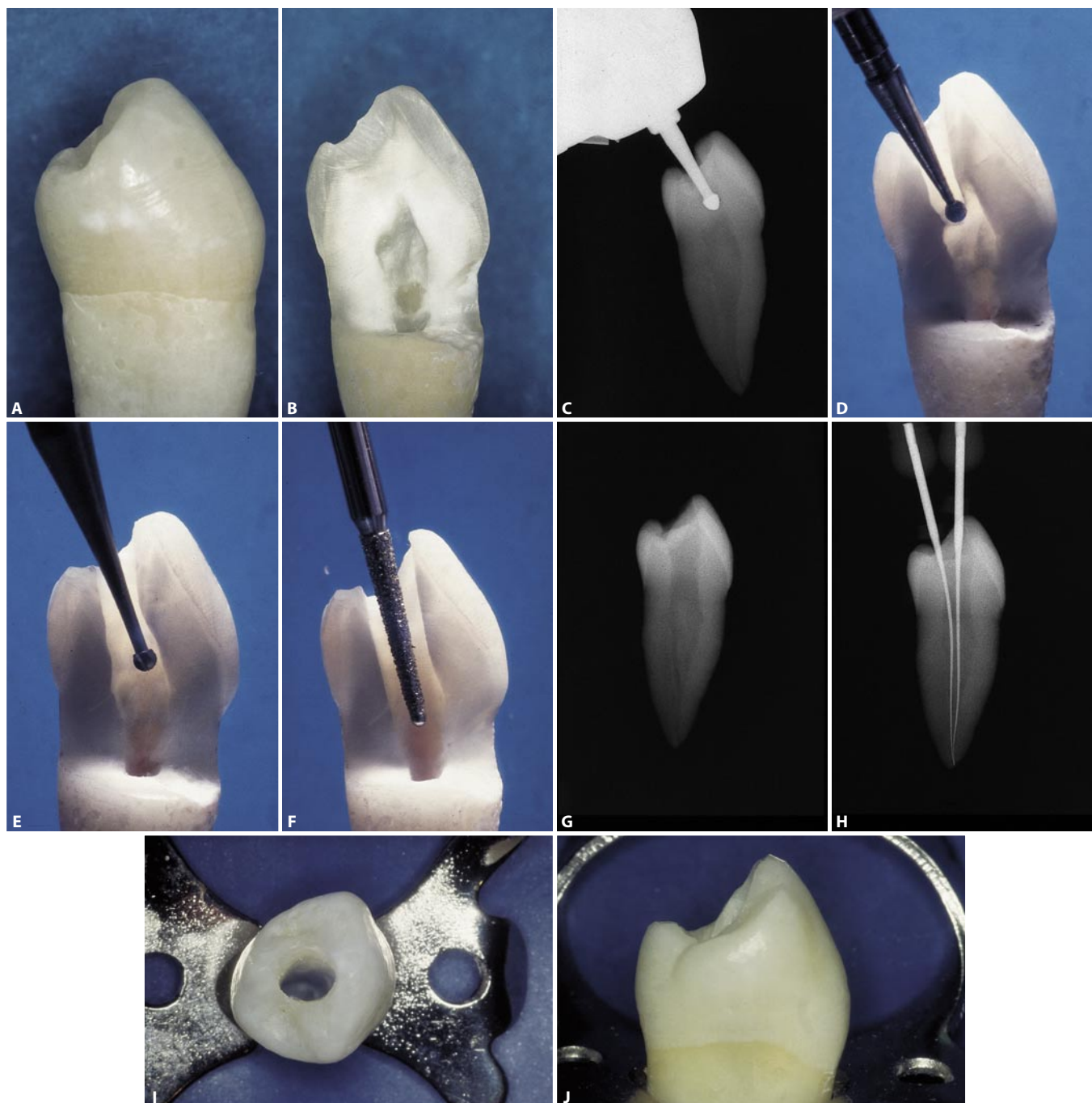


Fig. 11.98. **A.** The crown of a lower first premolar can be compared to that of a canine, given its highly developed cingulum. **B.** The pulp chamber lies almost entirely below the buccal cusp. **C.** In preparing the access cavity, the bur must be oriented buccally. **D.** The round diamond bur has accomplished the penetration phase. **E.** The round bur removes the residue of the chamber roof. **F.** The non-cutting diamond bur finishes and flares the cavity. **G.** Radiographic appearance of the completed access cavity. **H.** A correctly performed cavity allows the introduction of instruments in all the canals that may be present. **I.** Occlusal view of the access cavity. **J.** The cavity has been created almost entirely at the expense of the buccal cusp.

LOWER SECOND PREMOLAR

This tooth has fewer variants as compared to the first premolar. The lingual cusp is better developed, and the tooth is more symmetrical (Fig. 11.99).

Vertucci⁸⁷ has found that the lower second premolar has a single root with a single ovoid or round canal in 97.5% (Fig. 11.100 A) and a canal that bifurcates at the apex in 2.5% (Fig. 11.100 B). Other times the canal can trifurcate (Fig. 11.101).

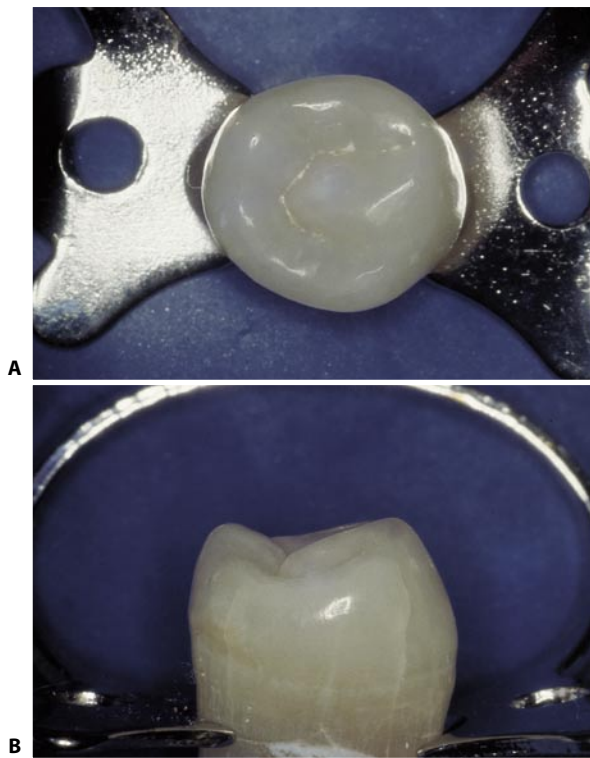


Fig. 11.99. **A.** Occlusal surface of the lower left second premolar. **B.** Note the greater symmetry as compared to the first premolar.

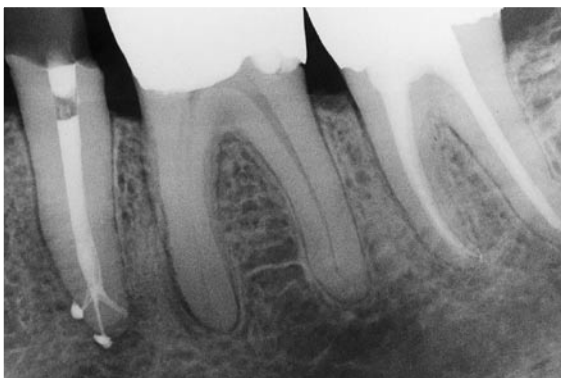


Fig. 11.101. Postoperative radiograph of a lower second premolar, with a trifurcated canal in the apical one third (Courtesy of Dr. C.J. Ruddle).

Other authors, including Green,⁴⁴ have found that one may encounter other situations, although rarely. One may find two canals joining at a single foramen (4%) or two completely separate canals (4%) (Fig. 11.102),

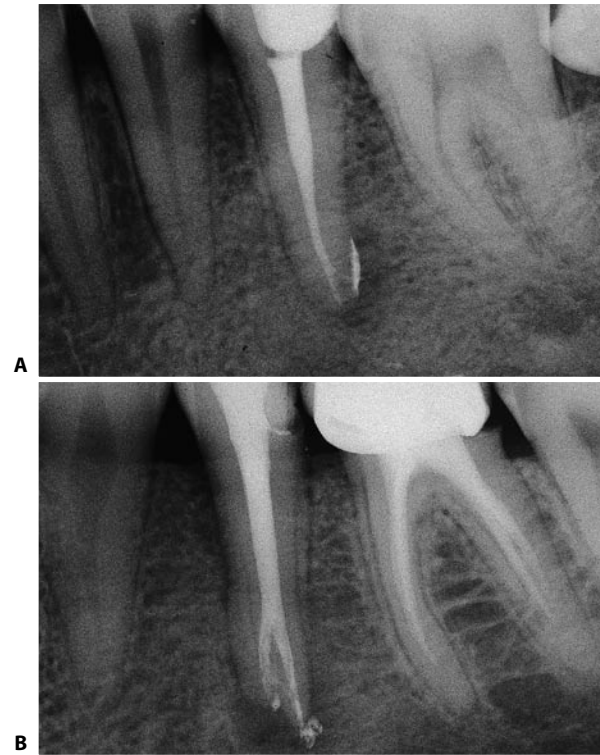


Fig. 11.100. **A.** Postoperative radiograph of a lower second premolar with a single canal. **B.** Postoperative radiograph of a lower second premolar with a canal that bifurcates near the apex.

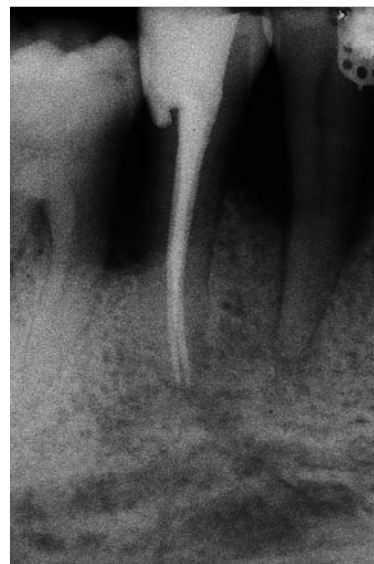

Fig. 11.102. Postoperative radiograph of the second lower premolar, with two independent canals.

or two canals in separate roots.⁴³ Even cases with three canals have been described (Fig. 11.103).^{32,101} The access cavity is ovoid and oriented buccolingually (Fig. 11.104).

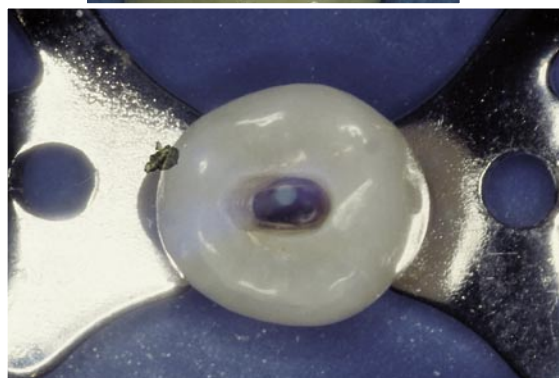
Lateral canals are very frequent in this tooth (Fig. 11.105). In a study by Fabio,³³ they were found to be histologically demonstrable in 66% of the teeth studied. This is the highest percentage reported in the literature.

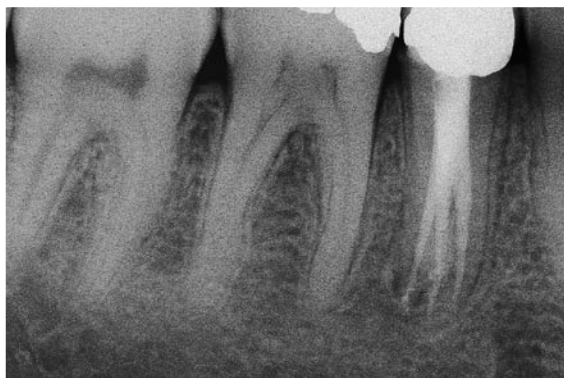
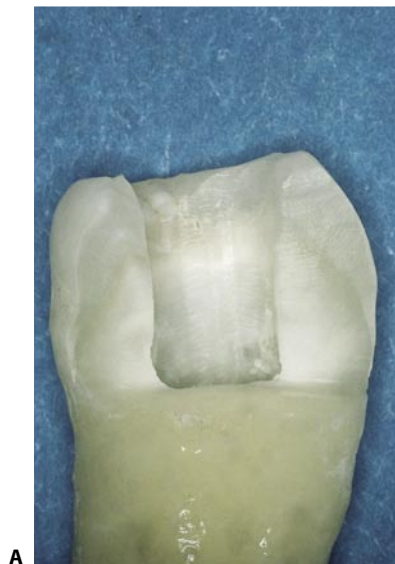
Fig. 11.103. The radiograph shows a lower right second premolar with three canals.

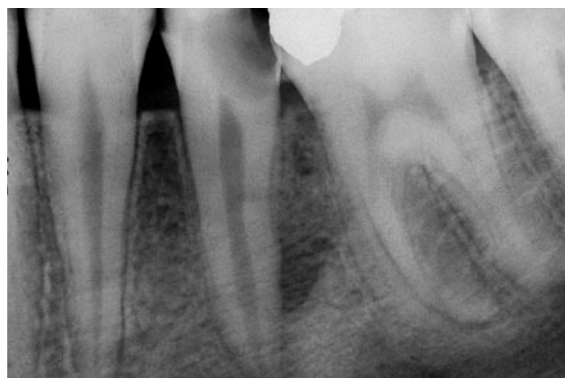

A

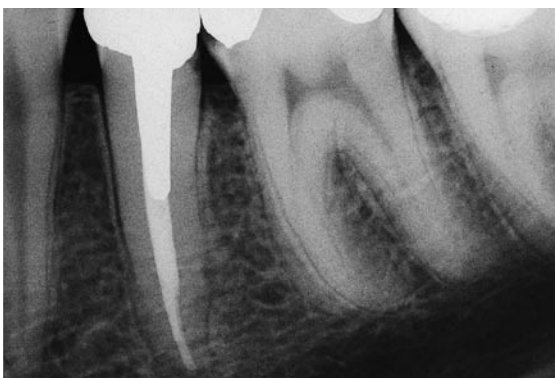

B

Fig. 11.104. **A.** Completed access cavity. Note that the cusps are not necessarily involved. **B.** Occlusal view of the access cavity.



A



B

Fig. 11.105. **A.** Preoperative radiograph of a lower left second premolar with a lesion of endodontic origin on the distal aspect of the middle one third of the root. **B.** Recall radiograph two years later. The lesion, which was adjacent to a lateral canal that is noted to be filled, has healed completely.

LOWER FIRST MOLAR

Together with the upper first molar, this tooth most frequently requires endodontic treatment.

The tooth generally has two separate roots with a round, or more frequently elliptical, canal in the distal root (Fig. 11.106) and two canals in the mesial root. In 90%, they remain separate as far as the foramen⁶¹ (Fig. 11.107); in the remaining 10%, they join together

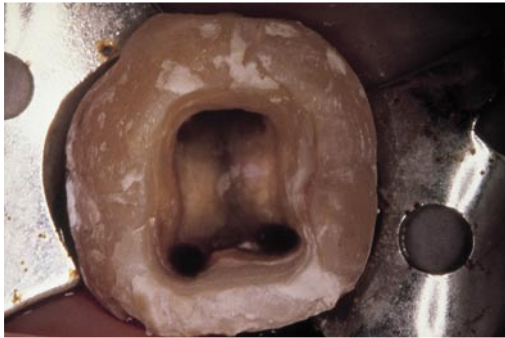

Fig. 11.106. Access cavity of a lower left first molar. The mesial canals have a roundish orifice, while the distal canal is usually elliptical.

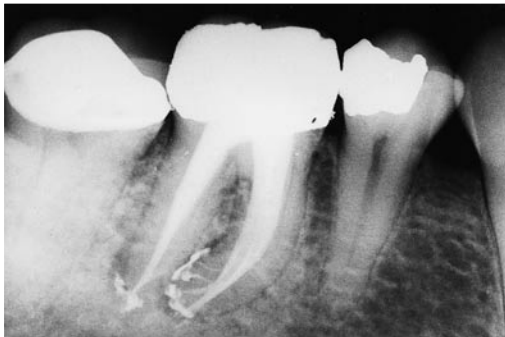

Fig. 11.107. The mesial canals of this lower molar have independent foramina. Note the numerous lateral canals in the apical one third (Courtesy of Dr. M. Scianamblo).

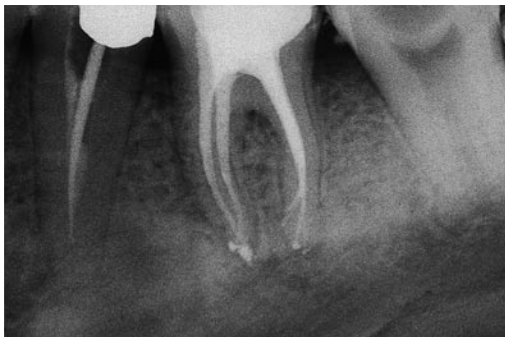

Fig. 11.108. The mesial canals of this lower molar are joining in a common foramen. Note the numerous lateral canals in the distal root.

at a common foramen⁹² (Fig. 11.108).

Numerous variants have been described:²³

- In 35% of cases, four canals are present.^{47,81} The distal root contains two canals, one in the buccal and the other in the lingual position (Fig. 11.109).

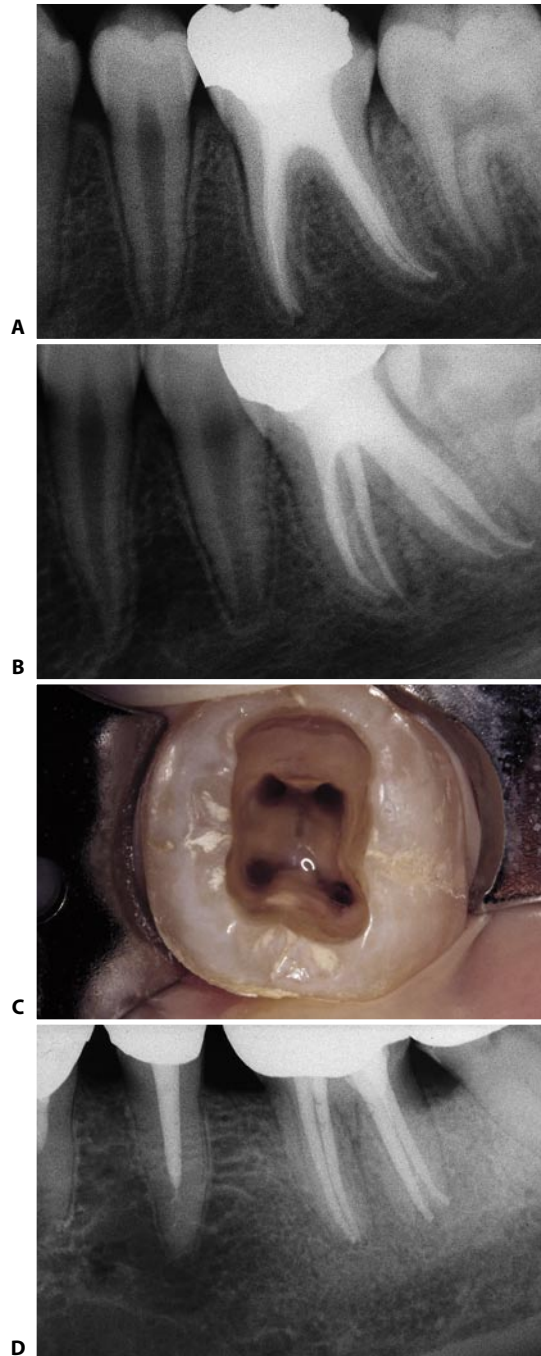


Fig. 11.109. **A.** Postoperative radiograph of the lower first molar. **B.** This mesiodistal view of the same tooth demonstrates, in addition to the two canals of the distal root, the mesial canals which, although they communicate with each other at the level of the middle one third, have independent apical foramina. **C.** Access cavity of a lower left first molar with two canals in the distal root and two canals in the mesial root. **D.** In this other lower molar the four canals in the two roots are visible, each with an independent apical foramen.

- The second distal canal is sometimes found in a separate root in the distolingual position. It is slightly smaller and mesial to the distobuccal root⁸⁸ (Fig. 11.110).
- Sometimes, the “extra” canal is found in the mesial root, which therefore contains three canals (Figs. 11.111-11.113). This is the middle mesial ca-

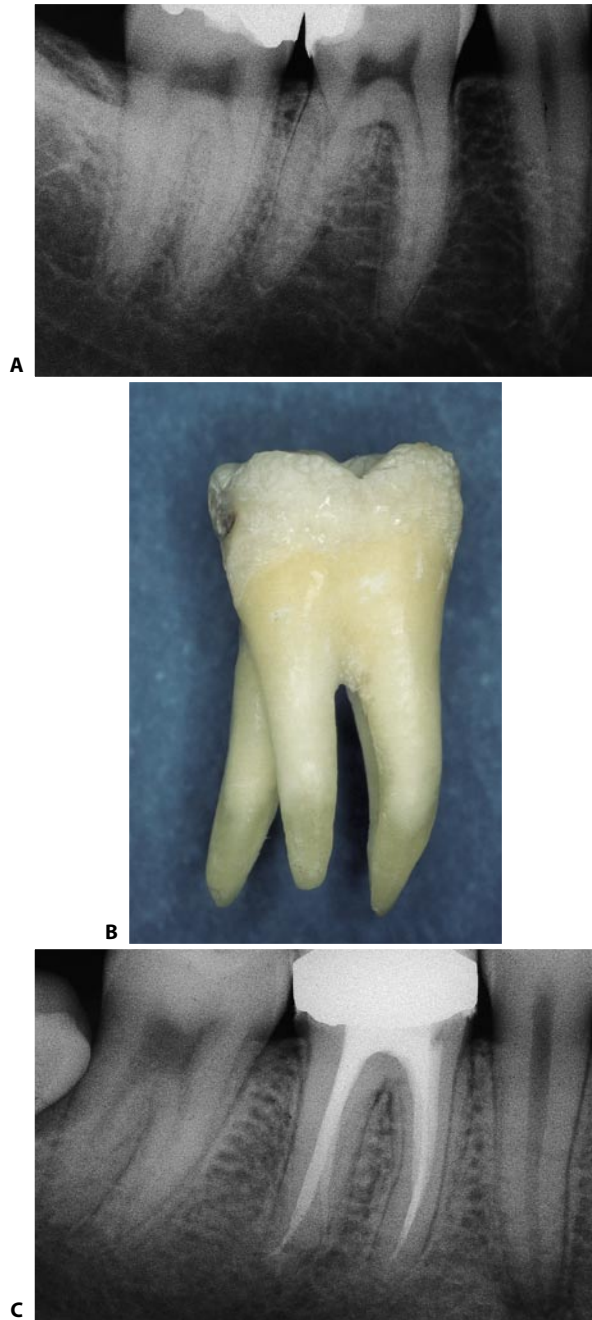

Fig. 11.110. **A.** The slight radiopacity within the bifurcation of this lower right first molar is due to the distolingual root. The lamina dura surrounding this root and the canal contained within are easily recognizable. **B.** First lower molar extracted: the tooth has the distolingual root. **C.** Postoperative radiograph of a lower right first molar with two distal roots and two distal canals.

nal.^{9,14,35,36,50,55,71,93}

In addition, cases with three canals in the distal root and two in the mesial root have been described.^{29,34,64,72,84} Cases with two canals in the mesial root and three canals in three distal roots have also been described.⁴¹

The most salient fact that emerges from an examination of these anatomical variants is that the lower first molar frequently has two canals in the distal root. If

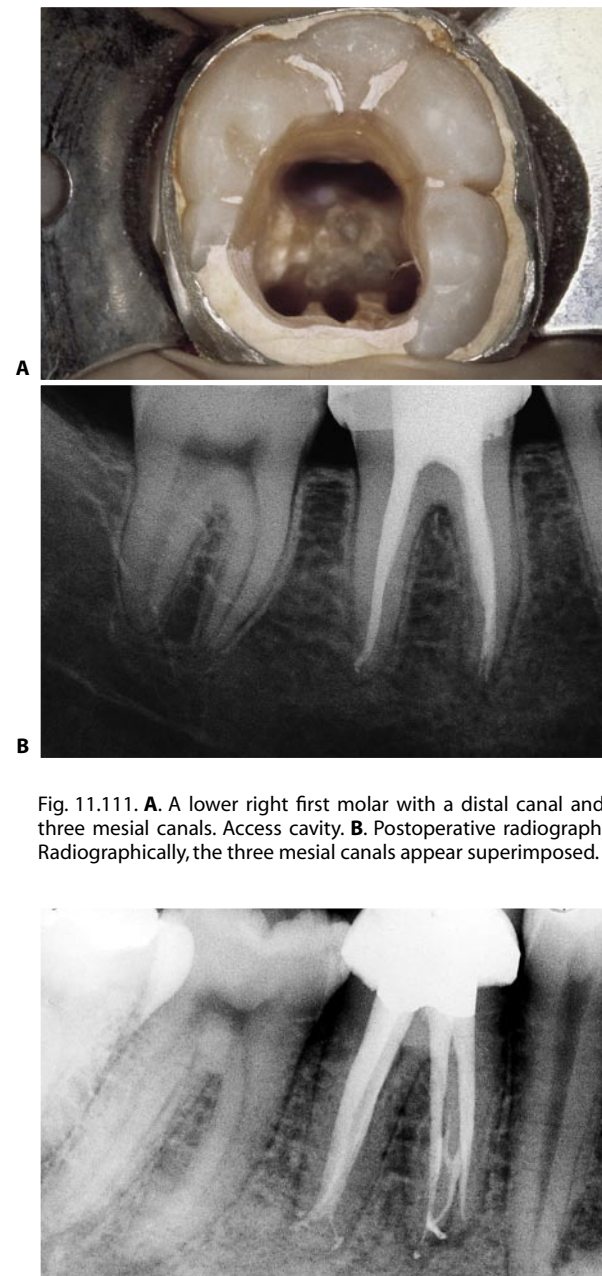


Fig. 11.111. **A.** A lower right first molar with a distal canal and three mesial canals. Access cavity. **B.** Postoperative radiograph. Radiographically, the three mesial canals appear superimposed.

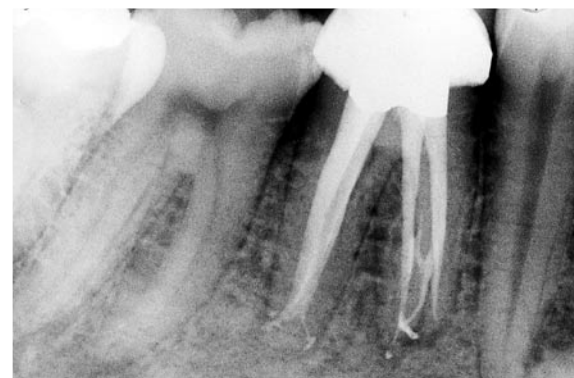

Fig. 11.112. In this other case, the middle mesial root canal is visible in the apical third of the mesial root (Courtesy of Dr. C.J. Ruddle).

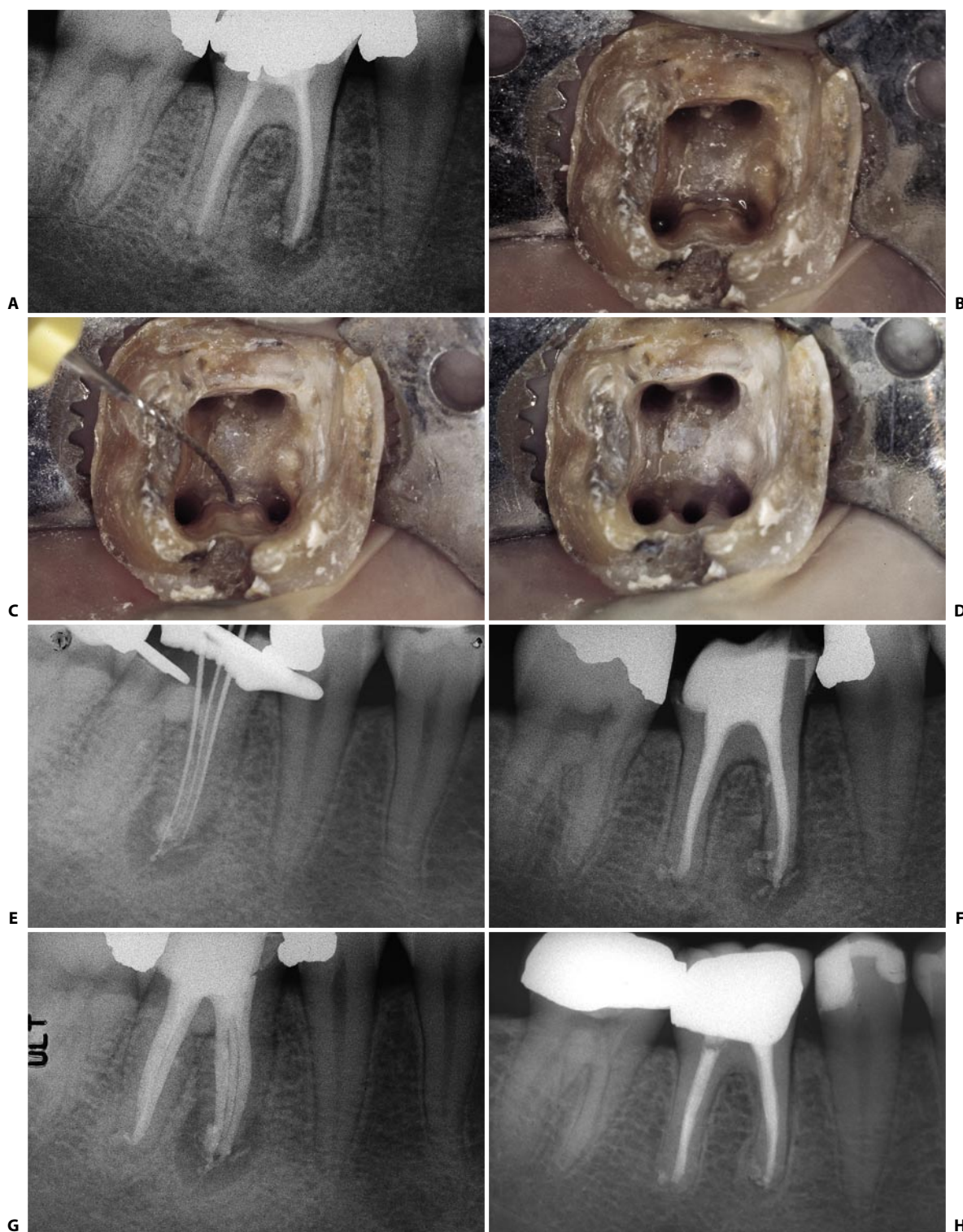


Fig. 11.113. Retreatment of a lower right first molar, where two canals had been missed: the distobuccal and the middle mesial canals. **A.** Preoperative radiograph. **B.** Access cavity after four canals had been prepared. Note the presence of a little depression in the isthmus between the two mesial canals. **C.** A # 10 file introduced into the depression very easily enters the middle mesial root canal, which has an independent foramen. **D.** The access cavity after preparing the five existing root canals. **E.** Three files show the three independent mesial root canals. **F.** Postoperative radiograph. **G.** The off-angle radiograph shows the five canals. **H.** The seven year recall radiograph shows the complete healing of the lesion, which was not caused by the foreign material, but by bacteria left in the missed root canals!

it has only one, it is usually ribbonshape, elliptical, or kidney shaped, that is, buccolingually elongated.

One must keep this in mind when creating the access cavity, which should not be triangular, as described by some authors, but rather trapezoidal or quadrangular with rounded corners.

The classical triangular shape would hamper the identification of the second distal canal (i.e., the distolingual one) and would also hamper adequate cleaning

and shaping of a single canal that might be present^{21,92} (Fig. 11.114).

Once more, therefore, the rule that it should not be the dentist to decide the shape of the access cavity but rather the anatomy of the pulp chamber floor, holds. The access cavity should therefore not have a pre-determined shape.

The access cavity is initiated with a round, diamond bur mounted on a high-speed handpiece. The bur is

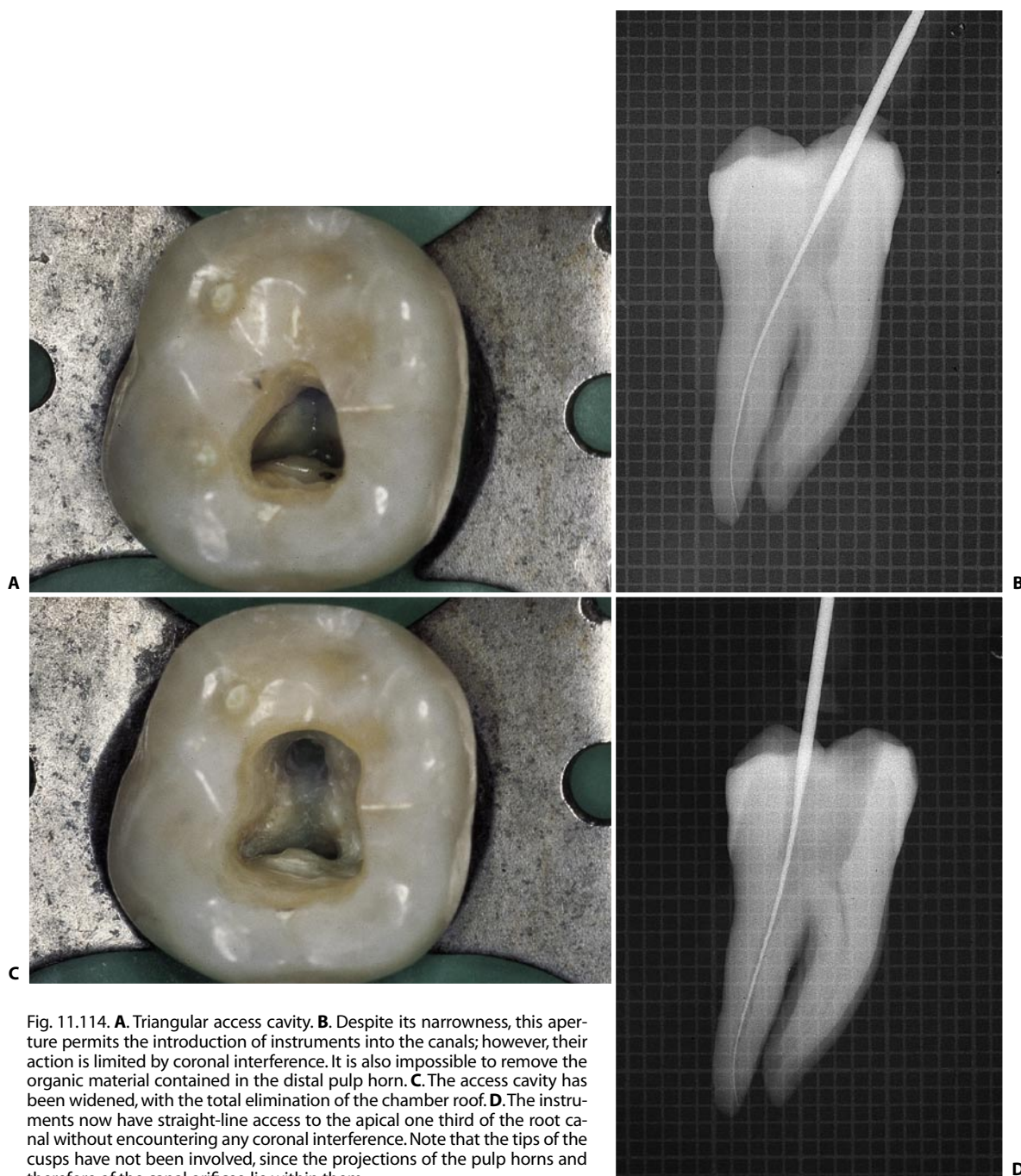


Fig. 11.114. **A.** Triangular access cavity. **B.** Despite its narrowness, this aperture permits the introduction of instruments into the canals; however, their action is limited by coronal interference. It is also impossible to remove the organic material contained in the distal pulp horn. **C.** The access cavity has been widened, with the total elimination of the chamber roof. **D.** The instruments now have straight-line access to the apical one third of the root canal without encountering any coronal interference. Note that the tips of the cusps have not been involved, since the projections of the pulp horns and therefore of the canal orifices, lie within them.

applied at the level of the central fossa (Fig. 11.115). A circular, helical movement is imparted to the bur, so as to scoop out an initial, funnel-shaped cavity as one tries to penetrate the roof of the pulp chamber. A careful radiographic examination allows one to orient the bur toward the widest pulp horn (Figs. 11.116 A-C). With a long-shafted round bur used at low speed, one removes the undercuts of dentin (Figs. 11.116 D, E); then, with the self-guiding diamond bur at high speed, one performs the finishing and slight flaring (Figs. 11.116 F-I). Only when there is a single, roundish distal canal should the access cavity be given a triangular shape (Fig. 11.114 C). In all other cases, the shape is trapezoidal, with the lesser base corresponding to the distal wall.



Fig. 11.115. The access cavity must have the shape of the projection of the pulp chamber floor onto the occlusal surface. The point of entry of the bur is identified by the central fossa.

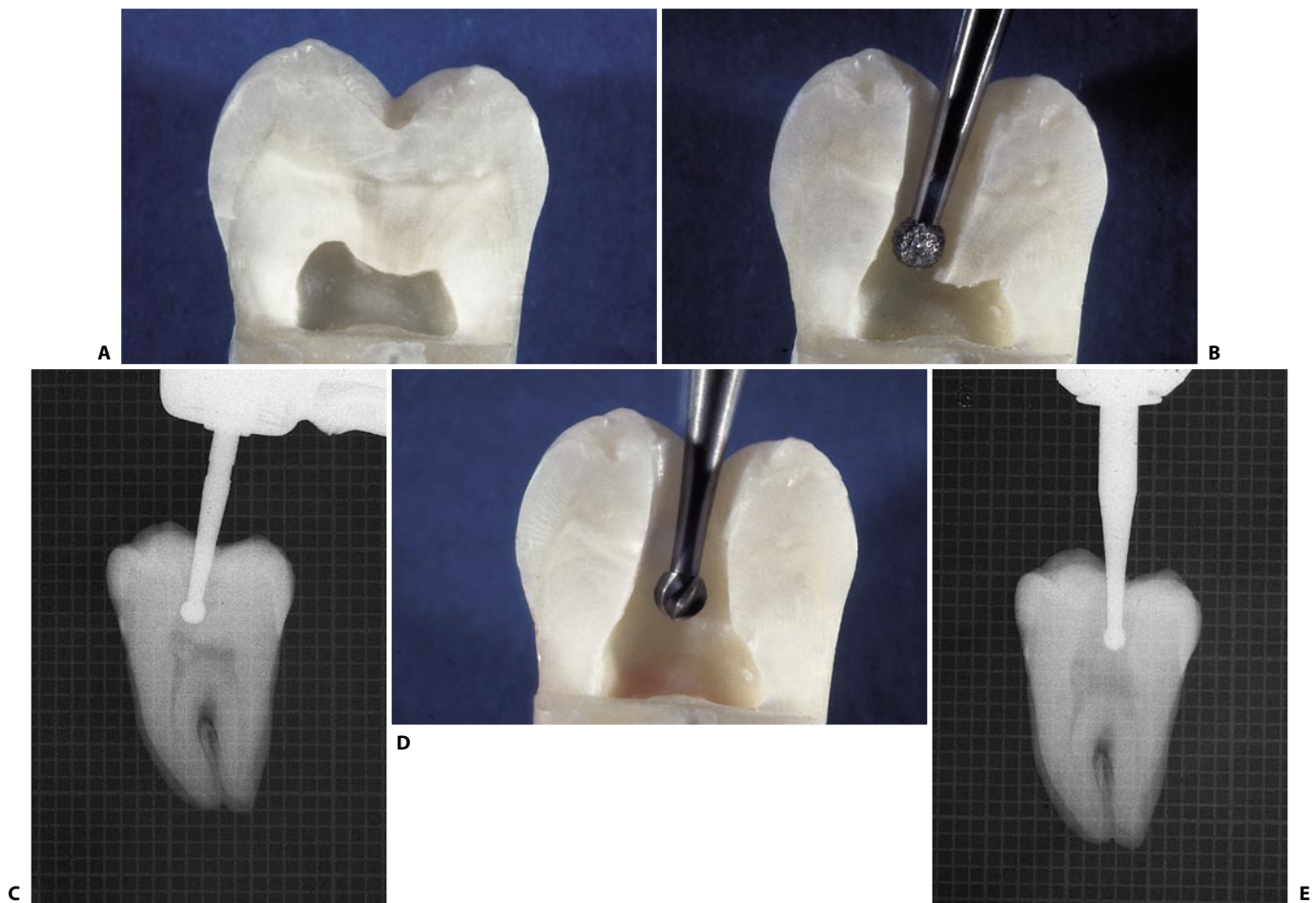


Fig. 11.116. **A.** Pulp chamber in a mesiodistal section. **B.** The round diamond bur penetrates toward the widest pulp horn. **C.** Radiographic appearance of the penetration phase. **D.** The low-speed round bur removes the residue of the chamber roof. **E.** Radiographic appearance of the widening phase (continued).

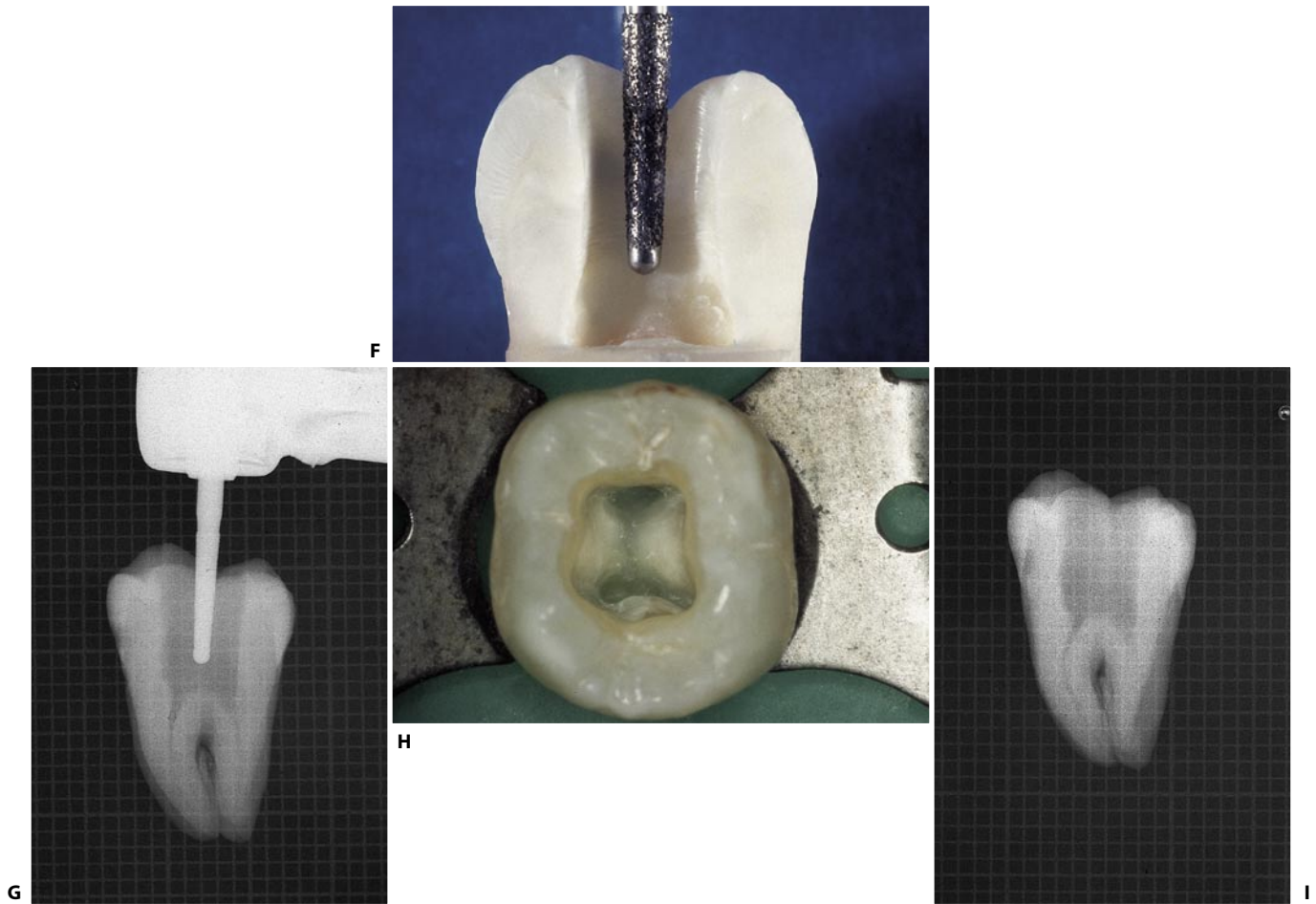


Fig. 11.116. (continued) **F.** The non-cutting diamond bur performs the finishing and flaring phase. **G.** Radiographic appearance of this phase. **H.** Completed access cavity. **I.** Radiographic appearance of the access cavity.

Once the access cavity has been prepared, the distal canal is the easiest to locate. Therefore, if there is any difficulty finding the other canals, it is advisable to start treating the distal. The irrigating solutions will help in identifying the other orifices.

Given that the mesiobuccal canal lies well below its respective cusp, it will very often be necessary to remove the cusp to find the orifice and to complete the treatment. It is certainly preferable to prosthetically reconstruct a cusp in an endodontically well-treated tooth rather than have an intact cusp above an endodontic failure. Furthermore, as in all the posterior teeth, protection of the cusps is always strongly advisable, if not mandatory.

The distal canal usually follows a rather straight course, except in the most apical portion, frequently oriented distally (Fig. 11.117). The reason this curve faces distally is easy to understand, if one keeps in mind

that the mandible has grown mesially while the tooth was completing its apical development. Consequently, the apex forms around a vascular peduncle, which, in the meantime, has assumed a mesiodistal inclination. It is important to keep in mind the existence of this canal curvature and to use small, precurved instruments. A straight instrument of inadequate size would be hampered by the external wall of the curve, giving the impression that it is in contact with the apical constriction or the cementodentinal junction. A small, precurved instrument, on the other hand, can easily negotiate such an apical curvature.

The canals of the mesial root take a more curved course with a mesial orientation immediately below the orifice and then distal in the rest of the root canal. Sometimes, the mesiobuccal canal at its opening faces buccally – in confirmation of which the handle of the instrument introduced faces lingually – and this fur-

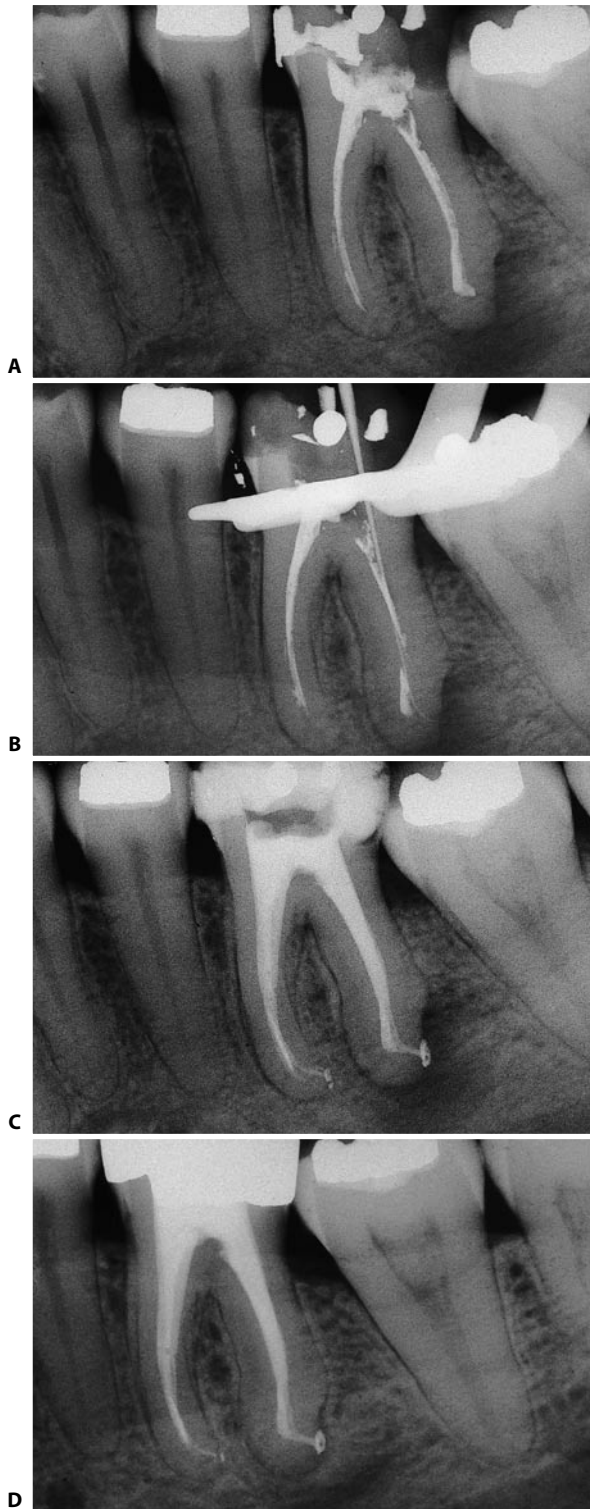


Fig. 11.117. The distal root canal of the lower molars often faces distally, sometimes with an angle of about 90° . If the instruments are not precurved, the obturation will be short, possibly leaving one with the impression that one has reached the cementodentinal junction or the apical constriction. **A.** Preoperative radiograph. The canals were treated with iodoformic paste. **B.** An adequately precurved # 08 file follows the pronounced curvature of the canal. **C.** Postoperative radiograph. **D.** Recall radiograph two years later. Note that the obturation has been made at the radiographic terminus of the canal and, at the same time, is at least three millimeters short from the radiographic apex!

ther obliges one to remove the cusp to obtain a straight-line access to the apical one third (Fig. 11.14). Since the presence of a curvature in the mesial canals – and therefore the root that contains them – is almost the rule, the use of the “anticurvature” filing method¹ is obligatory in the preparation of these root canals, which, together with the mesiobuccal canal of the upper first molars, are the most frequent site of strip perforations (Fig. 11.118).

In 10% of cases, the two canals join at the apex in a single foramen (Fig. 11.119). This joining, in this author's opinion, is more easily recognized after the complete cleaning and shaping of at least one canal rather than at the beginning of treatment. Indeed, two small files can be simultaneously introduced into the two different root canals down to the apex, even if they join together in a single foramen, since it can be sufficiently wide as to let both pass. The introduction of a larger instrument into one and a smaller one into the other can lead to fracture of the smaller instrument which, on the other hand, can also be passed between the spirals of the other and arrive equally at the canal terminus.

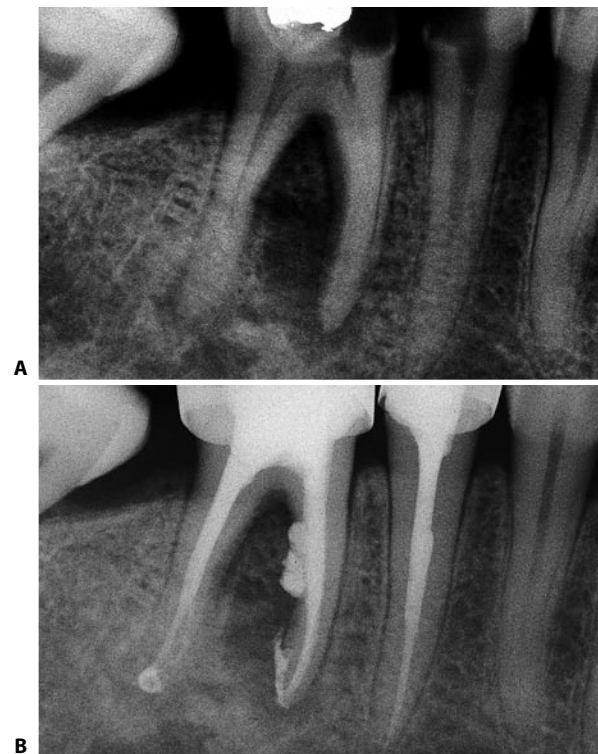


Fig. 11.118. Neglecting to apply the anticurvature filing method leads as a consequence to excessive thinning of the root and perforation or stripping. **A.** Preoperative radiograph. Note the thinness of the mesial root and its slight curvature. **B.** Postoperative radiograph. The result of the stripping is evident.

In this author's opinion,²² the use of a gutta-percha cone in a canal which has just been prepared and a small instrument in the other yet to be prepared, is safer. If the two canals join together, the imprint left by the instrument on the gutta-percha cone will be visible (Fig. 11.120).

Because it is easier to cause stripping in the mesiobuccal than the mesiolingual canal of the lower first molar,¹² it is advisable always to begin by cleaning and

shaping the two canals of the mesial root, beginning with the mesiolingual canal and then seek, with the help of a gutta-percha cone and a small instrument, the confluence of the mesiobuccal canal in a common foramen.

Such an occurrence allows one to save dentin in the mesiobuccal canal by enlarging the canal less, and one therefore runs less risk of causing stripping.

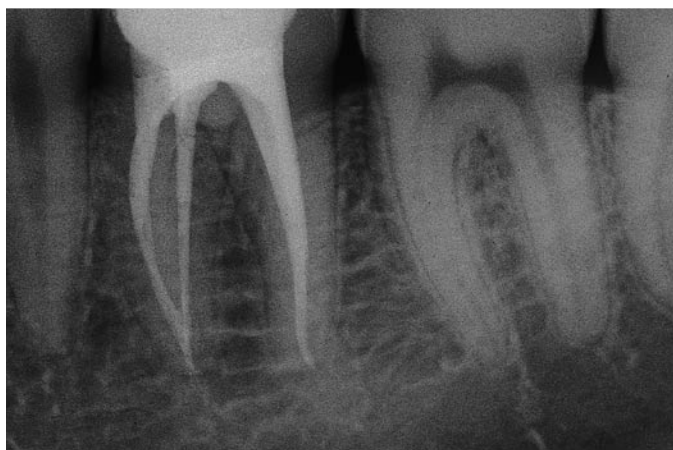

Fig. 11.119. The postoperative radiograph shows the mesial canals joining at a common foramen.

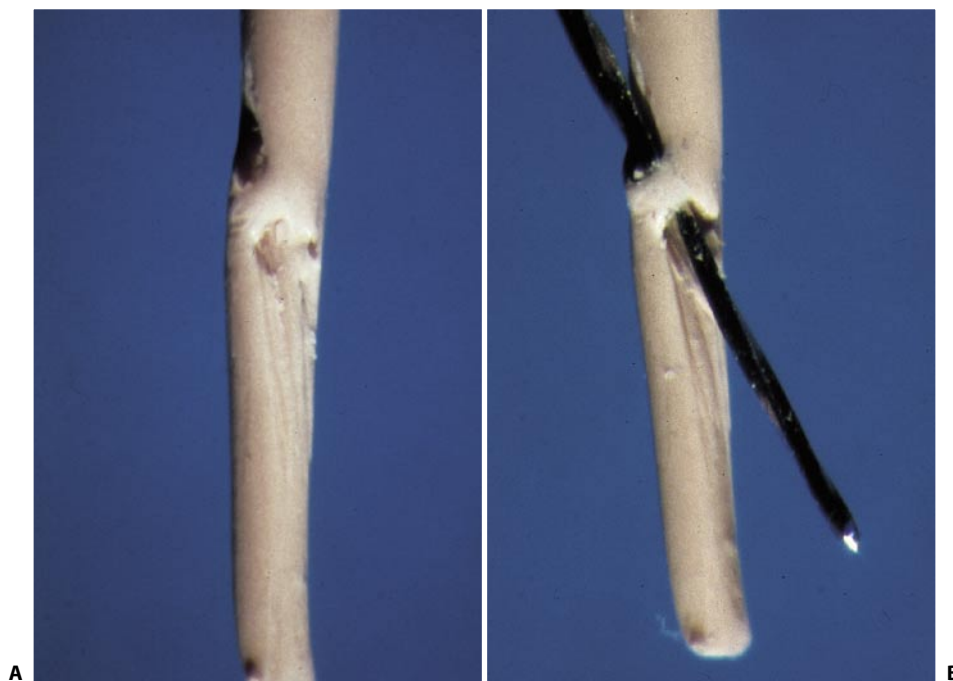


Fig. 11.120. **A, B.** The gutta-percha cone had been inserted in the cleaned and shaped mesiolingual canal, and the # 08 file has been inserted into the mesiobuccal canal, which has yet to be prepared. Given the confluence, the file has tunneled through the gutta-percha cone.

LOWER SECOND MOLAR

The anatomical variability of the lower second molar is even greater than that of the first molar.⁶² In general terms, its anatomy is very similar to that of the first molar; the only difference is that it is somewhat smaller, more symmetric, and has more closely-spaced roots.

Many times, however, its appearance may be bizarre, different from the usual morphology, as it may have various combinations:^{23,25}

- One canal may be in the distal root, while two independent canals (Fig. 11.121) or two canals joining at a single apical foramen (Fig. 11.122) may be in the mesial root.
- In other cases, the mesial root may have only a centrally-situated canal, so that the tooth has a distal canal and only one mesial canal (Fig. 11.123). To be certain that the mesial root has a single canal, it is necessary to check the position of its orifice in the floor of the pulp chamber and obtain different radiographic views. Sometimes a perforation can be found in the lingual side of the access cavity, because the previous dentist was looking for the mesiolingual canal while the mesial root had only one mesial canal.
- The tooth can have the classical three canals, but they may be oriented unusually. For example, the orifice of the mesiolingual canal might be found much closer to the distal than to the mesiobuccal canal (Fig. 11.124). There may be a mesial root with a single canal, while the distal root contains two ca-

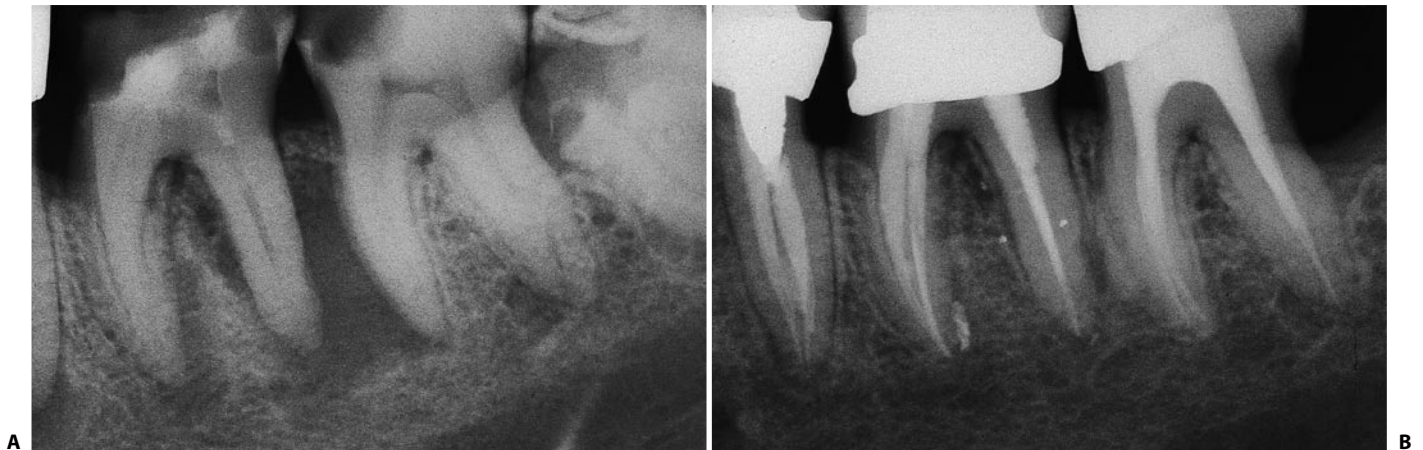

Fig. 11.121. A lower second molar with one distal and two mesial canals with independent apices. **A.** Preoperative radiograph. **B.** Recall radiograph two years later.

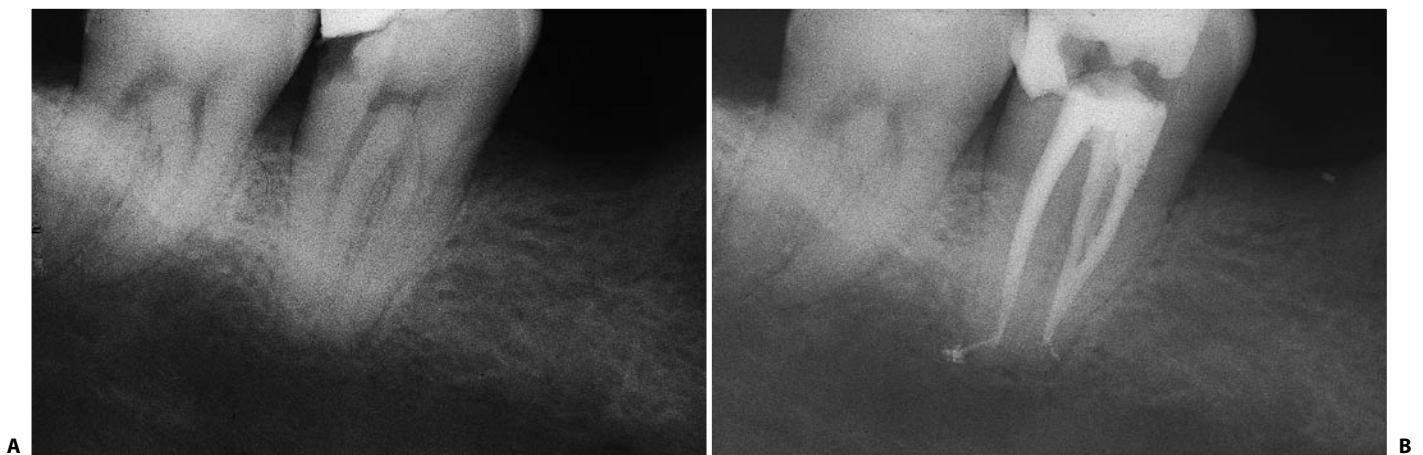


Fig. 11.122. A lower second molar with a distal and two mesial canals joining together at a common apex. **A.** Preoperative radiograph. **B.** Postoperative radiograph.

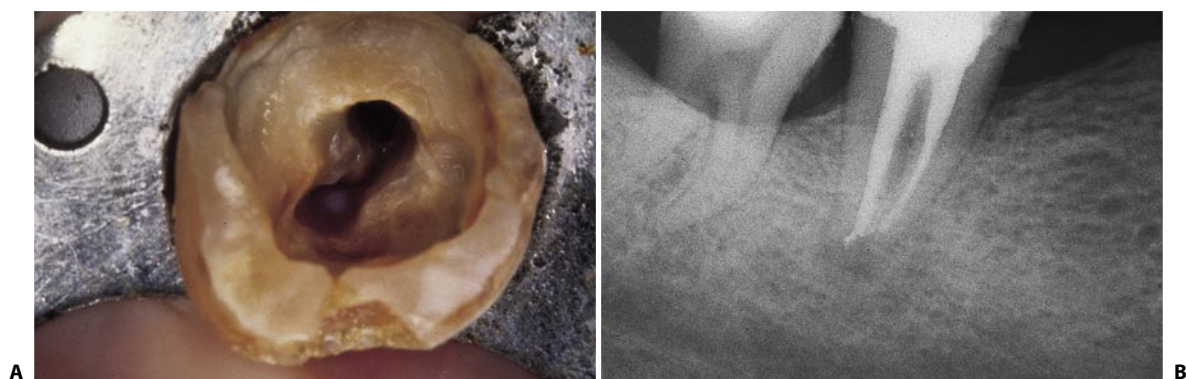

Fig. 11.123. A lower second molar with one canal in the distal root and a single canal in the mesial root. **A.** Access cavity: the two canals are at the two ends of the shallow groove in the floor of the pulp chamber. On the right, the impression of the bur is recognizable (in a lingual direction). The previous dentist was looking for the non-existing mesiolingual canal. **B.** Postoperative radiograph: the two canals lie in separate roots, which barely communicate near their apical foramina.

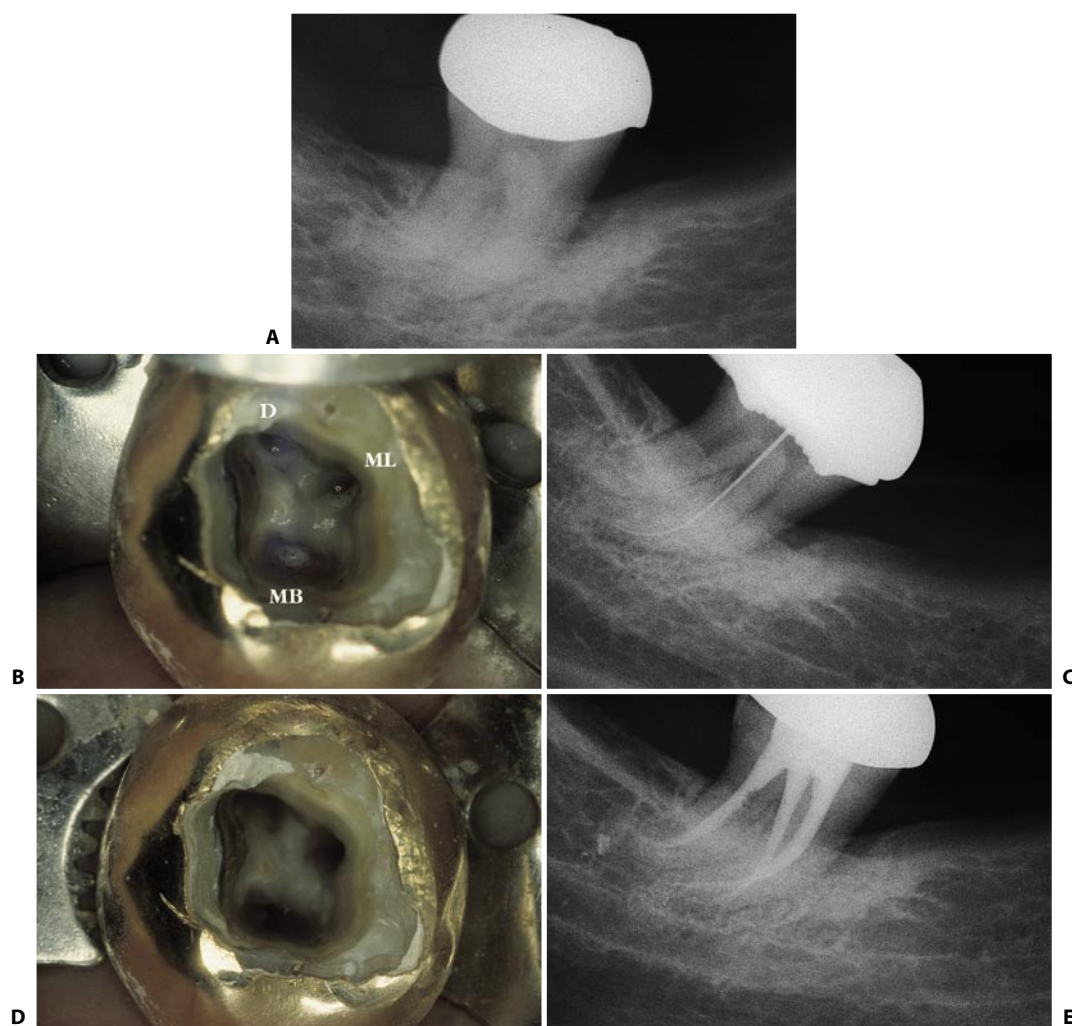


Fig. 11.124. A lower second molar with the three classical canals oriented a bit unusually: the mesiolingual canal is close to the distal canal. **A.** Preoperative radiograph. **B.** Access cavity: the opening of the mesiolingual canal is very close to that of the distal canal, so much so that it resembles a distolingual canal. D, distal canal; ML, mesiolingual canal; MB, mesiobuccal canal. **C.** Intraoperative radiograph demonstrating the course of the mesiolingual canal. **D.** Access cavity showing cleaned and shaped root canals. **E.** Postoperative radiograph.

nals, which join at the apex (Fig. 11.125). In this case, the tooth will have three canals, but will appear as though it was rotated 180 degrees.^{25,98}

- The tooth may have a single root containing two canals, one mesial and one distal, which are independent (Fig. 11.126) or joined at the apex (Fig. 11.127).
- The molar may have a single root containing a single canal (Fig. 11.128).
- Quite rarely, the lower second molar may have three roots with three independent canals, one distal and two mesial,⁹² (Fig. 11.129) or three roots

with four canals, one distobuccal, one distolingual, and two mesial (Fig. 11.130).

- In some cases, the molars may appear clinically and radiographically unexceptional, but in fact have unusual canal communications, which one can find out in different phases of the root canal treatment:

1. Following preparation of the access cavity.

This is the case of the so-called “C-shaped canal”, which Weine et al. have reported is present in 2.7% of cases.⁹⁵ It was described for the first time by Cook and Cox²⁷ in the lower second molar, but it may sometimes be found in the lower first molar.^{7,13,45,74,94}

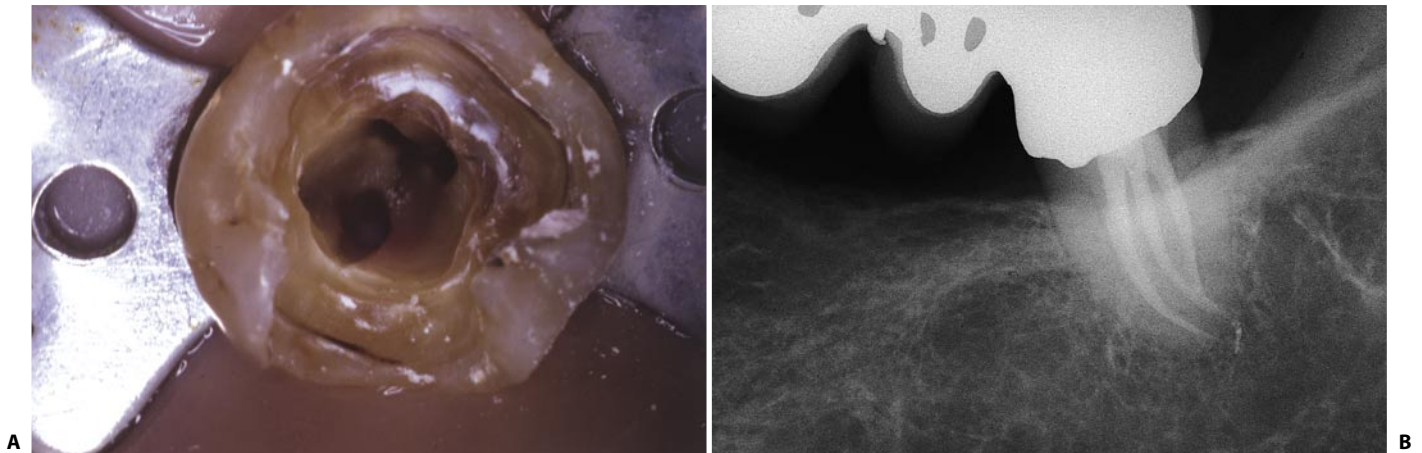


Fig. 11.125. A lower second molar with a single mesial canal and two distal canals, joining at a common apex. **A.** Access cavity: the three openings are noted, but the tooth seems to be rotated 180°. **B.** Two year recall.

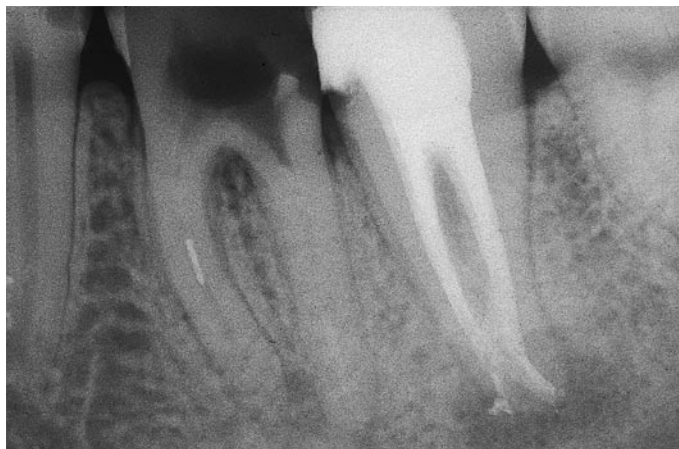

Fig. 11.126. Postoperative radiograph of a lower left second molar with two independent canals in a single root.

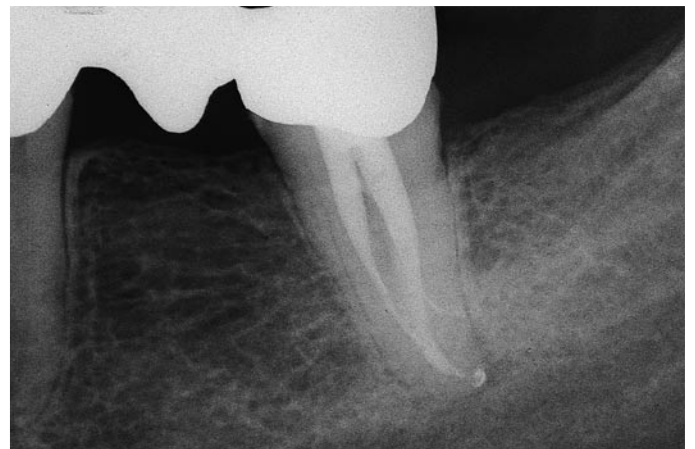

Fig. 11.127. Postoperative radiograph of a lower left second molar with two merging root canals in a single root.

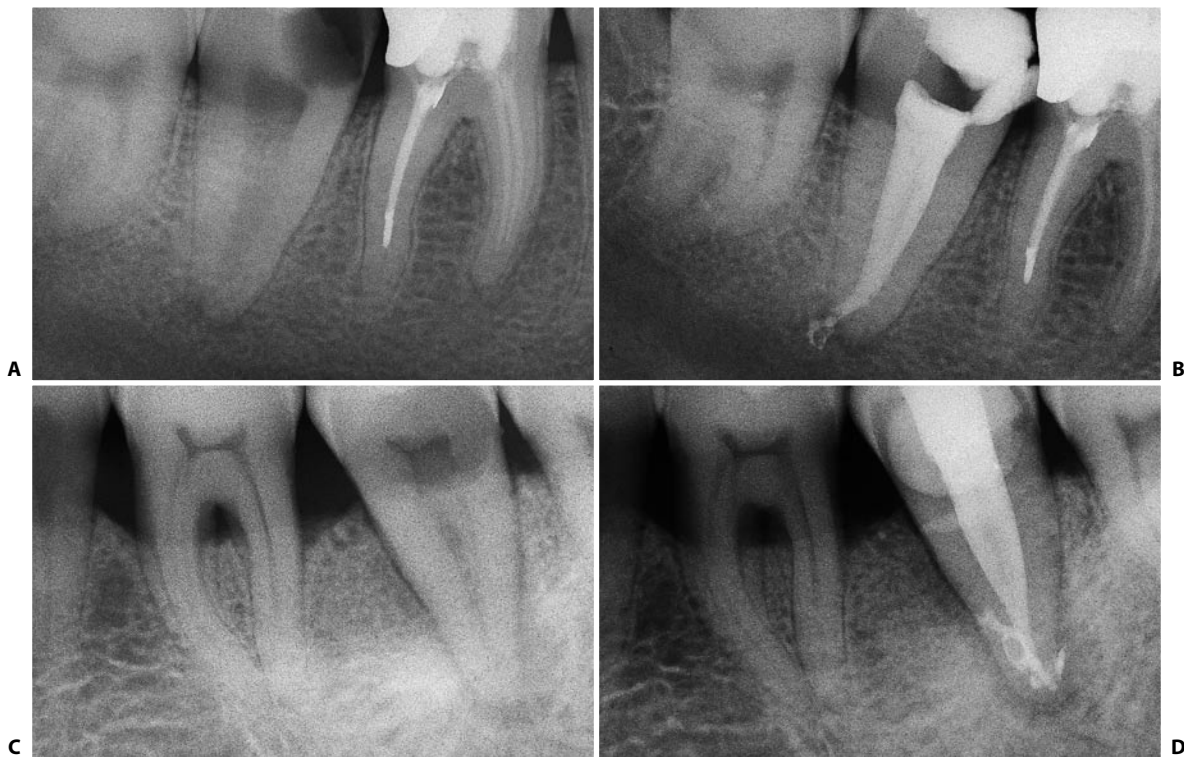

Fig. 11.128. Lower second molars with a single root and a single canal. **A.** Preoperative radiograph. **B.** Postoperative radiograph. **C.** In this other case, from the preoperative radiograph the second molar seems to have two fused roots with the three classical root canals. **D.** After cleaning and shaping, the tooth reveals a single root containing a single canal. Note the bizarre endodontic anatomy.

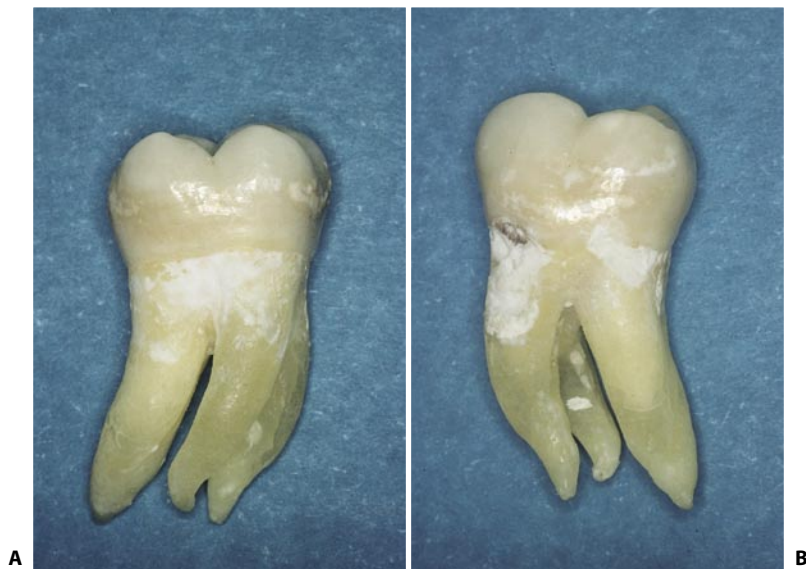


Fig. 11.129. The two mesial canals of this extracted second molar are in independent roots. **A.** Lingual view. **B.** Buccal view.

This anatomy is quite common among oriental patients.^{91,99}

Instead of having three separate orifices, the three canals have a single “C-shaped” one, the convexity facing buccally (Fig. 11.131).

The introduction of an instrument into the mesio-buccal portion causes an unusual radiographic image, which may lead one to suspect a perforation; in fact, it is the mesiobuccal canal, which can join the

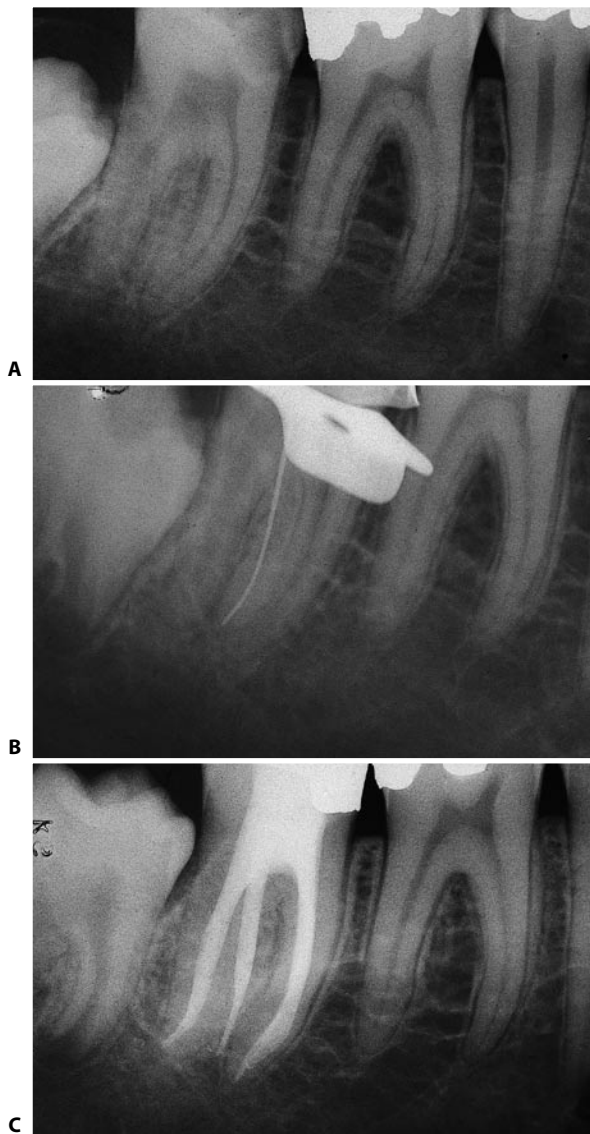


Fig. 11.130. A lower right second molar with two distal canals in two separate roots. **A.** The preoperative radiograph reveals the presence of one root, the distolingual root, within the bifurcation. **B.** The instrument that simulates a perforation of the floor is in fact within the distolingual canal. **C.** Two year recall.

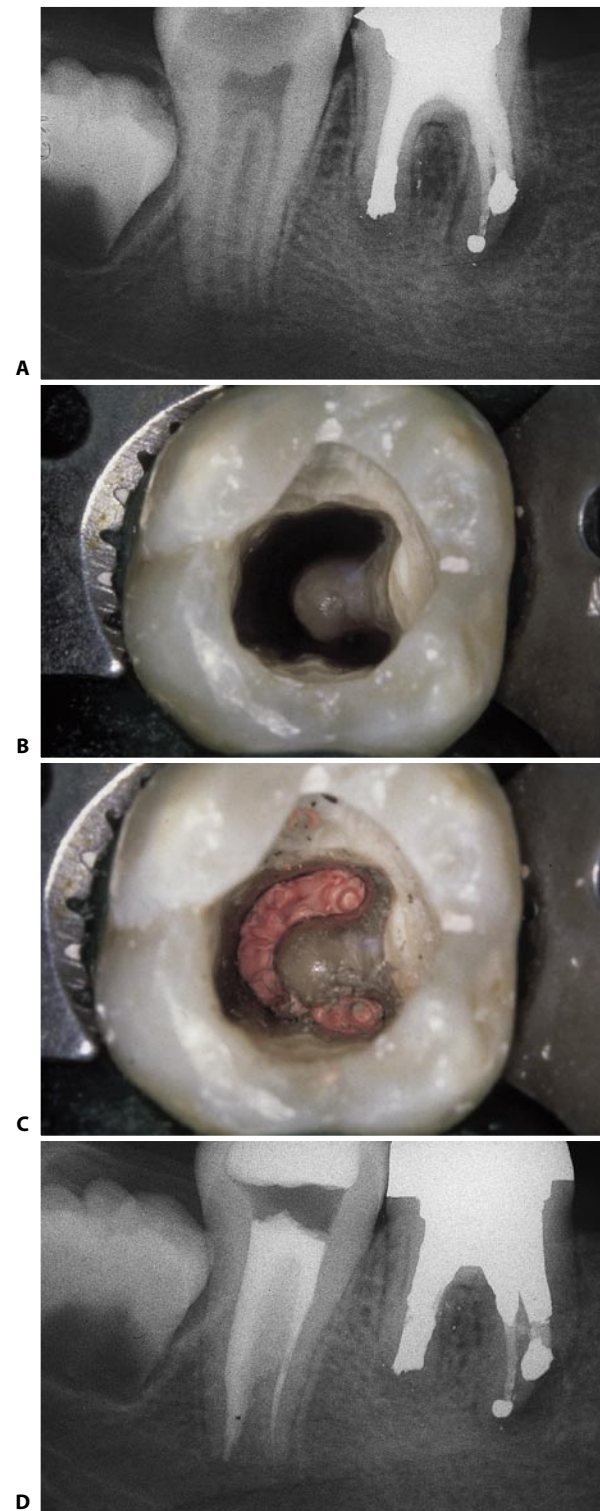


Fig. 11.131. A lower right second molar with a C-shaped canal. **A.** Preoperative radiograph. **B.** Access cavity. Note the typical C-shaped appearance of the three connected canal openings. **C.** Three-dimensional obturation with warm gutta-percha has been completed. **D.** Postoperative radiograph. The C-shaped communication extends to the level of the apical one third.

distal⁷ (Fig. 11.132) or the mesiolingual canal²³ (Fig. 11.133). The “C-shaped” communication among the various canal openings can extend apically to a variable depth, and this can be visualized only by the root canal filling (Figs. 11.134-11.136).

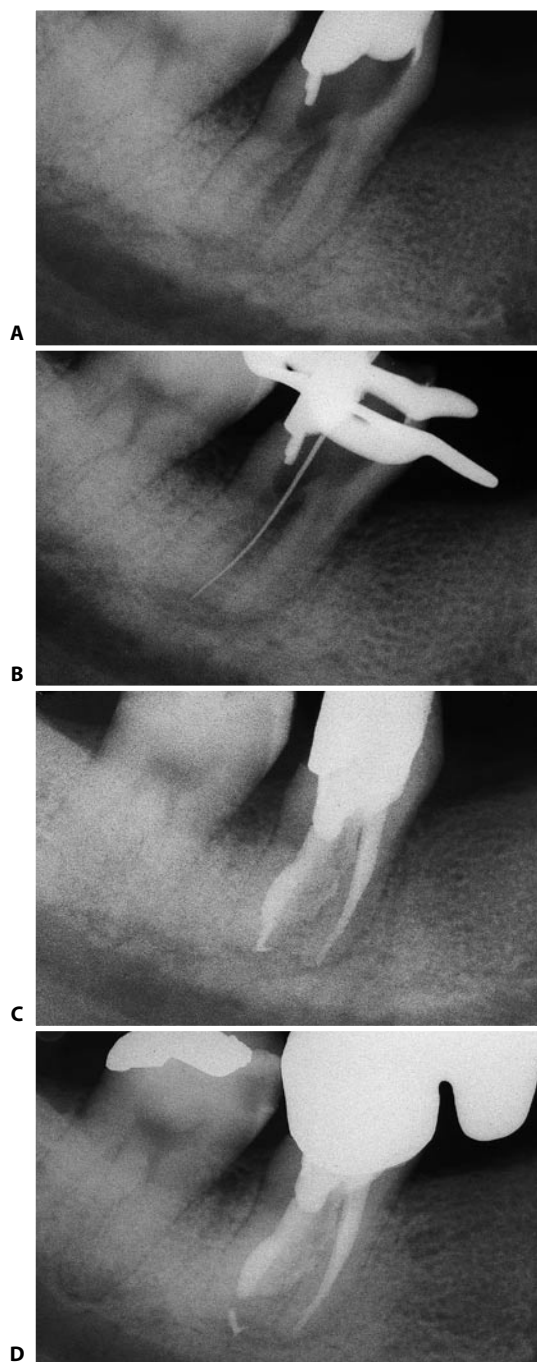


Fig. 11.132. A lower second molar with a C-shaped canal, in which the mesiobuccal canal runs into the distal canal. **A.** Preoperative radiograph. **B.** An instrument introduced into the convexity of the “C” simulates a perforation of the floor; actually, it is negotiating the mesiobuccal canal which, in this case, runs into the distal canal. **C.** Postoperative radiograph. **D.** Three year recall.

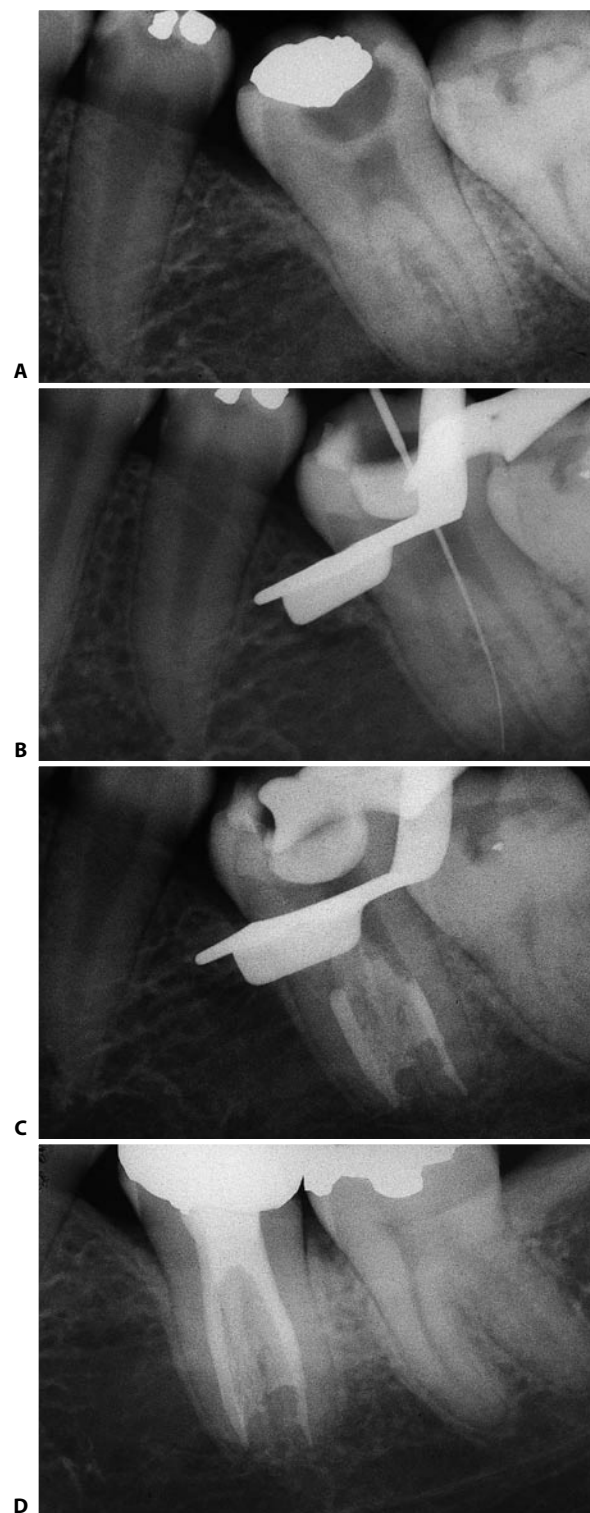


Fig. 11.133. A lower left second molar with a C-shaped canal, in which the mesiobuccal canal runs into the mesiolingual canal. **A.** Preoperative radiograph in which the presence of a C-shaped canal cannot be detected. **B.** Intraoperative radiograph: an instrument introduced in the convexity of the “C” simulates a perforation of the floor; actually, it negotiates the mesiobuccal canal which, in this case, runs into the mesiolingual canal. **C.** Intraoperative radiograph of the apical condensation: only with a technique that includes the condensation of the heat-softened gutta-percha is it possible to three-dimensionally obturate the entire extent of the “C”. **D.** Three year recall.

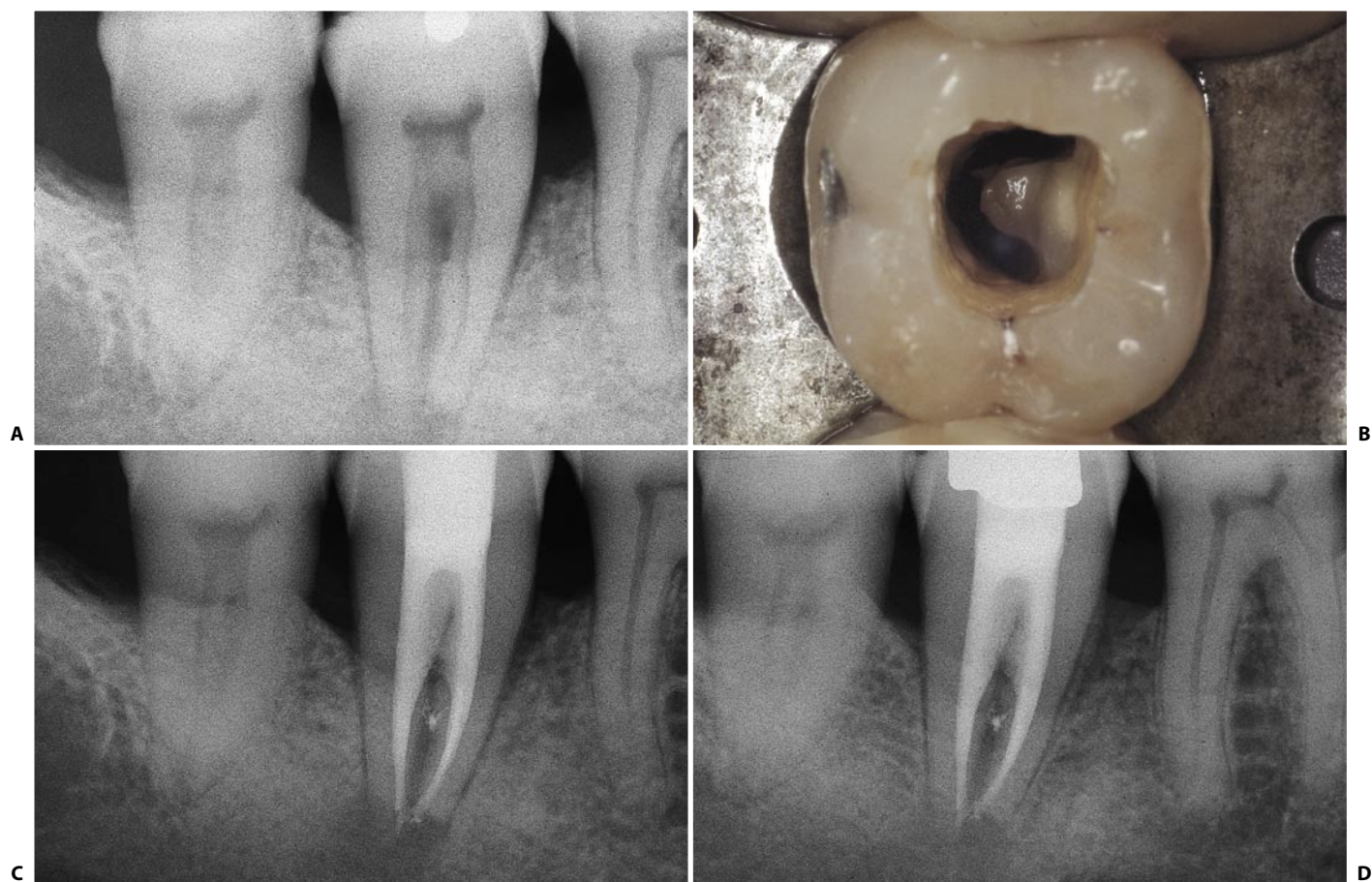


Fig. 11.134. A lower right second molar with a C-shaped canal. The ribbon shaped communication among the three canals extends apically as far as the middle one third. **A.** Preoperative radiograph. **B.** Access cavity with a typical ribbon shaped opening. **C.** Postoperative radiograph. **D.** Recall radiograph 18 months later.

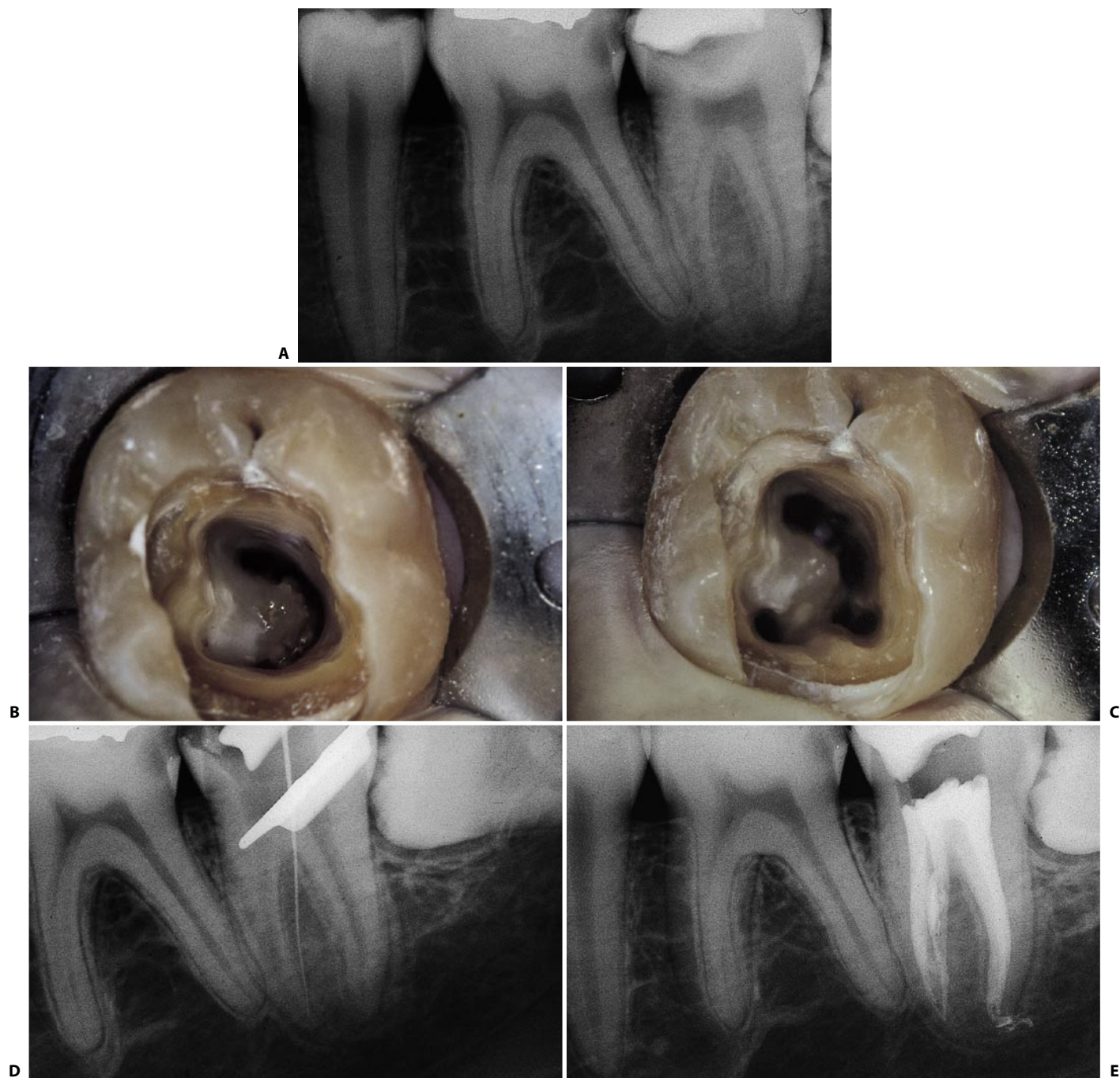


Fig. 11.135. A lower left second molar with an incomplete C-shaped canal. **A.** Preoperative radiograph. **B.** Access cavity: the three canals appear to be joined by a groove with a buccal convexity. A C-shaped canal was diagnosed. **C.** After completing the cleaning and shaping phases, the "C" appears incomplete, as it involves only the distal and mesiobuccal canals. **D.** An instrument introduced into the mesiobuccal canal indicates the confluence of this canal with the mesiolingual canal. **E.** Postoperative radiograph.

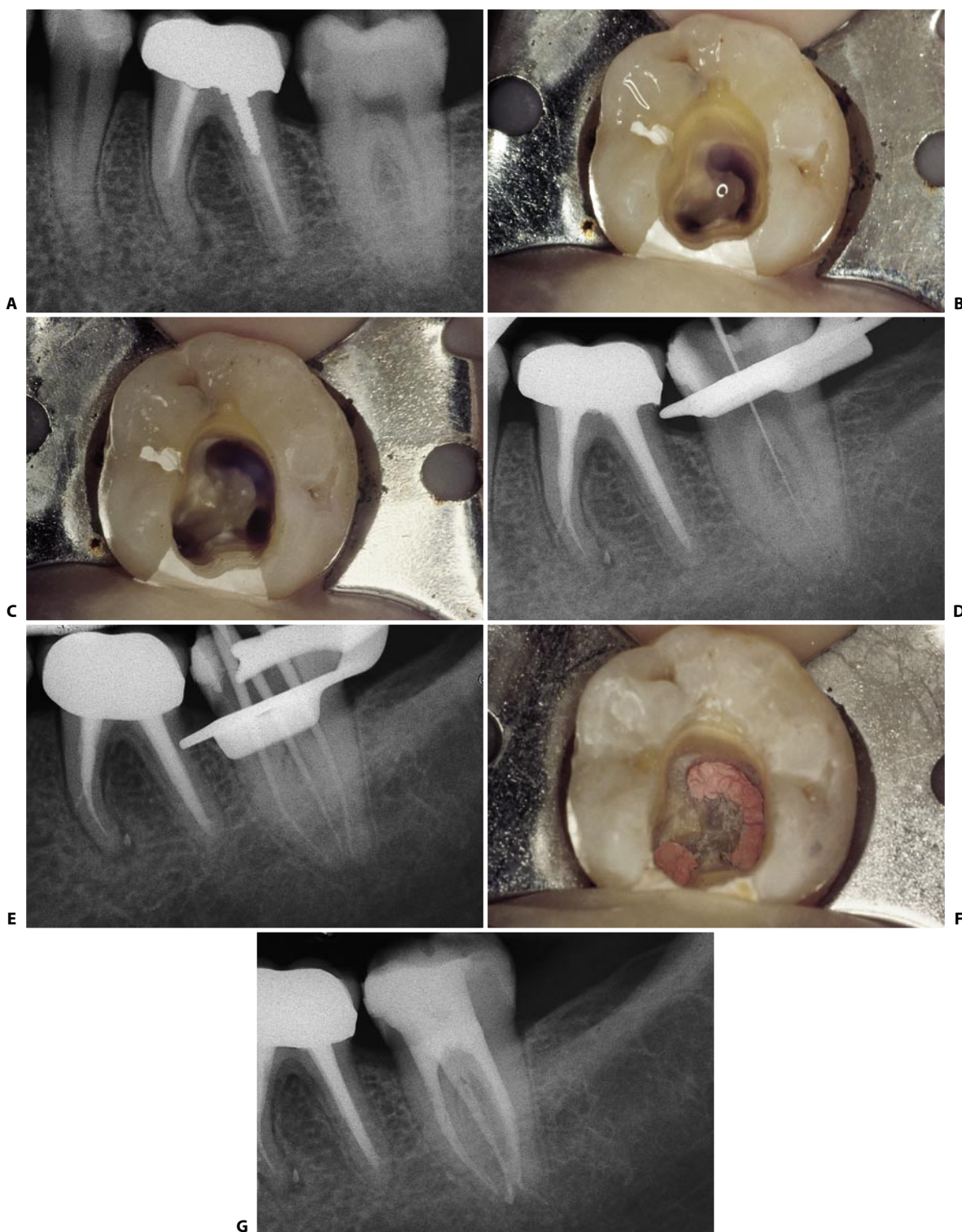

Fig. 11.136. A lower left second molar with an incomplete C-shaped canal. **A.** Preoperative radiograph. **B.** Access cavity. The distal and mesiobuccal canals appear to be joined by a groove with a buccal convexity. **C.** Access cavity following preparation of the root canal. **D.** An instrument introduced into the mesiobuccal canal raises the suspicion of a confluence between this and the distal canal. **E.** Intraoperative radiograph of the cone fit. **F.** Access cavity after obturation is completed. One notes more clearly that the "C" is incomplete. **G.** Postoperative radiograph. Note that the mesiobuccal canal communicates with the distal canal, but does not flow into it, as it has an independent apical foramen.

This bizarre type of endodontic anatomy is easily explained by examining an extracted tooth (Fig. 11.137). Seen from the buccal side (Fig. 11.137 E), the tooth appears singlerooted, while from the lingual side (Fig. 11.137 F) the tooth demonstrates the normal anatomy of a lower molar: two roots, one of which is mesial, the other distal, separated by a va-

riable interradicular bony septum. The molar with a “C-shaped” canal is therefore a singlerooted tooth with a kidney shaped root. The canal contained within also has a kidney shaped appearance which can be preserved unaltered throughout its coronal-apical length or which can branch into individual canals at various levels.

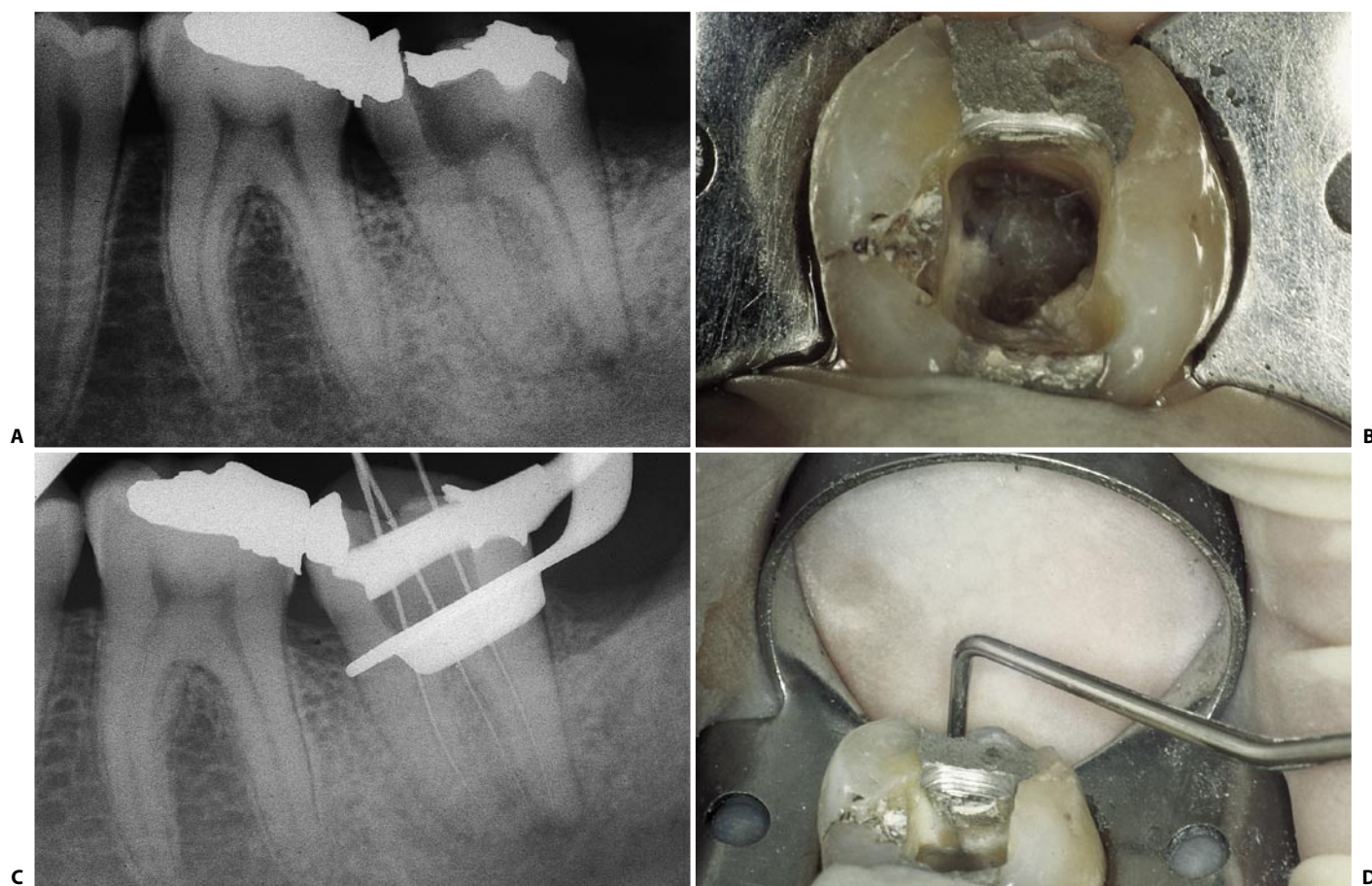


Fig. 11.137. **A.** Radiographically, the lower second molar seems to have the classical endodontic anatomy. **B.** Careful examination of the pulp chamber floor indicates a C-shaped canal. **C.** The introduction of instruments into the respective canals confirms the diagnosis. Note that the instrument in the mesiobuccal canal simulates a perforation of the floor. **D.** This tooth had a vertical root fracture distally and was therefore extracted (continued).

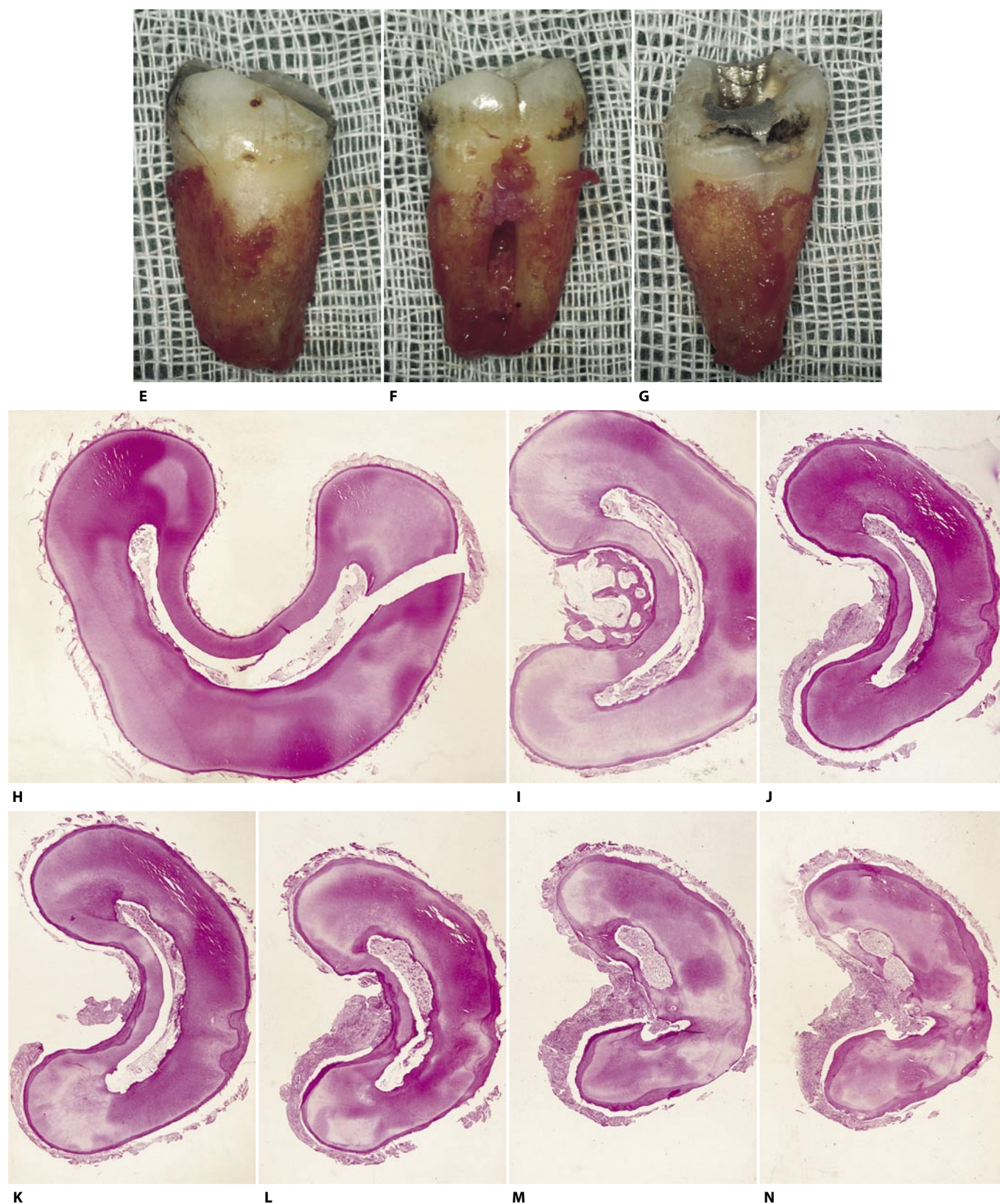


Fig. 11.137. (continued) **E.** Buccal aspect: the tooth is actually a singlerooted tooth, with a kidney shaped root. **F.** Lingual aspect: two roots separated by a bony septum are seen. **G.** The distal aspect shows the vertical root fracture with associated the granulation tissue. **H-N.** Histologic sections of the same tooth. Sections are about 1-2 millimeters from each other.

2. At the moment of canal obturation.

This is the case of confluence, albeit rare, between the mesiobuccal and the distal⁷³ canals (Fig. 11.138) or between the mesiobuccal and the distobuccal canals, in case two canals are found in the distal root (Fig. 11.139). At the moment of individually performing the obturation in the different canals, condensation of the material in the distal canal may push the sealer and gutta-percha into the mesiobuccal canal through the communication, which had pre-

Fig. 11.138. The postoperative radiograph shows the mesiobuccal merging into the distal canals.

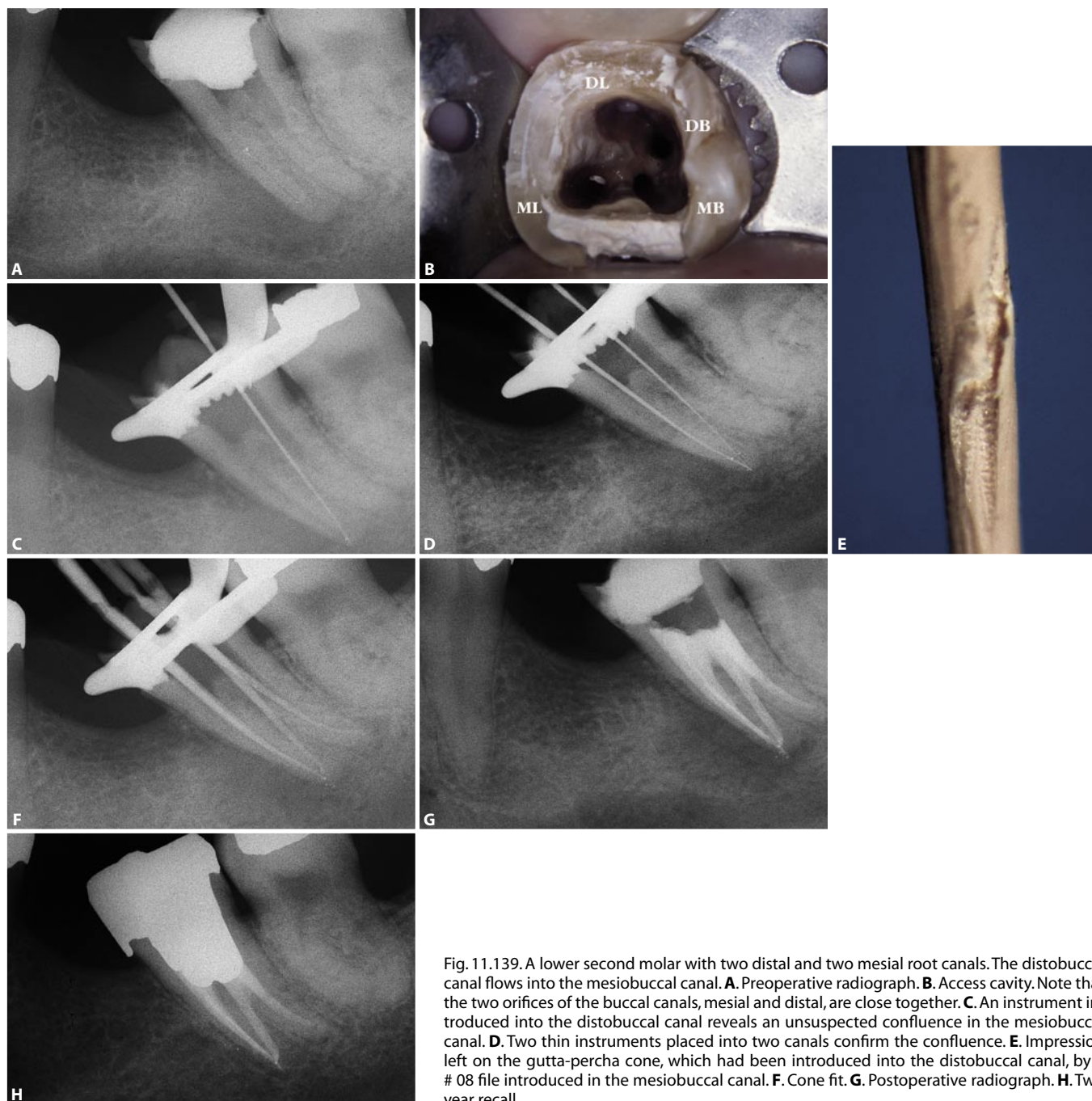
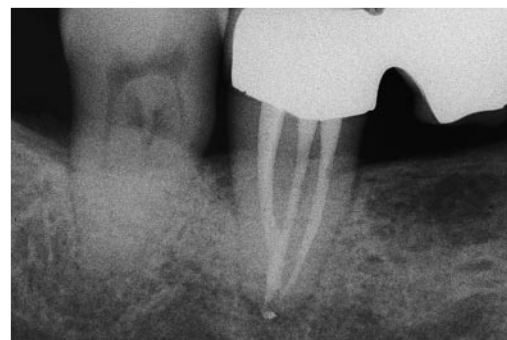

Fig. 11.139. A lower second molar with two distal and two mesial root canals. The distobuccal canal flows into the mesiobuccal canal. **A.** Preoperative radiograph. **B.** Access cavity. Note that the two orifices of the buccal canals, mesial and distal, are close together. **C.** An instrument introduced into the distobuccal canal reveals an unsuspected confluence in the mesiobuccal canal. **D.** Two thin instruments placed into two canals confirm the confluence. **E.** Impression left on the gutta-percha cone, which had been introduced into the distobuccal canal, by a # 08 file introduced in the mesiobuccal canal. **F.** Cone fit. **G.** Postoperative radiograph. **H.** Two year recall.

viously gone undetected. This, among other things, confirms that it is possible, with adequate technique, to prepare individually two confluent canals without any risk of obstructing either of them.²³ This type of communication between the mesiobuccal and distal canals can and must be diagnosed in an earlier phase, namely during the cleaning and shaping of one of the two canals. Once one canal has been prepared, a gutta-percha cone is placed into it and a small instrument (e.g., a # 08 file) is introduced into the other canal, which has yet to be prepared. If the two canals join together, careful examination of the surface of the gutta-percha co-

ne will reveal the imprint left by the file used in the other canal (Fig. 11.140).

The access cavity of this tooth is started from the central fossa, and it is created according to the same rules used for the first molar. Because of the slight distal angulation of its roots, the access cavity can, however, be less extensive in this case.¹⁷

The shape of the access cavity depends on whether there is one, two, three, or four canals; it may be round to oval, triangular, or quadrangular.

For this tooth as well, cusp protection is highly recommended.

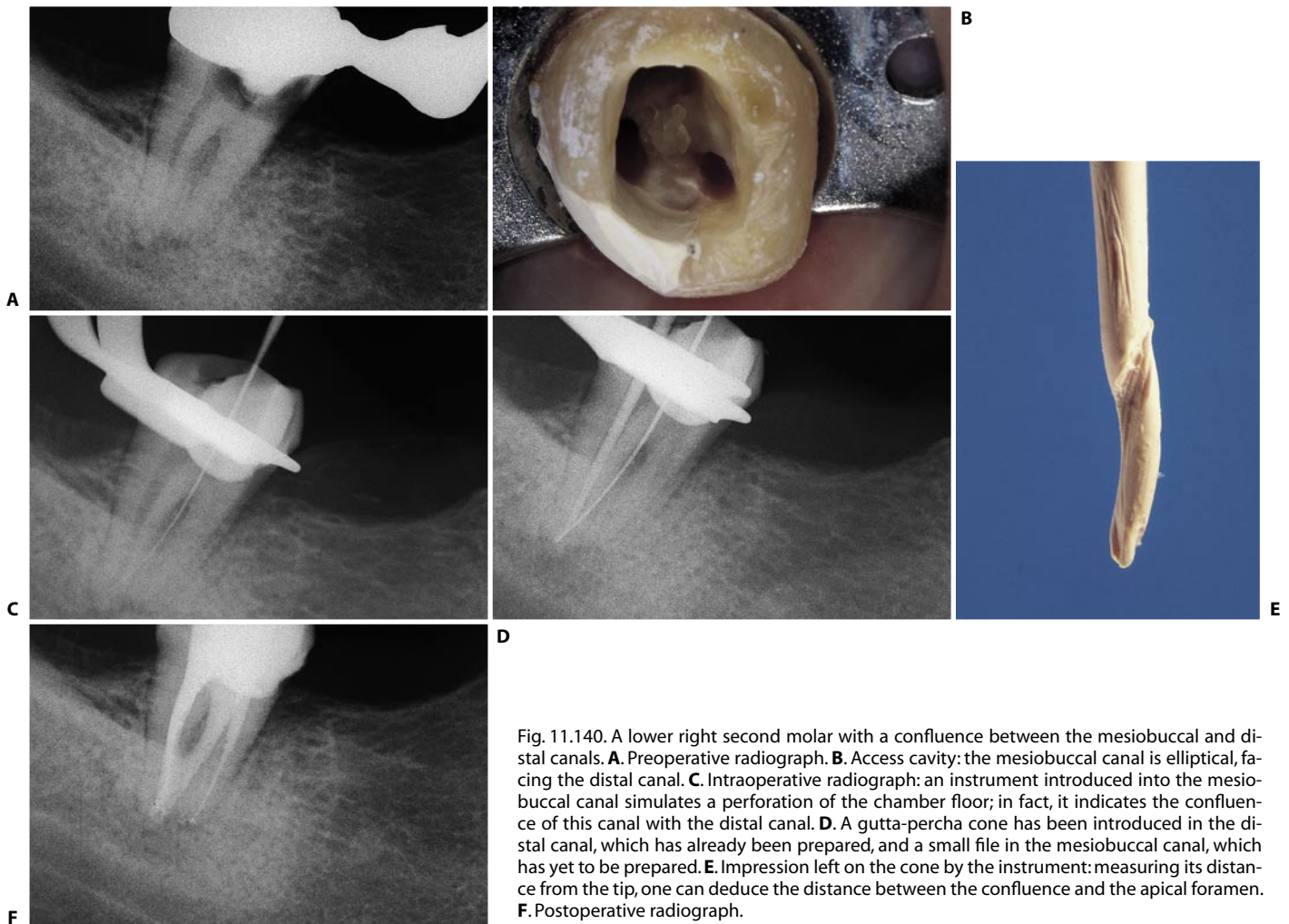


Fig. 11.140. A lower right second molar with a confluence between the mesiobuccal and distal canals. **A.** Preoperative radiograph. **B.** Access cavity: the mesiobuccal canal is elliptical, facing the distal canal. **C.** Intraoperative radiograph: an instrument introduced into the mesiobuccal canal simulates a perforation of the chamber floor; in fact, it indicates the confluence of this canal with the distal canal. **D.** A gutta-percha cone has been introduced in the distal canal, which has already been prepared, and a small file in the mesiobuccal canal, which has yet to be prepared. **E.** Impression left on the cone by the instrument: measuring its distance from the tip, one can deduce the distance between the confluence and the apical foramen. **F.** Postoperative radiograph.

LOWER THIRD MOLAR

The lower third molar may require endodontic therapy for the same reasons as the upper third molar. When it is the last distal abutment, this tooth acquires great importance.

The most varied and bizarre root morphology can correspond to an almost normal coronal appearance (Figs. 11.141, 11.142).

Nonetheless, this tooth can also be treated successfully by endodontic means (Figs. 11.143, 11.144).

The same rules that apply to the other lower molars also hold for its access cavity.

Owing to the distal inclination of the roots, its treatment is often easier than one might think on a first look at the radiograph.

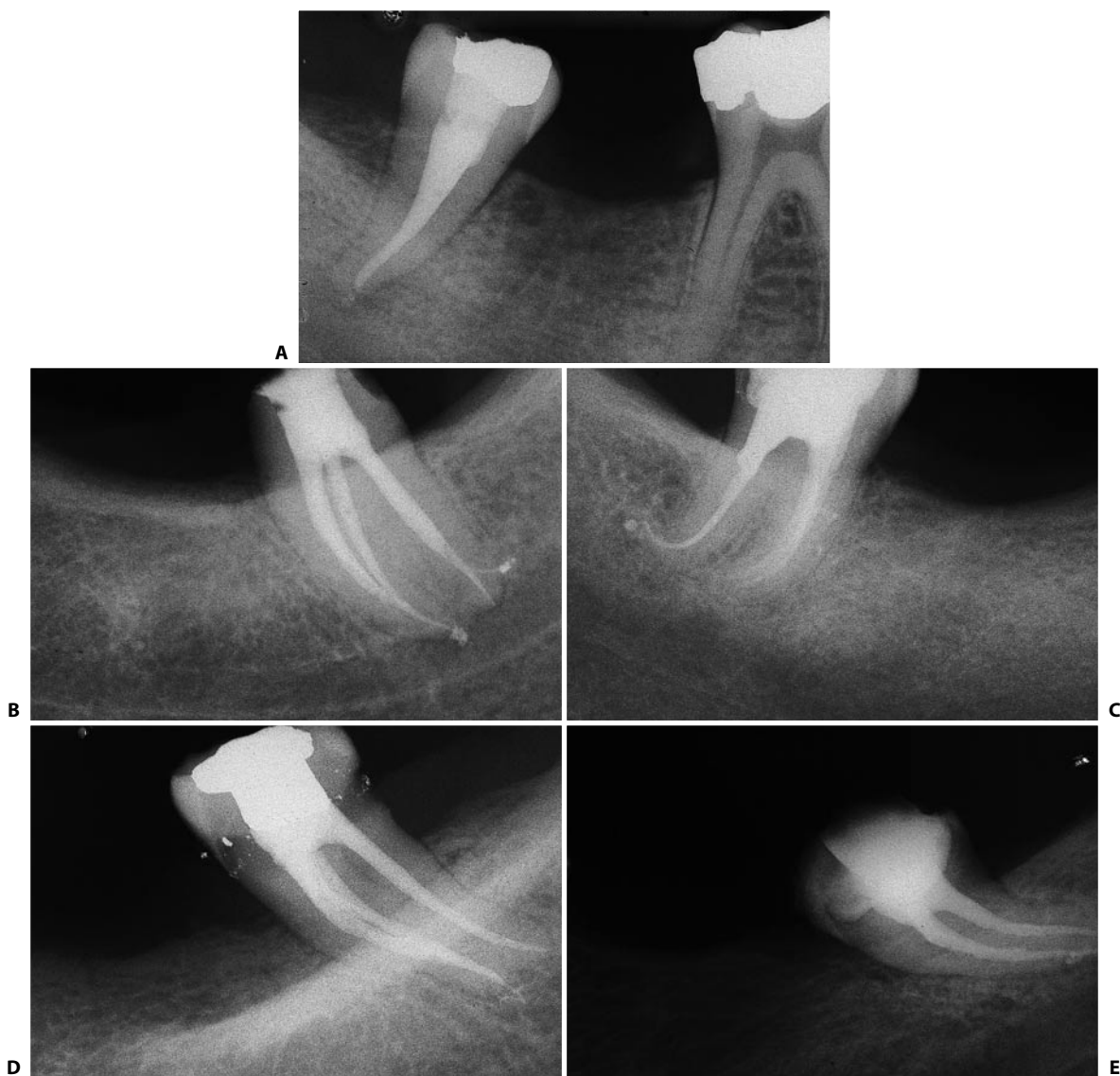


Fig. 11.141. **A-E.** Examples of the endodontic anatomy of lower third molars.

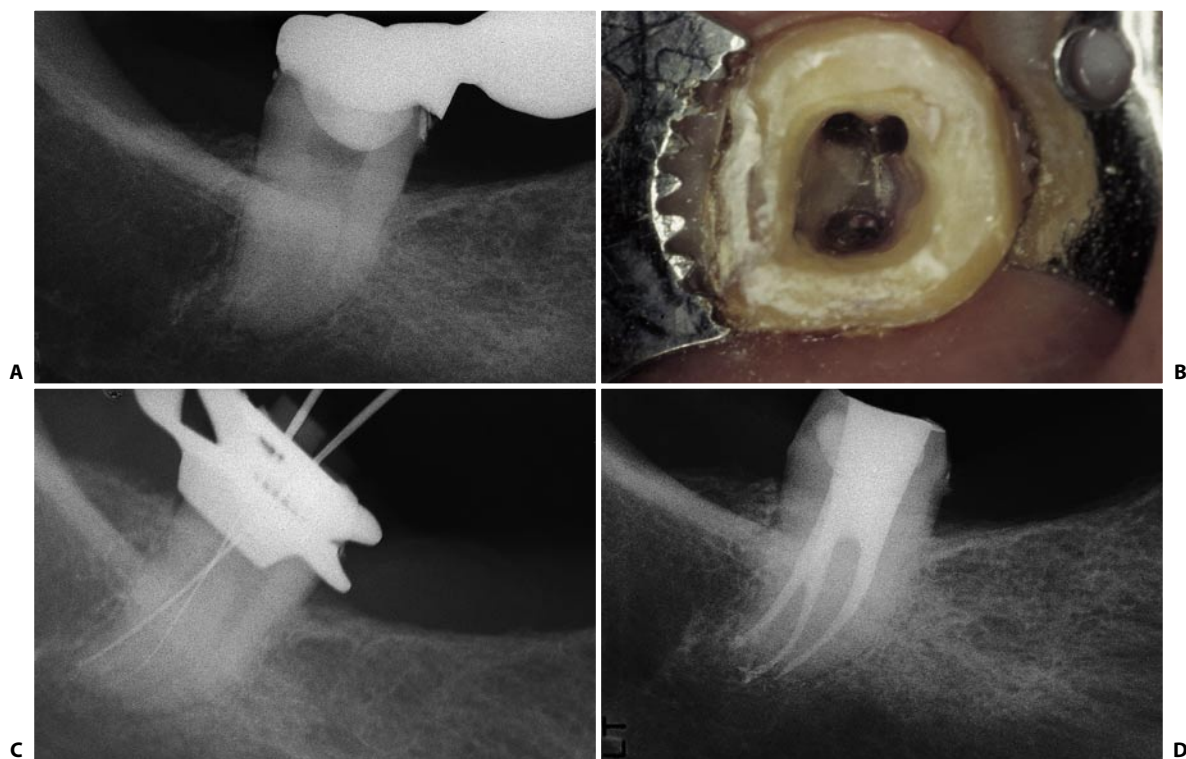


Fig. 11.142. A lower third molar with two distal canals and a single mesial canal. **A.** Preoperative radiograph. **B.** Access cavity. **C.** Intraoperative radiograph. **D.** Postoperative radiograph.

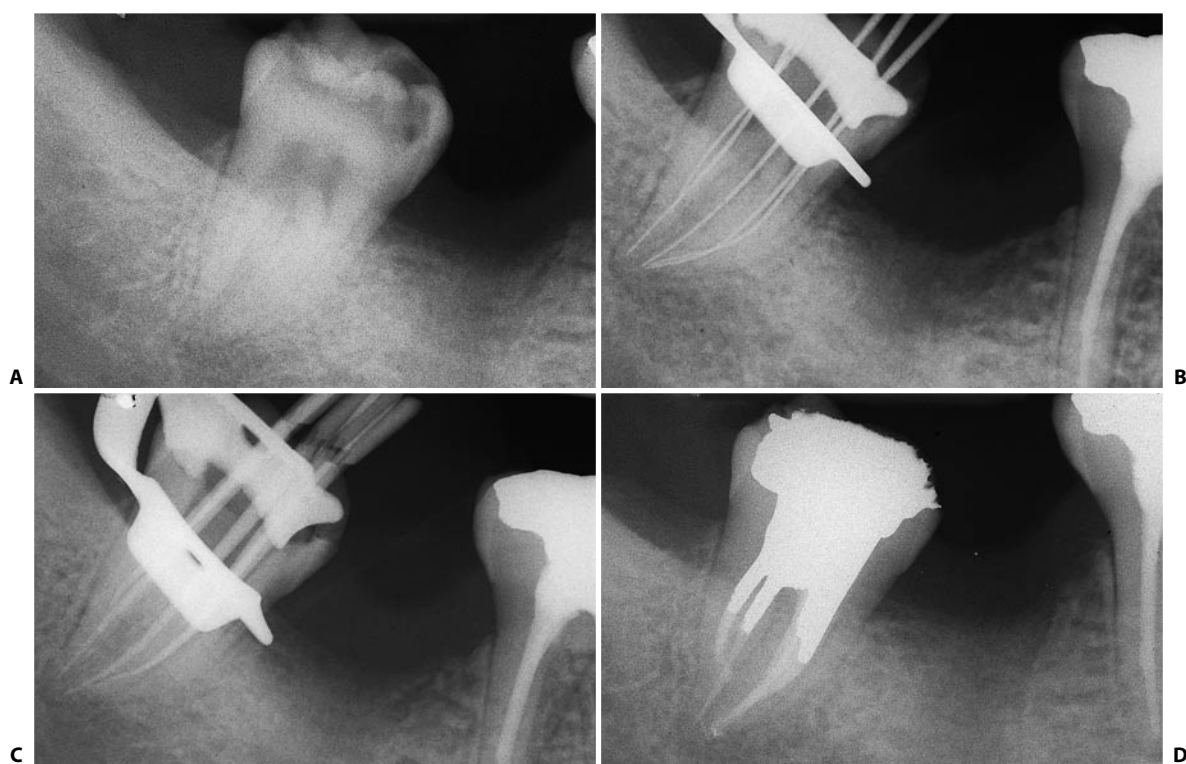


Fig. 11.143. A lower right third molar with five canals. **A.** Preoperative radiograph. **B.** Intraoperative radiograph: two canals are present in the distal and three in the mesial root. **C.** Cone fit. **D.** Postoperative radiograph.

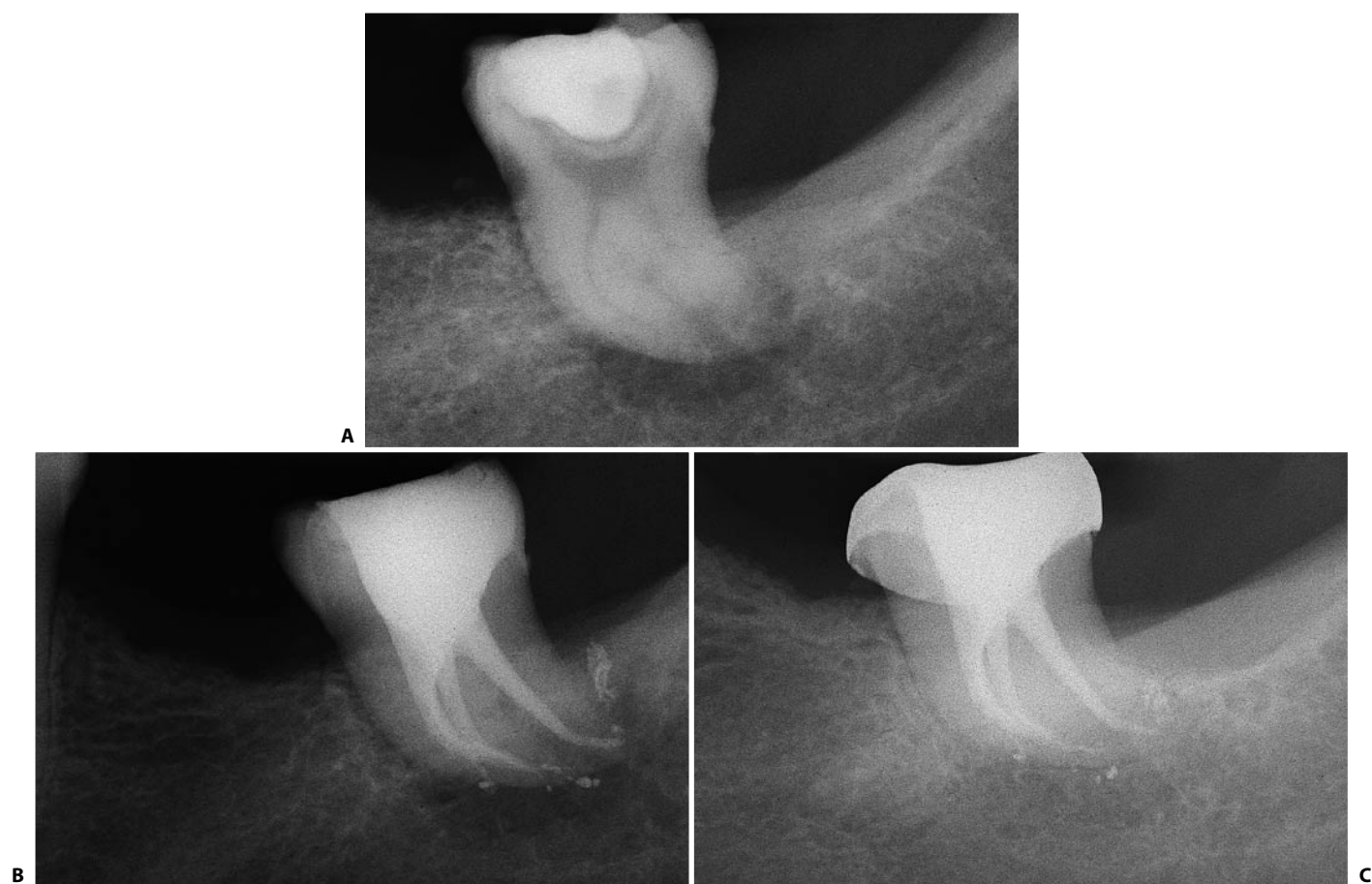


Fig. 11.144. Lower third molar with many lateral canals, responsible for the lesion mesial to the mesial root. **A.** Preoperative radiograph. **B.** Postoperative radiograph. **C.** The two year recall shows the complete healing.

THE ACCESS CAVITY IN PROSTHETICALLY PREPARED TEETH

When endodontic treatment is required for a tooth whose crown has been prosthetically prepared, the opening of the access cavity need not take into consideration the geometry of the prepared crown, but, as always, a straight-line access to the apical one third of the canal must be provided. Therefore, if possible, one must try to save the walls of the preparation by opening the tooth at the flattened tip of the cone (Fig. 11.145). However, if the surface of the dental crown has been removed asymmetrically with respect to the underlying pulp for the purposes of parallelism, in this case the access cavity will also have to involve one side of the preparation (Fig. 11.146) or even be performed entirely at the expense of this surface (Fig. 11.147).

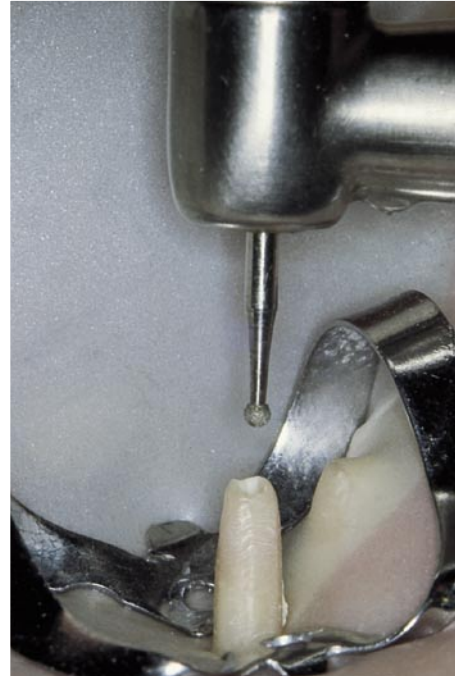


Fig. 11.145. The prosthetic preparation has been concentrically performed on the pulp chamber and canal; therefore, the access cavity may be created at the tip of the cone's trunk.

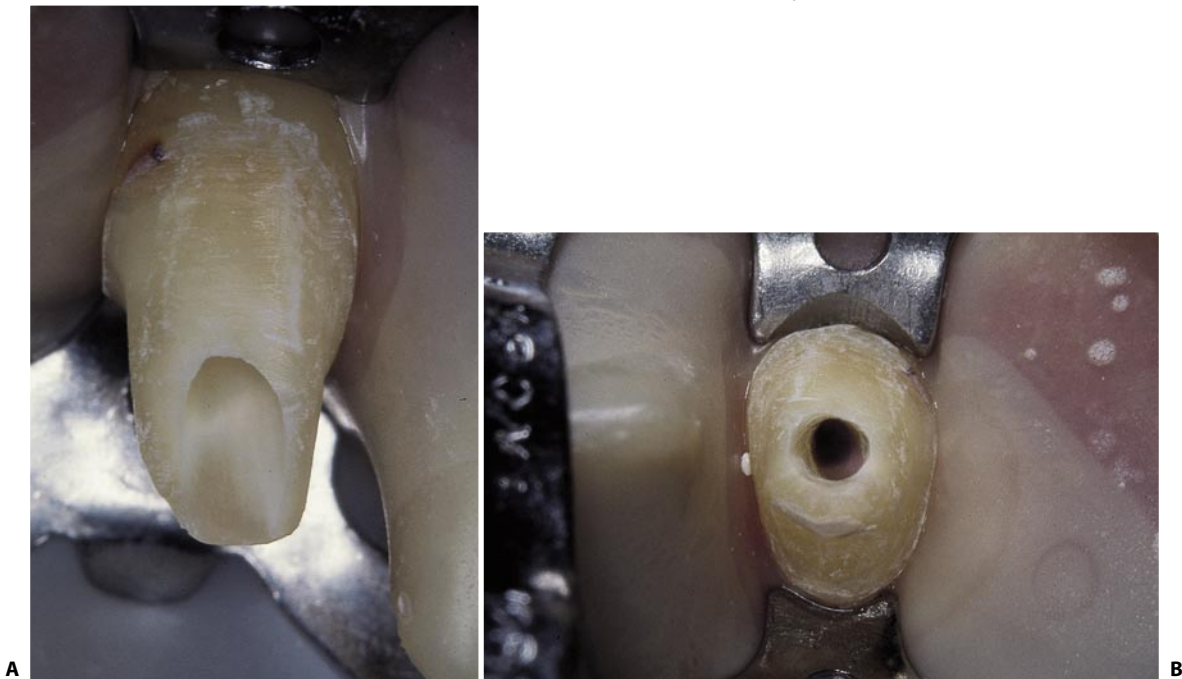


Fig. 11.146. **A.** The tooth has been prepared for the most part at the expense of the buccal portion for purposes of parallelism. Thus, the access cavity must also affect the buccal surface of the preparation. **B.** The same tooth photographed from the incisal side. The access cavity must always provide a straight-line access to the apical one third of the root canal.

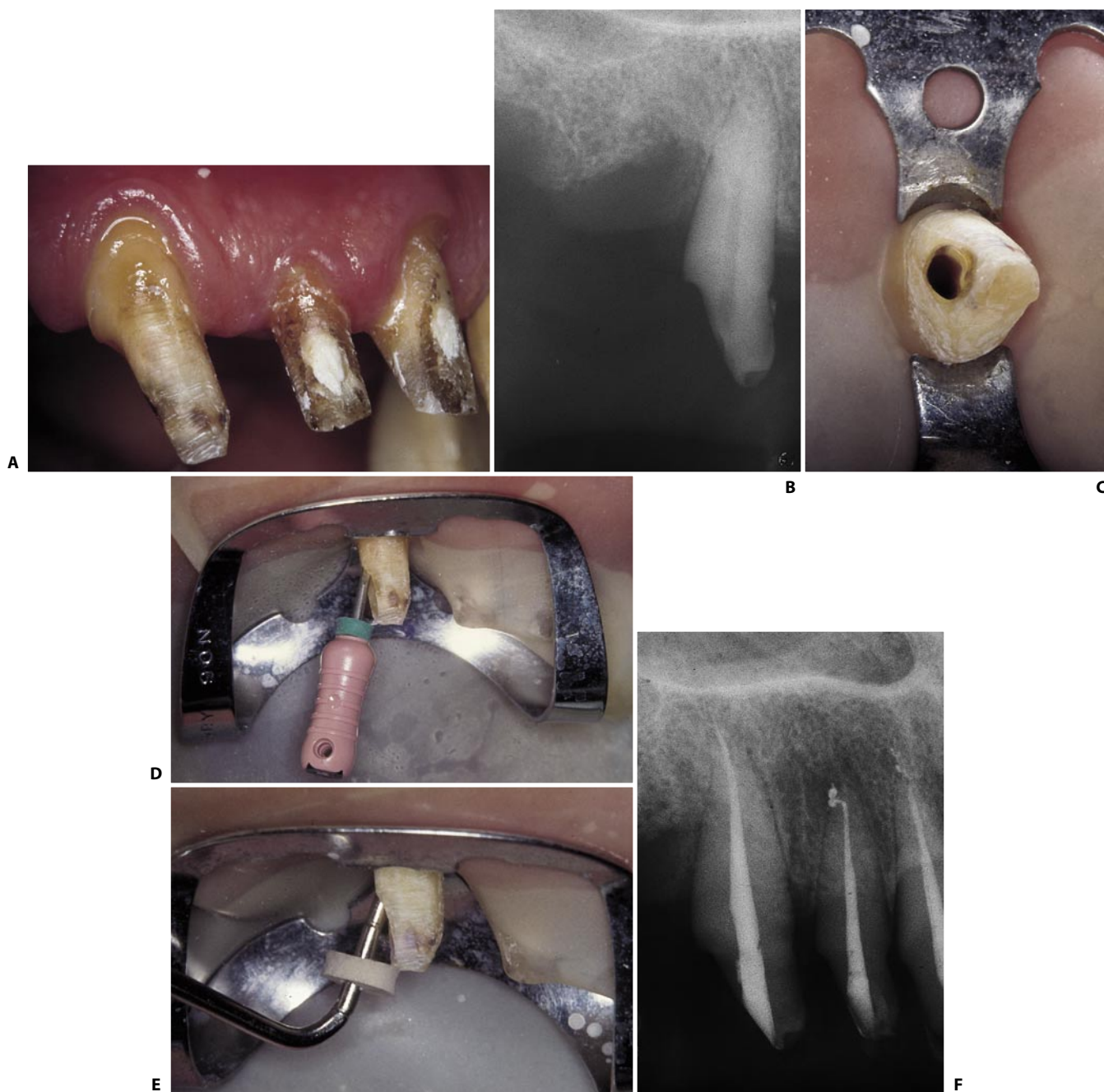


Fig. 11.147. **A.** The prosthetic preparation has particularly involved the distal aspect of this upper right canine, which mesially has been reduced by only a minimum amount. **B.** The preoperative radiograph confirms the asymmetry of the prosthetic preparation and indicates the site and inclination of the root canal with respect to the preparation. **C.** The access cavity has been entirely created at the level of the distal surface. **D.** Although the instruments take this apparently absurd inclination, they have straight-line access to the apical one third of the root canal. **E.** The access cavity must also allow easy introduction to materials and instruments used for obturation. **F.** Postoperative radiograph.

THE ACCESS CAVITY THROUGH PROSTHETIC CROWNS

In the case of a patient with a prosthetic crown, two situations arise, depending on whether the prosthetic crown must be kept in the patient's mouth or has to be replaced.

In the first circumstance, one must create a more conservative access cavity, though one must recall that if it is necessary to extend it for the purpose of improved visibility, this should be done without any regret. The crown can always be re-made, while a mistake in the cleaning and shaping procedure of the root canals cannot be corrected.

In the case in which the crown must, for some reason, be substituted after therapy, it is always preferable, for the stability of the rubber dam clamp, as well as esthetics and function, to perform the endodontic treatment through the prosthesis, which can be removed and substituted once the therapy has been completed.

Obviously, the access cavity should be as wide as possible to permit easier orientation through the pro-

sthesis, which can conceal or, in any case, mask, the tooth's true position in the arch.

It is therefore advisable to remove as much as possible, if not indeed completely, the occlusal surface of the metal crown, thus transforming the crown into a "band" before sinking the bur in search of the pulp chamber and canal openings.

In the case of a gold-porcelain crown, one can use the head of a large, round diamond bur (Fig. 11.148 A) to remove the esthetic surface until a large part of the underlying metal has been uncovered (Fig. 11.148 B). Then, with a tungsten fissure bur (Fig. 11.148 C), a groove is cut at the periphery of the metal surface (Fig. 11.148 D), and the diskette thus obtained is removed (Fig. 11.148 E). Once the thin layer of underlying oxyphosphate has been removed, it will be possible to see whether any old amalgam or composite restoration has been left. In such cases, the access cavity will have to be initiated at the expense of these materials, whose gradual removal permits even better orientation.

One then begins carefully to drill into the dentin, di-

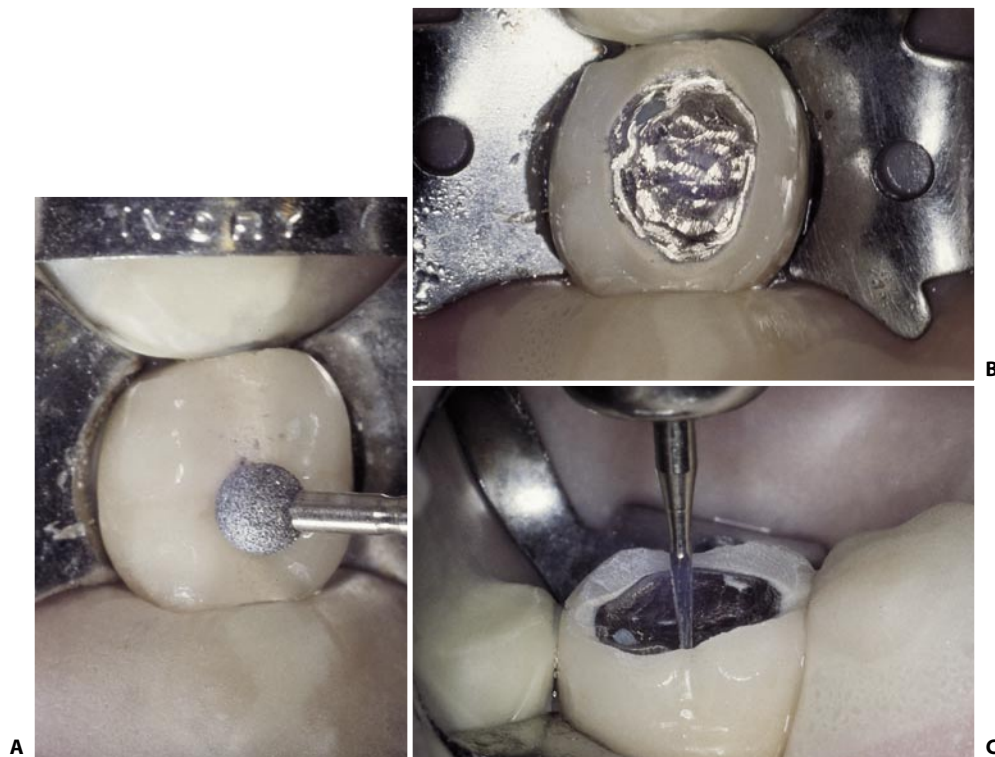

Fig. 11.148. An access cavity in a molar covered by a gold-porcelain crown requiring endodontic retreatment. **A.** Using a large, round diamond bur, the porcelain is removed. **B.** The underlying metal has been exposed. **C.** With a fissure bur, a groove is incised at the periphery of the metal (continued).

recting the bur toward the horn that one suspects is closest to the dentist.

If the tooth has already been treated endodontically (Fig. 11.148 F), the use of ultrasonics may help remove the old endodontic filling material from the pulp chamber (Fig. 11.148 G) to permit a clearer, more complete view of the floor of the pulp chamber (Figs. 11.148 H, I).

The access cavity dug in the dentin may be smaller than the opening created in the metal of the crown.

However, it is not the dentist who decides its extent, but as usual, the anatomy of the underlying pulp chamber.

Having prepared a generous opening in the metal of the prosthesis has another advantage: in the case in which, intraoperatively, an extension of the aperture of the access cavity becomes necessary, one will not run the risk of pushing metallic filings into the canals (Fig. 11.8).

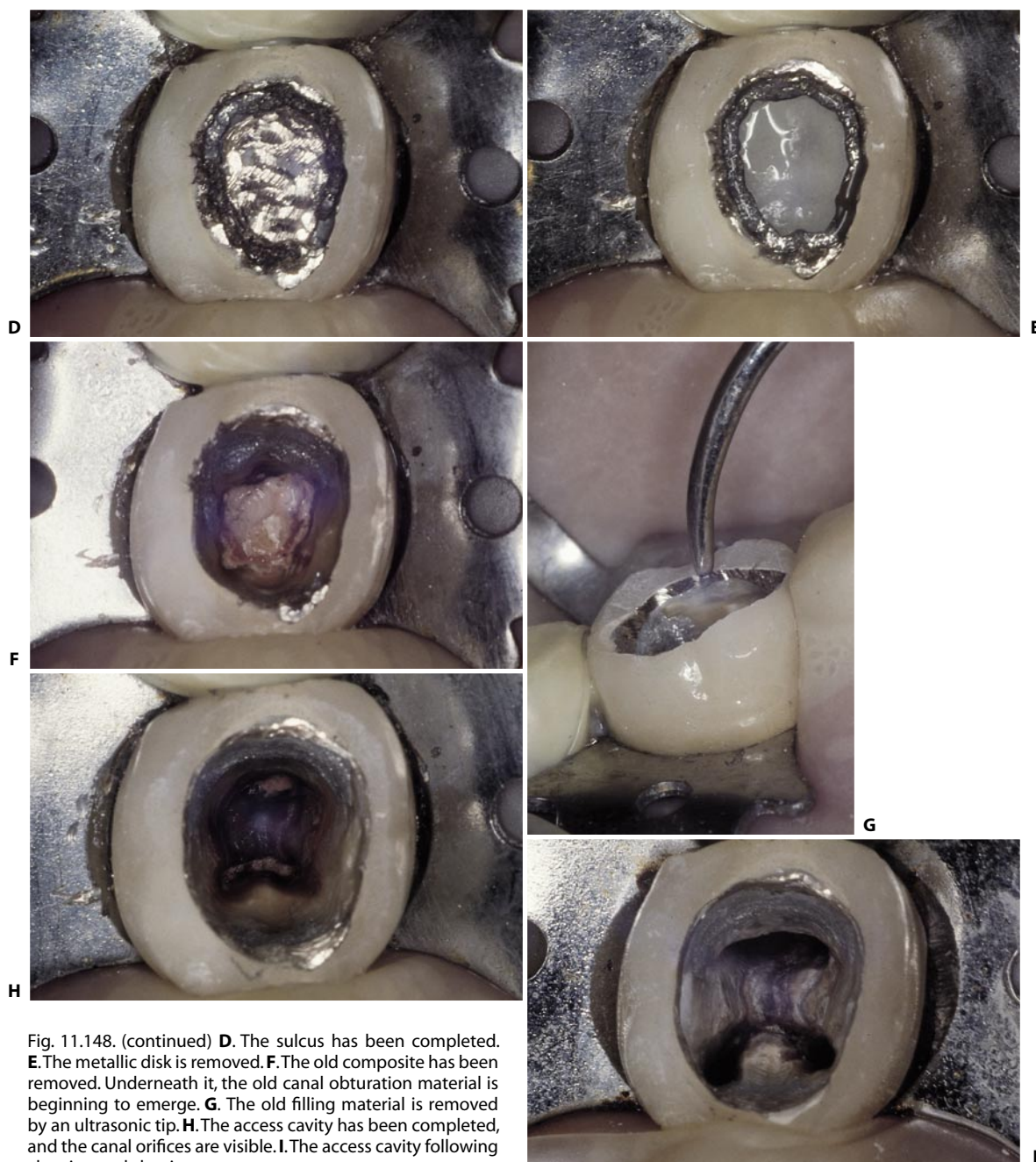


Fig. 11.148. (continued) **D**. The sulcus has been completed. **E**. The metallic disk is removed. **F**. The old composite has been removed. Underneath it, the old canal obturation material is beginning to emerge. **G**. The old filling material is removed by an ultrasonic tip. **H**. The access cavity has been completed, and the canal orifices are visible. **I**. The access cavity following cleaning and shaping.

COMMON ERRORS IN THE PREPARATION OF THE ACCESS CAVITY

Errors Related to Inadequate Preparation

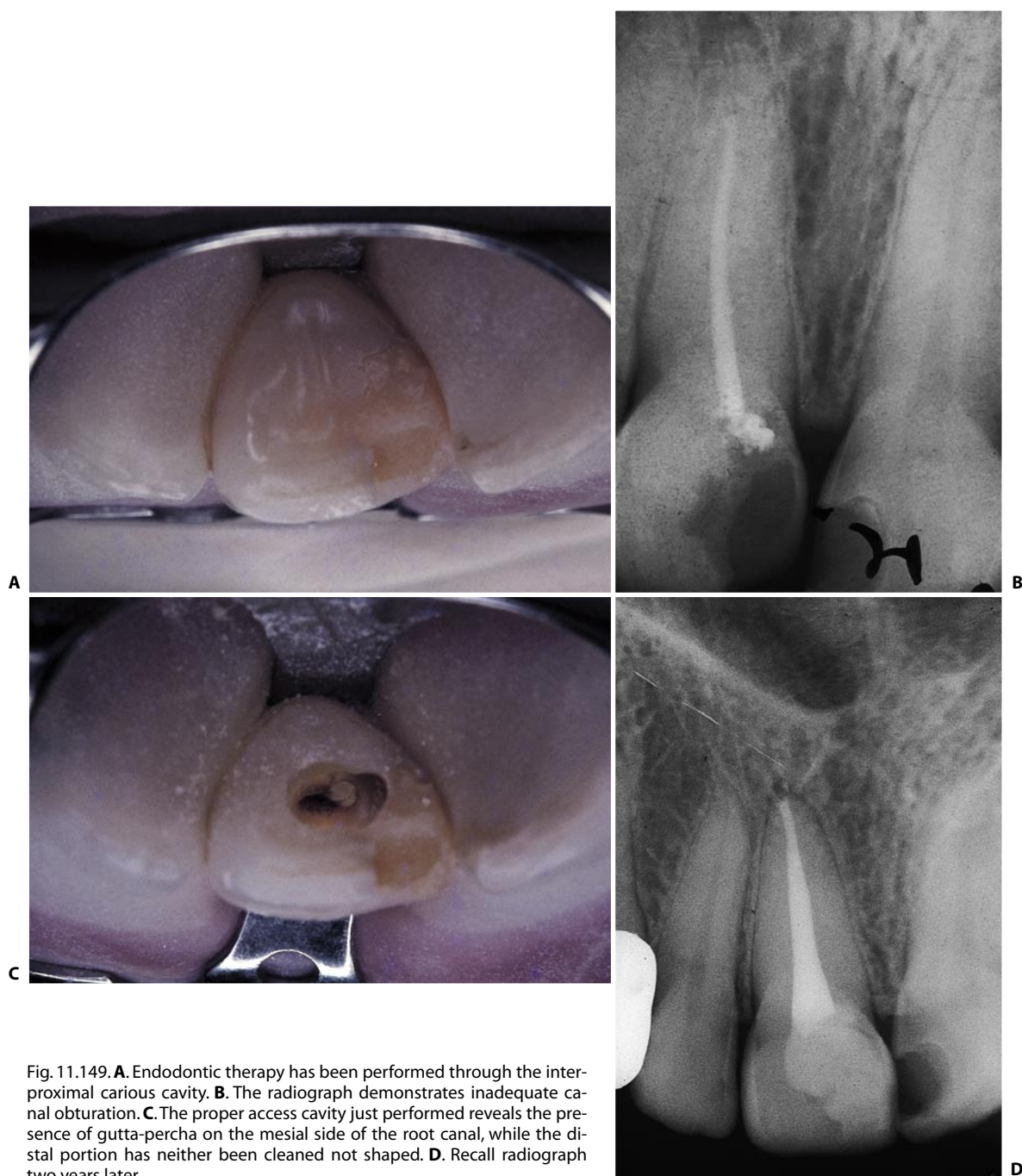


Fig. 11.149. **A.** Endodontic therapy has been performed through the interproximal carious cavity. **B.** The radiograph demonstrates inadequate canal obturation. **C.** The proper access cavity just performed reveals the presence of gutta-percha on the mesial side of the root canal, while the distal portion has neither been cleaned nor shaped. **D.** Recall radiograph two years later.

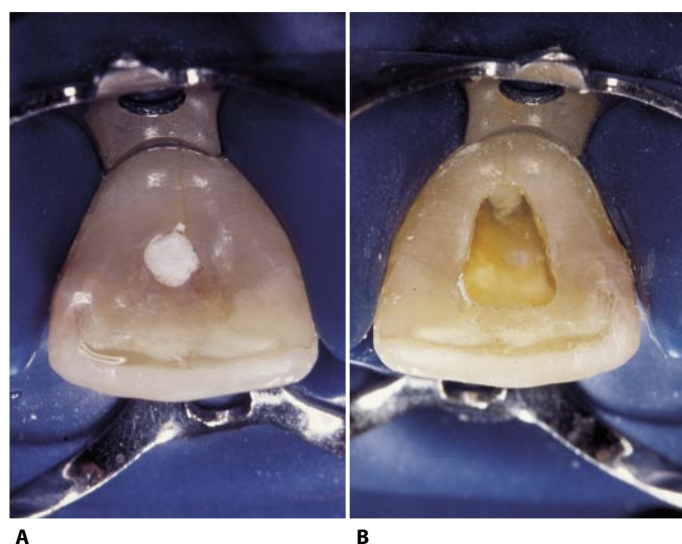


Fig. 11.150. **A.** Inadequate access cavity in an upper central incisor. **B.** Same tooth with a proper access cavity.

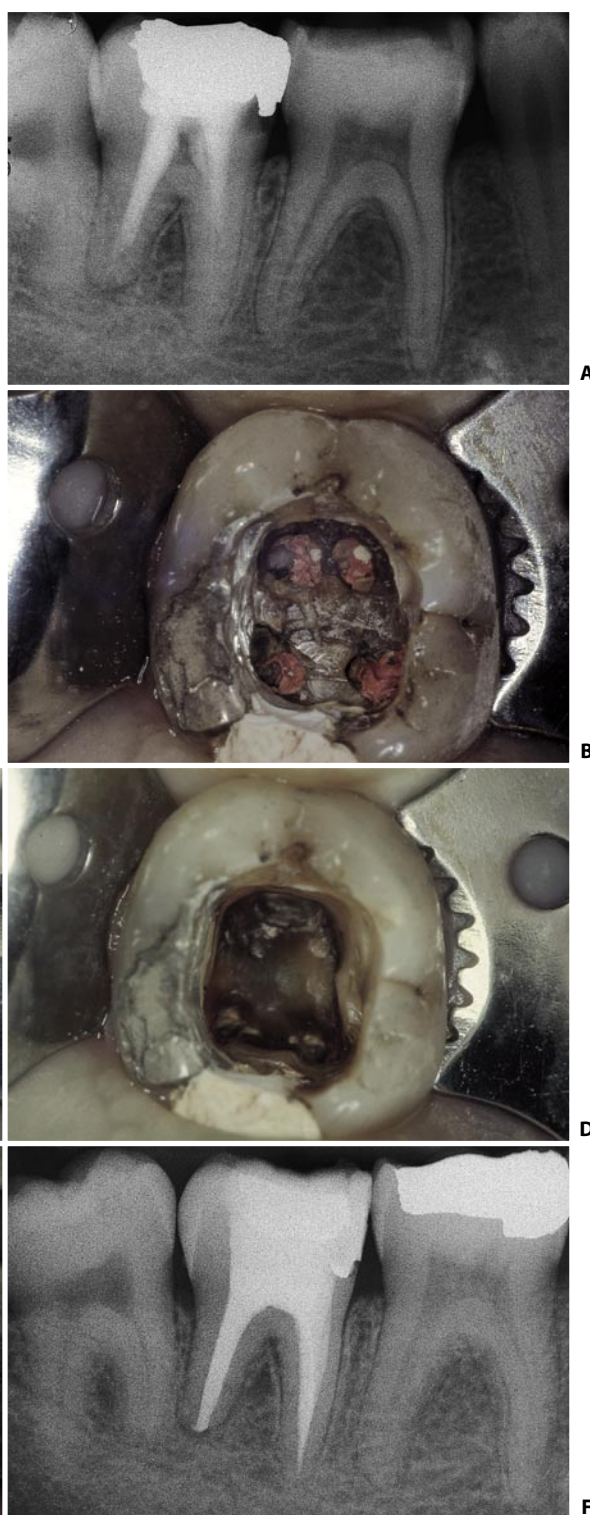


Fig. 11.151. **A.** Preoperative radiograph. The relatively radiolucent space between the base of the canal obturation and the pulp chamber raises the suspicion of the presence of a residuum of the pulp chamber roof. **B.** The previous endodontic therapy had been performed through four small holes made in the roof of the pulp chamber. The four pulp horn were interpreted as canal orifices. **C.** Once the obturating material has been removed with the help of ultrasonics, the chamber roof left in place is better visualized. **D.** The access cavity has been corrected with the complete removal of the roof of the pulp chamber. **E.** The same access cavity after preparation of the root canals. **F.** Post-operative radiograph.

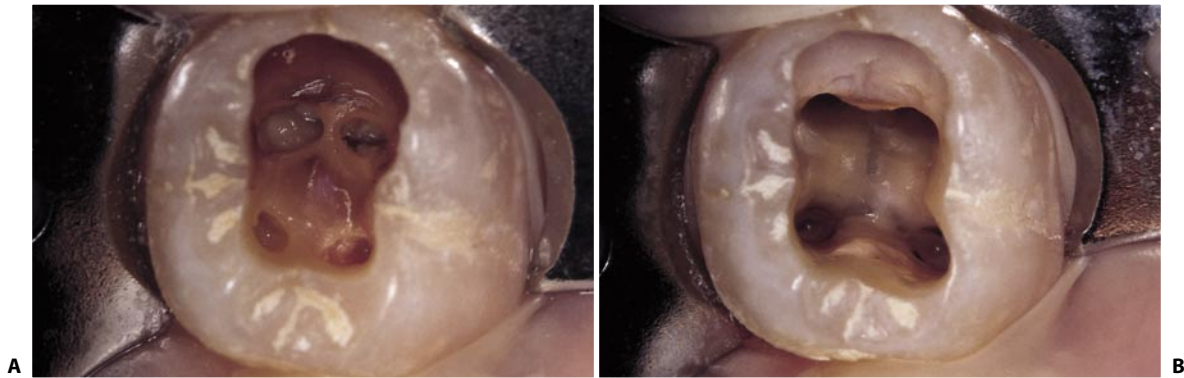


Fig. 11.152. **A.** The same error as that in the preceding figure has been committed: the tooth had been opened to establish a drainage, but part of the roof of the pulp chamber was left. **B.** The access cavity has been corrected, and the canals have been prepared.

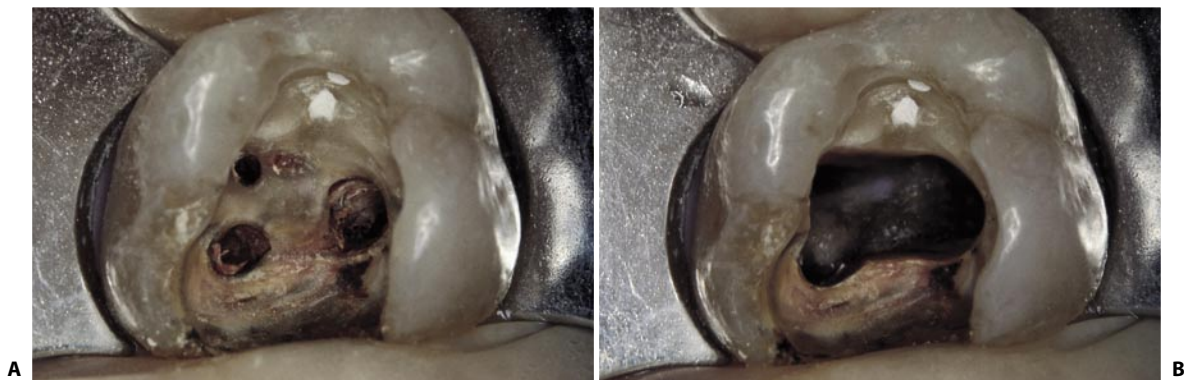


Fig. 11.153. **A.** The same error has been committed in an upper first molar. **B.** The access cavity as it appeared after complete removal of the chamber roof.

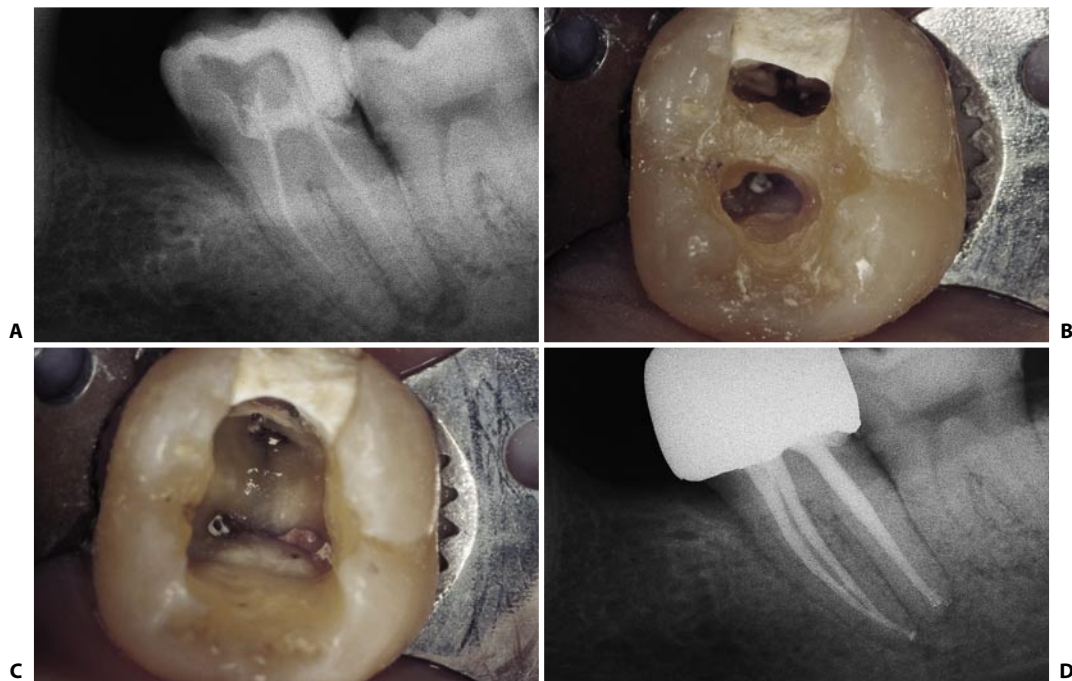

Fig. 11.154. **A.** Preoperative radiograph of the lower left second molar which necessitates retreatment. **B.** After the removal of the old composite filling, the access cavity made by the previous dentist is evident. **C.** The residual roof has been removed. **D.** One year recall.

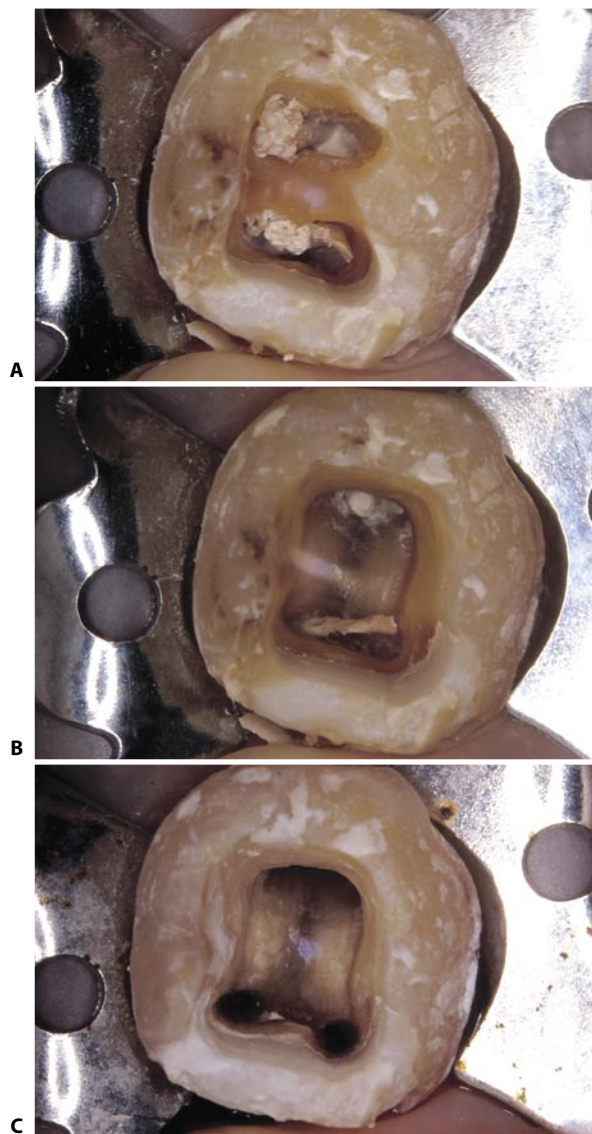


Fig. 11.155. **A.** Part of the roof of the pulp chamber is still in place. **B.** The roof has been removed. **C.** Access cavity after cleaning and shaping the root canals.

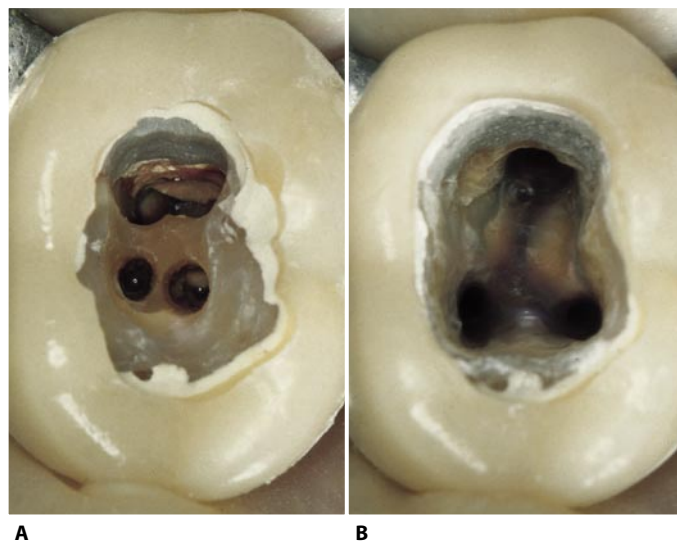


Fig. 11.156. **A.** The previous dentist forgot to remove part of the pulp chamber roof. **B.** Now the root canals are ready for packing.

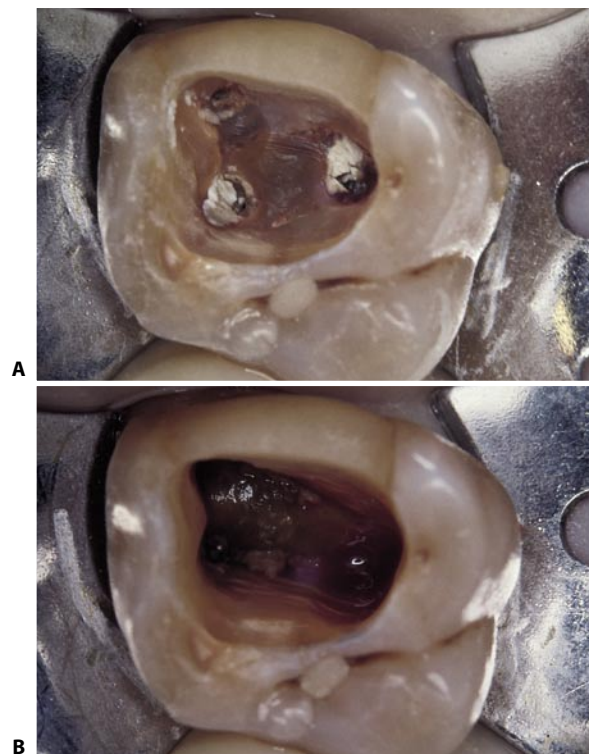


Fig. 11.157. **A.** The root canal treatment of this upper first molar has been made through three holes made in the pulp chamber roof. **B.** The bleeding from the palatal canal is caused by some remaining vital pulp tissue!

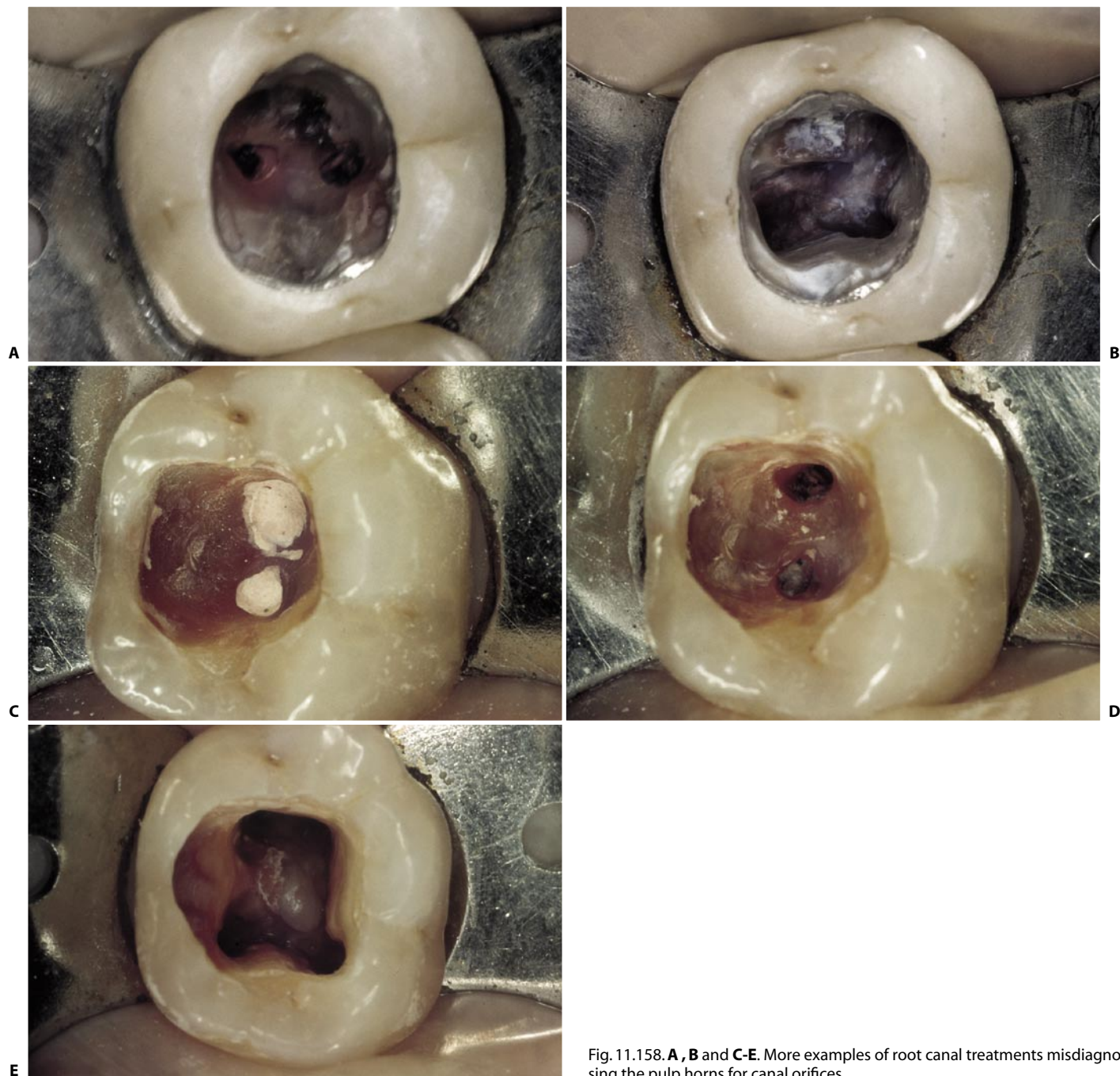


Fig. 11.158. **A, B** and **C-E**. More examples of root canal treatments misdiagnosing the pulp horns for canal orifices.

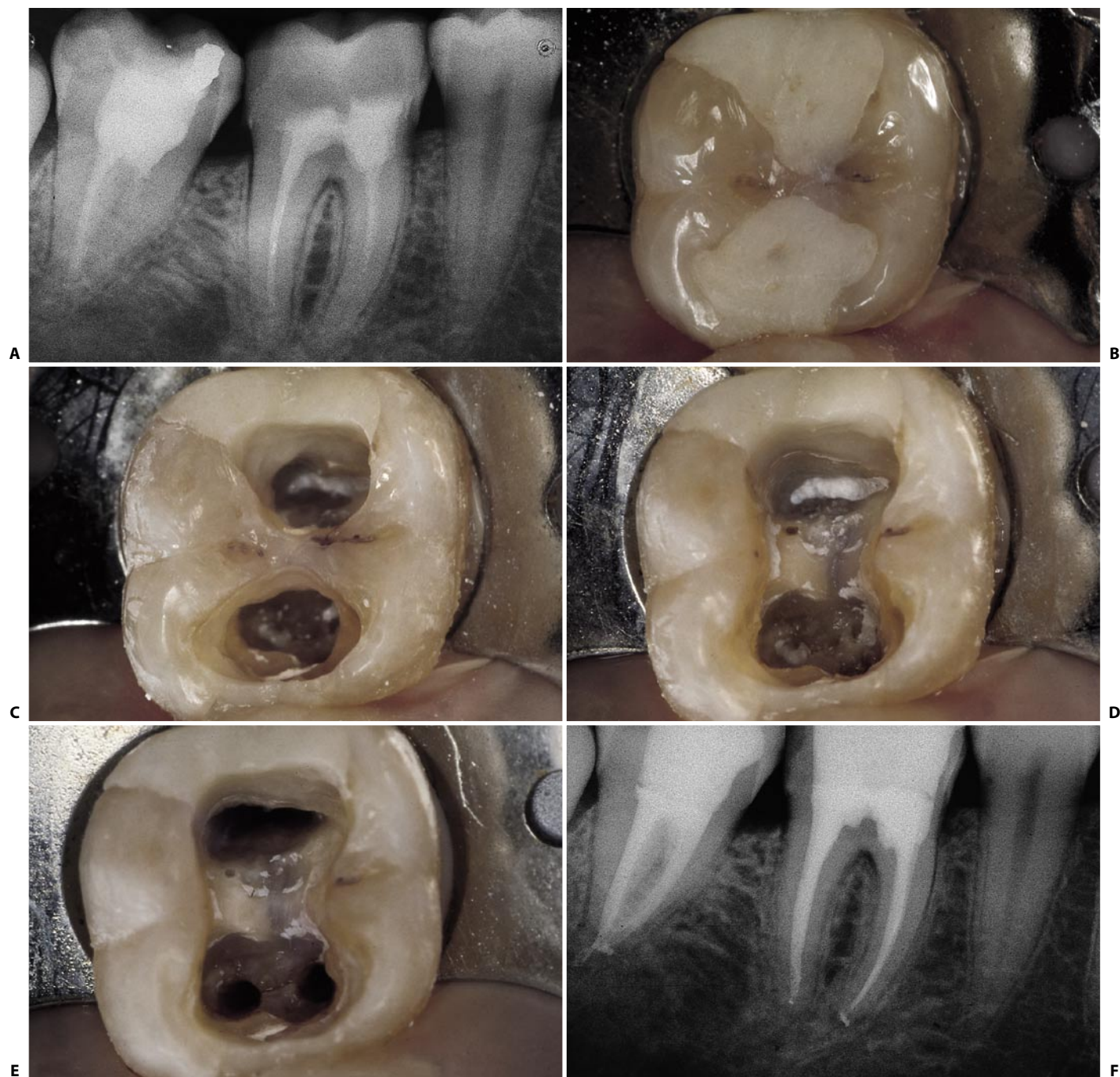


Fig. 11.159. **A.** This radiograph demonstrates a lower right first molar treated endodontically, with the occlusal surface apparently intact. **B.** The occlusal surface reveals the presence of two composite obturations, one mesial and one distal, separated by an enamel bridge. **C.** Careful removal of the composite reveals the bridge of enamel and dentin: the tooth has been treated endodontically through two distinct access cavities, one mesial for the two mesial root canals, the other distal for the distal root canal! **D.** The bridge has been chipped away, so as to allow visualization of the pulp chamber floor. **E.** Access cavity with cleaned and shaped root canals. **F.** Postoperative radiograph.

Errors Related to Over-Aggressive Preparation

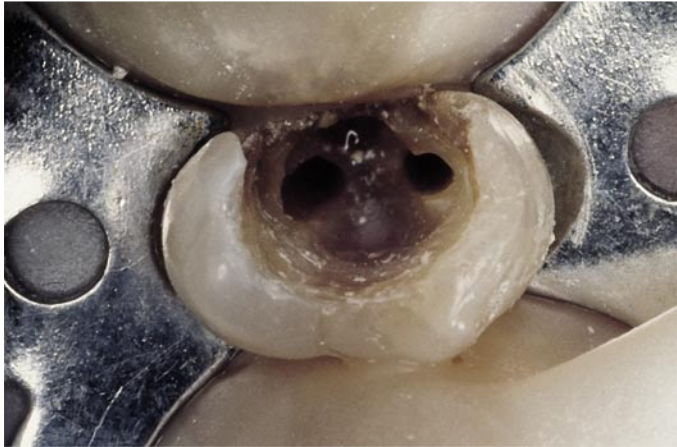


Fig. 11.160. Two perforations are visible, one mesial and one distal, caused by a fruitless search for the canal orifices, in this upper right first premolar.

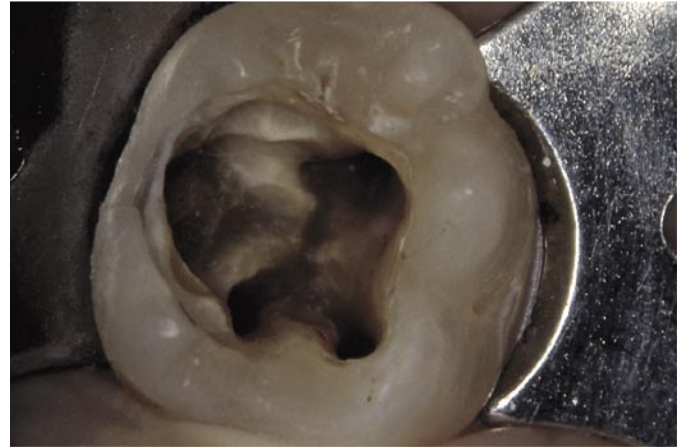
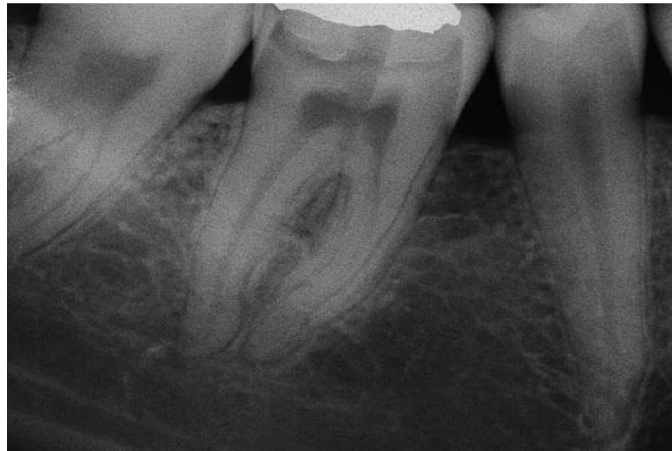
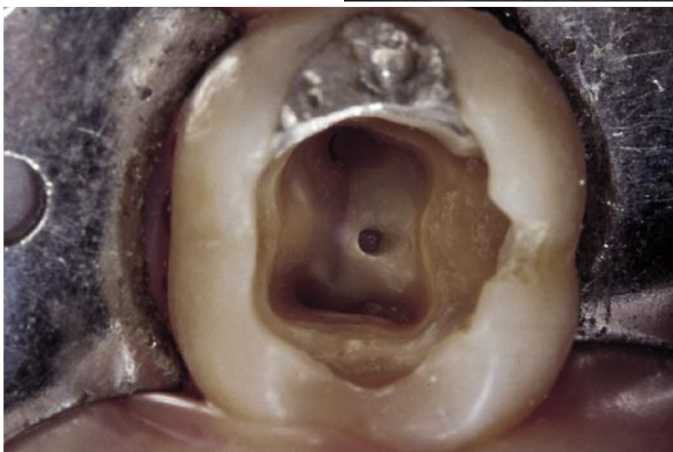
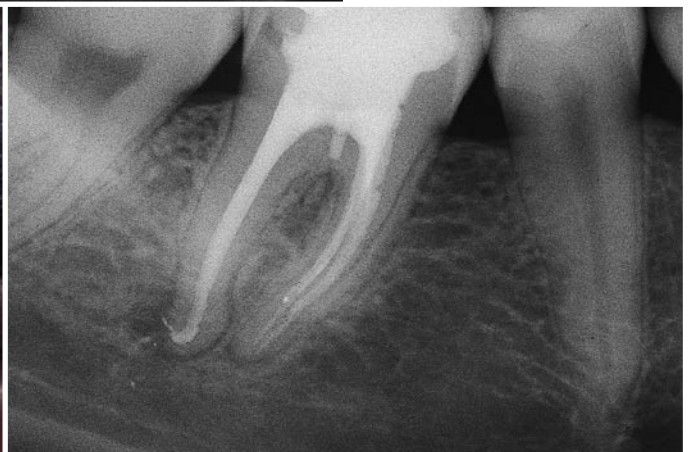Fig. 11.161. A lower left first molar. A too-limited access cavity had concealed the mesiobuccal canal. The mesiolingual canal had been taken to be the mesiobuccal, and the cut of the bur visible lingually had been created in the futile search for the orifice of the mesiolingual canal in the wrong place.



A



B



C

Fig. 11.162. **A.** Preoperative radiograph of a lower right first molar. The tooth had been "opened" with a conical bur, which has left an easily visible impression as far as the floor of the pulp chamber. **B.** Proper access cavity. **C.** Postoperative radiograph. Obturation of the small perforation created in the thickness of the chamber floor is visible.

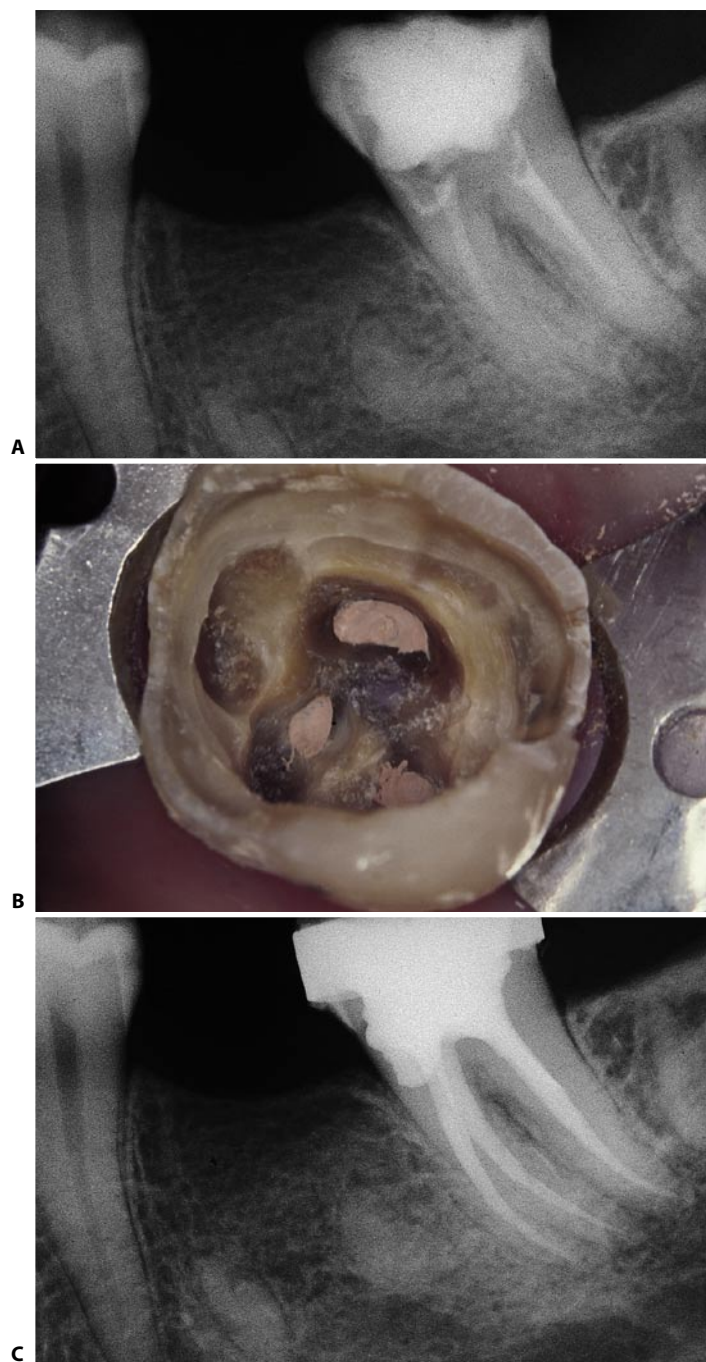


Fig. 11.163. A lower left second molar with an endodontic anatomy of the type illustrated in Fig. 11.124. **A.** Preoperative radiograph: note the bur cuts created in the search for the lingual canal. **B.** Access cavity at completion of obturation: the mesiolingual canal is distally displaced. The signs of a desperate search for the mesiolingual canal are visible. **C.** Postoperative radiograph.

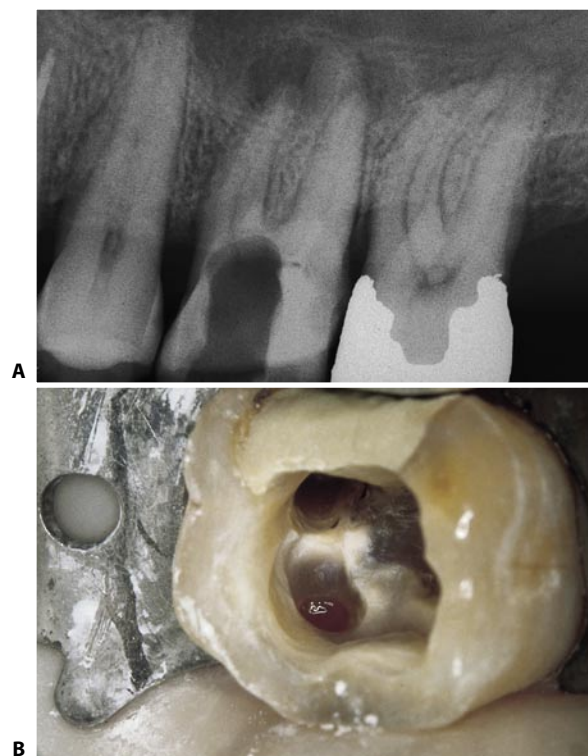


Fig. 11.164. **A.** The access cavity has been made too mesially. **B.** Perforation of the floor at the orifice of the mesiobuccal canal is evident.

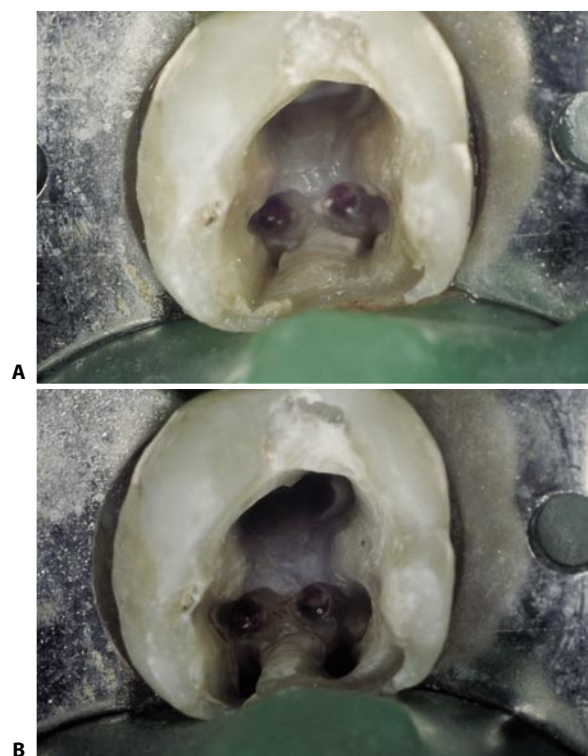


Fig. 11.165. **A.** In this lower left first molar, two perforations of the floor have been made in the attempt to find the orifices of the mesial canals, which are spotted on the mesial wall of the access cavity. **B.** The mesial canals have been prepared.

BIBLIOGRAPHY

- 1 ABOU-RASS, M., FRANK, A.L., GLICK, D.H.: The anticurvature filing method to prepare the curved root canal. *J. Am. Dent. Assoc.* 101:792, 1980.
- 2 ACOSTA VIGOUROUX, S.A., TRUGEDA BOSAAANS, S.A.: Anatomy of the pulp chamber floor of the permanent maxillary first molar. *J. Endod.* 4:214, 1978.
- 3 ARDINES, P.L.: Endodoncia. 1. El Acceso. Editorial Odontolibros. Mexico D.F. 1985, p. 126.
- 4 AYDOS, J.H., MILANO, N.F.: Morfologia interna o raiz mesio-vestibular primerio molar superior permanente. *Rev. Gaucha Odontol.* 21:10, 1973.
- 5 BAISDEN, M.K., KULILD, J.C., WELLER, R.N.: Root canal configuration of the mandibular first premolar. *J. Endod.* 18:505, 1992.
- 6 BARDELLI, M., BRUNO, E., ROSSI, G.: Considerazioni sull'anatomia del canale radicolare degli incisivi inferiori. *G. It. Endo.* 4:34, 1990.
- 7 BARNETT, F.: Mandibular molar with C-shaped canal. *Endod. Dent. Traumatol.* 2:79, 1986.
- 8 BEATTY, R.G.: A five-canal maxillary first molar. *J. Endod.* 10:156, 1984.
- 9 BEATTY, R.G., KRELL, K.: Mandibular molars with five canals: report of two cases. *J. Am. Dent. Assoc.* 114:802, 1987.
- 10 BELLIZZI, R., HARTWELL, G.: Evaluating the maxillary premolar with three canals for endodontic therapy. *J. Endod.* 7:521, 1981.
- 11 BENJAMIN, K.A., DOWSON, J.: Incidence of two root canal in human mandibular incisor teeth. *Oral Surg.* 38:122, 1974.
- 12 BERUTTI, E., FEDON, G.: Thickness of cementum/dentin in mesial roots of mandibular first molars. *J. Endod.* 18:545, 1992.
- 13 BOLGER, W.L., SCHINDLER, W.G.: A mandibular first molar with a C-shaped root configuration. *J. Endod.* 14:515, 1988.
- 14 BOND, J.L., HARTWELL, G.R., DONNELLY, J.C., PORTELL, F.R.: Clinical management of middle mesial root canals in mandibular molars. *J. Endod.* 14:312, 1988.
- 15 BOND, J.L., HARTWELL, G.R., PORTELL, F.R.: Maxillary first molar with six canals. *J. Endod.* 14:258, 1988.
- 16 BONE, J., MOULE, A.J.: The nature of curvature of palatal canals in maxillary molar teeth. *Int. Endod. J.* 19:178, 1986.
- 17 BURNS, R.C.: Access openings and tooth morphology. In Cohen S., Burns R.C. eds.: *Pathways of the pulp*, 3rd ed., The C.V. Mosby Company, 1984, pp. 118-174.
- 18 BURNS, R.C.: Access openings and tooth morphology. In Cohen S., Burns R.C. eds.: *Pathways of the pulp*, 4th ed., The C.V. Mosby Company, 1987, p. 124.
- 19 CARNS, E.J., SKIDMORE, A.E.: Configurations and deviations of root canals of maxillary first premolars. *Oral Surg.* 36:880, 1973.
- 20 CASTAGNOLA, M., TESTORI, T., BADINO, M.: La cavità d'accesso nel trattamento endodontico dei denti frontali. *G. It. Endo.* 5:15, 1991.
- 21 CASTELLUCCI, A.: La cavità d'accesso. *Seconde Giornate Odontoiatriche Liguri. Comunicazione personale.* Genova Aprile 1983.
- 22 CASTELLUCCI, A.: Two canals in a single root: clinical and practical considerations. *Endod. Practice*, 4(1): 17, 2001.
- 23 CASTELLUCCI, A., BECCIANI, R., BERTELLI, E.: Variabilità anatomica di molari inferiori. Canali a sorpresa. *Attualità Dentale* 11:10, 1986.
- 24 CASTELLUCCI, A., BECCIANI, R., BERTELLI, E.: L'anatomia endodontica degli incisivi inferiori. *Indagini radiografiche ed indirizzi terapeutici.* *Min. Stom.* 37:159, 1988.
- 25 CASTELLUCCI, A., BECCIANI, R., PATRONI, S., BERTELLI, E.: L'anatomia dei primi e secondi molari inferiori: considerazioni cliniche e chirurgiche. *Atti del XXI Congresso Nazionale S.I.O.C.M.F. Monduzzi ed.* Firenze, 1987, p. 1287.
- 26 CHRISTIE, W.H., PEIKOFF, M.D., FOGEL, H.M.: Maxillary molars with two palatal roots: a retrospective clinical study. *J. Endod.* 17:80, 1991.
- 27 COOK, H.G., COX, F.L.: C-shaped canal configurations in mandibular molars. *J. Am. Dent. Assoc.* 99:836, 1979.
- 28 DE FAZIO, P., PETRECCA, S., ESPOSITO, P., PETRELLI, I.: Metodiche di apertura della camera pulpare. *G. It. Endo.* 4:6, 1990.
- 29 DeGROOD, M.E., CUNNINGHAM, C.J.: Mandibular molar with 5 canals: report of a case. *J. Endod.* 23:60, 1997.
- 30 DEVEAUX, E.: Maxillary second molar with two palatal roots. *J. Endod.* 25:571, 1999.
- 31 DIAMOND, M.: *Dental Anatomy including anatomy of the head and neck*, ed. 3. New York, MacMillan and Co., 1952.
- 32 ELDEEB, M.E.: Three root canals in mandibular second premolars: literature review and a case report. *J. Endod.* 8:376, 1982.
- 33 FABIO, M.A.: Root canal morphology of the mandibular second premolars. Boston University, 1980, Thesis.
- 34 FABRA CAMPOS, H.: Tres conductos en la raiz distal de dos primeros molares inferiores. *Rev. Esp. Endodoncia* II, 1:7, 1984.
- 35 FABRA CAMPOS, H.: Unusual root canal anatomy of mandibular first molars. *J. Endod.* 11:568, 1985.
- 36 FABRA CAMPOS, H.: Three canals in the mesial root of mandibular first permanent molars: a clinical study. *Int. Endod. J.* 22:39, 1989.
- 37 FAVA, L.R., WEINFELD, I., FABRI, F.P., PAIS, C.R.: Four second molars with single roots and single canals in the same patient. *Int. Endod. J.* 33:138, 2000.
- 38 FOGEL, H.M., PEIKOFF, M.D., CHRISTIE, W.H.: Canal configuration in the mesiobuccal root of the maxillary first molar: a clinical study. *J. Endod.* 20:135, 1994.

- 39 FRANCHI, M., MONTANARI, G., EVANGELISTI, A., RUGGERI, A.: La corretta cavità d'accesso nel trattamento endodontico. *Minerva Stomatologica* 35:953, 1966.
- 40 FRANK, A.L., SIMON, J.H.S., ABOU-RASS, M., GLICK, H.D.: Clinical and surgical endodontics. Concepts in practice. J.B. Lippincot, Philadelphia, 1983, pp. 51-84.
- 41 FRIEDMAN, S., MOSHONOV, J., STABHOLZ, A.: Five root canals in a mandibular first molar. *Endod. Dent. Traumatol.* 2: 226, 1986.
- 42 GILLES, J., READER, A.: A SEM investigation of the mesiolingual canal in human maxillary first and second molars. *Oral Surg.* 70:638, 1990.
- 43 GOSWAMI, M., CHANDRA, S., CHANDRA, S., SINGH, S.: Mandibular premolars with two roots. *J. Endod.* 23:187, 1997
- 44 GREEN, D.: Double canals in single roots. *Oral Surg.* 35:689, 1973.
- 45 HADDA, G.Y., NEHME, W.B., OUNSI, H.F.: Diagnosis, classification, and frequency of C-shaped canals in mandibular second molars in the Lebanese population. *J. Endod.* 25:268, 1999.
- 46 HARRIS, W.E.: Unusual root canal anatomy in a maxillary molar. *J. Endod.* 6:573, 1980.
- 47 HARTWELL, G., BELLIZZI, R.: Clinical investigation of in vivo endodontically treated mandibular and maxillary molars. *J. Endod.* 8:555, 1982.
- 48 HESS, W.: The anatomy of the root canals of the teeth of the permanent dentition. John Bale Sons and Danielsen, London, 1925.
- 49 HOLTZMANN, L.: Root canal treatment of a mandibular first molar with three mesial root canals. *Int. Endod. J.* 30:422, 1997.
- 50 HULSMANN, M.: Mandibular first premolar with three root canals. *Endod. Dent. Traumatol.* 6:189, 1990.
- 51 HULSMANN, M.: A maxillary first molar with two disto-buccal root canals. *J. Endod.* 23:707, 1997.
- 52 IBARROLA, J.L., KNOWLES, K.I., LUDLOW, M.O., MCKINLEY Jr. I.B.: Factors affecting the negotiability of second mesiobuccal canals in maxillary molars. *J. Endod.* 23:236, 1997.
- 53 INGLE, J.I.: Endodontics. Philadelphia. Lea & Febiger, 1967, p. 153.
- 54 JACOBSEN, E.L.: Unusual palatal root canal morphology in maxillary molars. *Endod. Dent. Traumatol.* 10:19, 1994.
- 55 JACOBSEN, E.L., DICK, K., BODELL, R.: Mandibular first molars with multiple mesial canals. *J. Endod.* 20:610, 1994.
- 56 KULID, J.C., PETERS, D.D.: Incidence and configuration of canal systems in the mesiobuccal root of maxillary first and second molars. *J. Endod.* 16:311, 1990.
- 57 LA TURNO, S.A., ZILLICH, R.M.: Straight-line endodontic access to anterior teeth. *Oral Surg.* 59:418, 1985.
- 58 LASFARGUES, J.J., LAISON, F., LEVY, G.: Le vie d'accesso in endodonzia. *Dental Cadmos* 4:85, 1984.
- 59 LAVAGNOLI, G.: Cavità d'accesso e pretrattamento. *R.I.S.* 4: 34, 1978.
- 60 LAVAGNOLI, G.: La cavità d'accesso. *Dental Cadmos* 1:17, 1984.
- 61 MALAGNINO, V.A., CANTATORE, G., ROSSI, A.: Studio sull'anatomia endodontica dei primi molari inferiori. *G. It. Endo.* 5:142, 1991.
- 62 MALAGNINO, V.A., CANTATORE, G., SPINELLI, P.: Studio sull'anatomia endodontica dei secondi molari inferiori. *G. It. Endo.* 6:222, 1992.
- 63 MARINI, R., DOMINI, R., BERUTTI, E.: La presenza del quarto canale nei primi molari superiori. *Min. Stom.* 35: 137, 1986.
- 64 MARTINEZ-BERNA, A., BADANELLI MARCANO, P.: Investigación clínica de molares inferiores con cinco conductos. *B. de Inform. Dent., Ano XLIII*, 332(10):27, 1983.
- 65 MARTINEZ-BERNA, A., RUIZ-BADANELLI, P.: Maxillary first molars with six canals. *J. Endod.* 9:375, 1983.
- 66 MAUGER, M.J., WAITE, R.M., ALEXANDER, J.B., SCHINDLER, W.G.: Ideal endodontic access in mandibular incisors. *Endod.* 25:206, 1999.
- 67 MELTON, D.C., KRELL, K.V., FULLER, M.W.: Anatomical and histological features of C-shaped canals in mandibular second molars. *J. Endod.* 17:384, 1991
- 68 NOSONOWITZ, D.M., BRENNER, M.R.: The major canals of the mesiobuccal root of the maxillary 1st and 2nd molars. *N.Y. J. Dent.* 43:12, 1973.
- 69 PERRINI, N., FRANCINI, E., PERRINI, V.: Analisi morfologica della radice degli incisivi permanenti. *G. It. Endo.* 5:32, 1991.
- 70 PINEDA, F., KUTTLER, Y.: Mesiodistal and buccolingual roentgenographic investigation of 7.275 root canals. *Oral Surg.* 36: 253, 1973.
- 71 POMERANZ, H.H., EIDELMAN, D.L., GOLDBERG, G.: Treatment consideration of the middle mesial canal of mandibular first and second molars. *J. Endod.* 7:565, 1985.
- 72 QUACKENBUSH, L.: Mandibular molar with three distal root canals. *Endod. Dent. Traumatol.* 2:48, 1986.
- 73 RABIE, G.: Mandibular molar with merging mesiobuccal and distal root canals. *Endod. Dent. Traumatol.* 1:191, 1985.
- 74 RICE, R.T., GILBERT, B.O.: An unusual canal configuration in a mandibular first molar. *J. Endod.* 13:513, 1987.
- 75 RUDDLE, C.J.: Microendodontics: identification and treatment of the MB2 system. *J. Calif. Dent. Assoc.* 25:313, 1997.
- 76 SCHILDER, H.: Non-surgical endodontics. Continuing Education Course. Boston University, Nov. 1978.
- 77 SCHILDER, H., YEE, F.S.: Canal debridement and disinfection. In Cohen S., Burns R.C. eds. *Pathways of the pulp*. 3rd ed., The C.V. Mosby Company, 1984, p. 175.
- 78 SEIDBERG, B.H., ALTMAN, M., GUTTUSO, J., SUSON, M.: Frequency of two mesiobuccal root canals in maxillary permanent first molars. *J. Am. Dent. Assoc.* 87:852, 1973.
- 79 SIERASKI, S.M., TAILOR, G.N., KOHN, R.A.: Identification and endodontic management of three-canalled maxillary pre-

- molars. *J. Endod.* 15:29, 1989.
- 80 SION, A., KAUFMANN, A.Y.: L'identificazione dei canali doppi e dei denti anteriori a radice doppia mediante la proiezione di Walton. *Quintess. Intern.* 0(7).65, 1984
 - 81 SKIDMORE, A.E., BJORNDAAL, A.M.: Root canal morphology of the human mandibular first molar. *Oral Surg.* 32:778, 1971.
 - 82 SMITH, B.E.: Root canal morphology of the maxillary first molar: the mesiobuccal root. *Boston University Thesis*, 1977.
 - 83 STONE, L.H., STRONER, W.F.: Maxillary molars demonstrating more than one palatal root canal. *Oral Surg* 51:649, 1981.
 - 84 STRONER, W.F., REMEIKIS, N.A., CARR, G.B.: Mandibular first molar with three distal canals. *Oral Surg.* 57:554, 1984.
 - 85 STROPKO, J.J.: Canal morphology of maxillary molars: Clinical observations of canal configurations. *J. Endod.* 25:446, 1999.
 - 86 THEWS, M.E., KEMP, W.B., JONES, C.R.: Aberrations in palatal root and root canal morphology of two maxillary first molars. *J. Endod.* 5:94, 1979.
 - 87 VERTUCCI, F.J.: Root canal morphology of mandibular premolars. *J. Am Dent. Assoc.* 97:47, 1978.
 - 88 VERTUCCI, F.J.: Root canal anatomy of the human permanent teeth. *Oral Surg.* 58:589, 1984.
 - 89 VERTUCCI, F.J., GEGAUFF, A.: Root canal morphology of the maxillary first premolar. *J. Am. Dent. Assoc.* 99:194, 1979.
 - 90 VERTUCCI, F., SEELING, A., GILLIS, R.: Root canal morphology of the human maxillary second premolar. *Oral Surg.* 38:456, 1972.
 - 91 WALKER, R.T.: Root form and canal anatomy of mandibular second molars in a southern Chinese population. *J. Endod.* 14:325, 1988.
 - 92 WEINE, F.S.: *Endodontic therapy*. 3rd ed. St. Louis, The C.V. Mosby Company, 1982, pp.207-255.
 - 93 WEINE, F.S.: Case report: three canals in the mesial root of a mandibular first molar (?). *J. Endod.* 8:517, 1982.
 - 94 WEINE, F.S.: The C-shaped mandibular second molar: incidence and other considerations. *J. Endod.* 24:372, 1998.
 - 95 WEINE, F.S., PASIEWICZ, R.A., RICE, R.T.: Canal configuration of the mandibular second molar using a clinically oriented in vitro method. *J. Endod.* 14:207, 1988.
 - 96 WELLER, R.N., HARTWELL, G.R.: The impact of improved access and searching techniques on detection of the mesiolingual canal in maxillary molars. *J. Endod.* 15:82, 1989.
 - 97 WELLER, R.N., NIEMCZYK, S.P., KIM, S.: Incidence and position of the canal isthmus. Part1. Mesiobuccal root of the maxillary first molar. *J. Endod.* 21:380, 1995.
 - 98 WELLS, D.W., BERNIER, W.E.: A single mesial canal and two distal canals in a mandibular second molar. *J. Endod.* 10:400, 1984.
 - 99 YANG, Z.P., YANG, S.F., LIN, Y.C., SHAY, J.C., CHI, C.Y.: C-shaped root canals in mandibular second molars in a Chinese population. *Endod. Dent. Traumatol.* 4:160, 1988.
 - 100 ZILLICH, R.M., JEROME, J.K.: Endodontic access to maxillary lateral incisors. *Oral Surg.* 52:443, 1981.
 - 101 ZILLICH, R.M., DOWSON, J.: Root canal morphology of mandibular first and second premolars. *Oral Surg.* 36:738, 1973.