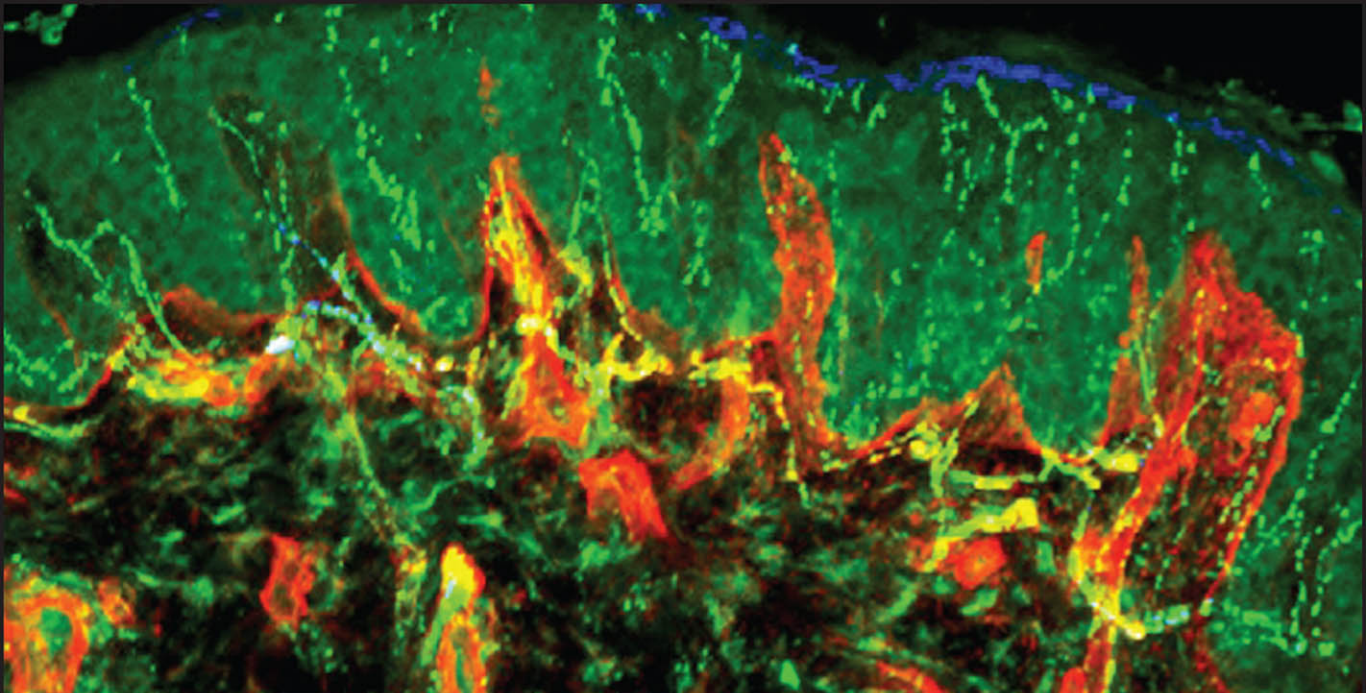

1st edition

CLINICAL DERMATOLOGY

Carol Soutor • Maria Hordinsky

Mc
Graw
Hill
Education

LANGE[®]

Includes access to
an online learning
center



Clinical Dermatology

Notice

Medicine is an ever-changing science. As new research and clinical experience broaden our knowledge, changes in treatment and drug therapy are required. The editors and the publisher of this work have checked with sources believed to be reliable in their efforts to provide information that is complete and generally in accord with the standards accepted at the time of publication. However, in view of the possibility of human error or changes in medical sciences, neither the editors nor the publisher nor any other party who has been involved in the preparation or publication of this work warrants that the information contained herein is in every respect accurate or complete, and they disclaim all responsibility for any errors or omissions or for the results obtained from use of such information contained in this work. Readers are encouraged to confirm the information contained herein with other sources. For example and in particular, readers are advised to check the product information sheet included in the package of each drug they plan to administer to be certain that the information contained in this work is accurate and that changes have not been made in the recommended dose or in the contraindications for administration. This recommendation is of particular importance in connection with new or infrequently used drugs.

a LANGE medical book

Clinical Dermatology

Carol Soutor, MD

Clinical Professor
Department of Dermatology
University of Minnesota Medical School
Minneapolis, Minnesota

Maria K. Hordinsky, MD

Chair and Professor
Department of Dermatology
University of Minnesota Medical School
Minneapolis, Minnesota



Medical

New York Chicago San Francisco Lisbon London Madrid Mexico City
Milan New Delhi San Juan Seoul Singapore Sydney Toronto



Copyright © 2013 by McGraw-Hill Education, LLC. All rights reserved. Except as permitted under the United States Copyright Act of 1976, no part of this publication may be reproduced or distributed in any form or by any means, or stored in a database or retrieval system, without the prior written permission of the publisher.

ISBN: 978-0-07-177296-9

MHID: 0-07-177296-0

The material in this eBook also appears in the print version of this title: ISBN: 978-0-07-176915-0,
MHID: 0-07-176915-3.

All trademarks are trademarks of their respective owners. Rather than put a trademark symbol after every occurrence of a trademarked name, we use names in an editorial fashion only, and to the benefit of the trademark owner, with no intention of infringement of the trademark. Where such designations appear in this book, they have been printed with initial caps.

McGraw-Hill Education eBooks are available at special quantity discounts to use as premiums and sales promotions, or for use in corporate training programs. To contact a representative please e-mail us at bulksales@mcgraw-hill.com.

TERMS OF USE

This is a copyrighted work and McGraw-Hill Education, LLC. and its licensors reserve all rights in and to the work. Use of this work is subject to these terms. Except as permitted under the Copyright Act of 1976 and the right to store and retrieve one copy of the work, you may not decompile, disassemble, reverse engineer, reproduce, modify, create derivative works based upon, transmit, distribute, disseminate, sell, publish or sublicense the work or any part of it without McGraw-Hill Education's prior consent. You may use the work for your own noncommercial and personal use; any other use of the work is strictly prohibited. Your right to use the work may be terminated if you fail to comply with these terms.

THE WORK IS PROVIDED "AS IS." McGRAW-HILL EDUCATION AND ITS LICENSORS MAKE NO GUARANTEES OR WARRANTIES AS TO THE ACCURACY, ADEQUACY OR COMPLETENESS OF OR RESULTS TO BE OBTAINED FROM USING THE WORK, INCLUDING ANY INFORMATION THAT CAN BE ACCESSED THROUGH THE WORK VIA HYPERLINK OR OTHERWISE, AND EXPRESSLY DISCLAIM ANY WARRANTY, EXPRESS OR IMPLIED, INCLUDING BUT NOT LIMITED TO IMPLIED WARRANTIES OF MERCHANTABILITY OR FITNESS FOR A PARTICULAR PURPOSE. McGraw-Hill Education and its licensors do not warrant or guarantee that the functions contained in the work will meet your requirements or that its operation will be uninterrupted or error free. Neither McGraw-Hill Education nor its licensors shall be liable to you or anyone else for any inaccuracy, error or omission, regardless of cause, in the work or for any damages resulting therefrom. McGraw-Hill Education has no responsibility for the content of any information accessed through the work. Under no circumstances shall McGraw-Hill Education and/or its licensors be liable for any indirect, incidental, special, punitive, consequential or similar damages that result from the use of or inability to use the work, even if any of them has been advised of the possibility of such damages. This limitation of liability shall apply to any claim or cause whatsoever whether such claim or cause arises in contract, tort or otherwise.

Contents

Contributors
Preface

vii
xi

I. FUNDAMENTALS OF DIAGNOSIS AND TREATMENT

1. Structure and Functions of the Skin	1
2. Morphology and Terminology of Skin Lesions	6
3. History and Physical Examination of the Skin, Hair, and Nails	15
4. Diagnostic Procedures	20
5. Principles of Diagnosis	25
6. Principles of Management	31
7. Dermatologic Procedures	38

II. DISEASE-BASED CHAPTERS

8. Dermatitis	47
9. Psoriasis and Other Papulosquamous Diseases	60
10. Superficial Fungal Infections	71
11. Viral Infections of the Skin	88
12. Bacterial Infections	97
13. Infestations and Bites	104
14. Urticaria and Drug Rashes	117
15. Acne, Rosacea, and Related Disorders	128

16. Benign Tumors and Vascular Lesions	141
17. Actinic Keratosis, Basal, and Squamous Cell Carcinoma	154
18. Nevi and Melanoma	163
19. Hair Disorders	175
20. Nail Disorders	188
21. Pigment Disorders	195
22. Immunobullous Diseases	204
23. Erythema Multiforme, Stevens-Johnson Syndrome, Toxic Epidermal Necrolysis, Staphylococcal Scalded Skin Syndrome	210
24. Skin Signs of Systemic Disease	219

III. PROBLEM-BASED CHAPTERS

25. The Differential Diagnosis of Purpura	229
26. Pruritus in Patients with No Underlying Skin Disease	238
27. Fever and Rash	243
28. Hospital-Acquired Rashes	253
29. Leg Ulcers	259
30. Skin Diseases of the Scalp	265
31. Skin Diseases of the Face	268
32. Skin Diseases of the Arms	272

33. Skin Diseases of the Hands	274	38. Diseases of the Oral Cavity	290
34. Skin Diseases of the Trunk	277	39. Diseases of the Genitals and Perineum	315
35. Skin Diseases of the Legs	280	40. Cosmetic Concerns	323
36. Skin Diseases of the Feet	283	Index	329
37. Skin Diseases Involving Multiple Body Regions	285		

Contributors

Rehana L. Ahmed, MD, PhD

Assistant Professor
Department of Dermatology
University of Minnesota Medical School
Minneapolis, Minnesota
Chapter 26

Bruce Bart, MD

Professor
Department of Dermatology
University of Minnesota Medical School
Minneapolis, Minnesota
Chapters 11, 12

Andrea Bershow, MD

Assistant Professor
University of Minnesota Medical School
Minneapolis, Minnesota
Chapters 10, 20

Kimberly Bohjanen, MD

Associate Professor
Department of Dermatology
University of Minnesota Medical School
Minneapolis, Minnesota
Chapters 1, 22

Caleb Creswell, MD

Clinical Assistant Professor
Department of Dermatology
University of Minnesota Medical School
Minneapolis, Minnesota
Chapter 14

Bart Endrizzi, MD, PhD

Assistant Professor
Department of Dermatology
University of Minnesota Medical School
Minneapolis, Minnesota
Chapters 7, 16

John Fenyk, MD

Professor
Department of Dermatology
University of Minnesota Medical School
Minneapolis, Minnesota
Chapter 24

Neal Foman, MD, MS

Clinical Associate Professor
Department of Dermatology
University of Minnesota Medical School
Minneapolis, Minnesota
Chapter 29

Noah Goldfarb, MD

Internal Medicine and Dermatology Resident
University of Minnesota Medical School
Minneapolis, Minnesota
Chapters 31, 32, 33, 34, 35, 36, and 37

Khaled M. Hassan, MD

Mohs Micrographic Surgery
Procedural Dermatology Fellow
Dermatologic SurgiCenter
Philadelphia, Pennsylvania
Chapter 40

H. Spencer Holmes, MD

Clinical Professor
Department of Dermatology
University of Minnesota Medical School
Minneapolis, Minnesota
Chapter 15

Kristen Hook, MD

Assistant Professor
Department of Dermatology
University of Minnesota Medical School
Minneapolis, Minnesota
Chapters 8, 27

Maria K. Hordinsky, MD

Chair and Professor
Department of Dermatology
University of Minnesota Medical School
Minneapolis, Minnesota
Chapters 19, 30

Laura E. Keck, MD

Dermatology Resident
Department of Dermatology
University of New Mexico School of Medicine
Albuquerque, New Mexico
Chapter 9

Phoebe Koch, MD

Park Nicollet Clinic
Dermatology Department
St. Louis Park, Minnesota
Chapter 39

Ioannis G. Koutlas, DDS, MS

Associate Professor
Division of Oral and Maxillofacial Pathology
University of Minnesota Medical School
Minneapolis, Minnesota
Chapter 38

Peter K. Lee, MD, PhD

Associate Professor
Department of Dermatology
University of Minnesota Medical School
Minneapolis, Minnesota
Chapter 17

Steven W. Lin, MD

Dermatology Resident
Department of Dermatology
University of Minnesota Medical School
Minneapolis, Minnesota
Chapters 31, 32, 33, 34, 35, 36, and 37

Sarah Nakib, MD, MS

Assistant Professor
Department of Dermatology
Johns Hopkins University
Baltimore, Maryland
Chapter 25

R. Steven Padilla, MD

Chair and Professor
Department of Dermatology
University of New Mexico School of Medicine
Albuquerque, New Mexico
Chapter 9

Amit G. Pandya, MD

Professor
Department of Dermatology
University of Texas Southwestern Medical Center
Dallas, Texas
Chapter 21

Scott Prawer, MD

Clinical Assistant Professor
Department of Dermatology
University of Minnesota Medical School
Minneapolis, Minnesota
Chapters 10, 12

Steven Prawer, MD

Clinical Professor
Department of Dermatology
University of Minnesota Medical School
Minneapolis, Minnesota
Chapter 10

Monica Rani, MD

Instructor
Departments of Dermatology and Medicine
Northwestern University
Feinberg School of Medicine
Chicago, Illinois
Chapter 25

April T. Sanchez, MD

Dermatology Resident
Department of Dermatology
University of Texas Southwestern Medical Center
Dallas, Texas
Chapter 21

Cindy Firkins Smith, MD

Clinical Professor
Department of Dermatology
University of Minnesota Medical School
Minneapolis, Minnesota
Chapters 13, 23

Carol Soutor, MD

Clinical Professor
Department of Dermatology
University of Minnesota Medical School
Minneapolis, Minnesota
Chapters 2, 3, 4, 5, and 6

David L. Swanson, MD

Associate Professor
Department of Dermatology
Mayo Clinic Scottsdale
Scottsdale, Arizona
Chapter 18

Erin Warshaw, MD, MS

Professor
Department of Dermatology
University of Minnesota Medical School
Minneapolis, Minnesota
Chapter 8

Barbara D. Wilson, MD

Associate Professor
Department of Dermatology
Medical College of Wisconsin
Milwaukee, Wisconsin
Chapter 28

Christopher B. Zachary, MBBS, FRCP

Chair and Professor
Department of Dermatology
University of California
Irvine, California
Chapters 40

Barrett Zlotoff, MD

Assistant Professor
Department of Dermatology
University of New Mexico School of Medicine
Albuquerque, New Mexico
Chapter 9

This page intentionally left blank

Preface

Clinical Dermatology is the product of decades of interaction with our primary care and dermatology colleagues and residents. It features concise, practical information on the diagnosis and management of common skin disorders. Diagnostic features, cost-effective management, evidence-based medicine, and patient-centered care are emphasized.

INTENDED AUDIENCE

Clinicians, residents, and medical students will find this textbook helpful in expanding their understanding and management of skin disorders. Our advisory group, consisting of primary care physicians, residents, nurse practitioners, physician assistants, and medical students, was instrumental in the design and review of this textbook.

ORGANIZATION AND CONTENT

Clinical Dermatology is divided into three sections.

- **Section One** covers the principles of diagnosis, management of common skin disorders, and diagnostic and surgical procedures.
- **Section Two** covers common skin disorders and selected less common disorders with high morbidity. The information on each disease is formatted into ten sections: introduction, pathogenesis, history, physical examination, laboratory findings, diagnosis, differential diagnosis, management, indications for consultation, and patient information. Evidence-based reviews and national and international guidelines are used when available in the management sections.
- **Section Three** focuses on the differential diagnosis of diseases in specific body regions based on history and physical examination. This section also includes the differential diagnosis of purpura, fever and rash, hospital-acquired rashes, pruritus, and skin ulcers. A chapter on cosmetic dermatology completes this section.

The online learning center (www.LangeClinicalDermatology.com) for this textbook contains multimedia

presentations that complement and expand the content in the textbook. It contains the following.

- Videos with detailed demonstrations of common cutaneous diagnostic and surgical procedures.
- Clinical unknown cases with self-assessment questions that cover challenging diagnostic and management problems.
- PowerPoint presentations that cover the diagnosis, evaluation, and management of common skin disorders. These PowerPoints can be used for a rapid review of cutaneous disease or by educators for teaching.

ACKNOWLEDGMENTS

We would like to thank our editors, Anne Sydor and Christina M. Thomas, the production supervisor, Sherri Souffrance, and the project manager, Asheesh Ratra. We are grateful for contributions of photographs from Doctors Whitney Tope, Spencer Holmes, Bruce Bart, Richard Steinberg, Cindy Vehe, Dan Kaplan, Marna Ericson, Valda Kaye, Mark Wilke, Warren Goodman, David Ahrenholz, and the residents of the University of Minnesota dermatology residency programs. We thank our reviewers Jamie Santilli, MD, Assistant Professor, University of Minnesota Department of Family Medicine and Community Health; Catherine Manabat, MD, medicine/dermatology resident; Sanober Amin, MD, PhD, dermatology resident; Cynthia Olson, MD, Associate Professor, University of Minnesota Department of Dermatology; our medical student reviewers James Dorrian, Kathleen P. Lane, Matthew Majerus, Julie Fox, Jaime Loso, Maria Smith, and Heather Haberman PA-C and Victoria Eddy NP.

We want to especially acknowledge Robert W. Goltz, MD, who was our mentor and chairman of the Department of Dermatology at the University of Minnesota (1971 to 1985). His mastery of the art, science, and practice of medicine influenced all who were privileged to train with him.

We are especially grateful for our husbands' support and patience during this project.

This page intentionally left blank

Structure and Functions of the Skin

Kimberly Bohjanen

1

Introduction to Chapter / 1
Barrier Function / 1
Immunologic Function / 1
Melanin Production and Protection from
Ultraviolet Light Damage / 2
Synthesis of Vitamin D / 4

Sensation / 4
Temperature Regulation / 4
Protection from Trauma / 5
Identity and Aesthetics / 5
References / 5

INTRODUCTION TO CHAPTER

The skin is the site of many complex and dynamic processes as demonstrated in Figure 1-1 and Table 1-1. These processes include barrier and immunologic functions, melanin production, vitamin D synthesis, sensation, temperature regulation, protection from trauma and aesthetics.

BARRIER FUNCTION

The epidermal barrier protects the skin from microbes, chemicals, physical trauma, and desiccation due to transepidermal water loss.¹⁻³ This barrier is created by differentiation of keratinocytes as they move from the basal cell layer to the stratum corneum. The keratinocytes of the epidermis are produced and renewed by stem cells in the basal layer resulting in replacement of the epidermis approximately every 28 days. It takes 14 days for these cells to reach the stratum corneum and another 14 days for the cells to desquamate.

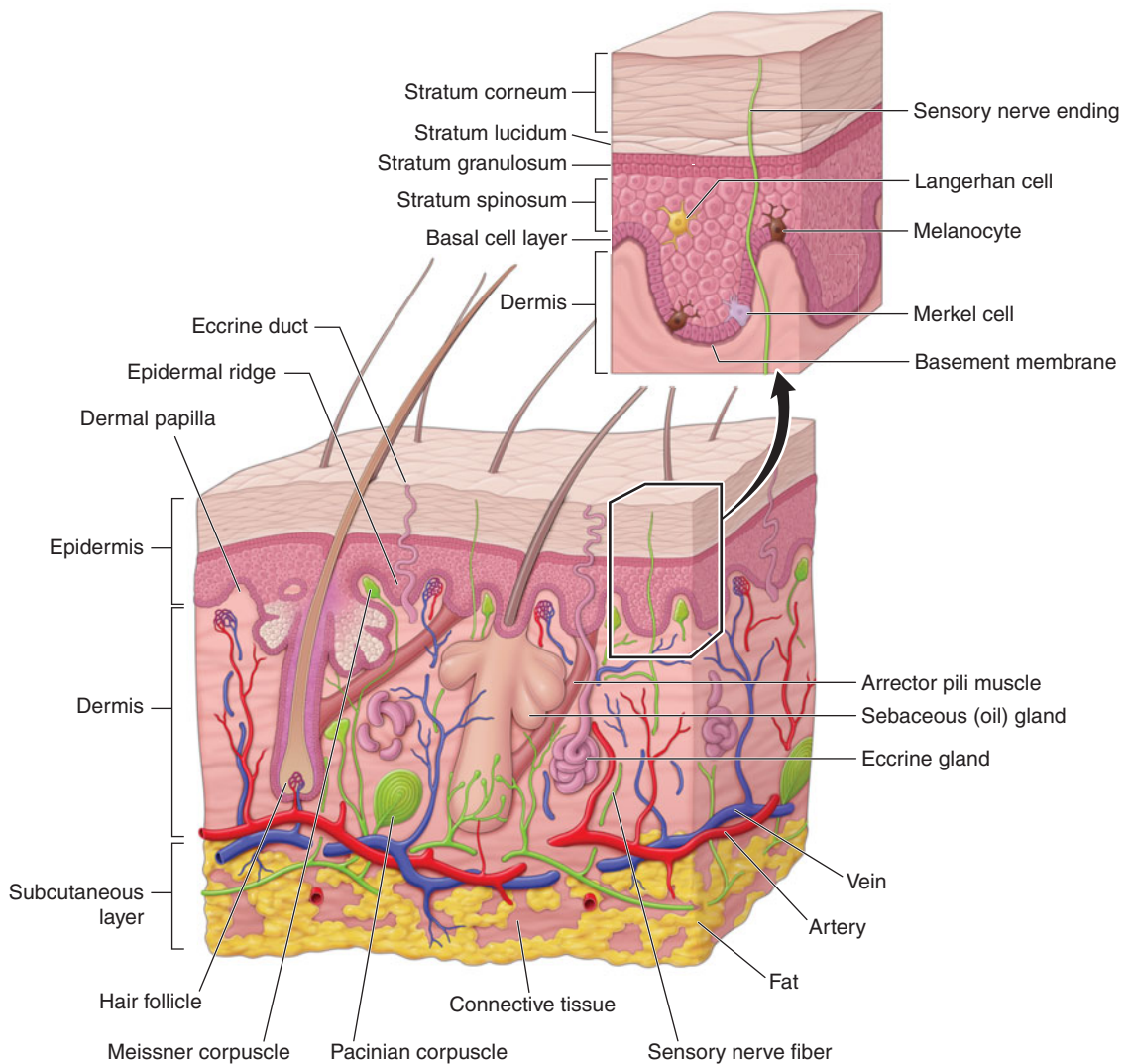
Keratinocytes produce keratins, structural proteins that form filaments that are part of the keratinocyte cytoskeleton. In the stratum spinosum keratin filaments radiate outwards from the nucleus and connect with desmosomes which are prominent under the microscope giving a “spiny” appearance to cells. As cells move into the stratum granulosum, keratohyalin granules composed of keratin and profilaggrin

are formed. Profilaggrin is converted into filaggrin (*filament aggregation protein*) that aggregates and aligns keratin filaments into tightly compressed parallel bundles that form the matrix for the cells of the stratum corneum. Filaggrin gene mutations are associated with ichthyosis vulgaris and atopic dermatitis. As keratinocytes move into the stratum corneum they lose their nuclei and organelles and develop a flat hexagon shape. These cells are stacked into a “bricks and mortar”-like pattern with 15 to 25 layers of cells (bricks) surrounded by lipids (mortar). The lipids consist of ceramides, free fatty acids, and cholesterol.

IMMUNOLOGIC FUNCTION

Epithelial cells at the interface between the skin and the environment provide the first line of defense via the innate immune system.⁴⁻⁶ Epithelial cells are equipped to respond to the environment through a variety of structures including Toll-like receptors (TLRs) of which there are at least 10, nucleotide-binding oligomerization domain-like receptors, C-type lectins, and peptidoglycan recognition proteins. TLR-mediated activation of epithelial cells is also associated with the production of defensins and cathelicidins, families of antimicrobial peptides.

Dendritic cells bridge the gap between the innate and adaptive immune systems. Dermal dendritic cells can induce autoprolieration of T cells and production



▲ **Figure 1-1.** Cross-section of skin.

of cytokines as well as nitric oxide synthase. The exact function of dendritic epidermal Langerhans cells is an area of rapidly evolving research suggesting that these cells are very important to the modulation of the adaptive immune response.⁷

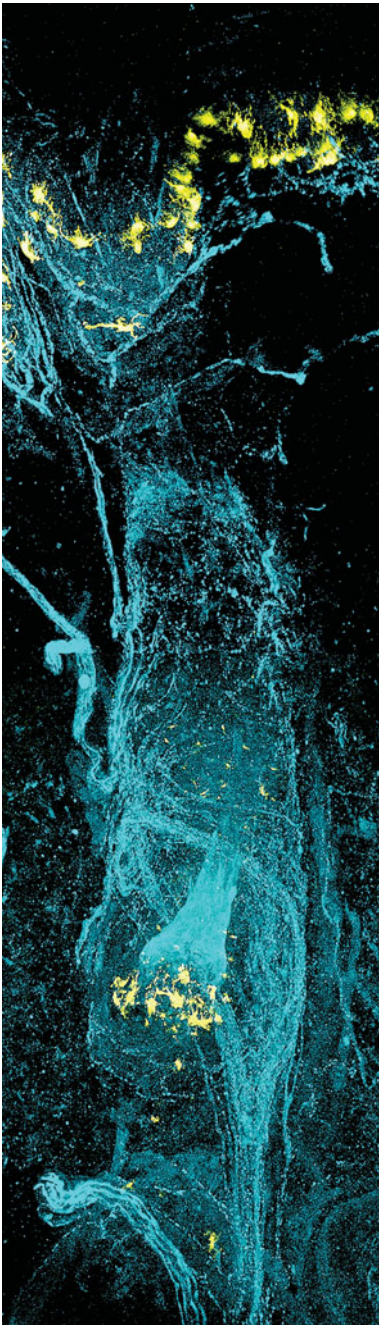
MELANIN PRODUCTION AND PROTECTION FROM ULTRAVIOLET LIGHT DAMAGE

Melanocytes comprise 10% of the cells in the basal cell layer.⁸ There is another population of melanocytes in the hair follicle that is responsible for hair color and replacing

epidermal melanocytes as needed (Figure 1-2). Melanocytes produce melanin, a pigmented polymer that absorbs UV light. Melanin is synthesized from tyrosine in several steps that require the enzyme tyrosinase. As melanin is produced it is then packaged into melanosomes, a specialized organelle. Melanosomes are phagocytosed by keratinocytes and moved to an area above the keratinocyte's nucleus acting as a protective shield from UV light. One melanocyte provides melanosomes for as many 30 to 40 keratinocytes. All humans have the same number of melanocytes. The variation in the degree of skin color is due to variations in melanosomes. Individuals with darker brown skin tones have

Table 1-1. Structure and function of the skin.

Component	Structure and Function
Stratum corneum	Semipermeable barrier with “bricks” (stacked cornified cells) and “mortar” (ceramides, cholesterol, and fatty acids) like construction
Stratum granulosum	Contains keratohyalin granules that produce profilaggrin
Stratum spinosum	Contains desmosomes for intercellular adhesion
Langerhans cells	Dendritic cells, important in the modulation of the adaptive immune response
Merkel cells	Specialized cells with neuroendocrine function
Melanocytes	Dendritic cells that produce melanin for ultraviolet light protection
Basal cell layer	Contains the stem cells that divide and produce the rest of the keratinocytes in the epidermis
Basement membrane	Interface between the epidermis and dermis
Ground substance	Amorphous gel of mucopolysaccharides that is the substrate for the dermis
Collagen	Network of fibrous proteins for skin tensile strength
Elastic fibers	Fibrous proteins responsible for skin elasticity
Fibroblasts	Cells that produce ground substance, collagen, and elastic fibers
Mast cells	Leukocytes that release histamine and heparin
Histiocytes/macrophages	Leukocytes that phagocytize and present antigen
Eccrine glands	Sweat glands that help with temperature regulation
Apocrine glands	Axillary and anogenital glands responsible for body odor
Sebaceous glands	Component of pilosebaceous unit that produces sebum
Hair follicle	Component of pilosebaceous unit that produces the hair fiber
Somatic sensory and sympathetic autonomic nerves	Supply blood vessels, glands, and hair follicles
Meissner corpuscles	Specialized nerve receptors for light touch
Pacinian corpuscles	Specialized nerve receptors for pressure and vibration
Blood vessels	Two horizontal plexes in the dermis that are connected and can shunt blood flow
Lymphatics	Parallel to blood vessels with 2 plexuses for flow of plasma
Fat	Provides protection from cold and trauma; Essential for storage of energy and metabolism of sex hormones and glucocorticoids



▲ **Figure 1-2.** Melanocytes in the basal cell layer and in the hair bulb region. Confocal image of nerves (aqua) and melanocytes (yellow) in the epidermis and the hair bulb region of a human anagen scalp hair follicle. Montage of 3 fields of view. Sample was immunostained with antibodies to a pan-neuronal marker PGP9.5 (aqua) and melanocytes (Mels-5) (yellow). (Reproduced with permission from Marna Ericson, PhD.)

more abundant, larger, and more dispersed melanosomes. Exposure to UV light stimulates the production of melanin within melanosomes producing a “tan.” Tyrosinase deficiency is associated with albinism and vitiligo is associated with absence of melanocytes.

SYNTHESIS OF VITAMIN D

The main sources for vitamin D are dietary intake and production of vitamin D precursors by the skin. With exposure to UV light provitamin D₃ (7-dehydrocholesterol) in the epidermis is converted into previtamin D that converts into vitamin D₃. Vitamin D₃ is converted to its metabolically active form in the liver and kidneys.⁸

SENSATION

The skin is one of the principal sites of interaction with the environment and many types of stimuli are processed by the peripheral and central nervous systems.^{9,10} Initially, cutaneous nerves were classified as being either “afferent” controlling sweat gland function and blood flow or “efferent” transmitting sensory signals to the central nervous system, but after the discovery of the neuropeptide substance P (SP) and other neuropeptides in sensory nerves, many trophic properties of nerve fibers and neuropeptides have been reported.

There are 3 major nerve types in the skin:

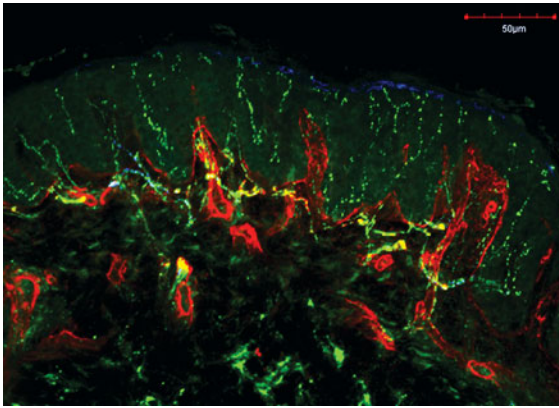
- Aβ fibers—large, heavily myelinated nerve fibers that transmit tactile sensation
- Aδ fibers—thinly myelinated nerve fibers involved in the transmission of short and fast painful stimuli
- C-fibers—unmyelinated nerves that transmit pain and itch sensations

Mixed nerve fiber bundles form a plexus from which individual nerve fibers extend toward their specific targets. The first tier is underneath the epidermis and innervates the epidermis and cutaneous mechanoreceptors or the upper dermis (Figure 1-3).

The second and third tiers are located between the dermis and subcutis or in the deep subcutis and innervate hair follicles, the arrector pili muscles, and sweat glands as well as the lower dermis and subcutis. All 3 plexi innervate blood vessels, smooth muscle cells, and mast cells, thereby connecting different skin cell populations with the brain.

TEMPERATURE REGULATION

The skin helps to regulate and maintain core body temperature through regulation of sweating and varying the blood flow in the skin. Evaporation of sweat contributes to temperature control of the body. Under normal conditions 900 mL of sweat is produced daily. With increased physical activity or increased environmental temperature, 1.4 to 3 L of sweat per hour can be produced.¹¹



▲ **Figure 1-3.** Epidermal nerve fibers and blood vessels. Confocal image of epidermal nerve fibers (green), collagen type IV (red), and the neuropeptide calcitonin gene-related peptide (CGRP) (blue) in human scalp skin. The dermal/epidermal boundary and blood vessels are delineated by collagen type IV (red). Sample was immunostained with antibodies to protein gene product (PGP) 9.5 (green), collagen type IV (red), and CGRP (blue). (Reproduced with permission from Marna Ericson, PhD.)

The regulation of blood flow in the capillaries in the dermal papillae and other cutaneous vessels plays an important role in convective heat loss and heat conservation. Normally the blood flow in the skin is approximately 5% of the cardiac output, but in extremely cold temperatures it can drop to almost zero and in severe heat stress it can be as high as 60%.¹² Dysfunction of thermoregulation can lead to hyperthermia and hypothermia.

PROTECTION FROM TRAUMA

The dermis varies in thickness from 1 to 4 mm. It protects and cushions underlying structures from injury and provides support for blood vessels, nerves, and adnexal structures. It is separated from the epidermis by the basement membrane, which is created by the basal layer of the epidermis. Collagen is responsible for the tensile strength of the skin and comprises 75% of the dry weight of the dermis. Defects in collagen synthesis are associated with diseases such as Ehlers–Danlos syndrome (hyperextensible

joints and skin). Elastic fibers are responsible for the elasticity and resilience of the skin and are 2% to 3% of the dry weight of the skin. Defects in elastic fibrils can be associated with cutis laxa and Marfan syndrome.

IDENTITY AND AESTHETICS

The perception of an individual's ethnicity, age, state of health, and attractiveness is affected by the appearance of his or her skin and hair. Sun-damaged skin, rashes, hair disorders, pigment disorders, and acne can have a profound effect on how individuals perceive themselves and others.

REFERENCES

1. Baroni A, Buommino E, De Gregorio V, Ruocco E, Ruocco V, Wolf R. Structure and function of the epidermis related to barrier properties. *Clin Dermatol*. 2012;30(3):257–262. PMID: 22507037.
2. Hwa C, Bauer EA, Cohen DE. Skin biology. *Dermatol Ther*. 2011;24(5):464–470. PMID: 22353152.
3. Brown SJ, McLean WH. One remarkable molecule: filaggrin. *J Invest Dermatol*. 2012;132(3):751–762. PMID: 22158554.
4. Gallo RL, Hooper LV. Epithelial antimicrobial defence of the skin and intestine. *Nat Rev Immunol*. 2012;12(7):503–516. PMID: 22728527.
5. Di Meglio P, Perera GK, Nestle FO. The multitasking organ: recent insights into skin immune function. *Immunity*. 2011;35(6):857–869. PMID: 22195743.
6. Nestle FO, Kaplan DH, Barker J. Mechanisms of disease: psoriasis. *N Engl J Med*. 2009;361(5):496–509. PMID: 19641206.
7. Kaplan DH. Langerhans cells: not your average dendritic cell. *Trends Immunol*. 2010;31(12):437. PMID: 21075684.
8. Brenner M, Hearing VJ. The protective role of melanin against UV damage in human skin. *Photochem Photobiol*. 2008;84(3):539–549. PMID: 18435612.
9. Peters EM, Ericson ME, Hosi J, et al. Neuropeptide control mechanisms in cutaneous biopsy: physiological mechanism and clinical significance. *J Invest Dermatol*. 2006;126(9):1937–1947. PMID: 16912691.
10. Davidson S, Giesler GJ. The multiple pathways for itch and their interactions with pain. *Trends Neurosci*. 2010;33(12):550–558. PMID: 21056479.
11. Shibasaki M, Wilson TE, Crandall CG. Neural control and mechanisms of eccrine sweating during heat stress and exercise. *J Appl Physiol*. 2006;100(5):1692–1701. PMID: 16614366.
12. Charkoudian N. Mechanisms and modifiers of reflex induced cutaneous vasodilation and vasoconstriction in humans. *J Appl Physiol*. 2010;109(4):1221–1228. PMID: 20448028.

2

Morphology and Terminology of Skin Lesions

Carol Soutor

Introduction to Chapter / 6
Types of Lesions / 6
Surface Changes / 8
Color / 10

Shape / 10
Arrangement and Distribution / 10
References / 14

INTRODUCTION TO CHAPTER

Identification and classification of a patient's skin lesions are important steps in the diagnosis of any skin disorder. The numerous descriptive terms used in dermatology can be overwhelming and at times confusing as there are some variations in the use and meaning of these words in the literature.¹ However, a few simple terms can be used to describe the cutaneous findings in most skin diseases. Using proper terminology to describe skin findings is essential for both documentation and communication with other clinicians. The effort to use precise descriptive terms also encourages a clinician to look with more

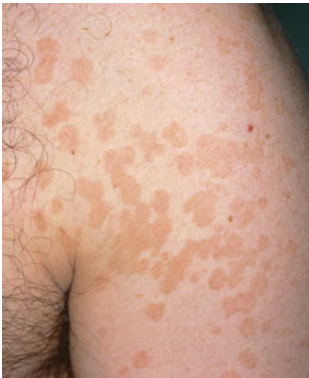care and more closely at a patient's skin lesions. The key features of skin lesions are (1) the type of lesion, (2) secondary changes to the surface of the lesion, (3) the color of the lesion, (4) the shape of the lesion, and (5) the arrangement and distribution of the lesions.

TYPES OF LESIONS

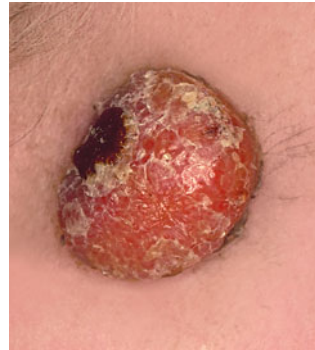
The first step is categorization of the primary skin lesion(s). This may be difficult if the lesions are excoriated or if the examination takes place late in the disease process. The lesion may need to be lightly touched or deeply palpated to accurately assess its features. Table 2-1 lists the 10 most

Table 2-1. Primary lesions and their morphology.

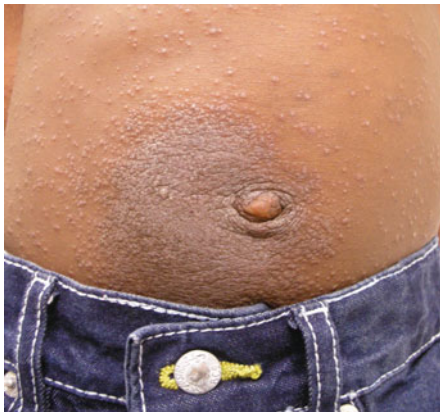Terminology	Diameter	Morphology	Example
Macule Patch	<0.5 cm >0.5 cm	Flat, level with surface of skin	Tinea versicolor (Figure 2-1)
Papule Plaque	<0.5 cm >0.5 cm	Solid, elevated lesion	Dermatitis (Figure 2-2)
Wheal	Any size	White to pink edematous papule or plaque that lasts less than 24 h	Urticaria (Figure 2-3)
Nodule	>0.5 cm	Dermal or subcutaneous solid, elevated lesion	Amelanotic melanoma (Figure 2-4)
Vesicle Bulla	<0.5 cm >0.5 cm	Blister containing fluid or blood	Pemphigus vulgaris (Figure 2-5)
Pustule	<0.5 cm	Cavity filled with pus, may be sterile	Pustular psoriasis (Figure 2-6)
Cyst	>0.5 cm	Cavity filled with pus or keratin	Epidermal cyst (Figure 2-7)



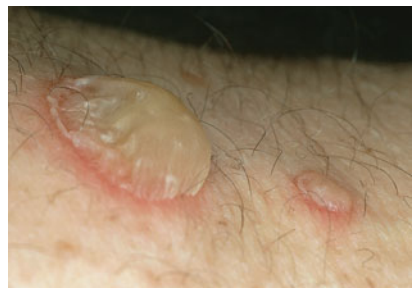▲ **Figure 2-1.** Macules and patches. Tinea versicolor.



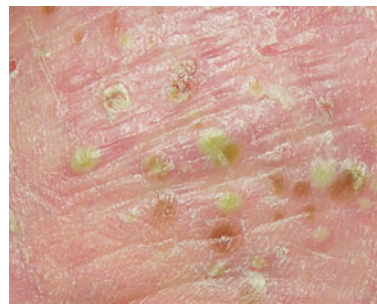▲ **Figure 2-4.** Nodule. Nodular amelanotic melanoma.



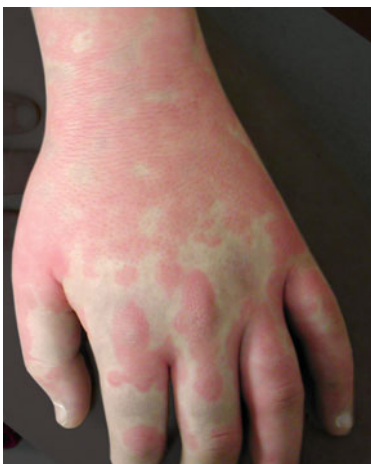▲ **Figure 2-2.** Papules and a plaque. Contact dermatitis due to nickel in metal button in a child with atopic dermatitis.



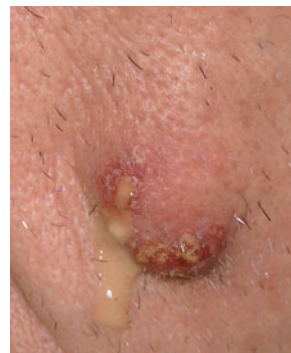▲ **Figure 2-5.** Vesicle and bulla. Pemphigus vulgaris.



▲ **Figure 2-6.** Pustules. Pustular psoriasis.



▲ **Figure 2-3.** Wheal. Urticaria.



▲ **Figure 2-7.** Cyst. Staphylococcal boil.

Table 2-2. Examples of surface changes in skin lesions.

Terminology	Surface Changes in Lesions	Example
Scale	Loose or adherent flake composed of stratum corneum cells. The term hyperkeratotic is used for small areas of thick adherent scale	Psoriasis (Figure 2-8)
Crust	Yellow, brown, black, or green surface deposits of serum, pus, and/or blood	Pemphigus vulgaris (Figure 2-9)
Lichenification	Thickening of the epidermis with accentuation of skin markings	Atopic dermatitis (Figure 2-10)
Fissure	Linear, sharply defined, deep crack in the skin	Callous (Figure 2-11)
Erosion Excoriation	Localized loss of the superficial epidermis Linear or punctate, superficial, erosions in the skin caused by fingernails and sharp objects	Drug rash (Figure 2-12)
Ulcer	Defect in epidermis and dermis due to loss of tissue	Pyoderma gangrenosum (Figure 2-13)
Eschar	Black, hard crust resulting from tissue necrosis of the epidermis and/or dermis	Self-induced injury (Figure 2-14)
Atrophy	Depression and/or surface change in skin as the result of diminution of a component(s) of the epidermis, dermis, or fat	Lichen sclerosis (Figure 2-15)
Scar	Depressed or elevated proliferation of connective tissue that has replaced inflamed or traumatized skin	Depressed scar (Figure 2-16) Hypertrophic scar (Figure 2-17)

common morphological terms for types of skin lesions. These are based on:

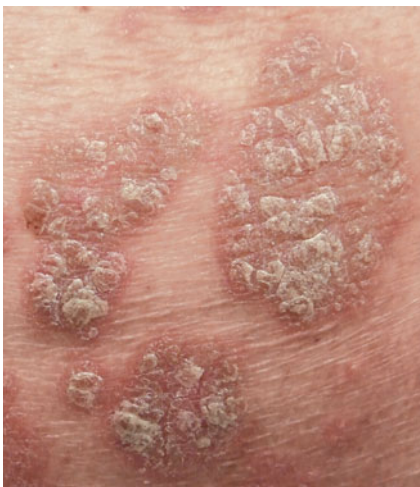- Diameter of the lesion.
- Relationship of the lesion to the surface of the skin—is the lesion flat or elevated above the surface of the skin?
- Composition of the lesion—is it fluid filled or solid?

Most textbooks use a lesion diameter of either 0.5 or 1 cm to distinguish between various lesion types. This textbook uses 0.5 cm. It is not uncommon for a skin

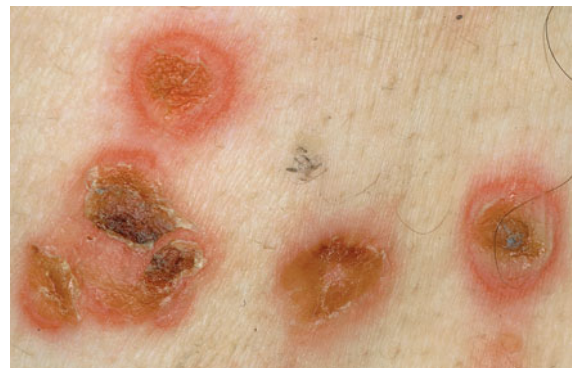disease to have multiple types of lesions. Therefore, terms such as maculopapular or vesiculobullous are commonly used.

SURFACE CHANGES

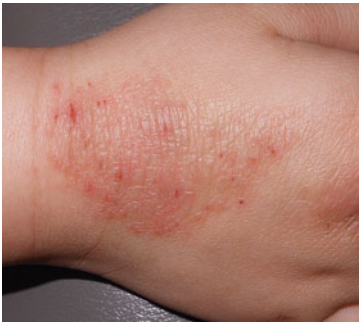Some lesions have a smooth surface, but surface changes frequently quickly develop during the course of a skin disorder. Table 2-2 lists common surface changes. Papulo-squamous is a term used to describe papules/plaques that have scale.



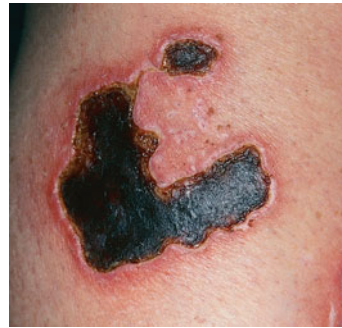▲ **Figure 2-8.** Scale. Psoriasis.



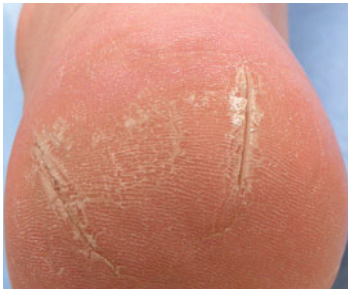▲ **Figure 2-9.** Crust on collapsed bullae of pemphigus vulgaris.



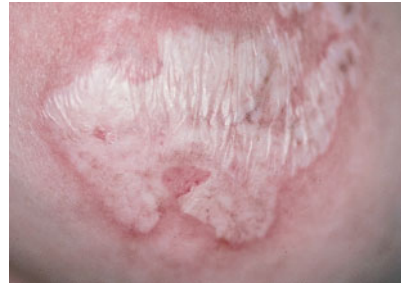▲ **Figure 2-10.** Lichenification. Atopic dermatitis.



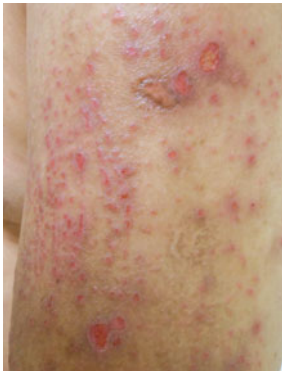▲ **Figure 2-14.** Eschar. Self-induced injury.



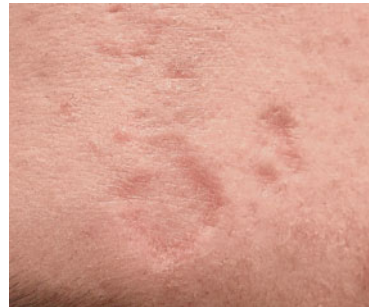▲ **Figure 2-11.** Fissure. Callous on heel.



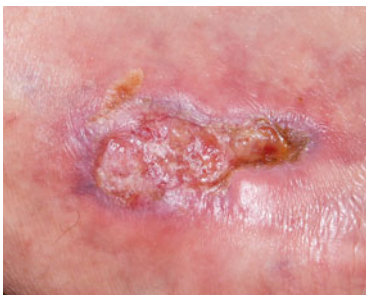▲ **Figure 2-15.** Atrophy. Lichen sclerosis, extragenital.



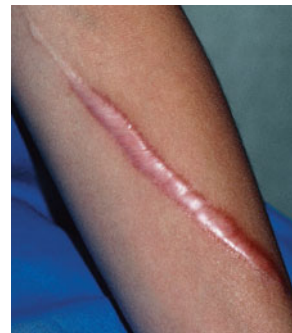▲ **Figure 2-12.** Excoriations and erosions. Lichenoid drug rash.



▲ **Figure 2-16.** Depressed scar. Scar after herpes zoster.



▲ **Figure 2-13.** Ulcer. Pyoderma gangrenosum.



▲ **Figure 2-17.** Elevated scar. Hypertrophic scar after laceration.

Table 2-3. Selected colors of lesions and their possible causes.

Color	Examples of Causes of Color Change	Example
Pale pink	Edema or dilated blood vessels	Urticaria
Pink	Dilated blood vessels	Dermatitis
Red	Dilated blood vessels or extravasated blood	Angiomas
Purple	Dilated blood vessels or extravasated blood	Vasculitis
Yellow	Carotenemia, bilirubinemia	Xanthoma
Brown	Increased melanin or dermal hemosiderin	Melasma, nevi
Black	Increased melanin, necrotic skin	Nevus, eschar
Blue	Melanin deep in dermis, cyanosis	Blue nevus
White	Decreased or absent melanin or melanocytes, vasoconstriction	Vitiligo

COLOR

The color of the lesion often correlates with underlying pathophysiologic changes (Table 2-3). Terms such as hyperpigmented and hypopigmented are often used to describe lesions that are darker or lighter than the patient's overall skin color. Erythema and erythematous are terms used for red hues of lesions that are primarily due to dilated blood vessels in the dermis.

SHAPE

The shape of the lesion may also aid in diagnosis (Table 2-4). Some common skin disorders such as tinea corporis, which typically presents with annular lesions, are characterized by the shape of the lesion.

ARRANGEMENT AND DISTRIBUTION

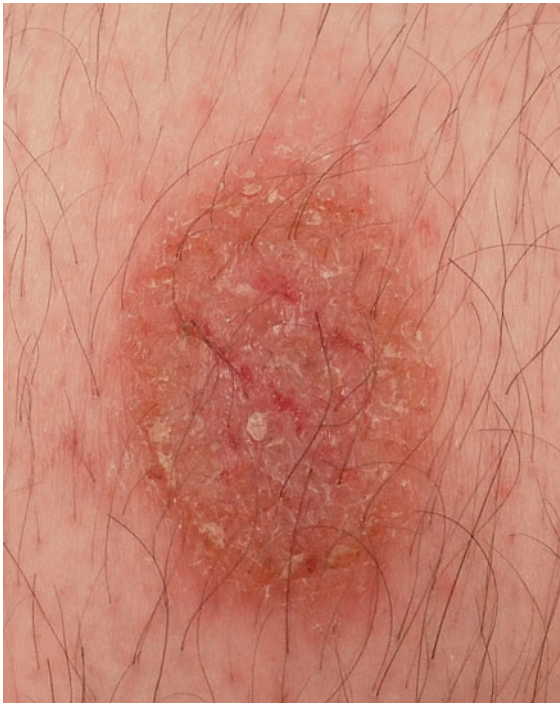The lesions of many skin disorders often have characteristic arrangements and distributions (Table 2-5). For instance, the lesions in viral exanthems and drug rashes are typically symmetrical and herpes simplex vesicles are usually grouped.

When documenting or describing a *skin rash* the most important features are:

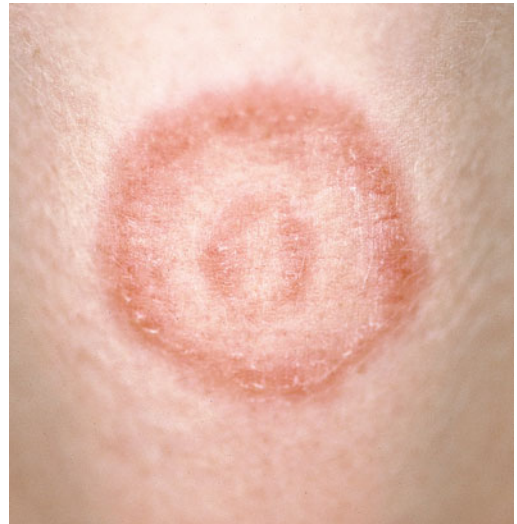- Type of skin lesion(s)
- Surface changes if present
- Color
- Location of lesions
- The percentage of affected body surface should be documented in cases of extensive rashes
- The arrangement/distribution and shapes of lesions may be helpful in some cases

Table 2-4. Shapes of individual lesions.

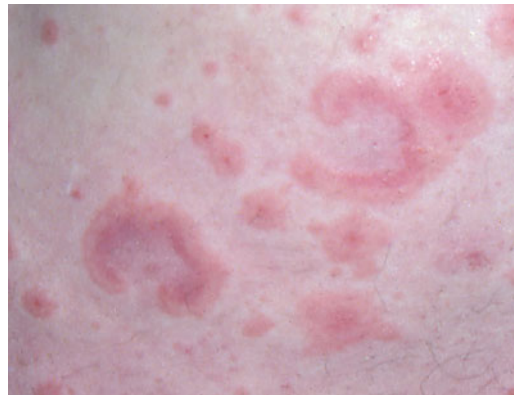Terminology	Shapes of Lesions	Examples
Discoid/round	Round with uniform appearance throughout the lesion ²	Nummular dermatitis (Figure 2-18)
Oval	Oval with uniform appearance throughout the lesion	Pityriasis rosea (Figure 2-19)
Annular	Ring shaped with variation in appearance between center and periphery ³	Tinea corporis (Figure 2-20)
Arcuate	Arc shaped, may be a portion of an annular lesion ³	Erythema multiforme (Figure 2-21)
Targetoid	Target-like with distinct zones	Erythema multiforme (Figure 2-22)



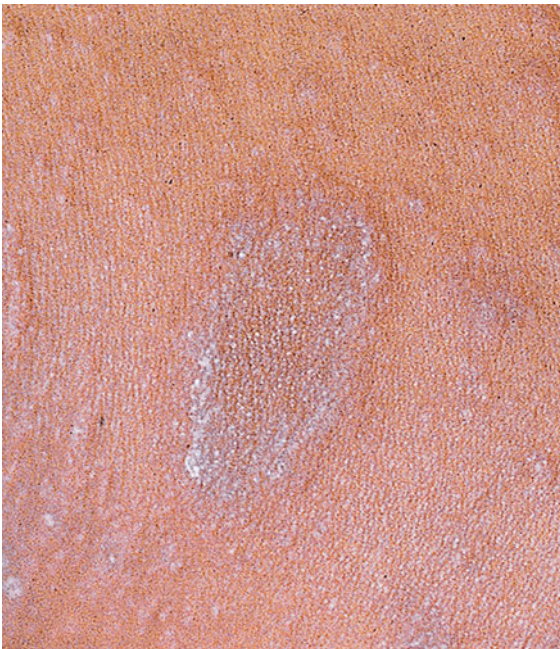▲ **Figure 2-18.** Discoid/round. Nummular dermatitis.



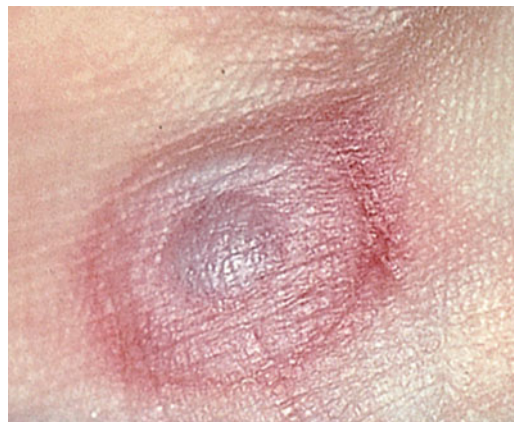
▲ **Figure 2-20.** Annular lesion. Tinea corporis.



▲ **Figure 2-21.** Arcuate lesion. Erythema multiforme.



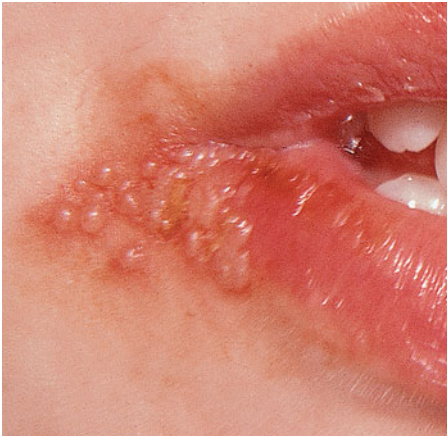▲ **Figure 2-19.** Oval. Pityriasis rosea.



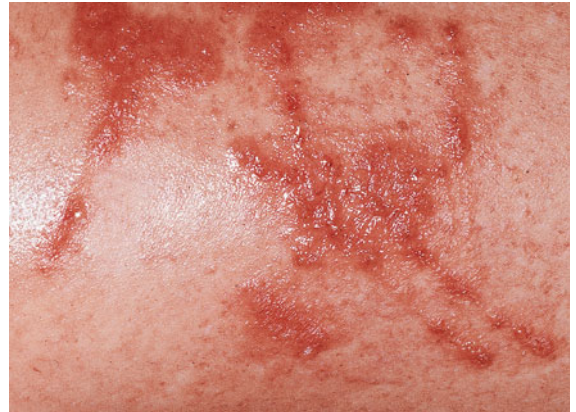▲ **Figure 2-22.** Targetoid lesion. Erythema multiforme.

Table 2-5. Arrangement and distribution of lesions.

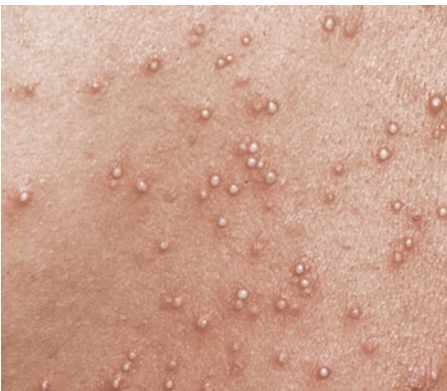Terminology	Arrangement and Distribution of Lesions	Example
Grouped	Clustered next to each other ⁴	Herpes simplex (Figure 2-23)
Discrete/isolated	Separated from one another	Miliaria (Figure 2-24)
Linear/streak	Thin straight line of lesions	Poison ivy dermatitis (Figure 2-25)
Dermatomal	Distributed along a dermatome ⁴	Herpes zoster (Figure 2-26)
Serpiginous	Wave or snake-like	Cutaneous larva migrans (Figure 2-27)
Reticular	Lace or net-like	Vasculitis (Figure 2-28)
Symmetrical	Uniform distribution on both sides of the body	Drug rash (Figure 2-29)
Generalized/disseminated	Spread over wide areas of the body	
Photodistributed	Located in areas of sunlight exposure ⁵	Phototoxic drug rash (Figure 2-30)



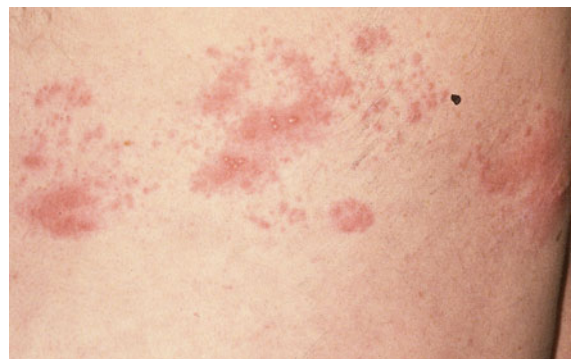▲ **Figure 2-23.** Grouped lesions. Vesicles of herpes simplex.



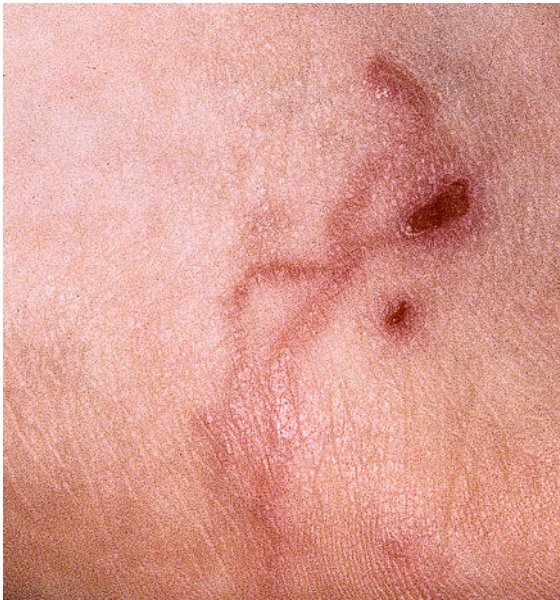▲ **Figure 2-25.** Linear arrangement of vesicles. Allergic contact dermatitis due to poison ivy.



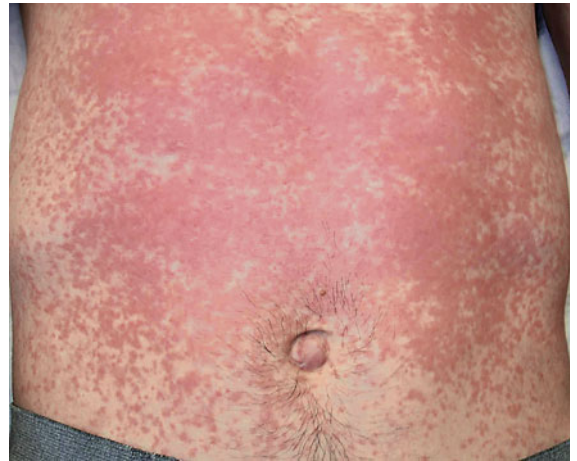▲ **Figure 2-24.** Discrete lesions. Pustules of miliaria pustulosa.



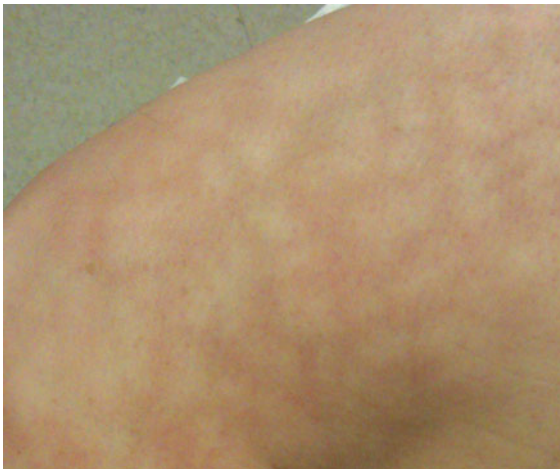▲ **Figure 2-26.** Dermatomal distribution of vesicles. Herpes zoster.



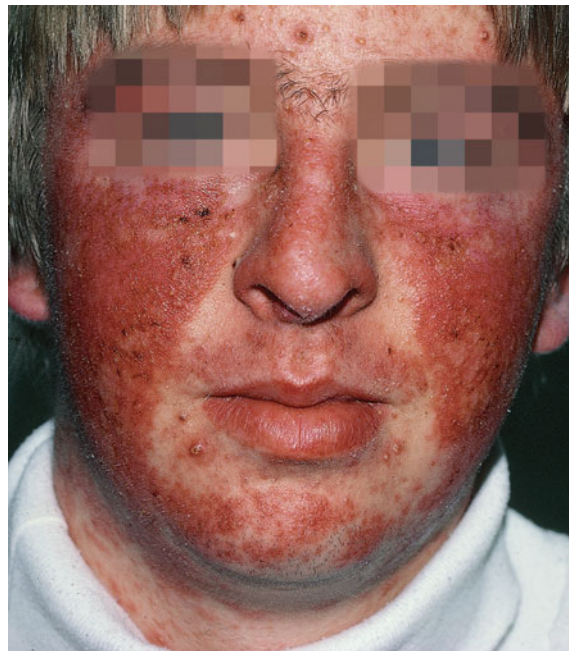▲ **Figure 2-27.** Serpiginous lesions. Cutaneous lava migrans.



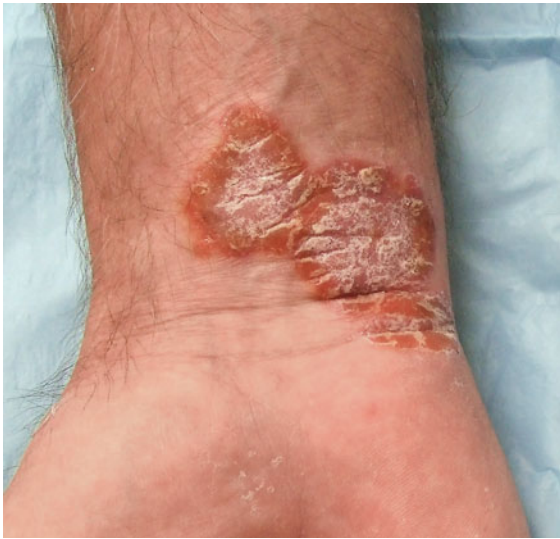▲ **Figure 2-29.** Symmetrical and generalized distribution of macules. Drug rash.



▲ **Figure 2-28.** Reticular. Vasculitis.



▲ **Figure 2-30.** Photodistribution of crusted plaques. Phototoxic drug rash. Note sparing of periorbital and perioral areas, and nasolabial folds.



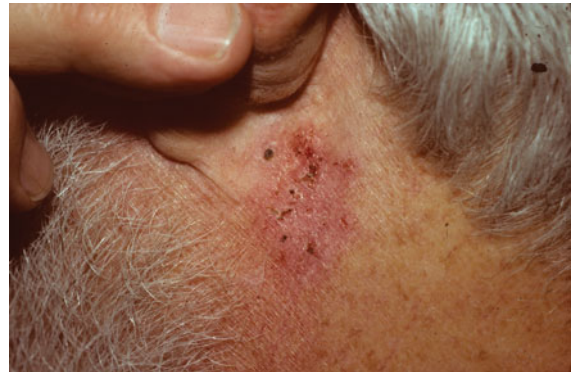▲ **Figure 2-31.** Psoriasis.

Using simple descriptive terms, the rash in Figure 2-31 (psoriasis) could be described as “pink, round plaques with white scale on the volar wrist.”

When documenting or describing a *skin tumor (growth)* the most important features are:

- Type of lesion
- Surface changes if present
- Color
- Diameter of lesion
- Precise location of lesion especially if malignancy is suspected

For example, the lesion in Figure 2-32 (superficial basal cell skin cancer) could be described as “a 2 cm pink plaque



▲ **Figure 2-32.** Superficial basal cell carcinoma.

with a slightly elevated border and erosions 1 cm lateral to the left earlobe.”

Additional clinical pictures for self-assessment of rash and tumor description can be found at www.LangeClinicalDermatology.com.

REFERENCES

1. Ashton RE. Teaching non-dermatologists to examine the skin: a review of the literature and some recommendations. *Br J Dermatol.* 1995;132(2):221–225. PMID: 7888358.
2. Rudikoff D. Differential diagnosis of round or discoid lesions. *Clin Dermatol.* 2011;29(5):489–497. PMID: 21855723.
3. Sharma A, Lambert PJ, Maghari A, et al. Arcuate, annular, and polycyclic inflammatory and infectious lesions. *Clin Dermatol.* 2011;29(2):140–150. PMID: 21396553.
4. Rebora A. Shape and configuration of skin lesions: grouped herpetiform. *Clin Dermatol.* 2011;29(5):509–510. PMID: 21855726.
5. Roelandts R. The diagnosis of photosensitivity. *Arch Dermatol.* 2000;136(9):1152–1157. PMID: 10987875.

History and Physical Examination of the Skin, Hair, and Nails

Carol Soutor

3

Introduction to Chapter / 15
Selected Key Points for History
of Cutaneous Disorders / 15
Physical Examination of the
Skin, Hair, and Nails / 16

Steps in the Physical
Examination / 17
References / 19

There is no more difficult art to acquire than the art of observation, and for some men it is quite as difficult to record an observation in brief and plain language.

—Sir William Osler, 1903

INTRODUCTION TO CHAPTER

The physical examination was a major tool in the diagnosis of disease prior to the widespread availability of diagnostic laboratory tests and imaging. Many evaluations and diagnoses are now made in the absence of an extensive physical examination and history.^{1,2} Most skin diseases, however, are still diagnosed on the basis of a careful physical examination and history.

Typically the history and physical examination for the skin is done in the same sequence and manner as with any other organ system. In some cases it is helpful to examine the patient after taking only a brief history so the questions for the patient can be more focused.³

SELECTED KEY POINTS FOR HISTORY OF CUTANEOUS DISORDERS

A problem-focused history is sufficient for most common skin disorders. If, the patient has systemic complaints, or if diseases such as lupus erythematosus or vasculitis are suspected, a detailed or comprehensive history may be needed.

History of Present Illness (HPI)

Ask about:

- Initial and subsequent morphology and location(s) of lesions
- Symptoms (eg, itch, pain, tenderness, burning)
- Date of onset and duration
- Severity and factors causing flares
- Medications (including over-the-counter products) used for treatment and response to treatment
- History of previous similar problem.

If the patient's chief complaint is a skin tumor/growth, the following additional questions should be added. With the increasing incidence of skin cancer, these questions could be added in any patient's history:

- What changes have occurred the size and appearance of the lesion?
- Is there a history of spontaneous or trauma-induced bleeding in the lesion?
- Is there a history of sunburns or tanning bed use?
- Is there a history of sunscreen use?

It is also important to determine the patient's Fitzpatrick skin type, as this helps to identify patients at risk for skin cancer (Table 3-1). Patients should be asked if they burn

Table 3-1. Fitzpatrick skin types.

Skin Type	Patient's Response to Initial Sun Exposure
I	Always burns, never tans
II	Usually burns, tans with difficulty
III	Sometimes burns, tans normally
IV	Rarely burns, tans easily
V	Never burns, tans easily
VI	Never burns, tans darkly

Reproduced with permission from Fitzpatrick TB. The validity and practicality of sun-reactive skin types I through VI. *Arch Dermatol.* 1988 Jun;124(6):869-871. Copyright (1988) American Medical Association. All rights reserved.

easily or tan after their initial exposure to sunlight.⁴ The patient's response determines his or her Fitzpatrick skin type. Typically there is a correlation between a patient's Fitzpatrick skin type and his or her skin color.

If indicated, the patient should also be asked about the effect of his or her skin condition on work and social and home life. The Dermatology Life Quality Index at www.dermatology.org.uk has a 10-point questionnaire that can be used to more accurately assess a patient's quality of life concerns. Skindex is another widely used instrument for quality of life evaluations.⁵

Past Medical History

Ask about past and current diseases, personal history of skin cancer, and other skin disorders.

Family History

Ask about a family history of skin cancer, atopy (atopic dermatitis, rhinitis, and asthma), psoriasis, autoimmune diseases, or any disorder similar to the patient's skin problem.

Social History

Ask about patient's occupation, hobbies, and travel.

Review of Systems (ROS)

Ask about fever, chills, fatigue, weight changes, lymphadenopathy, joint pains, wheezing, rhinitis, menstrual history, birth control methods, depression, and anxiety. Additional ROS questions can be asked based on the patient's chief complaint.

Medications

Ask about the use of all systemic and topical medications including over-the-counter medications and supplements.

Allergies and Medication Intolerances

Ask about adverse reaction to medications, foods, and pollens.

PHYSICAL EXAMINATION OF THE SKIN, HAIR, AND NAILS

A careful, systematic examination of the skin, hair, and nails is an essential and cost-effective method for the evaluation and diagnosis of skin disorders. It is important to examine the skin for lesions that are directly related to the chief complaint and for incidental findings, especially for lesions that may be skin cancer. A study done in a dermatology clinic in Florida found that 56.3% of the melanomas that were found during a full-body skin examination were not mentioned in the patient's presenting complaint.⁶ A full-body skin examination can easily be incorporated into the routine examination of other areas of the body.

A limited problem-focused exam may be all that is needed for some chief complaints, such as warts or acne in a child or young adult. However, there are several indications for a total body skin exam. These include:

- Personal history or family history of skin cancer and presence of risk factors for skin cancer (eg, history of severe sunburns or immunocompromised status).
- Presence of a generalized skin rash such as atopic dermatitis or psoriasis.
- An ill patient.
- Diagnosis is unknown or in doubt.

Some clinicians may be hesitant to perform a full-body skin examination because of concerns that a patient will be reluctant. However, a recent study of female veterans showed that most patients prefer a full-body skin examination.⁷ As with any examination, the clinician should explain the reasons for the examination and ask for permission to proceed. Also patients should be asked if they want a room attendant/chaperone present during the examination.⁸

It is important to create a comfortable setting for the patient. The exam room should be warm with the door and window shades closed. The patient should remove all clothing from the area(s) to be examined and be given an examination gown of adequate size and a sheet. Wigs, eye glasses, bandages, and makeup should be removed. Hearing aids and dentures should be removed at the time of the ear and mouth examination.

The following equipment should be available: additional lighting for the exam (eg, pen light, otoscope, or ophthalmoscope), a magnifying lens, gloves, a tongue blade, gauze pad, and a centimeter ruler. Other equipment that may be needed includes a Wood's light (black light), a dermatoscope, bacterial and viral transport media, a #15- scalpel blade, microscope slides, and/or a sterile collection jar for skin scrapings and a camera to document findings. It is also helpful to have a body diagram available for documentation of skin findings.

If the patient cannot get on the exam table because of issues with limited mobility, the upper body skin exam and the anterior surface of the legs can be examined while the patient is seated and the lower body skin exam of the buttocks and posterior legs can be done with patient standing with appropriate support. In a hospital setting, a patient may be unconscious or have limited ability to turn over. However, even in these circumstances it may be necessary to have the nurses turn the patient so the back of the trunk and extremities can be seen. Many common skin conditions such as drug rashes and vasculitis are more prominent in dependent areas of the body.

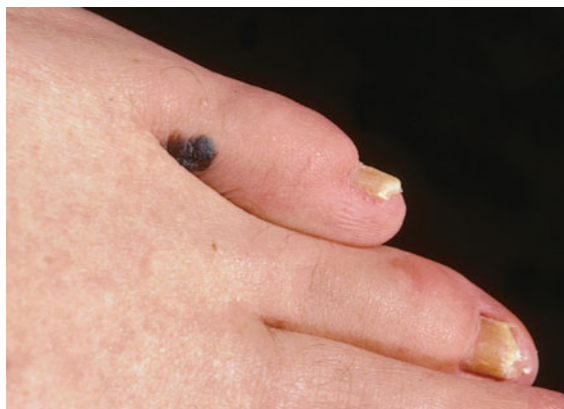A full-body examination should include a systematic examination of the entire surface of the skin, hair, and nails. Many skin diseases present in areas that are not normally examined or not easily seen by the patient, for example, a melanoma in a toe web (Figure 3-1) and a basal cell carcinoma on the posterior surface of the ear (Figure 3-2).

When examining and screening patients for **skin cancer** and **precancerous lesions**, give close attention to the following areas:

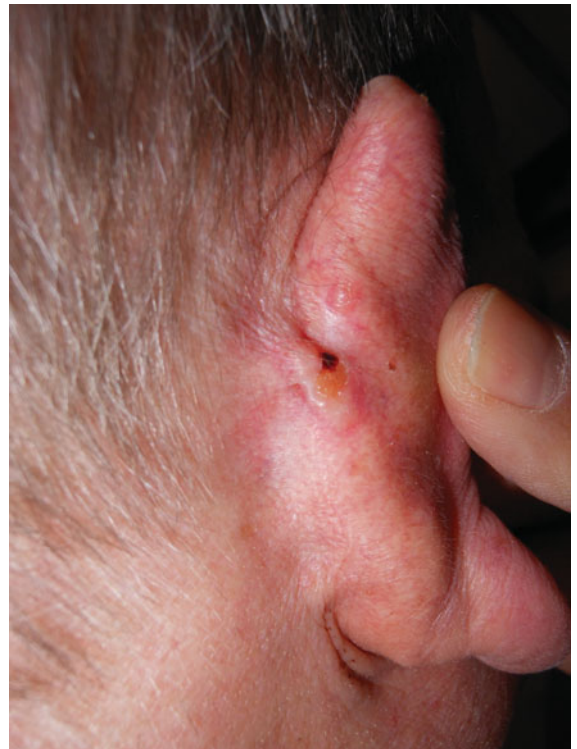- Any areas of chronic sun exposure such as the scalp, face, ears, neck, extensor forearms, dorsal hands, and upper trunk with special attention to:
 - The head and neck, which are the most common sites of basal and squamous cell carcinomas
 - The back, which is the site of almost 40% of melanomas in men⁹
 - The legs, which are the site of over 40% of melanomas in females⁹

When performing skin examinations for **dermatoses (rashes)**:

- Carefully and systematically examine all skin surfaces. Refer to Chapters 30 to 37 for common skin diseases that occur in specific body regions.



▲ **Figure 3-1.** Melanoma in web space between fourth and fifth toes.



▲ **Figure 3-2.** Basal cell carcinoma on the posterior aspect of the helix of the ear.

- Pay close attention to areas that are difficult for patients to see, such as the scalp, back, buttocks, and posterior legs.
- Examine the eyes, ears, nose, and oral cavity. These areas are of particular importance in exanthems, bullous diseases, and connective tissue disorders.

A video demonstration of a full-body skin exam can be found at www.LangeClinicalDermatology.com.

STEPS IN THE PHYSICAL EXAMINATION

Overall Assessment of the Skin

Begin the examination with the patient seated and facing you.

- Scan the skin for variations in skin tone looking for features such as pigment variations, erythema, flushing, jaundice, pallor, or cyanosis.
- Touch the skin lightly to check for abnormal variations in skin temperature and for increased sweating.
- Check the turgor and elasticity of the skin by pinching the skin over the dorsal hand or forearm and quickly releasing it. The skin should quickly return to its normal shape.

Scalp and Hair

- Evaluate hair for any abnormal changes in texture, the presence of fractured hair fibers, and pattern loss.
- Palpate the scalp for tumors, cysts, papules, or plaques.
- Visually inspect the scalp by parting the hair at regularly spaced intervals.

Head, Face, and Neck

- The face is the most common area for basal and squamous cell carcinomas, so careful inspection is important.
- Lightly palpate the face for the presence of gritty, rough keratotic areas that could indicate the presence of actinic keratoses.
- Carefully examine all areas of the face, especially the central portions for any evidence of skin cancers.
- Inspect the neck for evidence of sun damage or tumors and palpate the lymph nodes. Metastatic head and neck carcinomas may involve the anterior and posterior cervical lymph nodes.

Eyes, Nose, Throat, and Ears

- Eyes: Check the sclera for evidence of conjunctival injection or jaundice. Evert the eyelids to examine the palpebral conjunctiva.
- Nose: Examine the nostrils for tumors or erosions.
- Oral cavity: Using a tongue blade and a light source, examine all surfaces of the mucosa looking for erosions, vesicles, white, red, or brown macules, or plaques. Gently grasp the tongue with a gauze pad so that all surfaces can be examined. Examine the teeth and gums for abnormal dentition, cavities, abscesses, or periodontal disease.
- Ears: Lightly palpate the ears for the presence of rough, gritty keratotic areas. Examine all aspects of the ears for tumors with special attention to the postauricular areas where tumors may go undetected.

Arms

- Examine all surfaces with close attention to the elbows and antecubital fossae as these are common sites for psoriasis and atopic dermatitis, respectively.
- The flexor wrists are common sites for dermatitis, scabies, and lichen planus.

Hands

- Examine all surfaces of the hands including the web spaces. The hands are the site of involvement for many common skin disorders such as irritant and allergic contact dermatitis and less common disorders such as connective tissue diseases.

- The dorsal hands are sites for sunlight-related disorders such as actinic keratosis and photodermatoses.

Fingernails

- Examine the nail plate for any abnormalities such as thickening and onycholysis (distal nail plate detached from nail bed), horizontal or vertical defects, and evidence of clubbing.
- Examine the nail bed for pigment or color change or splinter hemorrhages.
- Use a dermatoscope or ophthalmoscope at +12 to +20 to examine the nail bed capillaries which should look like a picket fence. Look for evidence of dilation or any irregularities as these findings may indicate the presence of a connective tissue disorder.

Trunk

The trunk examination in males can be done with the patient remaining in the seated position. Many clinicians perform the trunk examination in females with the patient lying down to allow for appropriate draping.

- Begin with examination of the chest paying special attention to the central upper chest, which is an area of frequent sun exposure and sunburns.
- In females, lift the breasts if needed to examine the inframammary area to check for candida infections or intertrigo.
- Examine the axillae for the presence or absence of hair and any skin lesions. Check for lymphadenopathy if indicated.
- Carefully examine the back. Forty percent of melanomas in men are located on the back, especially the upper central back.

Abdomen

The patient should be asked to lie down for the rest of the examination if he or she has been in the seated position.

- Lift and spread the skin as needed to examine body fold areas in obese patients to check for any evidence of a candida infection or intertrigo.
- Check the inguinal area for lymphadenopathy and signs of a fungal infection.

Genitals

- In males the surface of the scrotum and penis should be carefully examined for skin lesions. If the patient is uncircumcised, the foreskin should be retracted.
- In females the entire vulva should be examined. The vagina should be examined if there are signs of warts or malignancy on the vulva.

Legs

- Examine the anterior and medial surfaces of the legs. Over 40% of melanomas in women are on the legs, so it is important to note pigmented or other suspicious lesions are noted.
- The knees and popliteal surfaces are common areas of involvement in psoriasis and atopic dermatitis, respectively.
- The lower legs should be evaluated for signs of edema, stasis dermatitis, and ulcers.

Feet

- Check the feet for pallor and decreased temperature as this may indicate vascular disease.
- Check the dorsalis pedis and posterior tibial pulses if indicated.
- Carefully examine the feet, especially the plantar surface in diabetic patients for evidence of neuropathic diabetic ulcers.
- Check all toes webs for presence of scales or fissures that could indicate a fungal infection.

Toenails

- As with the fingernails examine the nail plate for any abnormalities such as thickening, onycholysis, horizontal or vertical defects, and ingrowing of the nail plate into the cuticle folds.

Buttocks

At this point in the examination the patient should be asked to turn lying face down on the examination table, so that the buttock area and posterior surface of the legs can

be examined. If this is difficult or uncomfortable for the patient to do, complete the examination with the patient lying on his or her side.

- Examine the gluteal cleft and perianal area. These sites are often affected in inflammatory diseases such as psoriasis and lichen sclerosis, respectively. The perianal area is also a potential site for warts.

Lastly, help patients step off the exam table if needed.

REFERENCES

1. Verghese A, Brady E, Kapur CC, Horwitz RI. The bedside evaluation: ritual and reason. *Ann Intern Med.* 2011; 155(8):550–553. PMID: 22007047.
2. Schechter GP, Blank LL, Godwin HA, LaCombe MA, Novack DH, Rosse WF. Refocusing on history-taking skills during internal medicine training. *Am J Med.* 1996;101(2):210–216. PMID: 8757362.
3. Schwarzenberger K. The essentials of the complete skin examination. *Med Clin North Am.* 1998;82(5):981–999, v. PMID: 9769791.
4. Fitzpatrick TB. The validity and practicality of sun-reactive skin types I through VI. *Arch Dermatol.* 1988;124(6):869–871. PMID: 3377516.
5. Chren M. The Skindex instruments to measure the effects of skin disease on quality of life. *Dermatol Clin.* 2012;30(2): 231–236, xiii. PMID: 22284137.
6. Kantor J, Kantor DE. Routine dermatologist-performed full-body skin examination and early melanoma detection. *Arch Dermatol.* 2009;145(8):873–876. PMID: 19687416.
7. Federman DG, Kravetz JD, Haskell SG, Ma F, Kirsner RS. Full-body skin examinations and the female veteran: prevalence and perspective. *Arch Dermatol.* 2006;142(3):312–316. PMID: 16549706.
8. Gawande A. Naked. *N Engl J Med.* 2005;353(7):645–648. PMID: 16107618.
9. Garbe C, Leiter U. Melanoma epidemiology and trends. *Clin Dermatol.* 2009;27(1):3–9. PMID: 19095149.

4

Diagnostic Procedures

Carol Soutor

Introduction to Chapter / 20
KOH Examinations and Fungal Cultures / 20
Tzanck Test / 20
Scabies Scraping / 22

Wood's Light Examination (Black Light) / 23
Patch Testing / 23
Dermoscopy / 24
References / 24

INTRODUCTION TO CHAPTER

A few simple diagnostic skin procedures such as potassium hydroxide (KOH) examinations, Tzanck smears, and scrapings for scabies can be valuable tests to confirm a clinical diagnosis. However, these tests can have false-positive and false-negative results which are typically due to the following problems:

- Improper site or lesion selection
- Faulty collection technique
- Failure to systematically scan entire specimen
- Artifacts in the specimen

Polymerase chain reaction (PCR) tests are replacing some of the diagnostic tests used in dermatology, but they are more expensive and are not yet widely available in all clinical settings.¹⁻³

KOH EXAMINATIONS AND FUNGAL CULTURES

KOH examinations (Table 4-1) are a cost-effective method for the detection of superficial fungal skin infections. In the hands of an experienced clinician this test has a high level of specificity and sensitivity. However, cotton or nylon fibers from clothing and socks can mimic fungal hyphae, a mosaic artifact created by cell walls can also mimic fungal hyphae, and air bubbles can mimic spores. Some of

these false positives can be reduced by the use of special stains such as Chicago Sky Blue⁴ or Chlorazol Black E. Fungal cultures are another option for detection of fungal infections. Dermatophyte Test Media (DTM), a modified Sabouraud agar contains an indicator dye that turns red within 7 to 14 days in the presence of viable dermatophytes (Figure 4-3).

Indications for a KOH examination or fungal culture include the presence of scaly annular plaques, areas of scale and/or alopecia on the scalp (primarily in pre-adolescents), vesicular lesions on the feet, and thickened nail plates.

A video demonstrating specimen collection techniques and preparation of the specimen for KOH examination can be found at www.LangeClinicalDermatology.com.

TZANCK TEST

The Tzanck test (Table 4-2) is a cost-effective method for the detection of cutaneous herpes simplex and herpes zoster infections;¹ however, there can be significant rates of false positives and false negatives. Therefore, it is being replaced in many clinics and hospitals by PCR tests that have higher rates of sensitivity and specificity.

Indications for a Tzanck test include vesicles on an erythematous base, primarily on the central face, genitals, or in a unilateral dermatome. The Tzanck test can also be

Table 4-1. Potassium hydroxide (KOH) examination for superficial fungal infections.**Equipment needed**

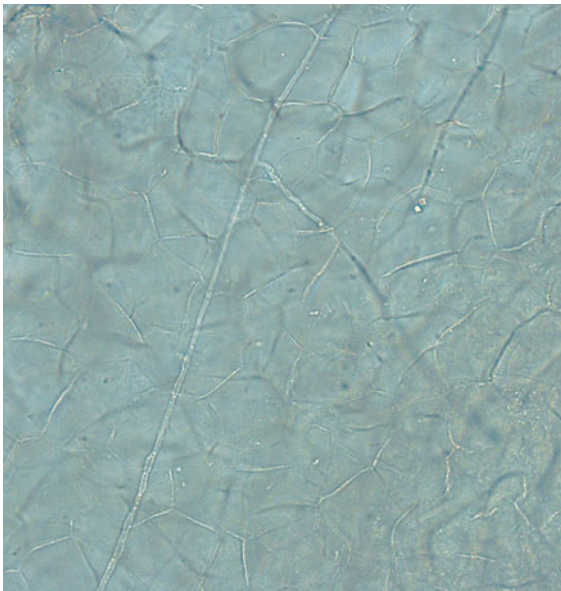
- #15-scalpel blade (for skin and nails), small curette (for nails), tweezers or needle holder, and swab or gauze (for scalp and hair)
- Microscope, glass slides, coverslip, and 20% KOH solution (plain or with dimethylsulfoxide [DMSO] or dyes such as Chlorazol Black E or Chicago Sky Blue)
- If specimens are submitted for culture, a sterile urine container or Petri dish is needed for transport of the specimens to the laboratory. Modified Sabouraud agar, such as Dermatophyte Test Medium (DTM) or Mycosel™ or Mycobiotic™, should be available if specimens will be directly placed onto fungal media

Techniques for specimen collection

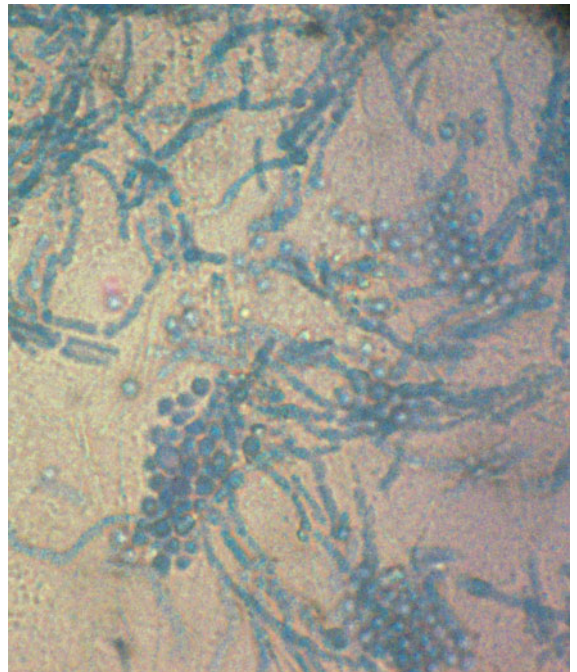
- **Skin:** Select an area of scale from the edge of the lesion. Clean the area with an alcohol pad. Gently scrape off the scale using a #15-scalpel blade onto a glass slide or sterile urine container. If the lesions are vesicular (eg, vesicular tinea pedis), trim off the roof of a vesicle with iris scissors and submit that as a specimen
- **Nails:** Scrape out subungual debris using a small metal skin or ear curette or a #15-scalpel blade
- **Scalp:** Pluck involved hairs with a needle holder or tweezers; cut the hair saving the proximal 1 to 2 cm of the hair fiber and bulb. Scalp scales can be collected for culture using a bacterial culturette swab that has been premoistened by the transport media or sterile gauze or a sterile tooth brush. The involved areas of the scalp should be vigorously rubbed with these devices

Examination of specimens

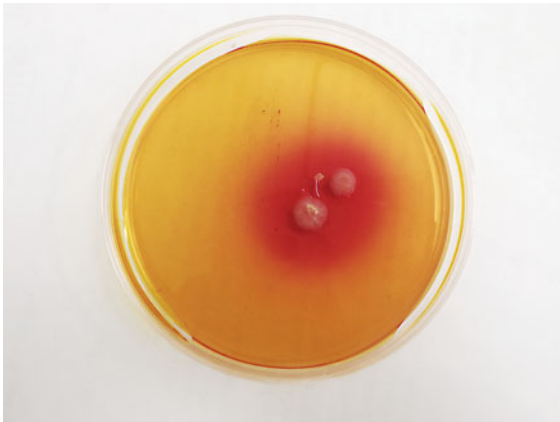- Place the skin scales or proximal hair fibers on a glass slide and cover the specimen with 2 to 4 drops of 20% KOH solution (plain or with DMSO or Chlorazol Black E or Chicago Sky Blue) to partially dissolve keratin. Apply a coverslip
- Let the slide sit for 20 min
- Lower the condenser on the microscope and decrease the intensity of the light
- Scan the entire preparation at low power (10×) magnification looking for branching septate hyphae (Figure 4-1) or pseudohyphae and spores (Figure 4-2). These may be slightly refractile. Switch to high power (40× magnification) to confirm findings
- Be aware of the many causes of false-positive examinations, such as clothing fibers, hair fibers, and the cell walls of keratinocytes, which can look like hyphae. Also, air bubbles and oil droplets which can look like spores



▲ **Figure 4-1.** Potassium hydroxide (KOH) preparation. Fungal hypha with branches.



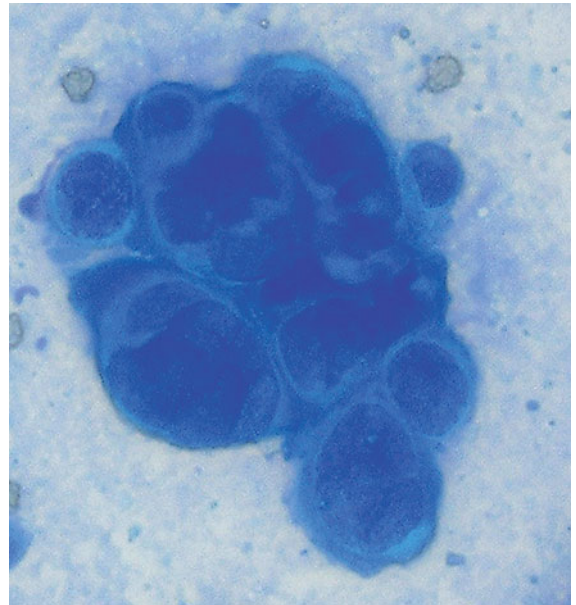
▲ **Figure 4-2.** Chicago Sky Blue and potassium hydroxide (KOH) preparation. Pseudohyphae and spores in tinea versicolor infection.



▲ **Figure 4-3.** Dermatophyte Test Media (DTM). Change in color of medium from yellow to red indicating the presence of a dermatophyte fungus.

done in many other vesicubullous disorders such as pemphigus and bullous impetigo, but the findings may be difficult to interpret.⁵

A video demonstrating specimen collection techniques and preparation of the Tzanck smear can be found at www.LangeClinicalDermatology.com.



▲ **Figure 4-4.** Positive Tzanck smear. Giant, multinucleated keratinocytes in herpes simplex infection.

Table 4-2. Tzanck test.

Equipment needed

- #15-scalpel blade and alcohol pad
- Microscope, glass slide, and coverslip
- Stain for specimen (Giemsa, Wright, toluidine blue, or methylene blue)

Technique for specimen collection

- Select an intact vesicle(s) and swab with an alcohol pad
- If there are no intact blisters, a crusted lesion or an erosion could be sampled
- Remove the roof of the blister or the crust with a #15 blade
- Gently scrape the base of the blister with the #15 blade
- Smear a thin film of the collected contents on to a microscope slide
- Let the slide air dry

Examination of specimen

- Apply 2 to 4 drops of one of the above stains and leave the stain on for the amount of time recommended by the manufacturer
- Rinse the slide with water and allow it to dry completely
- Scan the entire specimen first at low power (10× magnification) looking for cells (keratinocytes) with large nuclei
- Switch to high power (40× magnification) or oil immersion to confirm the presence of multinucleate giant cells (Figure 4-4) which represent infected keratinocytes

SCABIES SCRAPING

A scabies scraping (Table 4-3) can be used to confirm the presence of the scabies mite, which is less than 0.5 mm and invisible to the naked eye. The specimens are examined for

Table 4-3. Scabies scraping.

Equipment needed

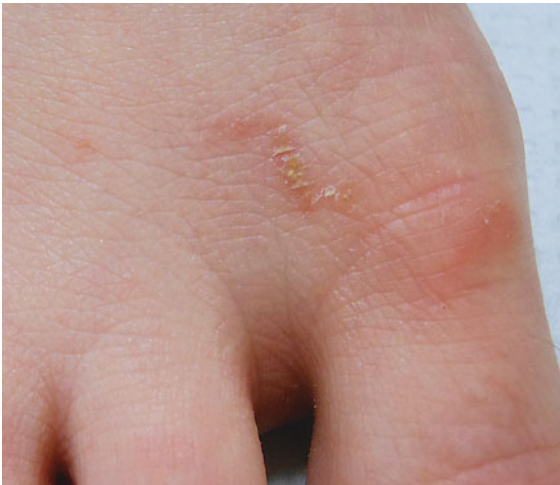- #15-scalpel blade, alcohol pad, and mineral oil
- Microscope, glass slide, and coverslip

Technique for specimen collection

- Select a burrow (Figure 4-5) or papule(s) that have not been excoriated and swab the lesion(s) with an alcohol pad
- Apply a small amount of mineral oil on the scalpel blade or on the lesion(s). This step is optional
- Using firm pressure scrape the burrow or papules with a #15-scalpel blade and smear the contents on a glass slide

Examination of specimens

- Cover the contents with 2 to 4 drops of mineral oil and apply a coverslip. Do not use KOH as this may dissolve the mite's fecal material
- Scan the entire specimen at low power (10×) for the presence of mites, eggs, and/or fecal material
- If needed, switch to high power (40× magnification) to confirm findings



▲ **Figure 4-5.** Scabies burrow. Thin white line above toe web.

the mite (Figure 13-6), eggs, and/or fecal material (scybala) (Figure 13-7). If these are present in the preparation, they can be easily detected. False negatives can occur because there are typically few mites present in scabies infestations and the chance of finding them in any one lesion is low, with the exception of burrows (Figure 4-5) which are short, wavy lines typically seen on the wrists, finger webs, feet, and penis.⁶

The indications for scabies scraping include intensely pruritic papules in patients of any age on the hands, feet, extensor extremities, or genitals.

WOOD'S LIGHT EXAMINATION (BLACK LIGHT)

A Wood's light is a handheld mercury vapor bulb (ultraviolet light 360 nm) which is helpful in the diagnosis of several conditions (Table 4-4).⁷ The examination should take place in a dark room with the Wood's light held about 10 cm from the skin. Patients should not look directly into the light during the examination. A Wood's light examination is most helpful in pigment disorders and certain infections. Lesions with increased melanin in the epidermis appear darker than surrounding skin. In contrast, lesions with increased melanin confined to the dermis do not appear darker than surrounding skin. A Wood's light examination also can be used to detect porphyrins in the urine.

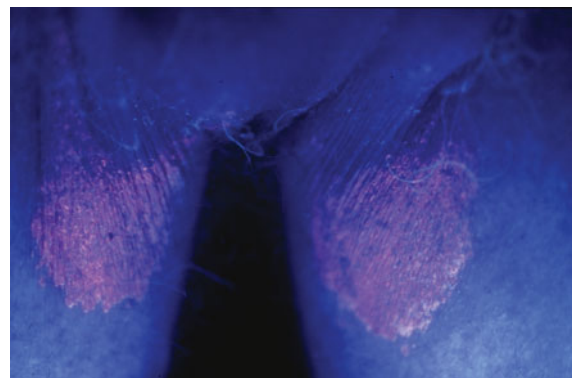
PATCH TESTING

Skin patch testing is used to detect allergens responsible for allergic contact dermatitis which is a type IV delayed hypersensitivity reaction. The Thin-layer Rapid Use Epicutaneous (TRUE) Test (SmartPractice, Phoenix, Arizona; Mekos Laboratories A/S, Hillerød, Denmark) is a

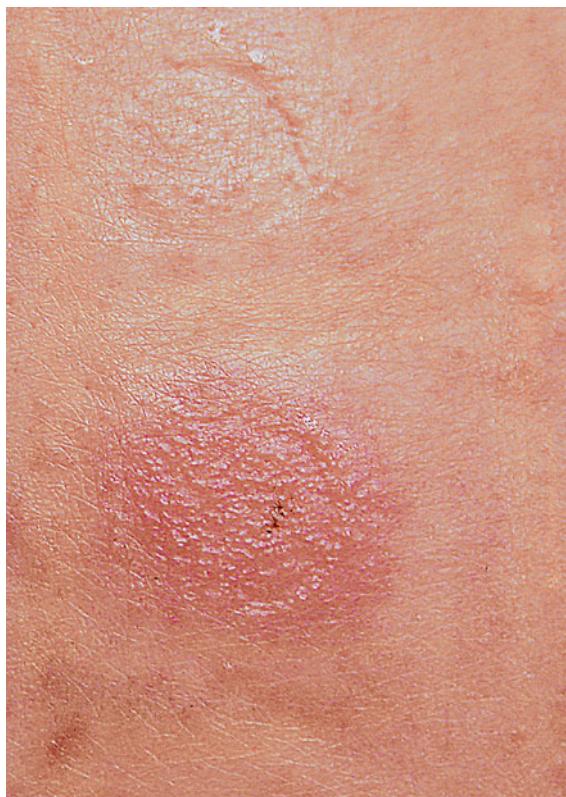Table 4-4. Wood's light findings in selected skin disorders.

Disease	Color with Wood's Light Examination
Vitiligo, postinflammatory depigmentation, halo nevus, tuberous sclerosis (ash leaf macules)	Bright white to off-white
Melasma (melanin in epidermis), lentigo, freckles, café au lait spots	Darker than surrounding skin
Melasma (melanin in dermis), Mongolian spot	No change from surrounding skin
Tinea capitis due to <i>Microsporum</i> species	Blue-green
Tinea (pityrosporum) versicolor	Yellow-white or copper-orange
Pityrosporum folliculitis	Blue-white around hair follicles
Erythrasma (Figure 4-6)	Coral red (porphyrins produced by <i>Corynebacterium minutissimum</i>)
<i>Pseudomonas</i>	Green (pyocyanin)
Porphyrins in urine, blood, and teeth	Red-pink

commercially available patch test kit that is Food and Drug Administration (FDA) approved.⁸ It consists of 36 common allergens and allergen mixes in a gel coating on polyester sheeting. The tests are placed on the patient's back and taped in place and left on for 48 hours. The results are read



▲ **Figure 4-6.** Erythrasma in medial and anterior thighs. Coral red fluorescence with Wood's light examination due to porphyrins produced by *Corynebacterium minutissimum*.



▲ **Figure 4-7.** Positive reaction to balsam of Peru in a patch test. Erythema and papules present at 48 hours after application of patch tests.

at 48, 72, and 96 hours after application. The presence of erythema, papules, and/or vesicles indicates a positive test (Figure 4-7). However, clinical correlation is needed to confirm that positive reactions are indeed the cause of the patient's dermatitis.

DERMOSCOPY

A dermatoscope is a handheld device with a 10× lens, light-emitting diode (LED) lighting, and polarizing filters that allow for visualization of skin structures in the epidermis and papillary dermis such as melanin and blood vessels. It is most commonly used to diagnose melanocytic lesions (eg, benign nevi, atypical nevi, and melanoma) (Figures 18-5 and 18-6), basal and squamous cell carcinomas, and benign tumors (eg, angiomas, seborrheic keratoses, and sebaceous gland hyperplasia).⁹ The first step in dermoscopy of tumors is distinguishing melanocytic tumors from nonmelanocytic tumors and the second step involves reaching a specific diagnosis using various algorithms.^{10,11} The 3-point algorithm for melanocytic

tumors is discussed on page 165 in Chapter 18. Studies have shown that even a 1-day training course in dermoscopy improves primary care clinicians' detection of skin cancers.¹² Training courses are regularly offered by organizations such as the International Dermoscopy Society and the American Academy of Dermatology.

Dermoscopy is also useful in the diagnosis of several other cutaneous disorders including scabies, lice, hair and scalp disorders, and several inflammatory disorders (eg, psoriasis and lichen planus).¹³ It also can be used to detect nail fold capillary abnormalities in connective tissue diseases.¹⁴

REFERENCES

1. Ruocco E, Baroni A, Donnarumma G, Ruocco V. Diagnostic procedures in dermatology. *Clin Dermatol.* 2011;29(5):548–556. PMID: 21855731.
2. Katano H, Kano M, Nakamura T, Kanno T, Asanuma H, Sata T. A novel real-time PCR system for simultaneous detection of human viruses in clinical samples from patients with uncertain diagnoses. *J Med Virol.* 2011;83(2):322–330. PMID: 21181930.
3. Jensen RH, Arendrup MC. Molecular diagnosis of dermatophyte infections. *Curr Opin Infect Dis.* 2012;25(2):126–134. PMID: 22248981.
4. Lim CS, Lim S. New contrast stain for the rapid diagnosis of onychomycosis. *Arch Dermatol.* 2011;147(8):981–982. PMID: 21844463.
5. Durdu M, Baba M, Sekin D. The value of Tzanck smear test in diagnosis of erosive, vesicular, bullous, and pustular skin lesions. *J Am Acad Dermatol.* 2008;59(6):958–964. PMID: 18929431.
6. Chosidow O. Clinical practices. Scabies. *N Engl J Med.* 2006;354(16):1718–1727. PMID: 16625010.
7. Asawanonda P, Taylor CR. Wood's light in dermatology. *Int J Dermatol.* 1999;38(11):801–807. PMID: 10583611.
8. Militello G, Woo DK, Kantor J, et al. The utility of the TRUE test in a private practice setting. *Dermatitis.* 2006;17(2):77–84. PMID: 16956457.
9. Hirokawa D, Lee JB. Dermatoscopy: an overview of subsurface morphology. *Clin Dermatol.* 2011;29(5):557–565. PMID: 21855732.
10. Braun RP, Rabinovitz HS, Oliviero M, Kopf AW, Saurat J. Dermoscopy of pigmented skin lesions. *J Am Acad Dermatol.* 2005;52(1):109–121. PMID: 15627088.
11. Campos-do-Carmo G, Ramos-e-Silva M. Dermoscopy: basic concepts. *Int J Dermatol.* 2008;47(7):712–719. PMID: 18613881.
12. Argenziano G, Puig S, Zalaudek IS, et al. Dermoscopy improves accuracy of primary care physicians to triage lesions suggestive of skin cancer. *J Clin Oncol.* 2006;24(12):1877–1882. PMID: 16622262.
13. Moscarella E, Caricala C, Zalaudek I, Argenziano G. The dermatoscope as the dermatologist's stethoscope. *Practical Dermatol.* 2010;6(7):34–38.
14. Bergman R, Sharony L, Schapira D, Nahir MA, Balbir Gurman A. The handheld dermatoscope as a nail-fold capillaroscopic instrument. *Arch Dermatol.* 2003;139(8):1027–1030. PMID: 12925391.

Principles of Diagnosis

Carol Soutor

5

Introduction to Chapter / 25
Pattern Recognition / 25
Analytic Method / 25
The Primary Lesion / 26
Broad Diagnostic Categories / 27

Laboratory Confirmation of Diagnosis / 28
Cutaneous Mimics / 29
Cutaneous Diseases with High Morbidity / 29
References / 30

INTRODUCTION TO CHAPTER

Diagnosis of cutaneous disorders can be done using 2 different methods: (1) visual pattern recognition, a rapid, intuitive, nonanalytic method, or (2) an analytic method using algorithms and decision trees. In actual practice most clinicians use both methods.^{1,2}

PATTERN RECOGNITION

Clinicians utilizing pattern recognition rapidly identify the cutaneous findings and compare them with a set of images stored in their long-term memory (sometimes called the “blink” diagnosis).^{2,3} These images are typically from clinical findings seen in previous patients or from pictures in textbooks and other sources. Pattern recognition is more effective in common disorders with typical presentations and in the hands of more experienced clinicians. However, studies have shown that in EKG interpretation⁴ and in dermatoscopy,⁵ it can be an effective diagnostic strategy even for less experienced clinicians.

Human beings and all animals are hardwired for visual pattern recognition. Otherwise we could not easily and quickly identify each other, objects, or predators. We know that pattern recognition can be learned, but can it be taught? One of the problems is that much of visual pattern recognition occurs subconsciously.³ An experienced clinician can usually tell a student what cutaneous findings led

to his or her diagnosis, but there may be other subtle, but important factors, not easily elucidated, that also contributed to the diagnosis.

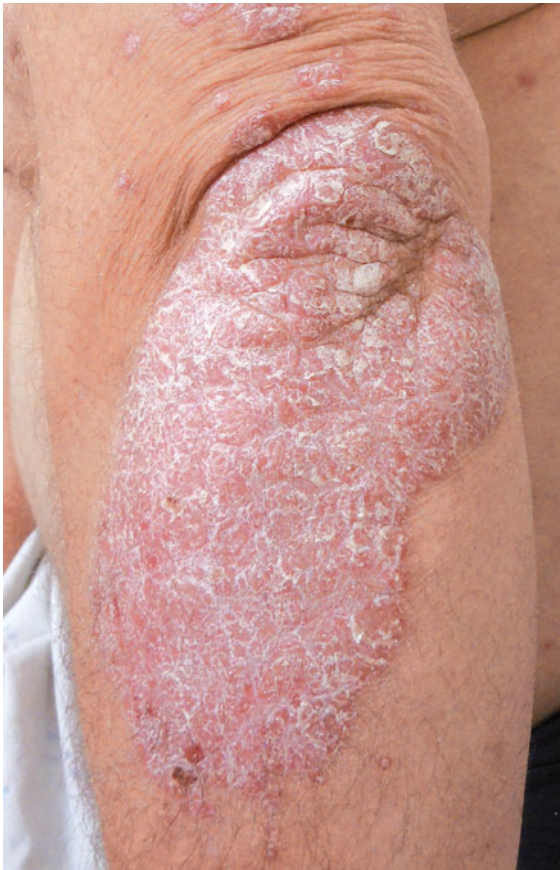The most common features of skin disorders used in pattern recognition include the following:

- The morphology of the primary lesion, its surface changes, color, and size
- Location of lesions
- Configuration of lesions

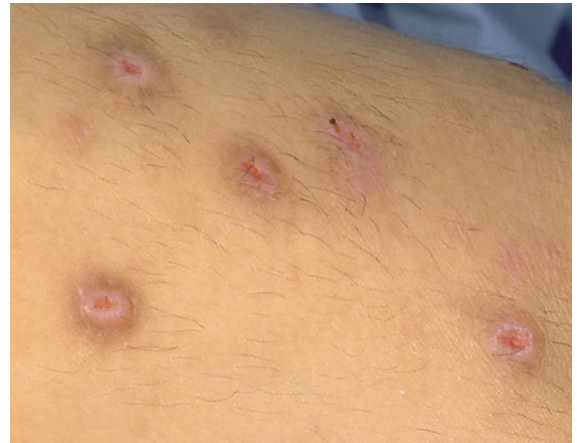Many common skin disorders have characteristic features. For example, pink plaques with silvery scale on knees and elbows are characteristic for psoriasis (Figure 5-1). These patterns are covered in more detail in Section Two of this book.

ANALYTIC METHOD

An analytic method for diagnosis is slower and more methodical. It utilizes a step by step evaluation of the patient’s history, the physical examination findings, and results of diagnostic tests (eg, potassium hydroxide [KOH] examination and skin biopsies).^{2,3} These are used as the basis for searches in differential diagnosis lists or decision tree algorithms. An analytic method is helpful in complex cases with atypical or numerous cutaneous findings and systemic complaints. Section Three of this book



▲ **Figure 5-1.** Psoriasis. Pink, well-demarcated plaque with silvery scale on elbow is a characteristic finding.



▲ **Figure 5-2.** Excoriations altering the morphology of papules on arm.

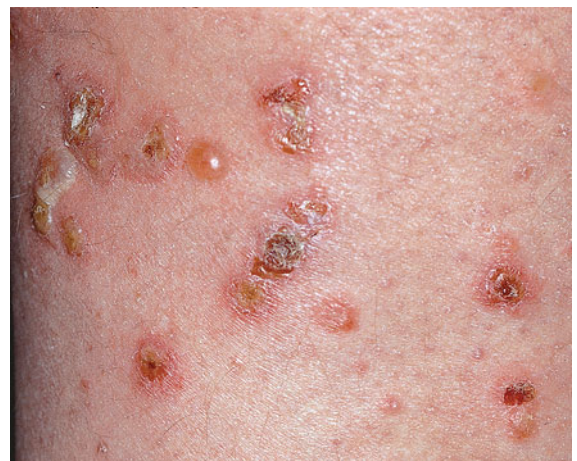- Postinflammatory hyperpigmentation and hypopigmentation may obscure the primary lesion (Figure 5-4).
- The examination may take place too early or too late in an evolving skin disease. For instance, many skin rashes present with pink macules in the first 1 to 2 days and then evolve into their more characteristic findings. As an example, herpes zoster could evolve from a pink macule/patch → pink plaque → plaque with vesicles → bullae → crusts → erosions → scars (Figure 5-5).

contains lists of differential diagnoses of skin diseases in various body regions based on the patient's history, lesion morphology, and laboratory results. It also contains differential diagnosis lists for purpura, pruritus, rash and fever, and leg ulcers.

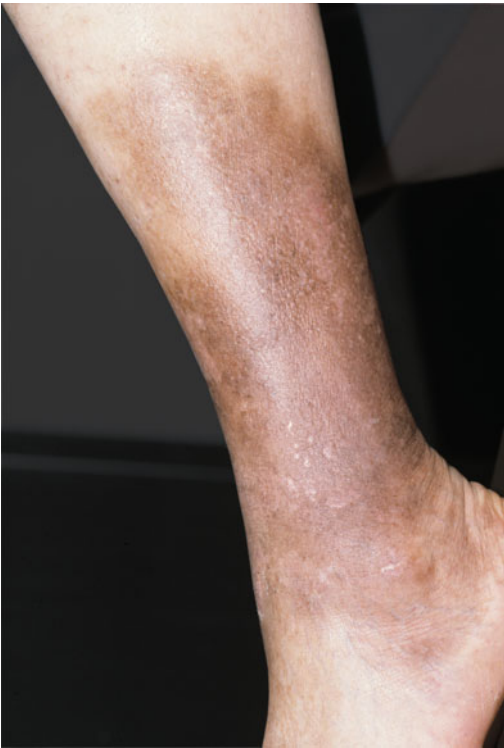THE PRIMARY LESION

Both strategies for diagnosis rely heavily on identification and classification of the primary lesion(s). However, there are several pitfalls in the identification of primary lesions. These include:

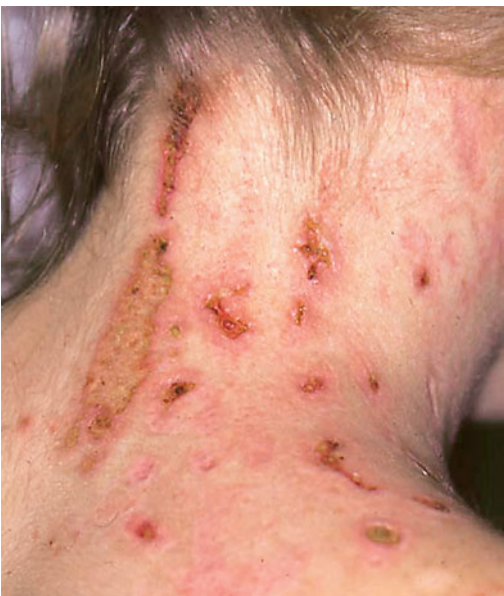- Excoriations may alter or partially destroy the primary lesions (Figure 5-2).
- Vesicles, bullae, and pustules may easily break, leaving only erosions or erythema (Figure 5-3). Also, vesicles may develop into pustules as in some case of herpes simplex and zoster.



▲ **Figure 5-3.** Bullous pemphigoid. An example of vesicles breaking to form crusts and erosions.



▲ **Figure 5-4.** Postinflammatory hyperpigmentation partially obscuring the erythematous plaques of stasis dermatitis.



▲ **Figure 5-5.** Herpes zoster. Crust, erosions, and scars on neck representing the evolution of the lesions.

- Treatment may alter the skin findings, for example, the use of a topical antifungal cream for tinea corporis may remove the characteristic scale or make it difficult to find fungal hyphae on a KOH examination.
- Lastly, many common diseases present with multiple types of primary lesions. For example, atopic dermatitis may present with macules, patches, papules, plaques, vesicles, and pustules and with surface changes that may include scale, crust, lichenification, fissures, erosions, and excoriations.

BROAD DIAGNOSTIC CATEGORIES

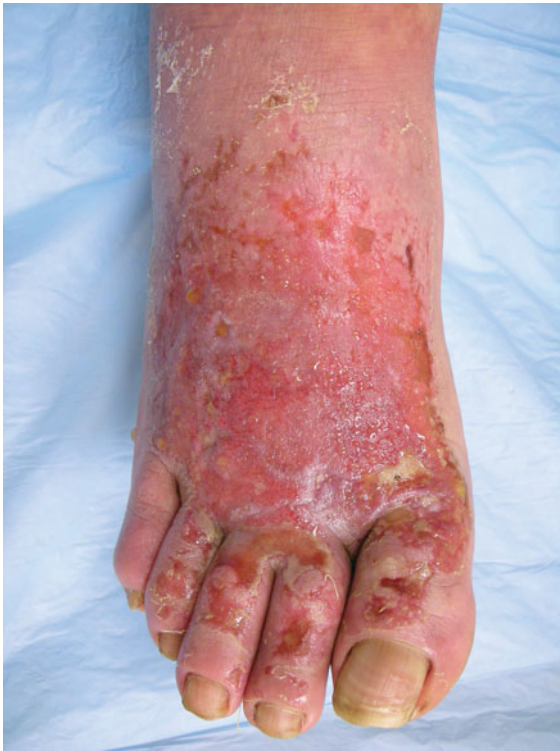Identification of the primary lesion(s) helps to categorize rashes. It is important to first consider the broad categories of disease in the differential diagnosis before making a specific diagnosis. The common skin rashes diseases covered in this textbook fall into 4 broad categories.

- Dermatitis
- Papulosquamous diseases
- Urticaria and drug rashes
- Infections (fungal, bacterial, viral)

Most errors in the diagnosis of rashes are made between inflammatory diseases and infectious diseases, for example, misdiagnosing dermatitis as a fungal infection (Table 5-1).⁶ Misdiagnosis is especially problematic in these cases, because the diseases in these 2 categories have different

Table 5-1. Common inflammatory and infectious skin diseases.

Inflammatory disorders
Dermatitis <ul style="list-style-type: none"> • Allergic and irritant contact dermatitis • Atopic dermatitis • Dyshidrotic dermatitis • Lichen simplex chronicus • Nummular dermatitis
Papulosquamous <ul style="list-style-type: none"> • Psoriasis • Seborrheic dermatitis • Lichen planus • Pityriasis rosea
Urticaria and drug rash <ul style="list-style-type: none"> • Urticaria • Morbilliform (maculopapular) drug rash
Diseases associated with microbes <ul style="list-style-type: none"> • Fungal infections: Tinea (capitis, corporis, manuum, pedis, cruris, versicolor) and <i>Candida</i> • Bacterial infections: Impetigo, boils, cellulitis • Viral: Herpes simplex and zoster



▲ **Figure 5-6.** Cellulitis in area of allergic contact dermatitis on dorsal foot.

treatments. However, it is important to note that there are some clinical cases in which an inflammatory disease and an infectious process coexist. The following are some examples:

- Atopic dermatitis and staphylococcal skin infection or herpes simplex
- Contact dermatitis and bacterial infection (Figure 5-6)
- Stasis dermatitis and cellulitis
- Dermatitis and molluscum contagiosum
- Dyshidrotic dermatitis and tinea pedis

LABORATORY CONFIRMATION OF DIAGNOSIS

A study of primary care physicians' errors found that 68% of misdiagnoses could be eliminated by 3 simple diagnostic tests: (1) KOH examination of scale for fungus, (2) Tzanck smear or viral culture for herpes, and (3) skin scraping for scabies.⁶ There are several other laboratory and diagnostic studies such as bacterial cultures and skin biopsies that can be done to confirm diagnoses. However,

Table 5-2. Common dermatoses that mimic each other and their high morbidity mimics.

Location	Common Dermatoses that Mimic Each Other	High Morbidity Mimics
Scalp	Tinea capitis Seborrheic dermatitis Contact dermatitis	Dermatomyositis
Face	Acne Rosacea Dermatitis (perioral, seborrheic)	Malar rash (butterfly) of systemic lupus erythematosus
Oral cavity	Aphthous ulcers Herpes simplex	Behçet disease
Hands	Contact dermatitis Tinea manuum	Dermatomyositis Systemic lupus erythematosus Porphyria cutanea tarda
Feet	Tinea pedis Allergic contact dermatitis	Cellulitis
Nails	Fungal infection Psoriasis Trauma	Nail changes due to systemic diseases
Genitals	Herpes simplex	Chancre (lesion of primary syphilis) Behçet disease
Multiple locations	Drug rash Viral exanthem	Early stages of Stevens-Johnson syndrome/toxic epidermal necrolysis Staphylococcal scalded skin syndrome Toxic shock syndrome
	Tinea corporis Nummular dermatitis Granuloma annulare	Subacute cutaneous lupus erythematosus
	Dermatitis Psoriasis	Cutaneous T-cell lymphoma
	Pityriasis rosea Guttate psoriasis Lichen planus	Secondary syphilis
	Urticaria Dermatitis	Prebullous pemphigoid
	Acute allergic contact dermatitis	Pemphigoid Pemphigus
	Dermatitis Scabies	Dermatitis herpetiformis

false-positive and false-negative results can occur due to errors in collection of specimens and in interpretation of the microscopic findings. Therefore, clinical correlation is important. The following are examples of laboratory tests

Table 5-3. Benign tumors and dermatoses and their malignant mimics.

Benign Tumors and Dermatoses that Mimic Each Other	Malignant Mimics
Seborrheic keratosis Benign nevus Atypical nevus	Melanoma Pigmented basal cell carcinoma
Dermatitis Psoriasis	In situ basal cell carcinoma–Bowen disease (squamous cell carcinoma in situ)
Viral wart Seborrheic keratosis	Squamous cell carcinoma
Dermatitis	Paget disease of the nipple or extramammary Paget disease
Genital lichen sclerosis Lichen planus Dermatitis	Vulvar intraepithelial neoplasia (VIN) Erythroplasia of Queyrat (in situ squamous cell carcinoma)
Oral candidiasis Lichen planus	Oral squamous cell carcinoma

that can be used to confirm diagnoses in various clinical findings:⁷

- **KOH examination and/or fungal cultures:** Scaling with or without alopecia in preadolescent children, annular scaly plaques at any age, scaling or vesicles on feet, hands, or groin area or body folds, and dystrophy of nails.
- **Tzanck smear, polymerase chain reaction (PCR), or viral culture for herpes simplex or varicella zoster virus:** Vesicles on an erythematous base, especially on face, genitals, or a unilateral dermatome.
- **Scabies scraping:** Intensely pruritic papules or vesicles and/or burrows in patients of any age, especially on the hands, feet, extensor extremities, or genitals.
- **Bacterial cultures:** Cysts or nodules with purulent drainage and crusted plaques surrounded by erythema.
- **Blood studies:** These are generally not helpful in the diagnosis of common skin disorders, but are helpful in connective tissue disorders. Indirect immunofluorescence done on serum is useful in the diagnosis of pemphigus and pemphigoid.
- **Skin biopsies:** Histopathologic examination of skin biopsy specimens is useful in the diagnosis of benign and malignant tumors. It is also helpful in the diagnosis of psoriasis, lichen planus, pemphigoid, pemphigus, vasculitis, connective tissue disorders, and many scalp disorders. It is also useful in the diagnosis of fungal infections, but special stains such as the periodic acid Schiff stain (PAS) need to be employed to visualize the fungal elements. Skin biopsies are generally not useful

in differentiating between various forms of dermatitis. The diagnostic accuracy of pathology reports is enhanced by the inclusion of detailed history and clinical findings on the biopsy requisition form.^{8,9}

Skin biopsies for direct immunofluorescence are diagnostic in pemphigoid, pemphigus, dermatitis herpetiformis, and cutaneous lupus erythematosus.

There can be differences in interpretation between some pathologists, so as with any laboratory test, clinical correlation is needed.¹⁰ Chapter 7 has more details on skin biopsy procedures.

CUTANEOUS MIMICS

Many common diseases that are in different broad diagnostic categories may not only mimic each other but also closely resemble skin findings in systemic diseases or diseases with high morbidity (Table 5-2). There are also several skin cancers that are very similar in appearance to benign conditions (Table 5-3).

CUTANEOUS DISEASES WITH HIGH MORBIDITY

“Could this be a serious disease?” is a common concern in medicine. Most skin disorders that have high morbidity or are associated with systemic disease have features that should alert a clinician that he or she may be dealing with a serious disorder. Table 5-4 lists some of the clinical findings that could indicate a serious disease.

Table 5-4. Clinical presentations of diseases with high morbidity.

Clinical Presentations	Diseases with High Morbidity Potential
Persistent, red plaques that only partially respond to steroids	Cutaneous T-cell lymphoma, connective tissue disorders
Red plaques primarily in sun-exposed areas in patient with systemic complaints	Lupus erythematosus, dermatomyositis
Urticaria-like lesions that last longer than 24 h	Urticarial vasculitis, prebullous pemphigoid
Urticaria and/or angioedema in a patient with acute breathing difficulty (stridor)	Laryngeal edema, anaphylaxis
Widespread vesicles or bullae, especially if mucosa is involved	Pemphigoid, pemphigus, Stevens-Johnson syndrome/toxic epidermal necrolysis
Widespread areas of red painful skin	Stevens-Johnson/toxic epidermal necrolysis, staphylococcal scalded skin syndrome
Widespread areas of peeling (desquamation) leaving areas of denuded skin	Stevens-Johnson syndrome/toxic epidermal necrolysis, staphylococcal scalded skin syndrome, toxic shock syndrome, exfoliative erythroderma
Localized area of red, tender, warm skin	Cellulitis
Dusky, red to blue, painful, edematous area; may have hemorrhagic bullae or crepitus	Necrotizing fasciitis
Necrosis of the skin with ulceration and/or eschar	Occlusion or inflammation of blood vessels from arteriosclerosis, localized infection, sepsis, hematologic diseases, paraproteinemia, calciphylaxis
Red or purple papules or macules that do not blanch	Purpura
Purple or red papules primarily in children with fever and neurological symptoms	Rocky Mountain spotted fever, meningococcemia
Rash and fever with multiple systemic complaints and findings	Exanthems due to certain infections
Widespread persistent pruritus in patient with no primary skin disease	Liver, kidney, and myeloproliferative disease

REFERENCES

- Kulatunga Moruzi C, Brooks LR, Norman GR. Coordination of analytic and similarity-based processing strategies and expertise in dermatological diagnosis. *Teach Learn Med.* 2001;13(2):110–116. PMID: 11302031.
- Pelaccia T, Tardif J, Tribby E, Charlin B. An analysis of clinical reasoning through a recent and comprehensive approach: the dual-process theory. *Med Educ Online.* 2011;16. PMID: 21430797.
- Croskerry P. A universal model of diagnostic reasoning. *Acad Med.* 2009;84(8):1022–1028. PMID: 19638766.
- Ark TK, Brooks LR, Eva KW. Giving learners the best of both worlds: do clinical teachers need to guard against teaching pattern recognition to novices? *Acad Med.* 2006;81(4):405–409. PMID: 16565197.
- Carli P, Quericioli E, Sestini S, et al. Pattern analysis, not simplified algorithms, is the most reliable method for teaching dermoscopy for melanoma diagnosis to residents in dermatology. *Br J Dermatol.* 2003;148(5):981–984. PMID: 12786829.
- Pariser RJ, Pariser DM. Primary care physicians' errors in handling cutaneous disorders. *J Am Acad Dermatol.* 1987;17(2):239–245. PMID: 3624563.
- Ruocco E, Baroni A, Donnarumma G, Ruocco V. Diagnostic procedures in dermatology. *Clin Dermatol.* 2011;29(5):548–556. PMID: 21855731.
- Rajaratnam R, Smith AG, Biswas A, Stephens M. The value of skin biopsy in inflammatory dermatoses. *Am J Dermatopathol.* 2009;31(4):350–353. PMID: 19461238.
- Aslan C, Gktay F, Mansur AT, Aydingöz IE, Güneş P, Ekmekçi TR. Clinicopathological consistency in skin disorders: a retrospective study of 3949 pathological reports. *J Am Acad Dermatol.* 2012;66(3):393–400. PMID: 22142653.
- Heal CF, Weedon D, Raasch BA, Hill BT, Buettner PG. Agreement between histological diagnosis of skin lesions by histopathologists and dermatologist-histopathologist. *Int J Dermatol.* 2009;48(12):1366–1369. PMID: 19930494.

Principles of Management

Carol Soutor

6

Introduction to Chapter / 31

Vehicle Selection / 31

Quantity to Dispense / 31

Cost Considerations / 32

Topical Steroids / 32

Systemic Steroids / 33

Topical Calcineurin Inhibitors / 33

Moisturizers / 34

Therapeutic Baths / 34

Wet Dressings / 35

Topical Antipruritic Medications / 35

Oral Antihistamines / 35

Antifungal Medications / 35

Antiviral Medications / 35

Acne and Rosacea Medications / 35

Antibiotics / 35

Medications for Scabies and Lice / 35

Sunscreens and Sun Protective Clothing / 35

Patient Compliance/Adherence Issues / 36

Quality of Life and Mental

Health Issues / 36

Web Sites / 37

References / 37

INTRODUCTION TO CHAPTER

Most common skin disorders can be treated with a formulary of cost-effective, widely available topical and oral products. Topical medications are effective for most common skin disorders and they have fewer serious adverse side effects when compared with their oral counterparts. Oral medications may be needed if a skin disease is widespread or more severe.

There are several things to consider before prescribing a topical product such as the active ingredient, the vehicle, and the quantity to dispense.

VEHICLE SELECTION

The vehicle of a topical product may be as important as the active ingredient. Table 6-1 lists commonly used vehicles. “If it’s dry, wet it and if it is wet, dry it” is still a good general guideline for treatment of common dermatoses. Most skin disorders, especially the chronic dermatoses (eg, psoriasis, chronic contact dermatitis), are “dry”; therefore, ointments

are preferred as they are more moisturizing. Also, ointments do not contain preservatives that can cause stinging and burning. The main problem with ointments, is that they are greasy and can stain clothing and bedding. Creams are a good option for the “wet” dermatoses, such as acute contact dermatitis, and other blistering or exudative dermatoses. They are also a good option for adults who do not want to use an ointment. However, some cream preparations are slightly drying and preservatives and other ingredients in the vehicle may sting or burn.

QUANTITY TO DISPENSE

The quantity of medication to be dispensed and the amount of medication that is needed per application are important considerations in prescription medications, especially topical steroids and calcineurin inhibitors.

There are a few general rules that can be used to estimate the quantity of topical medication a patient will need; however, the required amount may vary a great deal depending

Table 6-1. Vehicles for topical products arranged from most moisturizing to most drying.

Vehicle	Formulation	Indications
Ointment	80% oil and 20% or less water, petroleum jelly base, greasy, no preservatives, effective at moisturizing skin; may stain paper, clothing, and bedding	Best vehicle for most “dry,” thick, lichenified or fissured dermatoses (eg, atopic dermatitis and psoriasis), does not sting
Cream	50% oil and 50% water emulsion, moderate moisturizing effects, some residue, contains preservatives	Best vehicle for acute dermatitis and in cases in which ointments are not tolerated, for example, hot, humid climate, intertriginous skin
Lotion	Similar to cream with more water and lower viscosity, spreads easily, minimal residue, contains preservatives	Used in many moisturizers and sunscreens, cosmetically acceptable
Gel	Transparent base that liquefies on contact with skin, residue minimal, but may be shiny, drying	Best vehicle for facial and hair-bearing areas, cosmetically acceptable
Solution	Low viscosity, transparent, base of water and/or alcohol, very drying, evaporates quickly leaving no residue	Best vehicle for scalp dermatoses, too drying and irritating for use on other body areas
Foam	Leaves minimal residue, may be drying	Usually used in hair-bearing areas
Powder	Talc based, drying, decreases frictional forces in intertriginous areas	Used in body fold areas and feet

on the age of the patient, body size, type of vehicle, and how thickly the product is applied. In general:

- Approximately 30 g of cream will cover the entire adult body for 1 application.
- As an approximation, infants will need one fifth of the adult quantity, children two fifths of the adult quantity, and adolescents two thirds of the adult quantity.¹

It is also important to give instructions to patients on what quantity of medication they need to apply per application. The fingertip unit (FTU) is a commonly used measurement.² A FTU is the amount of medication dispensed (squeezed) from a tube with a 5 mm nozzle that covers the skin of the index finger from the tip to the distal crease (Figure 6-1). One FTU is equal to approximately 0.5 g. One FTU will cover an area of skin equivalent to the area covered

by 2 hands. Another option for estimating larger quantities is the use of a standardized kitchen tablespoon. One tablespoon holds slightly less than 15 g of a cream or ointment which will cover approximately half of an adult body.

Topical medications are usually packaged in increments of 15 g, most commonly in tubes and bottle sizes of 15, 30, 45, and 60 g. Many generic topical steroid medications can be dispensed in jars of larger sizes, typically at a lower cost per gram.

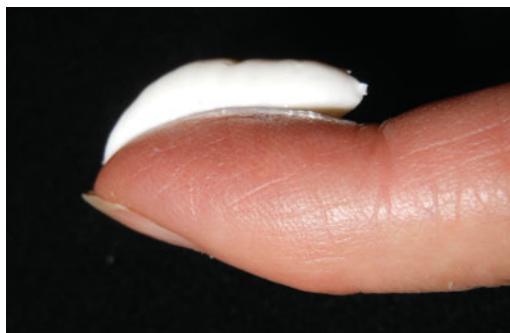COST CONSIDERATIONS

The cost of medications is an increasingly important issue and may affect a patient's decisions about the purchase and use of a prescription medication. There are generic forms of most of the commonly used topical medications. A study published in 2012 reported that in the United States, the average generic dermatologic medication was \$55.84 compared with \$115.72 for brand name products resulting in a cost saving of almost 55%.³

There were concerns about the quality of topical generic medications several years ago, but recent studies on selected products have shown that they are equivalent in efficacy to brand name medications.³ There are, however, some products such as emollient steroid creams, augmented steroids, combination medications, and certain vehicle preparations that are available only as branded products.

TOPICAL STEROIDS

Topical steroids are used for a wide range of inflammatory skin disorders such as dermatitis and papulosquamous skin disorders. They have anti-inflammatory, antiproliferative,



▲ **Figure 6-1.** Fingertip unit. Amount of medication dispensed from tube from the tip of the index finger to the distal crease is 0.5 g.

Table 6-2. Class and potency rank or selected topical steroid medications.

Class	Potency	Generic Name	Formulations
1	Super potent	Clobetasol propionate	Cream, ointment, gel, solution, foam, shampoo 0.05%
2	High potency	Desoximetasone Fluocinonide	Cream, ointment 0.25% Gel 0.5% Cream, ointment, gel, solution 0.05%
3	High potency	Triamcinalone acetonide	Ointment 0.1% (some brands are class 4)
4-5	Medium potency	Betamethasone valerate Fluocinolone acetonide Triamcinalone acetonide	Cream, ointment, lotion 0.1% and foam 0.12% Cream, ointment, 0.025% Cream 0.1% and ointment 0.025%
6	Low potency	Desonide	Cream, ointment 0.05%
7	Least potent	Hydrocortisone acetate	Cream, ointment 1% and 2.5%

and immunosuppressive effects on the skin. In the United States topical steroids are ranked from class 1 to 7 with superpotent steroids in class 1 and the least potent steroids in class 7.⁴ The steroids in any one class have equivalent potency, so a limited formulary of topical steroids is sufficient in most cases (Table 6-2).

There are many factors to consider when prescribing a topical steroid including the nature of the disease to be treated, the location of the rash, the amount of steroid needed, duration and frequency of treatment, and the age of the patient (Table 6-3).⁵

The risks of topical steroids are less severe than those associated with the use of oral corticosteroids; however, in certain situations the topical adverse effects can be cosmetically distressing to the patient and damaging to the skin (Table 6-4).⁶ Systemic adverse reactions, similar to those seen with systemic steroids, can occur with the use of more potent topical steroids, especially in children.

SYSTEMIC STEROIDS

Most common inflammatory dermatoses can be managed without systemic steroids. However, there are a few indications for their short-term use, such as widespread severe allergic contact dermatitis (eg, dermatitis due to poison ivy) and in some cases of atopic dermatitis that are unresponsive to other therapies. Chapter 8 contains additional information about the use of systemic steroids in these conditions.

TOPICAL CALCINEURIN INHIBITORS

Topical calcineurin inhibitors (tacrolimus and pimecrolimus) are nonsteroidal, immunosuppressant medications that are Food and Drug Administration (FDA) approved for use as a *second-line therapy* for short-term use in moderate to severe atopic dermatitis. Stinging and burning are common side effects of these medications. Pimecrolimus

Table 6-3. Factors in the usage and selection of topical steroids.

Disease and lesion category

- Acute inflammatory diseases such as contact dermatitis and atopic dermatitis usually respond to medium to high potency topical steroids. However, short-term use of more potent steroids may be needed for initial treatment
- Chronic localized dermatoses with thick lesions such as psoriasis may require high-potency steroids

Location of lesions

- Areas of thin skin such as the face, axilla, groin, diaper areas, and other intertriginous areas should be treated with the least potent to low potency steroids. The use of steroids in these locations should be limited in quantity and duration
- Dermatoses on the palms and soles may require high-potency steroids

Extent of area to be treated

- Low to medium potency steroids should be used if large body areas are to be treated

Quantity of steroid

- Package insert for clobetasol indicates that no more than 50 g should be used in 1 week

Duration of treatment

- The package insert of superpotent topical steroids such as clobetasol recommends use of no more than 2 consecutive weeks
- Topical steroids should be discontinued when the rash has resolved

Frequency of application

- Once to twice a day application is the usual recommendation

Age of patient

- Children have a higher ratio of total body surface to body weight and are more likely to have systemic adverse effects from topical steroids; the least to low potency steroids are recommended
- Low- to mid-potency steroids are recommended in elderly adults with thin and/or fragile skin as they may more easily develop adverse cutaneous problems with higher potency steroids

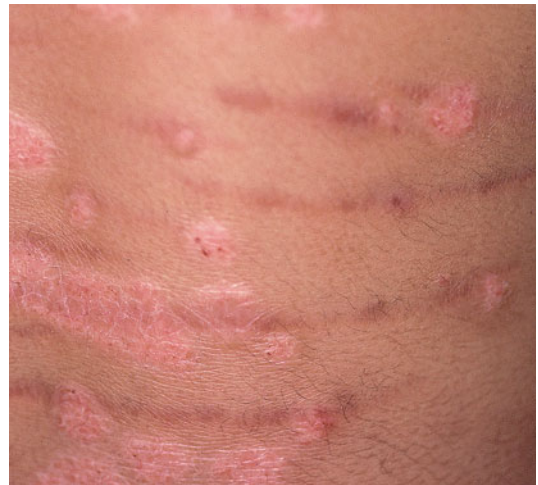Table 6-4. Potential adverse effects of topical steroids.

Adverse Effects	Notes
Atrophy	More common in children and the elderly, intertriginous areas, and face; risk increases with strength of steroid
Telangiectasia	Most commonly occurs on the face
Striae	Most common in intertriginous and flexural areas (Figure 6-2)
Purpura and ulcerations	More common in the elderly due to dermal atrophy
Delayed wound healing	May occur in ulcers and surgical sites
Hypopigmentation	More prominent in darker skin
Increased incidence of infections (bacterial, fungal, and viral)	May mask clinical features of fungal infections
Flares of acne, rosacea, perioral dermatitis	May occur with medium to superpotent steroids
Allergic or irritant contact dermatitis	Most commonly caused by a chemical in the vehicle or due to the steroid itself
Glaucoma	Uncommon, occurs with use near or on periorbital skin
Systemic adverse effects	More common in children or with use of high to superpotent steroids in any age group

(Elidel) cream 1% and tacrolimus (Protopic) 0.03% ointment are approved for patients 2 years and older and tacrolimus 0.1% ointment is approved for adults.

Several studies have been done on the off-label use of tacrolimus and pimecrolimus in cases in which the long-term use of topical steroids is contraindicated such as in dermatoses on the face (especially in the periorbital area) and other areas of thin skin. These studies have shown that calcineurin inhibitors are effective in seborrheic dermatitis, perioral dermatitis, intertriginous psoriasis, and vitiligo.⁷

Tacrolimus and pimecrolimus have black box warnings that state in part “Although a causal relationship has not been established, rare cases of malignancy (eg, skin and lymphoma) have been reported in patients treated with topical calcineurin inhibitors.” Therefore continuous long-term use of topical calcineurin inhibitors in any age group should be avoided, and application limited to areas of involvement with atopic dermatitis. The association with increased malignancy has been a subject of controversy in the literature.⁸ There are ongoing 10-year observational registries of children ages 2 to 17 who have used a topical calcineurin inhibitor.



▲ **Figure 6-2.** Psoriasis with striae caused by chronic use of high-potency steroid ointment.

MOISTURIZERS

The barrier function of the skin is impaired in many of the common dermatoses, especially in atopic dermatitis. It is essential that the barrier function be restored and maintained with use of moisturizers.⁹ Moisturizers should be applied liberally at least twice a day including immediately after bathing. The use of a low detergent bar or liquid soap is also important in the maintenance of the barrier. Examples of moisturizers and cleansers that can be used in patients with dermatitis and other inflammatory skin disorders are listed in Table 8-2.

Creams or lotions with ceramides, lactic acid, or urea may be helpful in some conditions, such as dry skin or dermatitis. At lower concentrations, lactic acid and urea act as moisturizers (humectants) and at higher concentrations, they act as keratolytic agents, which are especially helpful in thick fissured skin. The following are examples of these products:

- Ceramides: CeraVe Moisturizing Lotion and Cream and Cetaphil Restoraderm lotion. Prescription-only creams include Atopiclair and Mimyx Cream.
- Lactic acid: AmLactin Moisturizing Lotion and Lac-Hydrin Lotion.
- Urea: Carmol 10 and 20 Cream or Lotion. Carmol 40 is prescription only.

THERAPEUTIC BATHS

Tub baths with emollients added to the water are an efficient method of moisturizing the entire skin's surface. Aveeno Soothing Bath Treatment (colloidal oatmeal powder) and RoBathol Bath Oil (cottonseed oil) are examples

Table 6-5. Wet dressing materials and procedure.**Materials needed**

- For Burow's solution 1:40, mix 1 tablet or 1 powder packet of aluminum acetate (Domeboro or Bluboro) in 1 pint (16 oz/473 ml) of water
- Cotton material for dressings, for example, 4" gauze (eg, Kerlix) or bed sheets, pillow cases, or T-shirts

Procedure

- Apply a bland emollient or the appropriate steroid cream to the affected area
- Fold the cotton material to produce 4-8 layers of sufficient size to cover the affected area
- Drip the material into the solution and wring it out slightly so it is not dripping wet
- Apply the wet dressings to the affected area(s) and keep them in place for 15 to 30 min. Reapply 2-4 times a day until crusts and inflammation have resolved which typically takes 2-5 days
- Discontinue wet dressings if skin becomes fissured or dry
- If a large area is treated, cover wet dressings with a blanket to prevent hypothermia

of such products. Bath products may make the tub slippery, so caution is needed when entering or exiting the bathtub.

WET DRESSINGS

Wet dressings are a safe, cost-effective treatment for dermatoses that are vesicular or have crusts or exudate such as acute contact dermatitis, atopic dermatitis, bullous diseases, and impetigo.¹⁰ Topical emollients or topical steroid creams can be applied before or after the wet dressings. Table 6-5 covers the materials and procedure for wet dressings.

TOPICAL ANTIPRURITIC MEDICATIONS

Over-the-counter lotions containing calamine, camphor, menthol, or pramoxine are commonly used to reduce the symptoms of pruritus.¹¹ Some of the widely available products and their active ingredients are as follows:

- Aveeno Anti-Itch Lotion (calamine and pramoxine)
- Eucerin Calming Itch Relief Lotion (menthol)
- Prax Lotion (pramoxine)
- Sarna Original Anti-Itch Lotion (camphor and menthol)
- Sarna Sensitive Anti-Itch Lotion (pramoxine)

ORAL ANTIHISTAMINES

Oral antihistamines for urticaria are listed in Table 14-3. They are also commonly used for treatment of pruritus due to other etiologies. However, in conditions such as atopic dermatitis it may be the soporific effect of the sedating

antihistamines that is responsible for their efficacy in the treatment of pruritus.¹¹

ANTIFUNGAL MEDICATIONS

Superficial fungal infections such as tinea pedis, tinea cruris, and tinea corporis will usually respond to nonprescription topical antifungal agents, such as clotrimazole, miconazole, terbinafine, and tolnaftate. However, prescription medications may be needed in cases that do not respond to these products. Prescription and nonprescription topical antifungal agents are listed in Table 10-3.

Oral antifungal medications are needed for treatment of fungal infections in the scalp and nails and in some cases of fungal infections of the skin that do not respond to topical agents. These are listed in Tables 10-1 and 10-2 and in other sections of Chapter 10.

ANTIVIRAL MEDICATIONS

Oral and topical medications for herpes simplex and herpes zoster are covered in Tables 11-1 and 11-2.

ACNE AND ROSACEA MEDICATIONS

Topical and oral medications for the treatment of acne and rosacea are covered in Chapter 15.

ANTIBIOTICS

- Oral antibiotics for skin infections are covered in Chapter 12.
- Topical antibiotics are useful for treatment of localized areas of impetigo and superficial bacterial skin infection. Mupirocin ointment and cream 2% and retapamulin ointment 1% are examples of prescription topical antibiotics. Over-the-counter topical antibiotics can also be used but they have a higher rate of risk for allergic contact dermatitis. These include bacitracin, neomycin, and triple antibiotic (polymyxin, neomycin, and bacitracin) ointments.

MEDICATIONS FOR SCABIES AND LICE

Topical medications for the treatment of scabies and lice are covered in Tables 13-1 and 13-2.

SUNSCREENS AND SUN PROTECTIVE CLOTHING

Sunscreens are very important for the prevention of ultraviolet light (UVL)-related disorders such as skin cancer and photoaging (eg, wrinkles).¹² Several factors are important in the selection of a sunscreen including the sun protection factor (SPF) rating, the active ingredient, and the vehicle (Table 6-6). The SPF is a measurement of a sunscreen's ability to protect the skin against UVL in a laboratory setting. For example, if someone normally sunburns

Table 6-6. Sunscreen ingredients.

Ingredients	Chemical Agents	Brand Name Examples	Notes
Inorganic ingredients	Zinc oxide, titanium dioxide	Neutrogena Sensitive Skin Lotion, Vanicream SPF 30 or 60 Lotion	Best for individuals with allergies to sunscreens or who need visible light protection and children. May appear white on the skin
Organic ingredients	Benzophenones, cinnamates, padimates, salicylates	Aveeno, Banana Boat, Cetaphil, Coppertone, generic, Hawaiian Tropic creams, gel, lotions and sprays	Available in wide range of vehicles. Some are water resistant, may stain clothing

after 20 minutes of sunlight exposure, theoretically a SPF 15 sunscreen would protect him or her from burning for 15 × 20 minutes or 5 hours. However, there are several factors that in real life use of sunscreen reduce the level of protection. For maximum effectiveness sunscreens should be used as follows:

- Broad-spectrum sunscreens with SPF of 15 to 30 or higher should be used
- Applied 15 to 30 minutes before exposure
- Applied at the amount of 30 g (1 oz) per application if an entire adult body is to be covered
- Reapplied every 2 hours or after swimming or excessive sweating
- Kept at room temperature, not stored in car

FDA sunscreen regulations on labeling of sunscreens were changed in 2012. Some of these rules include criterion for the term “broad spectrum” and water-resistant claims will be specific (ie, sunscreen remains effective for 40 or 80 minutes after swimming). There will also be a limit on the SPF that can be claimed.

Clothing commonly worn in the summer such as cotton, rayon, and linen may not offer sufficient protection from UVL for some fair-skinned or photosensitive individuals.¹³ Polyester fabrics offer higher level of protection, but for prolonged sun exposure, sun protective clothing is a better option. The following are examples of companies that offer a wide range of sun protective clothing, swimwear, and hats for children and adults:

- Coolibar: www.coolibar.com
- Sun Precautions: www.sunprecautions.com
- Tilley Endurables: www.tilley.com

Some people are unwilling to limit UVL exposure because they want a tan. Sunless tanning products are an option for some of those individuals who want to have the appearance of a tan without exposure to the sunlight or tanning beds. These products usually contain dihydroxyacetone (DHA) that interacts with the amino acids in the stratum corneum to produce a temporary tanned appearance to the skin. DHA in a lower concentration in a daily

moisturizer (eg, Jergens Natural Glow and Neutrogena Build-A-Tan) is associated with less streaking. Sunless tanning products are not sunscreens and do not protect against sunburns.

Additional information about sun protection can be found at the Web site of the Skin Cancer Foundation (www.skincancer.org) and the American Academy of Dermatology (www.AAD.org).

PATIENT COMPLIANCE/ADHERENCE ISSUES

Compliance with the use of topical medications is low. Studies show that many patients do not actually purchase their prescriptions or use the medications less frequently or in smaller quantities than recommended.¹⁴ Compliance is particularly low in chronic conditions such as atopic dermatitis, psoriasis, and acne. Some of these compliance problems can be addressed by clinicians asking about patients’ preferences for various treatment regimens, setting realistic treatment goals, the use of clear written instructions about the importance and proper use of the prescribed medications, the use of medication reminder cell phone applications, and a follow-up visit to assess the patient’s response and compliance with the treatment plan.

QUALITY OF LIFE AND MENTAL HEALTH ISSUES

Patients with chronic skin disorders (eg, psoriasis, atopic dermatitis, chronic pruritus) have higher rates of anxiety and depression than healthy control subjects.¹⁵ These negative emotional states can trigger or worsen skin disease, setting off a vicious cycle. Patients with skin disorders and psychiatric comorbidities are best managed by a team approach including clinicians in primary care, mental health, and dermatology. These patients are often treated with standard psychotropic medications commonly used for anxiety and depression.¹⁶ Nonpharmacologic management such as psychotherapy, hypnosis, biofeedback, support groups, meditation, and other stress reduction techniques are also beneficial.¹⁷

WEB SITES

There are several free Web sites that have more detailed information about prescription and nonprescription products. The following is a list of selected sites:

- www.dailymed.com has the most recent FDA labels (package inserts) for many commonly used prescription medications. It is a free Web site of the US National Library of Medicine.
- www.nlm.nih.gov/medlineplus/druginformation has patient information for prescription products and herbs and supplements.
- www.drugstore.com lists the ingredients in many common topical nonprescription products.
- www.drugs.com contains information about generic availability of medications.

REFERENCES

1. Nelson A, Miller AD, Fleischer AB, Balkrishnan R, Feldman SR. How much of a topical agent should be prescribed for children of different sizes? *J Dermatol Treat.* 2006;17(4):224–228. PMID: 16971317.
2. Long CC, Finlay AY, Averill RW. The rule of hand: 4 hand areas = 2 FTU = 1 g. *Arch Dermatol.* 1992;128(8):1129–1130. PMID: 1497374.
3. Payette M, Grant Kels JM. Generic drugs in dermatology: part II. *J Am Acad Dermatol.* 2012;66(3):353.e1–353.e15. PMID: 22342022.
4. Cornell RC, Stoughton RB. Correlation of the vasoconstriction assay and clinical activity in psoriasis. *Arch Dermatol.* 1985;121(1):63–67. PMID: 3881088.
5. Drake LA, Dinehart SM, Farmer ER, et al. Guidelines of care for the use of topical glucocorticosteroids. American Academy of Dermatology. *J Am Acad Dermatol.* 1996;35(4):615–619. PMID: 8859293.
6. Hengge UR, Ruzicka T, Schwartz RA, Cork MJ. Adverse effects of topical glucocorticosteroids. *J Am Acad Dermatol.* 2006;54(1):1–15. PMID: 16384751.
7. Lin AN. Innovative use of topical calcineurin inhibitors. *Dermatol Clin.* 2010;28(3):535–545. PMID: 20510763.
8. Thai D, Salgo R. Malignancy concerns of topical calcineurin inhibitors for atopic dermatitis: facts and controversies. *Clin Dermatol.* 2010;28(1):52–56. PMID: 20082951.
9. Lodn M. Effect of moisturizers on epidermal barrier function. *Clin Dermatol.* 2012;30(3):286–296. PMID: 22507043.
10. Bingham LG, Noble JW, Davis MD. Wet dressings used with topical corticosteroids for pruritic dermatoses: a retrospective study. *J Am Acad Dermatol.* 2009;60(5):792–800. PMID: 19389521.
11. Patel T, Yosipovitch G. Therapy of pruritus. *Expert Opin Pharmacother.* 2010;11(10):1673–1682. PMID: 20426711.
12. Sambandan DR, Ratner D. Sunscreens: an overview and update. *J Am Acad Dermatol.* 2011;64(4):748–758. PMID: 21292345.
13. Hatch KL, Osterwalder U. Garments as solar ultraviolet radiation screening materials. *Dermatol Clin.* 2006;24(1):85–100. PMID: 16311171.
14. Nolan BV, Feldman SR. Adherence, the fourth dimension in the geometry of dermatological treatment. *Arch Dermatol.* 2009;145(11):1319–1321. PMID: 19917965.
15. Zachariae R, Zachariae C, Ibsen HH, Mortensen JT, Wulf HC. Psychological symptoms and quality of life of dermatology outpatients and hospitalized dermatology patients. *Acta Derm Venereol.* 2004;84(3):205–212. PMID: 15202837.
16. Lee CS, Accordino R, Howard J, Koo J. Psychopharmacology in dermatology. *Dermatol Ther.* 2008;21(1):69–82. PMID: 18318888.
17. Fried RG, Hussain SH. Nonpharmacologic management of common skin and psychocutaneous disorders. *Dermatol Ther.* 2008;21(1):60–68. PMID: 18318887.

7

Dermatologic Procedures

Bart Endrizzi

Introduction to Chapter / 38
Skin Biopsy / 38
Shave Biopsy Procedures / 40

Excision / 41
Destructive Techniques / 42
References / 45

INTRODUCTION TO CHAPTER

This chapter focuses on the most common procedures in dermatology that include biopsy techniques as well as surgical procedures for removal of benign and malignant tumors. **Videos of these procedures on pig's feet and in a clinical setting can be found at www.LangeClinicalDermatology.com.** The reader should seek hands-on supervised training to supplement the content in this section.

SKIN BIOPSY

Introduction

A skin biopsy is done to gather more information than is available from the patient's history and physical examination. This information can be used to establish or confirm a diagnosis. Often clinicians hesitate to perform a biopsy. There may be concerns about the cosmetic impact on the patient, the trauma associated with the procedure, or the technical aspects involved. Some disease processes are prone to sampling error and may require multiple skin biopsies for diagnosis. This is classically the case with cutaneous T-cell lymphoma or diseases with lesions of various stages or morphology.

Types of Biopsy Techniques

It is important to select the appropriate site, lesion, and technique for a biopsy. This often means focusing on the

location of the suspected pathologic process, for example, the epidermis, the dermal epidermal junction, deeper dermal structures, or subcutaneous dermal fat or muscle. The likely location of the pathology will determine if a shave, punch, or an excisional biopsy is most appropriate (Table 7-1).^{1,2} A biopsy should not be done on lesions that are excoriated or eroded.

- **Shave biopsy:** This is the most commonly used biopsy technique. It has the advantage of being less time consuming, yielding a good cosmetic result, and having a limited downtime for the patient. It is typically limited to processes occurring to the depth of the mid dermis. A saucerization biopsy is similar to a shave biopsy, but usually extends to the mid to lower dermis.^{3,5} If done too deeply, in certain locations the biopsy site may heal slowly (eg, on the lower leg) or leave a scar (eg, on the nose).
- **Punch biopsy:** This has the advantage of providing a sample of full thickness skin, rapid healing, and uniform control. It is limited by the diameter of the punch tool, and may not be adequate for processes in the subcutaneous tissue.
- **Excision and incision/wedge biopsy:** These are more advanced procedures that are done using a sterile technique. Advantages include an adequate sample down to the subcutaneous tissues. Margins can also be controlled and adjusted as needed. Limitations include the increased duration of the procedure and a longer healing time with a greater potential for scarring.

Table 7-1. Lesion, site, and biopsy selection for skin disorders.

Disorder	Procedures for Biopsy	Lesion or Site Selection
Dermatoses (rash) in epidermis or superficial dermis (lesions are not indurated, sclerotic, or deep)	Punch or shave	Select lesions that are characteristic or typical of the rash. Avoid old resolving lesions and excoriated lesions. If possible, avoid cosmetically sensitive areas, such as the central face
Dermatoses in deep dermis or fat (lesions are indurated, sclerotic, or deep)	Punch, incision, or excision	
Vesiculobullous diseases for routine histology	Punch or shave	Biopsy new lesions 2-7 days old with bullae intact. Include the edge of blister and perilesional normal skin
Vesiculobullous diseases for immunofluorescence studies	Punch or shave	For suspected pemphigoid and pemphigus biopsy perilesional skin. For suspected dermatitis herpetiformis biopsy normal adjacent skin
Ulcers	Punch or incision	Biopsy edge of ulcer, not the necrotic center
Tumors that are not suspected to be of melanocytic origin	Deep shave, punch, incision, or excision	Biopsy the thickest or elevated area
Tumors that are suspected to be of melanocytic origin (eg, lentigo, nevus, atypical nevus, or melanoma)	Deep shave, saucerization biopsy, excision, or punch biopsy (for small lesions) ^{3,4}	Remove entire lesion for biopsy

Equipment for Procedures

The next section contains a list of standard equipment that is essential for most dermatologic procedures. For each type of procedure additions to the standard tray are listed within the associated section. When surgical trays are being prepared, it is important to decide if the procedure will be clean or sterile. Shave biopsy and punch biopsy are performed with a clean technique. Deeper procedures such as excisions require a full sterile technique including a sterile tray, gloves, and disposables (eg, gauze sponges).

► Dermatology Standard Equipment Tray

- Seventy percent isopropyl alcohol pads/swabs, surgical marking pen, cotton-tipped applicators, and 4" × 4" gauze sponges.
- Sterile pack containing no. 3 scalpel handle, iris scissors, and Adson or Bishop forceps with small teeth.
- Dressing including bandage and sterile petroleum jelly.
- Pathology materials including a biopsy bottle (with 10% formalin for routine biopsies) labeled with the patient's name, identification number, birthdate, and the biopsy site. A pathology requisition slip and a biohazard bag are also needed.

► Electrosurgery Devices

Electrodesiccation and electrocautery are the most commonly used electrosurgery procedures in dermatology.

Electrodesiccation is primarily used to destroy tissue in superficial benign or malignant tumors and to control bleeding. It is performed using a device with a single electrode tip (monoterminal) and high voltage and low amperage (Figure 7-1).⁶ The electrical spark generated by this device causes desiccation (dehydration) of the treated tissue. Electrodesiccation should not be used in any patient with a pacemaker or implantable cardiac defibrillator as it can interfere with their function.

Electrocautery is performed using a device with 2 electrodes (biterminal) and low voltage and high amperage (Figure 7-1).⁶ The heat generated by this device destroys deeper tumors and controls bleeding by coagulation. Battery-operated disposable electrocautery devices are available. Electrocautery can be used in patients with implantable cardiac devices.

Patient Preparation

Care must be taken to properly inform the patient of the risks of any dermatologic procedure. Setting clear expectations is critical. The patient may have unrealistic expectations for scarring (or the expected lack thereof), or the anticipated duration of healing. This leads to frustration on the part of the patient and may lead to a negative impression of an otherwise normal outcome. Discussing these aspects clearly with the patient prior to the biopsy is critical, as is a review of postprocedure care. Patients do not need to stop aspirin or prescription anticoagulants for the skin procedures covered in this chapter.



▲ **Figure 7-1.** Electrocautery (left) is done with 2 electrode tips (biterminal) as in this battery-operated device. Electrodesiccation (right) is done with a single electrode tip (monoterminal).

After the risks, benefits, and alternatives of the procedure have been discussed, informed consent should be obtained and documented in the chart. Once the equipment is prepared, attention should turn to preparing the patient. Patient care should focus on limiting the physical and emotional trauma that may be associated with the procedure. The patient should be in a reclined, comfortable position that he or she can maintain during the entire procedure.

Anesthesia

Injectable local anesthetics are commonly used for skin biopsies. One percent lidocaine with epinephrine added at 1:100,000 is generally standard for most dermatologic procedures. Epinephrine decreases bleeding and increases the duration of dermatologic procedures. Onset of anesthesia after injection is very rapid with lidocaine. Epinephrine decreases bleeding and increases the duration of the anesthetic effect. Vasoconstriction from epinephrine may take 5 to 15 minutes for full onset. In sites with a high vascular network, like the scalp, waiting for several minutes postinjection will allow for vasoconstriction onset and greatly reduce bleeding during the procedure.

The maximum dose of lidocaine varies with the weight of the patient. The package insert recommendations for adult patients are 4.5 mg/kg (not to exceed 300 mg) for plain lidocaine and 7 mg/kg (not to exceed 500 mg) for lidocaine with epinephrine. Some patients metabolize lidocaine at a much higher rate and will require a larger dose. Other amide anesthetics vary in timing of onset and duration. A syringe is selected to match the anticipated volume of lidocaine, typically 1 to 3 cm³. Needle sizes of 26 or 30 gauge are preferred for patient comfort, but require increased pressure on the plunger and a slower rate of injection. Multiple syringes may be more appropriate for a large site as the needle will dull with repeated injections.

Lidocaine toxicity may initially present with tinnitus, lightheadedness, circumoral numbness, diplopia, or a metallic taste in the mouth. Nystagmus, slurred speech, localized muscle twitching, or fine tremors may occur with more profound toxicity. Epinephrine can lead to tachycardia and a feeling of uneasiness.

There are several things that can be done to minimize the pain and stinging associated with anesthetic injection:⁵

- 8.4% sodium bicarbonate can be added to the anesthetic at 10:1 ratio to lower the pH⁵
- The use of a 30-gauge needle
- Slowing the rate of injection to reduce injection pressure
- Icing or rubbing the skin
- Distraction (having the patient grasp or squeeze an object)

Topical anesthetics have a limited role in skin biopsy procedures due to the limited depth of penetration and the duration of application required to get an adequate effect. Generally they do not penetrate past the dermal epidermal junction. For younger or more apprehensive patients, a topical anesthetic can be applied to the site prior to injectable anesthesia for procedures extending into the dermis. Options include EMLA (lidocaine 2.5% and prilocaine 2.5%) cream or topical lidocaine. Absorption is slow and takes upward of 20 to 30 minutes for onset and 1 hour for maximum effect. The topical anesthesia must be applied to a sufficient thickness with the recommended number of grams as per the package insert and covered with an occlusive dressing. Peak anesthesia is achieved only after 1 hour or longer. If the need for anesthesia is anticipated, the anesthetic could be applied at home 1 hour before the procedure.

SHAVE BIOPSY PROCEDURES

Shave Biopsy

A shave technique is appropriate for removal of benign superficial lesions and the biopsy of lesions that extend into

the mid to lower dermis. Lesions appropriate for a shave biopsy include the following:

- Dermatoses
- Seborrheic keratoses and skin tags
- Nevi (when melanoma is not a concern)
- Suspected squamous and basal cell carcinomas
- A controlled deep dermal shave biopsy (saucerization biopsy) can be appropriate for a lesion considered for melanoma if adequate depth is obtained. However, consider a punch biopsy for smaller lesions or an excisional biopsy for larger lesions.⁴

In addition to the standard tray, the following items are added:

- Occupational Safety and Health Administration (OSHA)–approved safety blade (eg, DermaBlade or a no. 15 blade on a scalpel handle)
- Twenty percent aluminum chloride solution (eg, Drysol) for hemostasis with cotton-tipped applicators

The steps for a shave biopsy are presented in Table 7-2.^{3,5}

Table 7-2. Shave biopsy procedure.

- Clean the biopsy site with 70% isopropyl alcohol pads
- Mark the borders of the lesion with a surgical marking pen
- Inject 1% lidocaine with epinephrine 1-100,000 subcutaneously at the margin of the biopsy site, followed by intradermal infiltration creating a slightly elevated wheal above the plane of the skin
- For a superficial shave biopsy with a safety blade or scalpel, enter the skin parallel or at an angle of approximately 10° to the plane of the skin and at a steeper angle for deeper shave biopsies. For a saucerization biopsy, enter the skin at an angle of approximately 45°
- Use a smooth, short, back and forth motion of the blade to allow the cutting edge to slide through the tissue (Figure 7-2)
- Diminish the angle to maintain depth within the dermal plane
- If a safety blade is being used, control the depth of the biopsy by adjusting the curvature of the blade
- Use pressure with the tip of a cotton applicator to minimize tissue movement during the shave biopsy
- Exit the biopsy with a more acute angle
- Place the sample in the previously labeled specimen container
- Wipe the biopsy site with a gauze pad and press a cotton-tipped applicator soaked in aluminum chloride on the site to control bleeding. Use electrodesiccation if the biopsy site continues to bleed. Remember to ask patients about implanted cardiac devices before using electrodesiccation. If the patient has a cardiac device, use electrocautery if needed
- After hemostasis is obtained, cover the biopsy site with sterile petroleum jelly and a bandage with adhesion on all sides sufficient to cover the biopsy site
- Instruct the patient to remove the bandage in 24 h and wash the area with soap and water and apply petroleum jelly for 14 days or until the wound is healed

Video demonstrations of shave biopsy procedures on pig's feet and in a clinical setting can be found at www.LangeClinicalDermatology.com.

Punch Biopsy

A punch biopsy can be used as a diagnostic tool for lesions or dermatoses that extend into the deeper dermis or for removal of small- to medium-sized lesions such as compound/dermal nevi. Punch biopsy tools are typically available in increments of 1 mm and range in size from 2 to 10 mm in diameter. The most commonly used sizes for diagnostic biopsies are 3 to 4 mm.

In addition to the standard tray, the following items are needed for a punch biopsy:

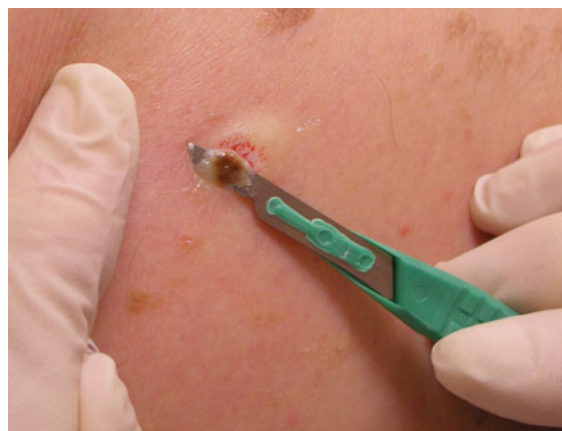- A punch tool of the appropriate size
- Twenty percent aluminum chloride solution (eg, Drysol) for hemostasis with cotton-tipped applicators
- A needle holder
- Suture, typically 4.0 or 5.0 polypropylene or nylon on a P-3 needle

The steps for a punch biopsy are presented in Table 7-3.^{3,5}

Video demonstrations of punch biopsy procedures on pig's feet and in a clinical setting can be found at www.LangeClinicalDermatology.com.

EXCISION

Excisions are used for biopsy of lesions or inflammatory processes that are in the deep dermis or subcuticular fat. They also can be used for removal of large benign lesions or malignant tumors such as basal or squamous cell carcinomas.



▲ **Figure 7-2.** Scalpel blade held parallel to plane of the skin cutting through the dermis below the nevus.

Table 7-3. Punch biopsy procedure.

- Cleanse, mark, and inject the biopsy site with lidocaine as in the shave biopsy procedure in Table 7-2
- Stretch the skin with the nondominant hand perpendicular to the relaxed tension lines (eg, wrinkle or Langer's lines) of the skin so that an oval rather than round defect will be created
- Place the punch tool vertically over the lesion and twist and push down with increasing pressure (Figure 7-3A)
- When the punch tool reaches the depth of the subcutaneous fat, there will be a decrease in tissue tension and the surrounding tissue will reach the level of the punch bezel
- Remove the core of tissue by very gently grasping the edge with forceps, taking care to not squeeze or crush the tissue. If the tissue is still attached to the skin, use scissors to snip the base of the specimen (Figure 7-3B)
- Place the biopsy specimen directly into the appropriate specimen bottle
- Control bleeding by wiping the biopsy site with a gauze pad and pressing a cotton-tipped applicator soaked in aluminum chloride over the site. Electrocautery is generally not necessary
- Small ≤ 4 mm punch biopsies can be left open to heal by secondary intention³
- If the biopsy is >4 mm, the site can be closed with interrupted sutures on either side of the center of the biopsy defect
- Use 4.0 polypropylene or 4.0 nylon on a P-3 needle for the trunk and extremities and 5.0 sutures for the face. The number of sutures is determined by the diameter of the defect. Alternatively, a figure of 8 suture technique can be used
- Place sterile petroleum jelly over the site and apply a bandage
- Instruct the patient to come back for suture removal in 7-10 days for the face and in 14 days for the trunk and extremities

In addition to the standard tray, the following items are needed for an excision:

- Sterile drapes, gloves, and bandages
- Povidone-iodine solution
- A number 15-scalpel blade and tissue scissors
- A needle holder
- 3-0 or 4-0 absorbable sutures (eg, Vicryl, Dexon) and nonabsorbable 4.0 or 5.0 sutures (eg, Prolene, Ethilon) on a P-3 needle. Alternative suture and needle sizes may be needed depending on location and degree of wound tension (Table 7-4)

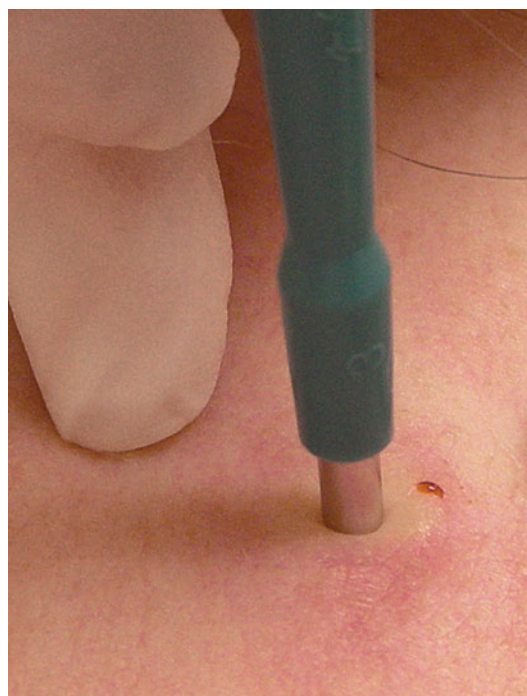
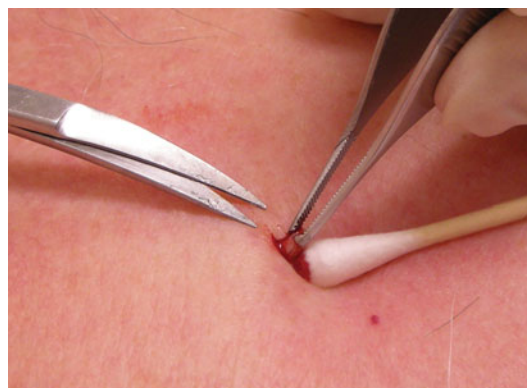
The steps for an excision are presented in Table 7-5.⁷

Video demonstrations of suturing techniques and excisions on pig's feet and in a clinical setting can be found at www.LangeClinicalDermatology.com.

DESTRUCTIVE TECHNIQUES

Cryotherapy

Cryotherapy is a common office procedure, and is the mainstay for the treatment of many benign and

**A****B**

▲ Figure 7-3. Punch biopsy. **A:** Punch biopsy tool held perpendicular to the skin and pressed halfway into the dermis. **B:** Tissue sample is gently grasped with forceps and base of the specimen is cut with iris scissors while assistant controls bleeding with cotton-tipped applicator.

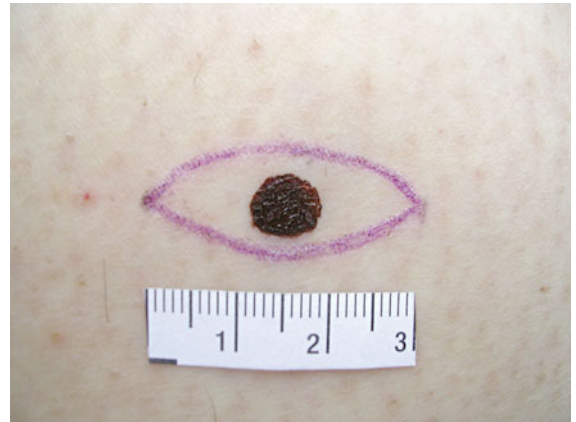precancerous lesions. Liquid nitrogen, which has a boiling point of -196°C (-321°F), is the coldest and most commonly used cryogen. A 30 second spray of liquid nitrogen will result in tissue temperatures of -25°C to -50°C (-13°F to -58°F). Most benign lesions will be destroyed at a tissue temperature of -20°C to 30°C .⁸

Table 7-4. Selection of suture size and timing of suture removal.

Location	Deep Absorbable Sutures (eg, Vicryl, Dexon)	Nonabsorbable Sutures for Closure of Epidermis (eg, Prolene, Nylon)	Timing of Suture Removal in Days*
Face and neck	5.0-6.0	5.0-6.0	Face—5-7 Neck—7-10
Back, scalp	3.0-4.0	3.0-4.0	14-21
Trunk and extremities	4.0	4.0	10-14

*Longer duration decreases risk of dehiscence, but may increase scarring.

The use of cryosurgical devices (eg, CRY-AC, CryoPro, FrigiSpray) with a spray tip and fingertip trigger is a safe and accurate way to use liquid nitrogen. Lesions commonly treated with cryotherapy include actinic keratoses, viral warts (human papillomavirus and molluscum contagiosum), seborrheic keratoses, and skin tags.

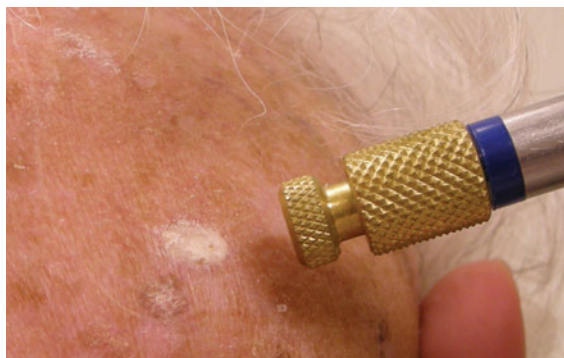

▲ **Figure 7-4.** Excision. The margins of the excision are marked to create at 3:1 length to width.

The patient should be informed that cryotherapy is painful during and sometimes for several minutes after the procedure. Erythema, bullae, and sometimes hemorrhagic bullae may develop. Hypopigmentation may be more prominent in individuals with darker skin types. Scarring can occur if the freezing extends into the dermis.

Table 7-5. Excision procedure.

- Mark the planned surgical margins using a surgical marking pen. The width of the fusiform excision should include 2 mm margins for benign lesions and 4-5 mm for basal or squamous cell carcinomas. The length of the excision should be 3 times greater than the width and the angle at the corner of the excision should be 30° or less. The long axis of the excision should be along the relaxed skin tension lines or at a cosmetic junction (Figure 7-4)
- Cleanse the skin with 70% isopropyl alcohol pads
- Inject 1% lidocaine with epinephrine 1:100,000 subcutaneously around the margin of the planned excision, carefully placing the needle into the edge of area that has already been anesthetized. Then inject the lidocaine intradermally until there is a slight swelling of the tissue
- Cleanse the skin with povidone-iodine solution and place sterile drapes around the surgical site
- To begin the excision insert the tip of the scalpel blade at the distal apex of the incision perpendicular and at 90° angle to the plane of the skin
- Lower the blade to a 45° angle and use the belly of the blade to cut the tissue rather than the tip that would quickly dull
- Continue with increased pressure and a smooth steady motion to the depth of the subcutaneous fat. At that point the tissue relaxes around the excision. It may take 2 passes to extend through the dermis depending on the site
- As the proximal apex of the excision is reached, increase the angle of the blade back to 90° to generate a clean excision with the tip of the blade
- Repeat the previous 4 steps on the other side of the excision
- Lift the skin specimen with forceps and separate the tissue specimen from the base of the excision at the level of the subcutaneous fat with the scalpel blade held parallel to the skin or with iris scissors. The thickness of the specimen should be uniform
- Place the sample in the previously labeled specimen container
- Use electrocautery or electrodesiccation to stop bleeding, taking care to limit thermal damage to the epidermis
- Narrowly undermine the skin at the level of the subcutaneous fat with rounded tip Mayo or Metzenbaum scissors
- Use absorbable suture in an interrupted pattern to approximate the deep dermis. Place each suture deep to superficial on one wound edge and superficial to deep on the other wound edge. This buries the knot deep in the wound. This can proceed from either the center to each apex for wounds of low tension or the apex to the center for high-tension wounds
- Close the epidermis with either interrupted sutures or a running suture. Wound margins should be carefully approximated without tension to achieve a satisfactory cosmetic result
- Place sterile petroleum jelly over the excision site and cover with an adhesive bandage



▲ **Figure 7-5.** Cryotherapy. The tip of the cryosurgical unit is used 1 cm from an actinic keratosis creating a 2 mm freeze margin.

► Procedure

- Position the nozzle of the spray tip 1 to 1.5 cm from the lesion to be treated.
- Spray the lesion until a 2 mm rim of frost develops around the lesion and then continue spraying for 5 to 30 seconds depending on the thickness, diameter, and location of the lesions (Figure 7-5). For larger lesions this can be done in spiral or paintbrush pattern. Approximate freeze times vary.
 - Actinic keratosis: 5 to 20 second freeze cycle, depending on the location and size of the lesion⁹
 - Seborrheic keratosis: 5 to 10 seconds for thin, flat lesions⁸
 - Warts: 10 seconds. Plantar warts may require a second freeze cycle¹⁰
 - Skin tags: 5 seconds⁸
- Cover the eyes, nostrils, and exterior auditory canal with gauze or cotton if cryosurgery is done near those

Table 7-6. Curettage and electrodesiccation procedure.

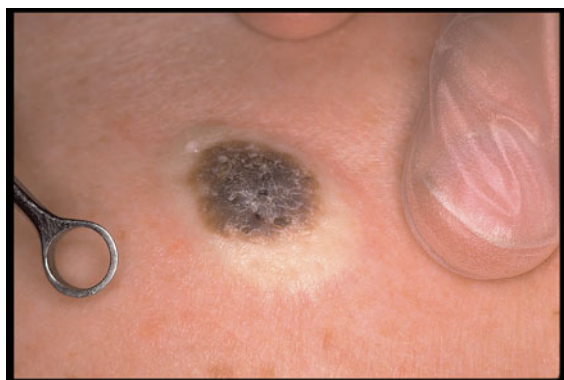- Cleanse and anesthetize the skin as for shave and punch biopsies
- Let the alcohol dry completely before proceeding to prevent possible fire
- Hold the curette in the dominant hand at a 45° angle and with firm pressure scrape the curette across the lesion with 1 or more smooth strokes. The nondominant hand can be used to stabilize the skin (Figure 7-6A and B)
- Repeat the procedure by scraping perpendicular to the original direction of curettage until a firm base is obtained
- Electrodesiccate the treated area at the lowest setting needed, taking care not to significantly increase the depth or width of the field
- Use the side of the electrode rather than the tip in order to maintain greater control of the depth
- Following electrodesiccation curette the tumor base again until a firm base is obtained. This will extend the wound margin by approximately 1 mm
- For basal cell carcinomas repeat with 3 rounds of curettage followed by cautery
- Place sterile petroleum jelly over the site and cover the site with an adhesive bandage
- The site should be kept moist with petroleum jelly and covered until reepithelialized

sites. Care should also be taken not to deeply freeze the skin near the digital nerves on the medial and lateral aspects of the fingers and toes.

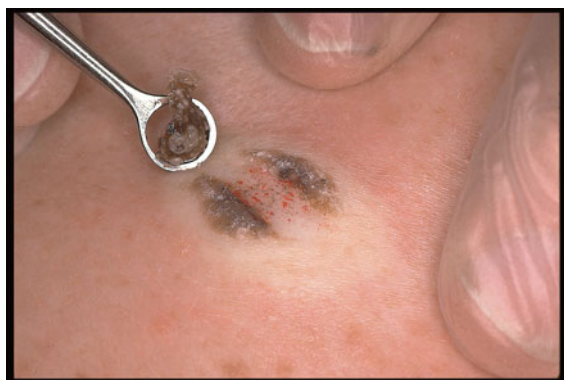Video demonstrations of cryotherapy can be found at www.LangeClinicalDermatology.com.

Curettage and Electrodesiccation

Curettage and electrodesiccation is a commonly used procedure for the treatment of seborrheic keratosis,



A



B

▲ **Figure 7-6.** Curettage. **A:** Wheal produced by lidocaine in seborrheic keratosis. **B:** A curette is stroked across the keratosis with firm pressure.

certain types of viral warts, pyogenic granulomas, and superficial basal cell carcinomas. In the hands of an experienced clinician, it also can be used for some small nodular basal cell carcinomas.¹¹ Electrodesiccation without cautery can be used on small skin tags and cherry angiomas. Electrodesiccation should not be used on any patient with an implantable cardiac device. If needed, a battery-operated, disposable heat cautery device could be used in these patients.

The patients should be informed of the risks of the procedure that include bleeding, infection, scars, and hyperpigmentation or hypopigmentation.

Equipment needed in addition to the standard tray is as follows:

- Fox round or oval curette, sizes 3 to 5 mm are most commonly used.
- Monoterminal electrodesiccation unit.

The steps for curettage and electrodesiccation are presented in Table 7-6.¹²

► Wound Care and Follow-Up

Wound care and follow-up are dictated by the type of procedure that was performed. Many patients have the false notion that air drying the wound will promote a more rapid healing response. In general, a clean wound will heal more rapidly and with less scarring if a good moisture barrier is maintained throughout the healing process. A firm pressure dressing is helpful for any full thickness procedure, and should be left in place for 24 to 48 hours.

Surgical Complications

► Bleeding

Excessive bleeding during a procedure is disconcerting to both the clinician and the patient. Firm application of pressure for several minutes often controls bleeding. Identification of the bleeding vessel and compression while performing cautery is usually very effective. An assistant who can hold pressure and wick away blood that is obscuring the surgical field is critical in this process.

A second concern is postprocedure bleeding. As the vasoconstriction due to epinephrine wears off, bleeding may occur minutes or hours later. Even a small amount of blood may cause anxiety in a patient. The patient should be advised of this possibility and given clear instructions to apply firm constant pressure for a minimum of 15 minutes. If the bleeding does not stop after this process, medical care should be sought either with the clinician who performed the procedure or at an urgent care facility. The development of a hematoma under a closed wound if large and firm warrants evacuation, cautery, and resuturing of the wound.

► Cardiac Devices

Part of patient screening should include questions regarding the presence of a pacemaker or implantable cardiac defibrillator. The use of monopolar electrodesiccation has a risk for triggering or damaging these devices. Electrocautery (heat cautery) and bipolar cautery should be used instead.

► Infection

Whenever the skin barrier is breached, infection is possible and prophylactic antibiotics may be indicated. Infection is more likely in wounds that have been exposed to the environment, or in certain body areas such as distal extremities and areas near body orifices.

Depending on the wound location and the exposure risk, topical or oral antibiotics individually or in combination may be appropriate. Cephalexin is often prescribed for wounds of the lower extremity due to a higher risk of infection. When to use prophylaxis and what type of prophylaxis to use is often a topic of debate among experts and its specific application is beyond the scope of this text.

Some nonprescription topical antibiotic ointments (eg, bacitracin, neosporin) have a significant risk of allergic contact dermatitis. Whenever a wound becomes more inflamed with the use of a topical antibiotic, an allergic contact dermatitis must be considered. Mupirocin ointment is less likely to cause allergic contact dermatitis.

► Wound Dehiscence

Separation of the wound can occur if the strength of the healing scar is not adequate at the time of suture removal. Excisions at sites with a poor vascular supply, such as the leg, will often require a significantly longer healing period of up to an additional week before suture removal. Infection can also lead to an increase in wound pressure and loss of wound integrity. Dehiscenced wounds can be resutured several days following a closure if the wound is cleaned and any risk for infection is addressed. The reclosed wound may require a drain if infection is present or anticipated. Resuturing should not be performed if an abscess is present. If the dehiscence occurs more than 24 hours after the excision, the reepithelialized tissue from the center of wound may need to be removed. A dehiscenced wound can also be left to heal with secondary intention, but this may result in a significant scar.

REFERENCES

1. Alguire PC, Mathes BM. Skin biopsy techniques for the internist. *J Gen Intern Med.* 1998;13(1):46–54. PMID: 9462495.
2. Sina B, Kao GF, Deng AC, Gaspari A. Skin biopsy for inflammatory and common neoplastic skin diseases: optimum time, best location and preferred techniques. A critical review. *J Cutan Pathol.* 2009;36(5):505–510. PMID: 19187117.
3. Pickett H. Shave and punch biopsy for skin lesions. *Am Fam Physician.* 2011;84(9):995–1002. PMID: 22046939.

4. Bichakjian CK, Halpern AC, Johnson TM, et al. Guidelines of care for the management of primary cutaneous melanoma. American Academy of Dermatology. *J Am Acad Dermatol*. 2011;65(5):1032–1047. PMID: 21868127.
5. Nischal U, Nischal Kc, Khopkar U. Techniques of skin biopsy and practical considerations. *J Cutan Aesthetic Surg*. 2008;1(2):107–111. PMID: 20300359.
6. Vuljevich JJ, Goldberg LH. Cryosurgery and electrosurgery. In: Goldsmith LA, Katz SI, Gilchrist BA, Paller AS, Leffell DJ, Wolff K, eds. *Fitzpatrick's Dermatology in General Medicine*. Vol. 2. 8th ed. New York, NY: McGraw-Hill; 2012.
7. Zuber TJ. Fusiform excision. *Am Fam Physician*. 2003;67(7):1539–1544, 1547. PMID: 12722855.
8. Andrews MD. Cryosurgery for common skin conditions. *Am Fam Physician*. 2004;69(10):2365–2372. PMID: 15168956.
9. Thai K, Fergin P, Freeman M, et al. A prospective study of the use of cryosurgery for the treatment of actinic keratoses. *Int J Dermatol*. 2004;43(9):687–692. PMID: 15357755.
10. Connolly M, Bazmi K, O'Connell M, Lyons JF, Bourke JF. Cryotherapy of viral warts: a sustained 10-s freeze is more effective than the traditional method. *Br J Dermatol*. 2001;145(4):554–557. PMID: 11703280.
11. Telfer NR, Colver GB, Morton CA. Guidelines for the management of basal cell carcinoma. *Br J Dermatol*. 2008;159(1):35–48. PMID: 18593385.
12. Goldman G. The current status of curettage and electrodesiccation. *Dermatol Clin*. 2002;20(3):569–578. PMID: 12170889.

Dermatitis

Erin Warshaw
Kristen Hook

8

Introduction to Chapter / 47
Contact Dermatitis / 47
Irritant Contact Dermatitis / 47
Allergic Contact Dermatitis / 49
Atopic Dermatitis / 52

Nummular Dermatitis / 56
Dyshidrotic Dermatitis / 57
Lichen Simplex Chronicus / 58
References / 59

INTRODUCTION TO CHAPTER

Dermatitis (eczema) refers to a heterogeneous group of disorders that share similarities in clinical appearance and histopathologic findings, but may have very different etiologies. Eczema originates from a Greek word meaning “to boil.” Acute dermatitis often appears vesicular (like water boiling on the skin), whereas chronic dermatitis may be red, scaly, and lichenified. Pruritus is a common symptom of all types of dermatitis.

CONTACT DERMATITIS

The 2 major types of contact dermatitis are irritant contact dermatitis and allergic contact dermatitis. These reactions are not mutually exclusive, and may occur simultaneously in a particular patient. For example, contact allergy to a glove chemical may complicate irritant hand dermatitis due to irritating soaps used for hand washing. Furthermore, one substance may act as both an irritant and an allergen; a patient may have an allergic reaction to a preservative in a liquid soap as well as having an irritant reaction to a detergent in a soap. Common allergens include urushiol (eg, poison ivy), nickel, fragrances, preservatives, topical antibiotics (eg, neomycin, bacitracin), and paraphenylenediamine (eg, black hair dye). Common irritants include water, soap, industrial cleansers, and frictional forces.

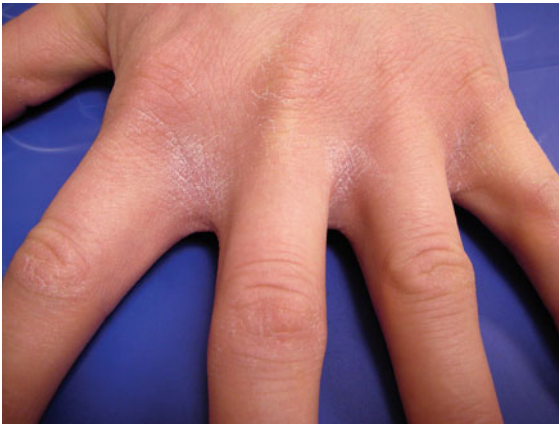IRRITANT CONTACT DERMATITIS

Introduction

Irritant contact dermatitis is the most common form of contact dermatitis. It is estimated that irritant contact dermatitis represents approximately 80% of occupational contact dermatitis. Occupations at high risk include those involving repeated exposure to water and/or soap (wet work) such as health care workers, janitorial services, and food industry employees or those involving exposure to solvents such as machinists.¹

Pathophysiology

Irritant contact dermatitis is a nonimmunologic response to chemicals or physical agents such as friction that disrupt the normal epidermal barrier. Strong irritants include acids and alkalis, whereas weak irritants include soaps and cleansers. Damaged skin lacks the proper oils and moisture, thus allowing irritants to penetrate more deeply and cause further damage by triggering inflammation. Any condition that impairs skin barrier function, such as atopic dermatitis or asteatotic dermatitis/dry skin, is a risk factor for developing irritant contact dermatitis.



▲ **Figure 8-1.** Irritant contact dermatitis in finger webs from dish detergent. Subtle erythema and scale in the finger webs.

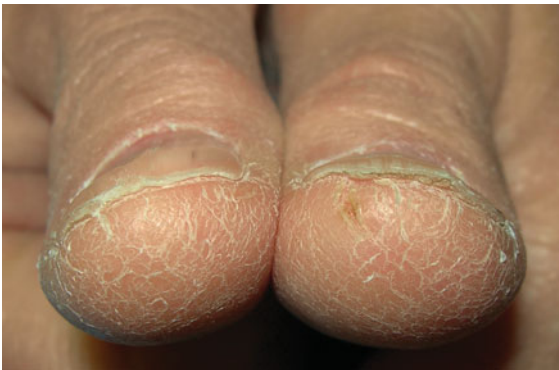Clinical Presentation

History

Irritant contact dermatitis typically develops weeks after exposure to weak irritants such as hand soap or immediately after exposure to strong irritants such as bleach. It may affect any individual, given sufficient exposure to irritants, but those with a history of atopic dermatitis are at higher risk because of disruption of the normal epidermal barrier. Pruritus, pain, and burning are common symptoms.

Physical Examination

Irritant contact dermatitis is often well demarcated with a glazed appearance, but there may also be erythema, swelling, blistering, and scaling. Initially, irritant reactions are



▲ **Figure 8-2.** Irritant contact dermatitis on finger tips from frequent hand washing with high detergent soap. Scale and fissures.

usually confined to the site of contact with the irritant. The most common locations are hands, forearms, eyelids, and face (Figures 8-1 to 8-3).

Laboratory Findings

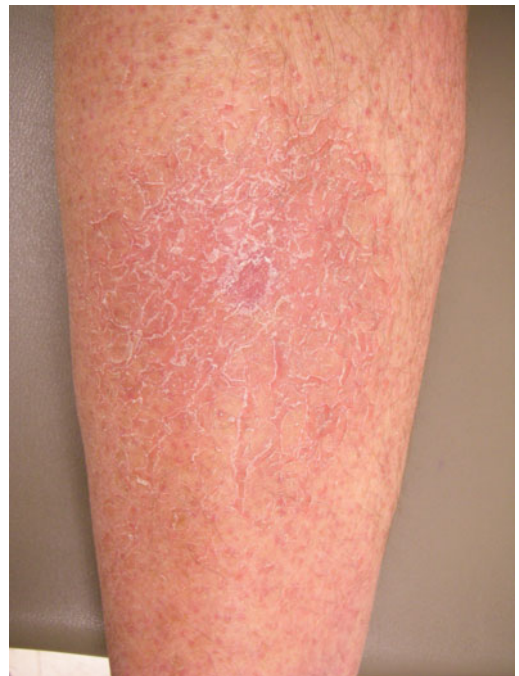Skin biopsies are usually not diagnostic and are only helpful to rule out noneczematous conditions such as psoriasis. Skin scrapings for fungal elements or a scabies preparation will rule out those conditions.

Diagnosis

Irritant contact dermatitis is a diagnosis of exclusion. The typical patient presents with pruritic or painful dermatitis beginning approximately 3 months after low-grade irritant exposure (eg, hand dermatitis in a nursing student) or shortly after exposure to a strong irritant or frictional exposure.

Differential Diagnosis

- ✓ **Allergic contact dermatitis:** This may appear identical to irritant contact dermatitis. Allergic contact dermatitis is diagnosed by patch testing.



▲ **Figure 8-3.** Chronic irritant contact dermatitis on legs from long, hot showers. Eczema craquelé (cracked porcelain) pattern with erythema, scale, and fine fissures on the lower leg.

- ✓ **Atopic dermatitis:** Individuals with atopic dermatitis usually have a personal or family history of atopic dermatitis (childhood eczema), allergic rhinitis, or asthma.
- ✓ **Cutaneous fungal infections:** Tinea infections present with annular plaques with a scaly border. Fungal hyphae causing tinea (corporis, manus, cruris, pedis) can be visualized on a potassium hydroxide (KOH) preparation from skin scrapings.
- ✓ **Other eczematous skin conditions:** Nummular dermatitis, dyshidrotic eczema, and lichen simplex chronicus.
- ✓ **Uncommon conditions:** Cutaneous T-cell lymphoma.

Management

The management of irritant contact dermatitis is 2-fold:

- Identification and removal of the irritant(s) (Table 8-1)
- Repair of the normal skin barrier

Mild soaps and moisturizers listed in Table 8-2 should be used. For irritant hand dermatitis, vinyl gloves should be worn as a barrier to unavoidable irritant exposures such as dish soap and juice from citrus fruits. Cotton gloves over a heavy emollient such as petroleum jelly overnight may also be helpful.² Each water exposure should be immediately followed by application of an emollient to prevent dehydration of the skin and restore the normal skin barrier.

Table 8-1. Examples of common skin irritants and their sources.

Irritant	Examples of Common Sources
Acids	Organic acids (eg, chromic, formic, hydrochloric, hydrofluoric, nitric, oxalic, sulfuric)
Alcohols	Antiseptics, waterless hand cleansers
Alkalis	Organic alkalis (eg, calcium oxide and potassium and sodium hydroxide)
Body fluids	Urine, feces, saliva
Concrete	Wet cement
Detergents	Hand soap, shampoo, dish detergents
Fiberglass	Insulation
Food	Fruit acids, meat enzymes, proteins, vinegar
Metal salts	Metal working, pulp, steel, and paper manufacturing
Physical agents	Temperature extremes, friction, humidity
Plastic resins	Unpolymerized monomers in plastic industries
Solvents	Turpentine, gasoline, kerosene, benzene

Table 8-2. Selected hypoallergenic moisturizers and cleansers.

Moisturizers
<ul style="list-style-type: none"> • Petroleum jelly • Aquaphor Healing Ointment • Vanicream Skin Cream • Eucerin Original Moisturizer Cream and Lotion • Cetaphil Moisturizing Cream and Lotion • Aveeno Lotion
Cleansers
<ul style="list-style-type: none"> • Cetaphil Gentle Skin Cleanser • Dove Bar Soap (unscented) • Aveeno Body Wash

For cracks and fissures, application of superglue as a sealant may also be helpful. Mid-potency topical corticosteroid ointments or creams may be used twice a day as needed to treat symptoms as adjunctive therapy to aggressive moisturization (Table 8-3).

Indications for Consultation

Severe or persistent disease that does not respond to treatment.

Patient Information

National Eczema Association: www.nationaleczema.org/living-with-eczema/hand-eczema

ALLERGIC CONTACT DERMATITIS

Introduction

The most common allergen causing allergic contact dermatitis in the United States is urushiol, found in poison ivy, oak, and sumac. Of individuals patch tested by specialists in North America, the most common allergens include:

- Metals (eg, nickel 19%; cobalt 8%; chromate 5%)
- Fragrances (eg, balsam of Peru 12%; fragrance mix 12%)
- Preservatives (eg, quaternium-15 10%)
- Topical antibiotics (eg, neomycin 10%; bacitracin 9%)³

Pathophysiology

Allergic contact dermatitis is a cell-mediated, delayed, type IV hypersensitivity reaction, resulting from contact with a specific allergen to which a patient has developed a specific sensitivity. There are 2 main steps in developing allergic contact dermatitis: induction and elicitation. During the *induction* phase, also known as sensitization, an allergen penetrates the epidermis and is processed

Table 8-3. Selected topical steroids for treatment of dermatitis.

Class	Potency	Generic Name	Trade Name Examples	Formulations
1	Superpotent	Clobetasol propionate	Temovate	Cream, gel ointment, solution 0.05%
2-3	High potency	Fluocinonide	Lidex	Cream, gel ointment, solution 0.05%
4-5	Medium-potency	Triamcinalone acetonide		Cream, ointment 0.1%
		Fluocinolone acetonide	Synalar	Ointment 0.025% Cream, ointment 0.025%
6	Low potency	Fluocinolone acetonide Desonide	Derma-Smoothe FS Desowen	Oil, solution 0.01% Cream, ointment 0.05%
7	Least potent	Hydrocortisone acetate	Cortaid	Cream, ointment 1% and 2.5%

by antigen-presenting cells (Langerhans cells, dendritic cells, and macrophages) and presented to T lymphocytes. This initial phase generally takes between 10 and 14 days. In the *elicitation* phase, reexposure to the allergen causes activation of circulating effector T lymphocytes, which produce cytokines resulting in an inflammatory response.⁴ Clinical manifestations usually occur within hours to days after allergen exposure. After removal of the allergen, allergic contact dermatitis typically persists for up to 3 weeks.

Clinical Presentation

History

The patient usually complains of an intensely pruritic rash at the site of contact with the allergen.

Physical Examination

- Acute allergic contact dermatitis classically presents as papules and vesicles on an erythematous base (Figures 8-4 and 8-5).
- Chronic allergic contact dermatitis may manifest as xerosis, fissuring, and lichenified eczematous plaques.

In general, allergic contact dermatitis occurs at the site of contact with the allergen. Nickel allergy usually results in dermatitis underlying nickel-containing objects (Figure 8-6) (eg, jewelry—earlobes, neck, wrists; belt buckles—umbilicus; cell phones—cheeks). However, dermatitis in certain sites, especially the eyelids and face, may result from contact to allergens on the hands (fingernail polish) or scalp (hair products). Table 8-4 lists common allergens at selected body sites.

Laboratory Findings

Skin biopsies are usually not diagnostic and are only helpful to rule out noneczematous conditions such as psoriasis. Skin scrapings for fungal elements or a scabies preparation will rule out those conditions.

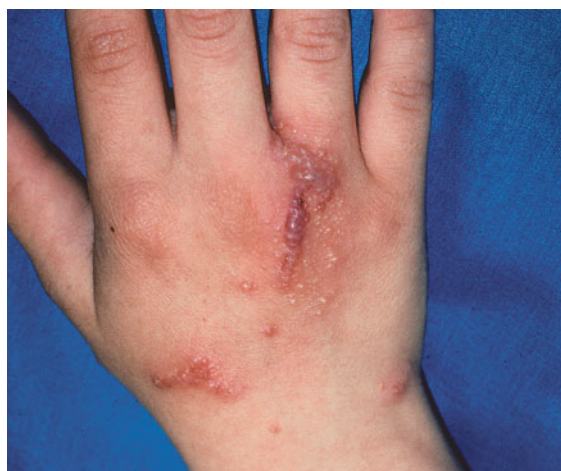Diagnosis

The key diagnostic features of allergic contact dermatitis are pruritic vesicles or scaly, lichenified plaques that correspond to the area of contact with the allergen.

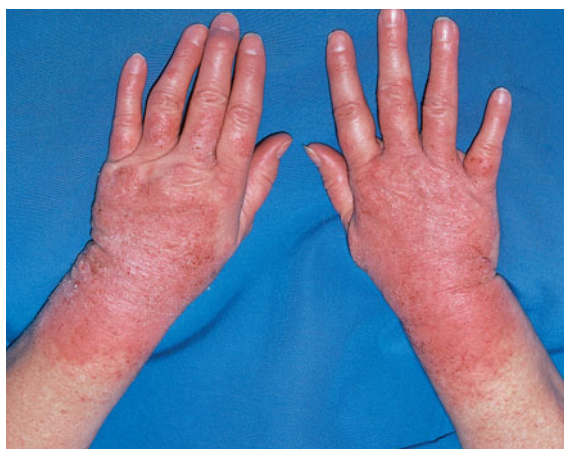Pruritus should always be present in allergic contact dermatitis. The presence or history of vesicles is helpful in confirming the diagnosis, although this is not solely specific for allergic contact dermatitis.

Differential Diagnosis

- ✓ **Irritant contact dermatitis:** This may appear identical to allergic contact dermatitis.
- ✓ **Atopic dermatitis:** Individuals with atopic dermatitis usually have a personal or family history of atopic dermatitis (childhood eczema), allergic rhinitis, or asthma.

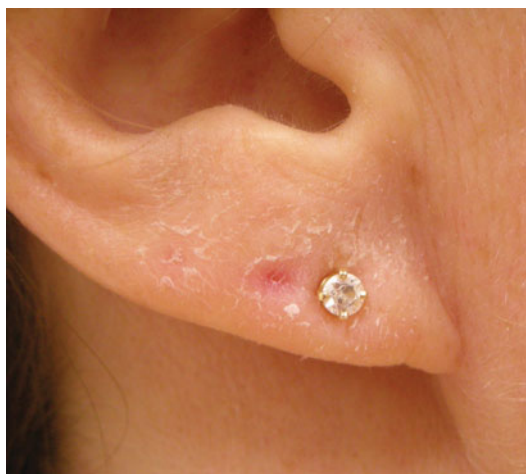

▲ **Figure 8-4.** Acute allergic contact dermatitis from poison ivy on hand. Linear streaks of erythema and vesicles at sites of direct contact with urushiol.



▲ **Figure 8-5.** Acute allergic contact dermatitis due to latex in gloves. Erythematous, edematous, scaly, crusted plaques on the hands and wrists.

- ✓ **Cutaneous fungal infections:** Tinea infections usually present with annular plaques with a scaly border. Fungal hyphae can be visualized on a KOH preparation from skin scrapings.
- ✓ **Other eczematous skin conditions:** Nummular dermatitis, dyshidrotic eczema, and lichen simplex chronicus.
- ✓ **Uncommon conditions:** Cutaneous T-cell lymphoma and dermatitis herpetiformis.



▲ **Figure 8-6.** Allergic contact dermatitis due to nickel in earrings. Scale and mild erythema at 3 sites of ear piercing.

Table 8-4. Common skin allergens at selected body sites.

Body Site	Common Sources and Responsible Allergens
All locations	Topical preparations (bacitracin, neomycin, corticosteroids, preservatives, emulsifiers) Personal care products (preservatives, emulsifiers)
Face	Cosmetics, personal care products (emulsifiers, preservatives) Hair products (surfactants, fragrances, preservatives) Cell phones, eyeglasses, headsets (nickel) Consort/connubial contact from spouse/partner's products
Eyelids	Cosmetics (emulsifiers, preservatives) Nail polish (toluene sulfonamide resin) Artificial nails (acrylates) Eyelash curlers, tweezers (nickel) Jewelry (gold—may cause a distant allergic contact dermatitis) Eye drops (active ingredients, preservatives)
Hands	Gloves (rubber accelerators, leather tanning agents) Hand soap/sanitizers (fragrance, antibacterial agents, surfactants) Tools/utensils (rubber, metals) Occupation-specific chemicals (eg, hairdressers—hair dye)
Neck, shoulders	Jewelry (nickel, cobalt, gold) Hair products (surfactants, fragrances, preservatives)
Feet	Shoes (rubber accelerators, leather tanning agents, glue ingredients)
Under clothing only	Clothing dye (disperse blue dyes) Clothing finishes (formaldehyde resins)

Management

The management of allergic contact dermatitis consists of 3 steps:

- Identification of the allergen through patch testing
- Avoidance of the allergen
- Repair of the normal skin barrier

The allergen responsible for allergic contact dermatitis may be identified by patch testing with purified or specially prepared allergens. See Chapter 4 for details of patch testing. Patch testing typically occurs over 5 to 7 days. On the first day, allergens are applied to the upper back and taped in place. After about 2 days, the patches are removed and locations are marked and the patch sites are evaluated by the clinician. They are re-evaluated once again between 3 to 4 days after application. Allergic reactions manifest as palpable, pink-red, edematous and/or vesicular–bullous plaques at the patch site. After identification of the allergen by patch testing, clinical relevance is determined by evaluating potential exposures to the allergen (identifying

the ingredient in the patient's products used in the location of dermatitis). If the dermatitis clears after avoidance of the allergen, this is good evidence that the allergic reaction is clinically relevant. Improvement of allergic contact dermatitis typically requires at least 3 weeks and often up to 2 months of allergen avoidance.

Patient information sheets on specific allergens, customizable lists of allergen-free products (Contact Allergen Management Plan [CAMP]), and other helpful resources are available through the American Contact Dermatitis Society Web site (www.contactderm.org). Mid- to high-potency topical corticosteroids (Table 8-3) applied twice a day are usually sufficient for treatment of allergic contact dermatitis. Restoration of the skin barrier includes mild soaps and moisturizers as listed in Table 8-2. An acute flare of widespread and extensive allergic contact dermatitis will respond to a 3-week tapering course of systemic corticosteroids. A standard adult dose consists of 40 to 60 mg of prednisone daily for 1 week, followed by a tapering dose over the next 2 weeks. Treatment with less than 3 weeks will usually result in rebound dermatitis, as this is a cell-mediated, delayed-type allergic reaction.

Indications for Consultation

Severe or persistent disease that does not respond to treatment.

Limited patch testing to about 36 allergens is performed by many general dermatologists. More extensive patch testing is typically performed by specialized dermatologists for occupational and more difficult cases.

Patient Information

American Contact Dermatitis Society: www.contactderm.org

ATOPIC DERMATITIS

Introduction

Atopic dermatitis is a very common skin condition that affects approximately 20% of children in developed countries. Ninety percent of patients have onset of disease before age 5 and 65% will have symptoms by 18 months of age. Rates continue to increase in developing countries, but have stabilized in developed countries. Diagnostic criteria, established by Hanifin and Rajka, and adapted by the UK Working Party in 1994, are based on clinical manifestations (Table 8-5).^{5,6} More than 75% of patients will report a family history of atopy (allergic rhinitis, asthma, and dermatitis). Asthma and allergic rhinitis are seen in many patients with atopic dermatitis; however, asthma flares do not necessarily occur at the same time as skin flares. The atopic march is commonly referred to as the march from atopic dermatitis to asthma and allergic rhinitis. It is estimated that approximately 33% of all children with atopic dermatitis will go on to

Table 8-5. Diagnostic Guidelines for Atopic Dermatitis.

Must have
• An itchy skin condition (or parental report of itching/rubbing in a child)
And
Three or more of the following:
• History of involvement of skin creases such as folds of elbows, behind the knees, fronts of ankles, or around the neck (including cheeks in children <10 years old)
• A personal history of asthma, or hay fever (history of atopic disease in first-degree relative in children <4 years old)
• A history of generally dry skin in the last year
• Visible flexural eczema (or eczema involving the cheeks/forehead and extensor limbs in children <4 years old)
• Onset under 2 years old (not used if child is under 4 years old)

Reproduced with permission from Williams HC, Burney PG, Pembroke AC, Hay RJ. The U.K. Working Party's Diagnostic Criteria for Atopic Dermatitis. III. Independent hospital validation. *Br J Dermatol*. 1994;131(3):406-416.

develop asthma. However, 50% of children with severe atopic dermatitis will go on to develop asthma and 75% will develop allergic rhinitis.⁷

The psychosocial effects of atopic dermatitis have been emphasized in recent years, and were summarized in a recent review by Kelsay et al.⁸ Chamlin et al identified 4 domains of distress⁹:

- Physical health (sleep disruption, itching, and related scratching)
- Emotional health (fussiness in children, various emotional stresses for parents)
- Physical functioning (activity restrictions, missed work)
- Social functioning (feelings of isolation, negative reactions from family members)

Pathophysiology

The etiology of atopic dermatitis is multifactorial, including a combination of genetic susceptibility and environmental triggers and/or exposures. Many gene loci have been linked to atopic dermatitis, including genes associated with increased immunoglobulin E (IgE) levels, or T lymphocyte activation. Filaggrin, a protein that is important in the barrier function of the epidermis, is also a factor in the pathogenesis of the disease.¹⁰

The association of atopic dermatitis and food allergy is a very controversial topic, as many believe that food allergies are responsible for skin flares. In rare cases, specific foods may cause worsening of atopic dermatitis. Usually elimination diets do not result in significant skin improvement.

Patients with atopic dermatitis have increased susceptibility to *Staphylococcus aureus* and other infections such as molluscum, herpes simplex virus (HSV), human

papilloma virus (HPV), and *Trichophyton rubrum* and *Malassezia* species. About 90% of atopic dermatitis skin lesions are colonized with microbes, usually *S. aureus*. This is thought to be related not only to an altered epidermal barrier but also to decreased production of antimicrobial peptides.¹¹ Recurrent infections can be problematic and drive the inflammatory cascade.

Clinical Presentation

History

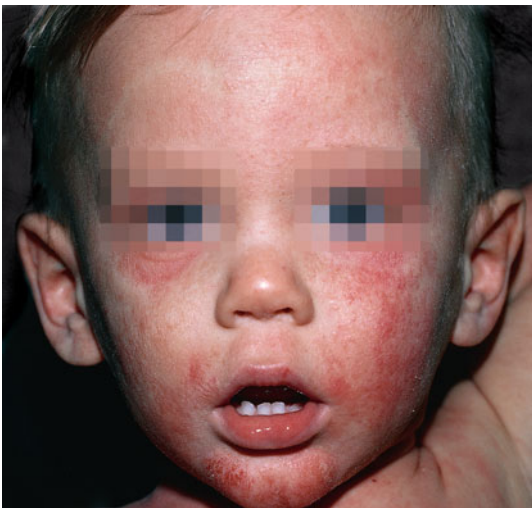The parent or patient usually complains of a rash and moderate to severe itching.

Physical Examination

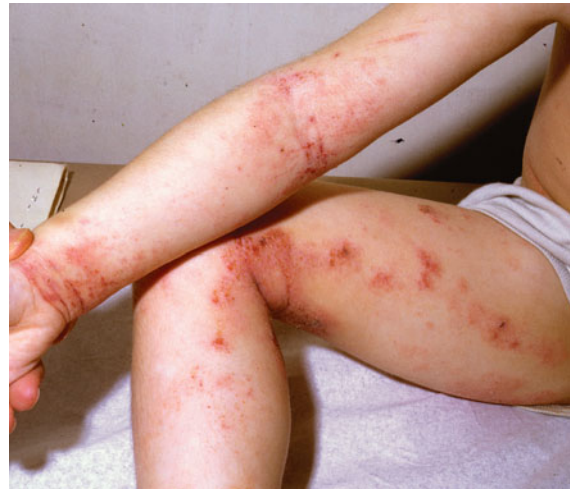The morphology of the skin lesions in atopic dermatitis is similar in all age groups. Excoriations, erythematous, scaly papules and plaques, vesicles, serous drainage, and crusts are common findings.

Three classic distributions of atopic dermatitis are recognized: infantile, childhood, and adult variants.

- **Infants** usually present with dermatitis involving the cheeks, trunk, and extensor extremities (Figure 8-7). The scalp may also be involved, but the diaper area is notably spared.
- **Young children** tend to have involvement of the posterior neck, flexor extremities (antecubital fossae and popliteal fossae), wrists, hands, ankles, and feet (Figure 8-8). Keratosis pilaris may be present on the extensor arms and thighs (Figure 8-9).



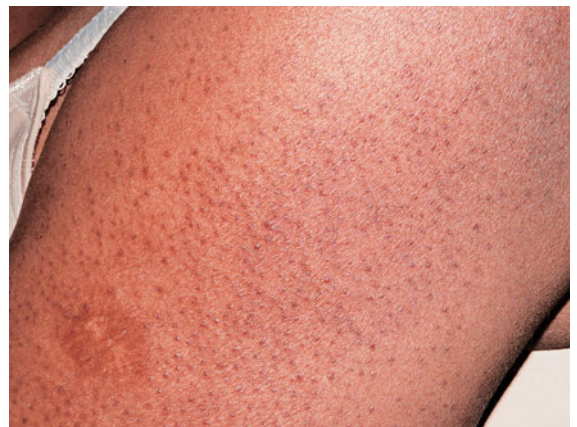▲ **Figure 8-7.** Atopic dermatitis, infantile presentation. Erythematous, scaly, crusted plaques in the periorbital area, cheeks, and chin. Note the accentuated creases under the eyes (Dennie's lines).



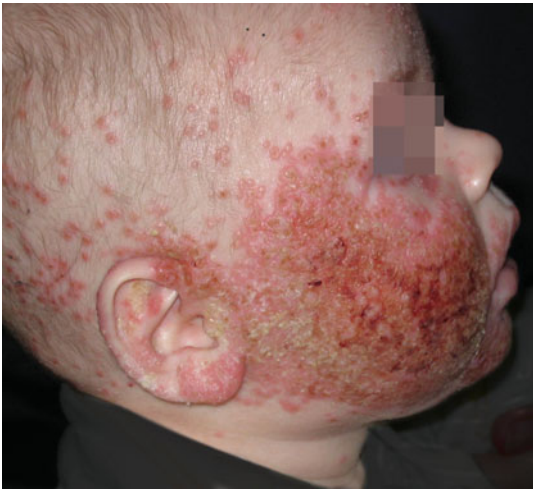▲ **Figure 8-8.** Atopic dermatitis, childhood presentation. Erythematous, scaly, excoriated plaques on the volar wrist and flexural extremities, most prominent in the antecubital and popliteal fossae.

- **Older children and adults** have posterior neck, flexor extremities, and hand involvement. Changes of chronic atopic dermatitis, including thickened hyperkeratotic plaques with lichenification and prurigo nodularis, may also be present. Postinflammatory hypopigmentation or hyperpigmentation are common associated findings. Xerosis is a common feature.

Patients with atopic dermatitis are frequently colonized with *S. aureus* and they may have plaques with erosions, drainage with yellow crusting, or hemorrhagic crusting.



▲ **Figure 8-9.** Keratosis pilaris. One to 2 mm perifollicular papules on the extensor arms.



▲ **Figure 8-10.** Eczema herpeticum (HSV) in infant with atopic dermatitis. Erythematous, confluent papules and vesicles with “punched-out” discrete erosions with hemorrhagic crusts.

Infections with warts and molluscum contagiosum are also more common in patients with atopic dermatitis. Susceptibility to widespread HSV infection is characteristic of atopic dermatitis. Eczema herpeticum is the result of a severe HSV infection. It presents with multiple widespread monomorphic, “punched-out” discrete erosions with hemorrhagic crusting (Figure 8-10). Usually this can be treated with oral antiviral medications. Concurrent staphylococcal infection is common in patients with eczema herpeticum. Patients may be ill-appearing or have associated fever. Parenteral antiviral medications and hospital admission may be appropriate in these cases. Rapid initiation of antiviral therapy has been shown to improve outcomes.¹²

► Laboratory Findings

Skin biopsies are usually not required, but they can be helpful to rule out other disorders. Elevated serum IgE levels are common. Radioallergosorbent (RAST) testing has not been shown to be clinically relevant in the treatment of atopic dermatitis.

Diagnosis

Infants: The key diagnostic features are red, crusted, scaly, pruritic plaques on cheeks, trunk, and extensor extremities.

Older children and adults: The key diagnostic features are red, scaly pruritic plaques on the neck, antecubital and popliteal fossae, wrists, ankles, and feet. Lichenification may be present.

► Differential Diagnosis

- ✓ **Seborrheic dermatitis:** Presents with yellow, greasy scale most commonly on head, face, and neck region. Can be widespread in infancy. Not as pruritic as atopic dermatitis.
- ✓ **Psoriasis:** Presents with well-demarcated, persistent plaques with overlying scale. The diaper area in infants is commonly affected.
- ✓ **Contact dermatitis (irritant or allergic):** Presents with well-demarcated eczematous plaques, usually localized to areas of contact.
- ✓ **Dyshidrotic eczema:** Presents with deep-seated noninflammatory 1 to 3 mm vesicles on the palms and soles.
- ✓ **Juvenile palmar-plantar dermatosis:** Presents with superficial desquamation of the feet, exacerbated by sweating.
- ✓ **Tinea corporis:** Presents with well-demarcated scaly, annular plaques, often with a raised border and central clearing.
- ✓ **Other:** Nummular dermatitis, scabies, perioral dermatitis, immune deficiency syndromes, nutritional deficiency syndromes, drug eruption, and graft-versus-host disease.

Management

- **Education:** Treatment begins with education of the parents, caregivers, and patients on the care of skin in atopic dermatitis.^{13,14}
- **Hydration and restoration of the skin’s barrier function:** This plays a vital part in the management of atopic dermatitis. Daily 5-minute baths in lukewarm water are encouraged. Colloidal oatmeal powder (Aveeno) and bath oil (RoBathol) can be added to the tub water. Bubble bath products should be avoided. Low detergent hypoallergenic cleansers are recommended for removal of any surface crusts (Table 8-2). Allowing the water to evaporate off the skin can increase xerosis, but application of a hypoallergenic moisturizing ointment or cream (Table 8-2), within 3 minutes after exiting the tub, increases hydration and improves barrier function. Lotions and products containing alpha or beta hydroxy acids, or urea may improve xerosis, but often sting when applied to inflamed skin. Lotions containing ceramides (eg, CeraVe, Cetaphil Restoraderm) may be better tolerated. Tap water soaks or Burow’s wet dressings may be helpful for crusted areas. See Table 6-5 for instructions on wet dressings. Moisturizers or topical steroids can be applied during or after the soaks.

- **Topical steroids:** Mild atopic dermatitis can usually be controlled with cream or ointment-based moisturizers and over-the-counter 1% hydrocortisone ointment. One percent hydrocortisone ointment can be used, once or twice a day, to any area of involvement, including the face and buttocks.

Moderate disease, in children and adults, may require class 4 or class 5 mid-potency steroid ointments or creams (Table 8-3). Good starting regimens for the body and extremities include Derma-Smooth FS oil twice a day after baths. The oil serves as a moisturizer, so additional moisturizers are not required with this regimen. Additional choices for older children and adults include fluocinolone 0.025% ointment and triamcinolone acetonide 0.025% or 0.1% ointments. For the face and neck, good starting choices include hydrocortisone 2.5% ointment and desonide 0.05% ointment. Creams tend to be preferred by adult patients, and may be more elegant, but also may burn or sting more than ointments when applied, and are considered less potent for a given steroid class. Systemic steroids should be used rarely as discontinuation often leads to more severe flaring.

- **Topical calcineurin inhibitors:** These are nonsteroidal anti-inflammatory immunosuppressant agents. They are good choices for the face and intertriginous areas, as secondary cutaneous atrophy is not a risk with their use. Pimecrolimus (Elidel) 1% cream is approved for mild to moderate atopic dermatitis in children older than 2 years, but has been studied in the 3- to 23-month age group with no severe side effects. Tacrolimus (Protopic) 0.03% ointment and 0.1% ointments are approved for moderate to severe atopic dermatitis in children older than 2 years of age. Both medications have US Food and Drug Administration (FDA) black box warnings attached for a theoretical risk of cancer (specifically lymphoma in mice who received 30-50 times higher doses than the maximum recommended human dose). Ongoing safety studies have not revealed any increased systemic immunosuppression or increased malignancy risk.¹⁵
- **Antihistamines:** Oral antihistamines can be helpful in breaking the “itch-scratch” cycle, but they are not considered a primary treatment for atopic dermatitis-related pruritus. Sedating agents can be especially helpful in children who have trouble falling asleep due to itching at night. Short courses can be used regularly until pruritus is improved. Diphenhydramine and hydroxyzine may be used. Additionally cetirizine (Zyrtec), loratadine (Claritin), and fexofenadine (Allegra) can be helpful in the morning due to their nonsedating effects.
- **Management of active infections:** Cephalexin (Keflex) is a reasonable antibiotic to start with. Standard dosing for 7 to 10 days is usually appropriate. If there is concern for methicillin-resistant *S. aureus* (MRSA), a culture should be sent to confirm the susceptibility. Oral trimethoprim-sulfamethoxazole (Bactrim) or clindamycin is usually acceptable in the pediatric age group. Tetracyclines should not be used in children less than 8 years old. Bleach (sodium hypochlorite) baths and mupirocin (Bactroban) ointment can be helpful in reducing bacterial load and staphylococcal carriage.¹⁶ Mupirocin ointment should be used twice daily for the first 5 days of each month in the nostrils. Bleach baths with one quarter to one half cup of bleach per full bathtub can be done once or twice a week. Bleach baths do not usually cause burning or stinging, as the chlorine concentration is low. Parents should continue with skin moisturization routine after baths.
- **Avoidance of triggers:** Common triggers include heat and sweat for some individuals and for others, cold, dry air. Other potential triggers include house dust mites, pet fur, wool, synthetic fabrics (eg, nylon), dyed fabrics, tobacco smoke, fragrances (which may be present in shampoos, soaps, lotions, laundry detergents, fabric softeners), saliva, or prolonged exposure to water. Fingernails should be trimmed short.
- **Food allergy:** Allergies to foods such as cow's milk, eggs, fish, peanuts, and wheat are more common in children with atopic dermatitis, but foods are specific triggers for flares in only a small percentage of children. There are blood (RAST) and skin prick tests that can identify specific allergens, but they are often positive in children who are not truly allergic and they are not considered to be helpful before age 2. It is important to determine which foods are relevant and cause clinical symptoms such as urticaria. Extreme food elimination diets, which have become more popular in recent years, are discouraged as they can result in nutrition and lack of essential dietary nutrients.
- **Ultraviolet light therapy and systemic immunosuppressant agents:** Severe widespread disease may require narrow-band ultraviolet light therapy, cyclosporine, methotrexate, azathioprine, or mycophenolate mofetil, but these should be used in consultation with specialists.
- **Psychological burden of disease and quality of life issues:** Controlling pruritus is an important aspect of atopic dermatitis treatment. In a quality of life study, ratings of pruritus intensity, both self-reported and parent reported, were inversely correlated with parents' quality of life (psychosomatic well-being, social life, emotional coping, and acceptance of the disease). Older children's itch has been shown to be negatively correlated with quality of life, and positively with depressed mood and catastrophic thinking.¹⁷ Nighttime itching affects both parents and children. Parents try to comfort the children at night and this can result in parental sleep deprivation and daytime exhaustion. Parental depression correlates more strongly with sleep deprivation

than with severity of their child's atopic dermatitis. Sleep deprivation also has consequences for school-age children (patients and siblings), affecting cognitive function and behavior.

► Prognosis

Most patients with atopic dermatitis improve with time, but a subset progresses to persistent skin disease and allergic rhinitis and/or asthma.

Indications for Consultation

- Severe or persistent disease that does not respond to treatment, especially in children, could indicate concurrent serious underlying disease.
- Patients with recurrent skin infections requiring oral or topical antibiotics.
- Patients with eczema herpeticum should be referred to dermatology and to ophthalmology emergently if there is questionable or confirmed eye involvement.

Patient Information

- Rady Children's Hospital: www.eczemacenter.org
- National Institute of Allergy and Infectious Diseases: www.niaid.nih.gov/topics/foodallergy/clinical/pages/default.aspx
- National Eczema Association: www.nationaleczema.org

NUMMULAR DERMATITIS

Introduction

Nummular is a Greek word meaning “coin.” Nummular dermatitis is a common skin disorder that presents with “coin-shaped” plaques on the extremities. It is more common in older individuals and is often associated with dry skin.

Pathophysiology

The pathophysiology of nummular dermatitis is unknown, but thought to be linked to impaired skin barrier function.

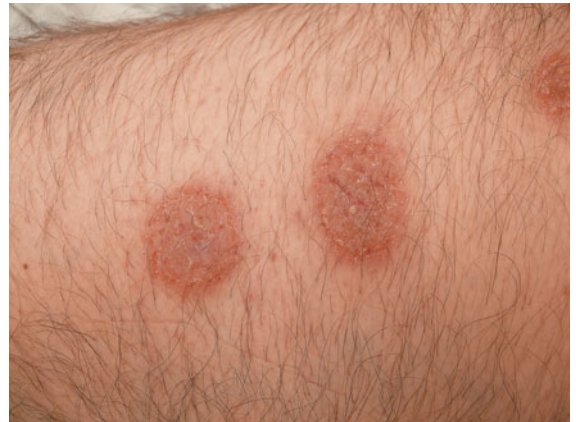Clinical Presentation

► History

The patient typically complains of an itchy rash on the extremities.

► Physical Examination

The patient typically presents with round, light pink, scaly, thin, 1 to 3 cm plaques on the extremities (Figure 8-11). The plaques are typically uniform with no central clearing. The trunk may also be affected.



▲ **Figure 8-11.** Nummular dermatitis on arm. Round, scaly, crusted plaques.

► Laboratory Findings

Skin biopsies are usually not diagnostic and are only helpful to rule out other disorders. Examination of a KOH preparation will be negative for fungal hyphae.

Diagnosis

The key diagnostic features of nummular dermatitis are pruritic, pink, scaly plaques, with no central clearing, commonly located on the arms and legs. The trunk may also be affected.

► Differential Diagnosis

- ✓ **Cutaneous fungal infections:** Tinea corporis may present in circular plaques but these are typically annular (ring-shaped with central clearing). Fungal hyphae can be visualized on a KOH preparation from skin scrapings.
- ✓ **Allergic and irritant contact dermatitis:** Allergic and irritant contact dermatitis usually do not present in coin-shaped plaques. Allergic contact dermatitis is diagnosed by patch testing.
- ✓ **Atopic dermatitis:** Individuals with atopic dermatitis usually have a personal or family history of atopic dermatitis (childhood eczema), allergic rhinitis, or asthma. Atopic dermatitis does not usually present with coin-shaped plaques.
- ✓ Other eczematous skin conditions including lichen simplex chronicus.
- ✓ Uncommon conditions may include cutaneous T-cell lymphoma, subacute cutaneous lupus, granuloma annulare, psoriasis, or squamous cell carcinoma in situ.

Management

The management of nummular dermatitis includes the use of mid- to high-potency topical corticosteroids (Table 8-3) twice a day, and mild soaps and moisturizers (Table 8-2).

Indications for Consultation

Severe or persistent disease that does not respond to treatment.

Patient Information

American Academy of Dermatology: <http://www.aad.org/skin-conditions/dermatology-a-to-z/nummular-dermatitis>

▼ DYSHIDROTIC DERMATITIS

Introduction

Dyshidrotic dermatitis (sometimes called pompholyx) is a common pruritic, vesicular skin disorder of the palms and soles. Some experts consider dyshidrotic dermatitis and pompholyx to be distinct conditions, although the terms are often used interchangeably.¹⁸ Dyshidrotic dermatitis is characterized by chronic, relapsing eruptions of vesicles. Pompholyx presents as explosive eruptions of large bullae. Dyshidrotic dermatitis is common, affecting approximately 1% of the general population,¹⁸ whereas pompholyx is rare. Men and women are affected equally.

Pathophysiology

The term “dyshidrosis” (meaning “difficult sweating”) is a misnomer. The condition does not involve dysfunction of sweat glands. The cause is unknown. A few studies have found a link between flares of vesicular palmoplantar dermatitis and oral ingestion of nickel in nickel-allergic patients.¹⁸ Most cases are idiopathic but often exacerbated by stress and/or sweat.

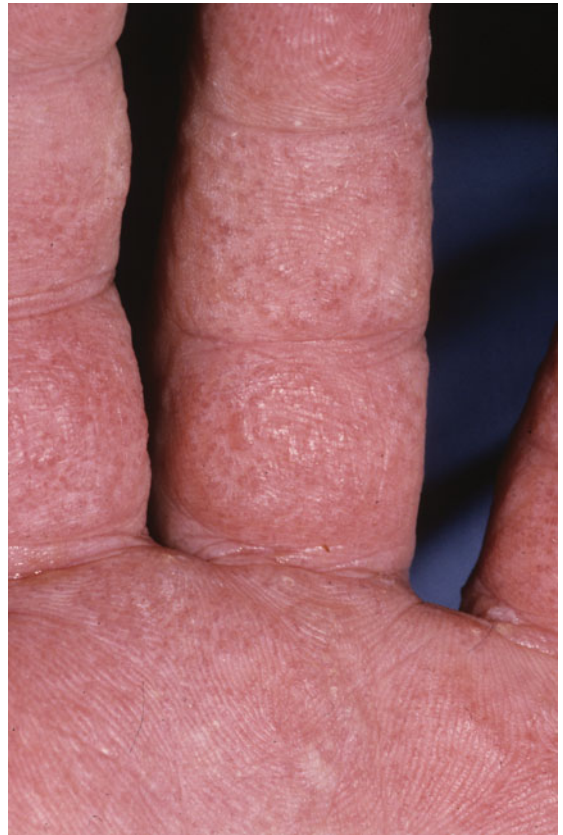Clinical Presentation

► History

The patient typically complains of pruritic or painful blisters on the palms and soles.

► Physical Examination

Dyshidrotic dermatitis presents with grouped 2 to 5 mm vesicles, sometimes likened to “tapioca pudding” (Figure 8-12). The most common locations include lateral fingers, central palms, insteps, and lateral borders of the feet. Pompholyx presents as large, 1 to 5 cm bullae. Both present on a noninflammatory base, with little surrounding erythema.



▲ **Figure 8-12.** Acute dyshidrotic dermatitis. Grouped, tiny “tapioca-like” vesicles with minimal erythema.

► Laboratory Findings

Skin biopsies are usually not diagnostic and are only helpful to rule out other disorders. Examination of a KOH preparation will be negative for fungal hyphae.

Diagnosis

The key diagnostic features of dyshidrotic dermatitis are small, grouped vesicles on the palms and/or soles.

► Differential Diagnosis

- ✓ **Allergic and irritant contact dermatitis of the palms and soles:** Allergic and irritant contact dermatitis usually are not limited to these locations and have surrounding erythema, scale, and eczematous plaques.
- ✓ **Cutaneous fungal infections:** Inflammatory tinea pedis caused by *Trichophyton mentagrophytes* may present with vesicles, but these typically have

surrounding erythema. Fungal hyphae will be visualized on a KOH preparation from skin scrapings.

- ✓ **Erythema multiforme:** This can present with inflammatory, “bull’s-eye” bullae on the palms and soles. Skin biopsies will have specific findings.
- ✓ **Scabies:** This may present with vesicles and papules on the palms and soles, but usually there are burrows and more widespread lesions.
- ✓ **Vesiculobullous diseases such as pemphigoid and pemphigus:** Dyshidrotic eczema is typically noninflammatory and only affects the palms and soles, whereas other vesiculobullous conditions have significant surrounding erythema and commonly affect multiple body sites.

Management

Dyshidrotic dermatitis is managed with mid- to high-potency topical corticosteroids (Table 8-3) twice a day. In individuals where sweat is a significant aggravating factor, iontophoresis or onabotulinumtoxin (Botox) injections may be helpful. In patients who have a strong positive reaction to nickel, a low-nickel diet¹⁹ may be tried.

Dyshidrotic dermatitis may not completely clear with treatment and recurrences are common.

Indications for Consultation

Inflammatory bullae, severe or persistent disease that does not respond to treatment, or extension to sites other than the palms and soles.

Patient Information

American Contact Dermatitis Society—low-nickel diet: www.contactderm.org

LICHEN SIMPLEX CHRONICUS

Introduction

Lichen simplex chronicus is a term used to describe the clinical appearance of any long-standing, chronically pruritic skin condition. As a primary diagnosis, it exists without a known underlying condition or cause. As a secondary diagnosis, it results after years of scratching due to another condition, most commonly atopic dermatitis.

Pathophysiology

The exact pathophysiology is unknown. Chronic rubbing and scratching of the skin leads to thickening of the epidermis and fibrosis of the dermis. Chronic cutaneous nerve stimulation is hypothesized to result in nerve dysfunction;

an “itch–scratch” cycle ensues perpetuating the need to rub and scratch affected areas.

Clinical Presentation

History

The patient typically complains of localized areas of intensely pruritic skin. Sleep is often interrupted. In some cases, the chronic rubbing and scratching becomes a subconscious or compulsive habit.

Physical Examination

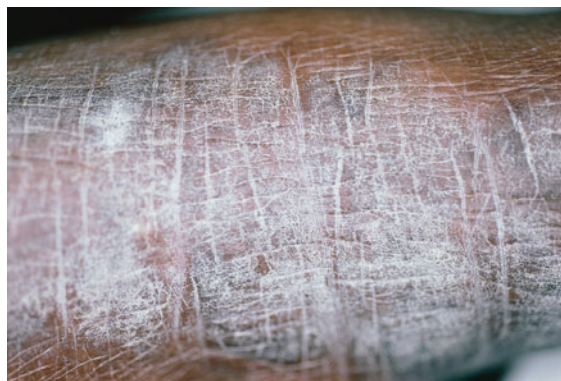Common locations for primary lichen simplex chronicus include the lateral neck, scrotum/vulva, and dorsal foot. The plaque is typically solitary, well-defined, pink to tan, thick, and lichenified (Figure 8-13). Secondary lichen simplex chronicus occurs at the sites of the underlying skin conditions such as in the antecubital and popliteal fossae in atopic dermatitis. A prurigo nodule is a term used for a lichenified papule that has been chronically picked and manipulated. Secondary prurigo nodularis may present with many widespread lichenified papules in patients with generalized pruritus due to systemic diseases such as liver or kidney disease.

Laboratory Findings

Skin biopsies are usually not diagnostic and are only helpful to rule out other disorders.

Diagnosis

The key diagnostic features of lichen simplex chronicus are chronic, intensely pruritic, lichenified plaques, mostly commonly found on the neck, genitals, or dorsum of the foot.



▲ **Figure 8-13.** Lichen simplex chronicus on leg. Thick scaly plaque with accentuation of scale in skin markings.

Differential Diagnosis

- ✓ **Psoriasis:** Presents with multiple, symmetric lesions most commonly on the elbows, knees and scalp.
- ✓ **Psychological disorders:** Usually other signs of psychological disease are present.
- ✓ **Squamous cell carcinoma:** This can present as a hyperkeratotic plaque, but it is typically not pruritic and rarely becomes lichenified.

Management

Primary lichen simplex chronicus is typically managed with class 1 or 2 high to superpotent topical corticosteroid ointments or creams twice a day (Table 8-3). Corticosteroid-impregnated tapes, such as Cordran Tape which can be applied directly over the plaque, are often helpful. Oral antidepressants or antihistamines, especially doxepin, may benefit individuals with nighttime itching and sleep disturbance. It is important that patients become aware of the habit or compulsion to scratch or rub, replacing these activities with pushing on the skin. Application of ice provides a better alternative. In more severe cases, behavioral therapy may be of benefit. For generalized prurigo nodularis, ultraviolet light therapy is often very helpful.

Indications for Consultation

Severe or persistent disease that does not respond to treatment.

Patient Information

PubMed Health: <http://www.ncbi.nlm.nih.gov/pubmed/health/PMH0001875/>

REFERENCES

- Cashman MW, Reutemann PA, Ehrlich A. Contact dermatitis in the United States: epidemiology, economic impact, and workplace prevention. *Dermatol Clin*. 2012;30(1):87–98. PMID: 22117870.
- Warshaw EM, Lee G, Storrs FJ. Hand dermatitis: a review of clinical features, therapeutic options, and long-term outcomes. *Am J Contact Dermatitis*. 2003;14(3):119–137. PMID: 14744403.
- Zug KA, Warshaw EM, Belsito DV, et al. North American Contact Dermatitis Group 2005–2006 patch test results. *Dermatitis*. 2009;20(3):149–160. PMID: 19470301.
- Kalish RS. Recent developments in the pathogenesis of allergic contact dermatitis. *Arch Dermatol*. 1991;127(10):1558. PMID: 1929465.
- Hanifin JM, Rajka G. Diagnostic features of atopic eczema. *Acta Derm Venereol Suppl (Stockh)*. 1980;92:44–47. PMID: none assigned.
- Williams HC, Burney PG, Pembroke AC, Hay RJ. The U.K. Working Party's Diagnostic Criteria for Atopic Dermatitis. III. Independent hospital validation. *Br J Dermatol*. 1994;131(3):406–416. PMID: 7918017.
- Spergel JM. Epidemiology of atopic dermatitis and atopic march in children. *Immunol Allergy Clin North Am*. 2010;30(3):269–280 [review]. PMID: 20670812.
- Kelsay K, Klinnert M, Bender B. Addressing psychosocial aspects of atopic dermatitis. *Immunol Allergy Clin North Am*. 2010;30(3):385–396. PMID: 20670820.
- Chamlin SL, Cella D, Frieden IJ, et al. Development of the Childhood Atopic Dermatitis Impact Scale: initial validation of a quality-of-life measure for young children with atopic dermatitis and their families. *J Invest Dermatol*. 2005;125(6):1106–1111. PMID: 16354179.
- Irvine AD, McLean WH, Leung DY. Filaggrin mutations associated with skin and allergic diseases. *N Engl J Med*. 2011;365(14):1315–1327. PMID: 21991953.
- Ong PY, Leung DY. The infectious aspects of atopic dermatitis. *Immunol Allergy Clin North Am*. 2010;30(3):309–321. PMID: 20670815.
- Aronson PL, Yan AC, Mittal MK, Mohamad Z, Shah SS. Delayed acyclovir and outcomes of children hospitalized with eczema herpeticum. *Pediatrics*. 2011;128(6):1161–1167. PMID: 22084327.
- Krakowski AC, Eichenfield LF, Dohil MA. Management of atopic dermatitis in the pediatric population. *Pediatrics*. 2008;122(4):812–824. PMID: 18829806.
- Hanifin JM, Cooper KD, Ho VC, et al. Guidelines of care for atopic dermatitis, developed in accordance with the American Academy of Dermatology (AAD)/American Academy of Dermatology Association “Administrative Regulations for Evidence-Based Clinical Practice Guidelines”. *J Am Acad Dermatol*. 2004;50(3):391–404. PMID: 14988682.
- Kalavala M, Dohil MA. Calcineurin inhibitors in pediatric atopic dermatitis: a review of current evidence. *Am J Clin Dermatol*. 2011;12(1):15–24. PMID: 21067248.
- Huang JT, Abrams M, Tlougan B, Rademaker A, Paller AS. Treatment of *Staphylococcus aureus* colonization in atopic dermatitis decreases disease severity. *Pediatrics*. 2009;123(5):e808–e814. PMID: 19403473.
- Weisshaar E, Diepgen TL, Bruckner T, et al. Itch intensity evaluated in the German Atopic Dermatitis Intervention Study (GADIS): correlations with quality of life, coping behaviour and SCORAD severity in 823 children. *Acta Derm Venereol*. 2008;88(3):234–239. PMID: 18480921.
- Lofgren SM, Warshaw EM. Dyshidrosis: a review of epidemiology, clinical characteristics, and therapy. *Dermatitis*. 2006;17(4):165–181. PMID: 17150166.
- Veien NK. Restriction of nickel intake in the treatment of nickel-sensitive patients. *Curr Probl Dermatol*. 1991;20:203–214. PMID: 1935212.

9

Psoriasis and Other Papulosquamous Diseases

Barrett Zlotoff
Laura E. Keck
R. Steven Padilla

Introduction to Chapter / 60
Psoriasis / 60
Seborrheic Dermatitis / 65

Pityriasis Rosea / 67
Lichen Planus / 68
References / 69

INTRODUCTION TO CHAPTER

Psoriasis, seborrheic dermatitis, pityriasis rosea, and lichen planus are diseases that present with papulosquamous lesions (scaly papules and plaques). Although these diseases may have a similar morphology, their underlying etiologies vary. Secondary syphilis, cutaneous T-cell lymphomas, and connective tissue disease may also present with papulosquamous lesions and should be included in the differential diagnosis.

PSORIASIS

Introduction

Psoriasis is a common, chronic, inflammatory disease that can result in decreased quality of life. Clinicians have long been vexed by this ancient affliction. Although most medical literature prior to Willan (1757-1812) lumped psoriasis, leprosy, eczema, and other inflammatory dermatoses into a confusing menagerie, Celsus gave a convincing account of psoriasis vulgaris almost 2000 years ago. His description included many of the morphologic features that physicians today utilize to diagnose psoriasis, including the “ruddy” or salmon-colored plaques with silvery scales that often are associated with punctate hemorrhage or “erosions” when removed.¹

More than 7.5 million adults (2.1% of the population) in the United States are affected and 30% of these individuals will develop psoriatic arthritis.² About

1.5 million of them are considered to have moderate to severe disease. Psoriasis may have a significant negative impact on a patient’s quality of life. Patient often are self-conscious, depressed, or frustrated over the appearance of their skin.

Psoriasis spans all socioeconomic groups, and its prevalence varies by geographic location. Historically, the disease is more common in the northern latitudes. The rate of psoriatic disease is lower in African Americans compared with that in European Americans.²

Pathophysiology

The primary cause of psoriasis is a dysregulation of the cell-mediated, adaptive immune response. This dysregulation is likely triggered by hyperactivity of the innate immunological surveillance system to environmental antigens. In genetically predisposed individuals, the Th1 pathway response is overstimulated. This overproduction of Th1-related cytokines along with IL-12, -17, and -23 causes hyperproliferation of epidermal keratinocytes. These events lead to the formation of the psoriatic plaques.³

Environmental factors and disease states that interact with polygenic inheritance patterns most likely account for the variable expression of psoriatic disease. These include streptococcal pharyngitis (guttate psoriasis), stressful life events, low humidity, human immunodeficiency virus (HIV), trauma, medications, cold, and obesity. Diets high in fish oils seem to be protective against the development of psoriasis.^{2,4}

Clinical Presentation

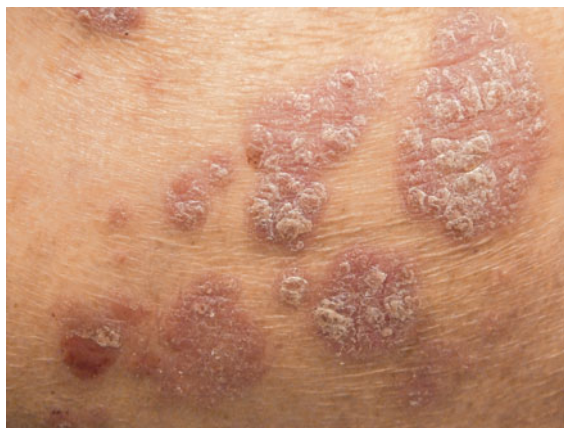History

Most patients with mild to moderate psoriasis are asymptomatic, but pruritus is common in severe or widespread disease. Patients may also give a history of joint pain and swelling, especially in the fingers and toes.

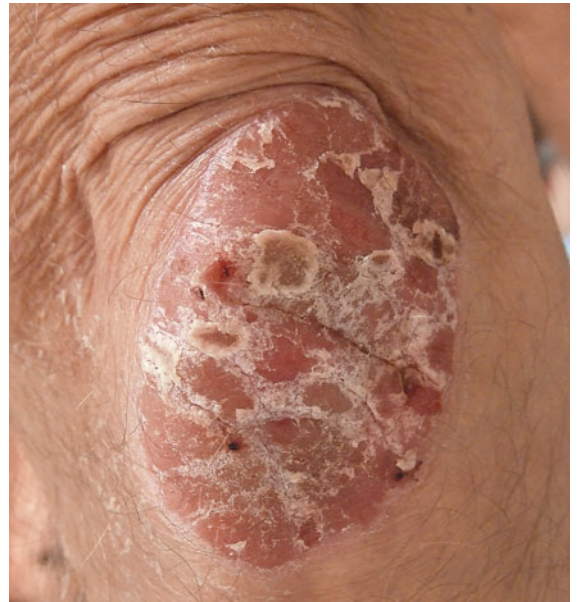Physical Examination

Psoriasis can vary in appearance and distribution. However, there are clues in the physical examination that allow the clinician to properly diagnose psoriasis and identify its subtypes.

- **Plaque-type psoriasis vulgaris** accounts for 90% of all cases. The primary lesion is a scaly, red- to salmon-pink-colored papule that expands centrifugally to form a similarly colored plaque (Figure 9-1). It is usually covered by a white or silvery scale that, when removed, may show pinpoint bleeding (Auspitz sign). Its border may be red and with time central clearing may occur, with the plaques taking on an annular or arcuate configuration. Plaque-type psoriasis is classically an extensor disease often involving the knees, elbows (Figure 9-2), gluteal cleft, lumbosacral region, and the umbilicus. Psoriasis may involve the scalp (Figure 9-3). Psoriatic plaques may occur in an area after trauma, pressure, or injury. This is known as the Koebner phenomenon.
- **Inverse psoriasis** presents with thin pink plaques with minimal scale in the axillae (Figure 9-4), inguinal and inframammary area, and body folds of the trunk. It may occur in conjunction with typical plaque psoriasis or it may be the only manifestation of psoriasis.

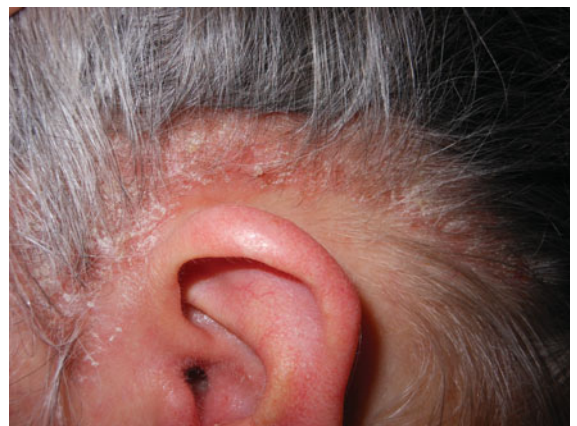

▲ **Figure 9-1.** Psoriasis. Pink plaques with silvery white scale. Note small area of bleeding in plaque with scale removed.

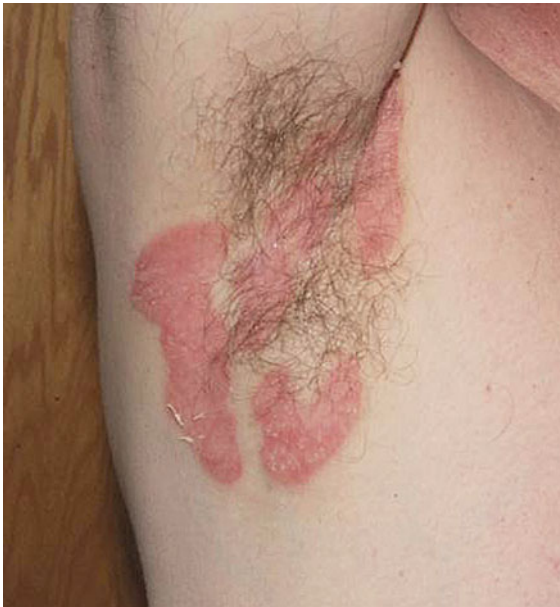

▲ **Figure 9-2.** Psoriasis. Red plaque on elbow with scale partially resolved after treatment with topical steroids.

- **Guttate psoriasis** occurs in less than 2% of cases, but it is a common psoriatic subtype in young adults. It is characterized by small “droplet-like” thin pink to salmon-colored papules and plaques surmounted by a fine white scale (Figure 9-5). The distribution is often similar to that of classic pityriasis rosea, favoring the trunk, abdomen, and upper thighs and fading toward the acral surfaces and sparing the palms and soles.

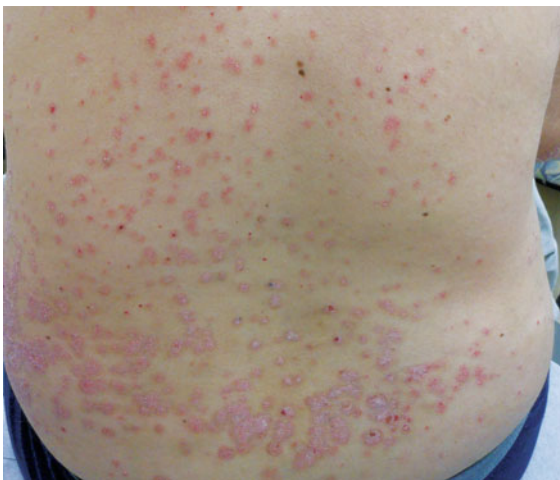

▲ **Figure 9-3.** Scalp psoriasis. Pink plaque with white scale along the hairline above the ear.

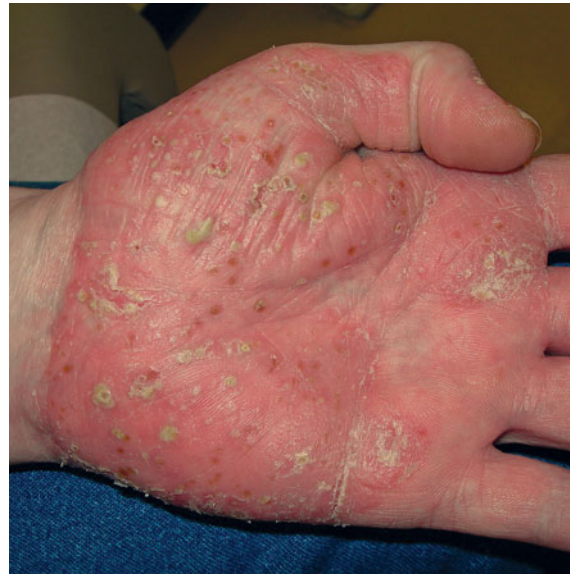

▲ **Figure 9-4.** Inverse psoriasis. Well-demarcated pink plaques with no scale in axilla.

- **Pustular psoriasis** (von Zumbusch) is an acute variant of the disease that presents with small, monomorphic sterile pustules surmounting painful, inflamed, erythematous papules. Fever, systemic symptoms, and an elevated white blood cell count often accompany generalized pustular psoriasis. Acral pustules, usually without systemic symptoms, characterize palmoplantar



▲ **Figure 9-5.** Guttate psoriasis. Pink papules and plaques with fine white scale.



▲ **Figure 9-6.** Pustular psoriasis on palm. Erythematous plaque with pustules.

pustulosis (Figure 9-6), which is a milder, but more common presentation of pustular psoriasis.

- **Erythrodermic psoriasis** is a skin reaction pattern of total body redness and desquamation of the skin. There are many causes of erythroderma and it is not specific to psoriasis. The massive shedding of skin that occurs during an erythrodermic flare of psoriasis can result in infection, hypothermia, protein loss, hypoalbuminuria, dehydration, and electrolyte disturbances.⁴
- **Psoriatic nails** can be seen in up to 50% of patients with psoriasis. It may be the only manifestation of psoriasis. It is recognized that nail disease is more closely linked with psoriatic joint disease. Up to 90% of patients with psoriatic arthritis have nail disease.⁴ Nail dystrophies associated with psoriasis include pitting, onycholysis (nail plate separation), oil spots (yellow-orange subungual discoloration), thickening, and subungual debris (Figure 20-3). Splinter hemorrhages may also be present.

▶ Laboratory Findings

Blood work is generally not necessary to make a diagnosis of psoriasis. Pustular flares of psoriasis during pregnancy may be associated with hypocalcemia. A biopsy is often helpful if the diagnosis is unclear. A punch biopsy of a plaque or pustule often supports the diagnosis. A biopsy is warranted in any patient not responding as expected to traditional therapy. The microscopic findings of common plaque-type psoriasis are epidermal hyperplasia, parakeratosis, thinning

of the granular layer, epidermal infiltration of neutrophils, and occasional “Munro abscesses” (intraepithelial collections of neutrophils).

Diagnosis

The key diagnostic clinical features of psoriasis are red to pink plaques with silvery white scale on the elbows, knees, scalp, and lower back and legs.

Differential Diagnosis

- ✓ The differential diagnosis of psoriasis includes other papulosquamous diseases (Table 9-1).

Table 9-1. Differential diagnosis of diseases presenting with papulosquamous lesions.

Diseases	Clinical Presentation
Psoriasis	Asymptomatic or mildly pruritic, pink-red plaques with white scale on scalp and extensor extremities. Bimodal age of onset at 22 and 55 years
Seborrheic dermatitis	Asymptomatic or mildly pruritic pink patches with fine greasy white scale on the scalp, eyebrows, ears, nasolabial folds, and central chest. More common in infants or after age 40
Pityriasis rosea	Asymptomatic 1-2 cm oval thin plaques with a fine central scale, a larger 2-10 cm “herald patch” may precede rash. Lasts 6-8 weeks. More common in teens and young adults
Nummular dermatitis	Pruritic well-defined pink scaly plaques on extremities but not necessarily on elbows and knees
Lichen planus	Pruritic violaceous flat-topped papules on volar wrists, forearms, ankles, and lower back
Subacute cutaneous lupus	Annular erythematous scaly plaques in sun-exposed areas and on trunk
Tinea corporis	Asymptomatic or mildly pruritic pink scaly plaques with a scaly border and central clearing
Secondary syphilis	Asymptomatic scaly papules or plaques on palms, soles, and trunk. History of preceding genital ulcer
Cutaneous T-cell lymphoma (mycosis fungoides)	Asymptomatic or mildly pruritic scaly well-defined plaques with random distribution. Lesions may also be annular or arcuate and are chronic and persist in the same location. Typically presents after age 50

Management

Topical steroids are the first-line treatment of mild to moderate psoriasis. They act as a foundation on which to build a therapeutic regimen for more severe disease. While topical regimens demonstrate efficacy in clinical trials, the response to these agents in everyday practice is often variable. Frequently, this is a result of poor compliance. Ointments are the most effective vehicles for psoriasis, but they stain clothing and bedding. Creams are better patient-accepted vehicles for the face, neck, and hands. Solutions and foams are appropriate for the scalp. Table 9-2 contains commonly used topical medications for psoriasis.

It is often advisable to begin therapy with one simple agent. In plaque-type psoriasis, superpotent topical steroids, such as clobetasol or betamethasone, are usually necessary to treat thick plaques.⁴ Scalp disease requires ultrapotent steroids in solution or foam vehicles. A simple regimen utilizing clobetasol or betamethasone twice a day for 2 to 4 weeks is an easy way to achieve efficacy. With time, the patient can move to an alternating regimen of vitamin D analogues, such as calcipotriol (calcipotriene) or calcitriol. These medications can be alternated by day (calcipotriol Monday to Thursday and clobetasol Friday to Sunday) or by application (calcipotriol in morning and clobetasol at bedtime). Topical vitamin D analogues may cause hypercalcemia; therefore, the weekly dose should be under 100 mg. A less potent topical steroid and more cost-effective agent such as triamcinolone, when utilized regularly, may be more effective than higher potency steroids. After finding the preferred vehicle and topical regimen for a patient, closely spaced follow-up visits improve adherence and will give the clinician opportunity to encourage continued compliance, and fine-tune the regimen based on the patient's condition.

In areas of thin skin such as the face, neck, axillae, groin, genitals, and body folds, lower potency steroids such as hydrocortisone 2.5%, desonide, and hydrocortisone valerate 2.5% are useful.⁵ Vitamin D analogues such as calcipotriene have traditionally not been used in these areas due to their tendency to cause inflammation.

Topical calcineurin-inhibiting agents are also quite useful for therapy of psoriasis.⁶ Tacrolimus ointment (0.1% for adults, 0.03% for children) may burn a bit on application, but seems to have slightly more efficacy than topical pimecrolimus. Because these medications are not corticosteroids, they do not cause skin atrophy, glaucoma, or many other steroid-related side effects. Thus, they are an effective, safe way to treat psoriasis on the face, in the skin folds, and around the eyes. In the United States these medications are Food and Drug Administration (FDA) approved only for atopic dermatitis and carry a black box warning for lymphoma.

Tazarotene (gel or cream, 0.05% or 0.1%) is a retinoid. It can be used as a steroid-sparing agent in a manner similar

Table 9-2. Topical medications for psoriasis.

Generic Name	Trade Name Examples	Formulations	Uses
Topical steroids			
Clobetasol	Temovate	Cream, gel, ointment, solution, foam, shampoo 0.05%	Super to high-potency steroids for use on localized areas of thick plaques on extremities and trunk BID initially for 2-4 weeks and then alternate with calcipotriene or calcitriol. Use solutions and foams and/or shampoos for scalp
Betamethasone dipropionate	Diprosone	Cream, gel, ointment, solution 0.05%	
Fluocinonide	Lidex	Cream, ointment 0.05%	
Triamcinolone		Cream, ointment 0.1%	Medium-potency steroid for chronic use to widespread plaques on extremities and trunk BID
Desonide	DesOwen	Cream, ointment 0.05%	Low-potency steroids for use on psoriasis face, groin, axillae in adults or psoriasis in children BID
Hydrocortisone	Hytone	Cream, ointment 2.5%, 1%	
Topical calcineurin inhibitors			
Tacrolimus Pimecrolimus	Protopic Elidel	Ointment 0.03%, 0.1% Cream 1%	Psoriasis on face, axillae, groin, and genitals BID
Topical vitamin D ₃ analogues			
Calcipotriol (calcipotriene) Calcitriol	Dovonex Vectical	Cream, solution 0.005% Ointment	Typically used in combination therapy with topical steroids in adults. Weekly dose should not exceed 100 g
Calcipotriene + betamethasone dipropionate	Taclonex	Ointment, suspension, spray	For use in adults >18 years old for up to 4 weeks. Should not be used on face, axillae, or groin. Weekly dose should not exceed 100 g
Topical retinoid			
Tazarotene	Tazorac	Cream, gel 0.05%, 0.1%	For use in thick plaques in adults in combination with topical steroids. Pregnancy category X
Topical salicylic acid			
Salicylic acid	Kerlalyt Scalpicin	Gel 3%, 6%; solution 3%, shampoo 3%	For use in thick plaques in combination with topical steroids

to the vitamin D analogues. This agent tends to cause more inflammation than calcipotriene. Therefore, patients may find that tazarotene fits best into their regimen when applied in conjunction with topical steroids. Tazarotene is in pregnancy category X.

In the setting of hyperkeratotic, scaly plaques there may be a role for keratolytics to remove scale and facilitate penetration of the topical steroid and/or vitamin D analogue. Salicylic acid, urea, and lactic acid are agents that can be added to a regimen for this purpose. Salicylic acid comes as a cream, gel, cream, or shampoo in concentrations that range from 2% to 10%.

Topical coal tar products have an anti-inflammatory effect in psoriasis and can be used in conjunction with topical steroids and keratolytic agents. Examples of tar products include Estar, Fototar, PsoriGel, and Neutrogena T/Derm Tar Emollient.

Emollients may aid treatment of psoriasis. They can improve efficacy and lower the economic burden of other

topical agents by softening the stratum corneum through hydration and reduction of superficial scale. A daily bath in warm water, followed by application of petrolatum and supplemented by 2 or 3 further applications of a moisturizer during the day, is a beneficial addition to any treatment regimen.⁴

Pediatric Psoriasis

There is a dearth of evidence regarding treatment of psoriatic disease in children. The lack of good, double-blinded, placebo, controlled trials is not specific to psoriasis treatment, but it does make foretelling the future consequences of one's therapeutic decisions in this population quite difficult. Most of the principles discussed above with regard to adults still hold for the pediatric population. In the pediatric population one must, of course, consider long-term side effects due to lengthy exposure to immunomodulators.

Psoriatic Arthritis

Every patient with psoriasis should be specifically screened for joint disease and enthesitis (inflammation of the tendon insertions).⁴ History of morning stiffness, joint tenderness, swelling, sausage digits, and involvement of the peripheral small joints is characteristic. The hands are the most common site of involvement. Enthesitis usually occurs at the insertion sites of the Achilles tendon, the plantar fascia, and ligamentous attachment points of the rib, spine, and pelvis. Musculoskeletal involvement can present at any time, but most often between the ages of 30 and 50 years.

Comorbidities in Patient with Psoriasis

Psoriasis is an independent risk factor for atherosclerosis, coronary artery disease, myocardial infarction, stroke, and cardiovascular mortality. Patients with psoriasis are more likely to have other cardiovascular risk factors such as diabetes, hypertension, dyslipidemia, tobacco use, and obesity.^{4,7}

Potential Causes of Flares of Psoriasis

Group A beta-hemolytic streptococci infection can act as an environmental trigger for guttate psoriasis particularly in the pediatric population.⁴ Many clinicians will obtain an antistreptolysin-O, antihyaluronidase, anti-DNase-B, and streptozyme titer along with streptococcal cultures of the throat and perianal area as part of the initial workup of pediatric psoriasis. Other commensal organisms on the skin may play a role in specific variants of psoriasis. Management of these microbes can be an adjunct to psoriatic treatment.

Common medications that may exacerbate psoriasis include beta-blockers, ACE inhibitors, nonsteroidal anti-inflammatory drugs, lithium, interferon, and antimalarials.⁴ Systemic corticosteroids, although providing short-term benefit in control of psoriasis, are not recommended. Abrupt discontinuation of the drug commonly exacerbates the disease.

Psychiatric comorbidities such as anxiety and depression may exacerbate psoriasis. Stress is also common trigger of psoriasis.³ Thus, psoriatic patients may benefit from psychological intervention.

Indications for Consultation

Dermatological consultation is indicated when topical medications have not been effective and ultraviolet light or systemic therapy are needed. These therapies include office- or home-based narrow-band ultraviolet B or A light therapy, light therapy with psoralens (PUVA), Goeckerman therapy (light therapy with tar), acitretin, methotrexate, biologics (etanercept, adalimumab, alefacept, infliximab, ustekinumab, golimumab, etc), and cyclosporine.⁸

Pregnant or lactating women with psoriasis should be managed by obstetrics and dermatology.⁹

All systemic comorbidities should be monitored and discussed with patients, with consultation to specialists when appropriate as discussed above. Rheumatologic consultation is indicated if signs or symptoms of psoriatic joint disease or enthesitis are present.

Patient Information

- The National Psoriasis Foundation: www.psoriasis.org
- Youth and Parents: www.PsoMe.org
- Arthritis and Psoriasis: www.rheumatology.org
- The Arthritis Foundation: www.arthritis.org
- National Institute of Arthritis and Musculoskeletal and Skin Diseases Information Clearinghouse: www.niams.nih.gov

SEBORRHEIC DERMATITIS

Introduction

Seborrheic dermatitis is a common skin disorder that involves the scalp and other areas of high sebaceous gland activity such as the central face and chest. It can present at any age, but its peak incidence occurs in infants and middle-aged adults. Seborrheic dermatitis is more prevalent and more severe in patients with acquired immunodeficiency syndrome (AIDS) and neurological disorders.

Pathophysiology

Etiology is dependent on 3 factors, sebum, *Malassezia* yeast, and individual susceptibility. Recent work has revealed that *Malassezia globosa* and *Malassezia restricta* predominate and oleic acid alone can initiate dandruff-like desquamation.¹⁰

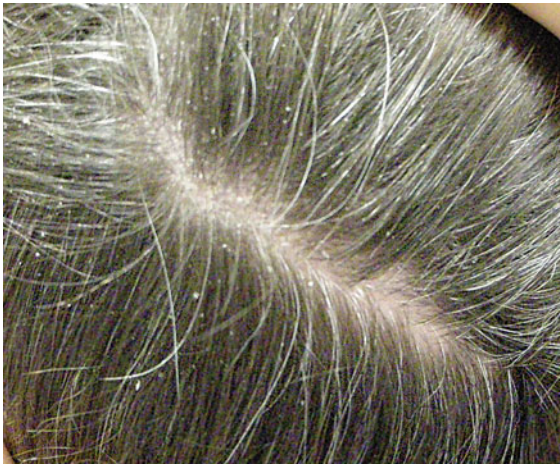Clinical Presentation

History

The patient typically complains of a dry, scaly or flaky, itchy scalp.

Physical Examination

Infants usually present with “cradle cap,” pink to yellow macules, and patches with white greasy scales on the scalp. The face, trunk, and diaper areas may also be affected. Adolescents and adults also present with scalp involvement most commonly with “dandruff,” white flakes with no erythema (Figure 9-7). Moderate to severe seborrheic dermatitis is characterized by erythematous plaques with white greasy scales. It may involve the forehead, eye brows, eyelash line, nasolabial folds, and ears (Figure 9-8) and less commonly the upper chest and intertriginous areas.



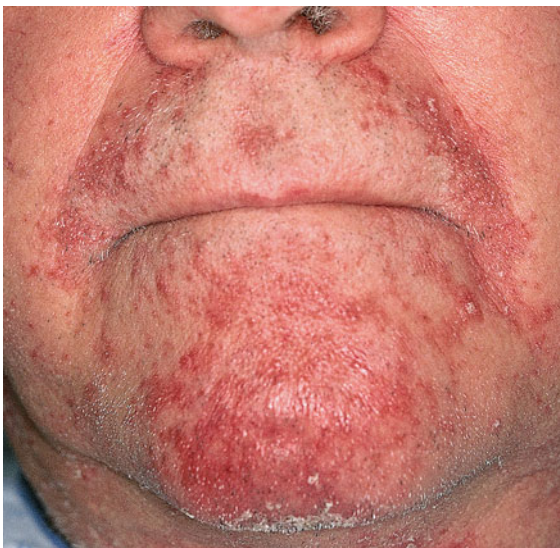▲ **Figure 9-7.** Seborrheic dermatitis. Loose white flakes with no erythema on scalp.

► Laboratory Findings

Skin biopsies are usually not diagnostic and are only helpful to rule out other disorders.

Diagnosis

The key diagnostic clinical features of seborrheic dermatitis are pink plaques with fine greasy white scale on the scalp, eyebrows, nasolabial fold, and ears.



▲ **Figure 9-8.** Seborrheic dermatitis. Erythema and scale in the nasolabial folds and chin.

► Differential Diagnosis

- ✓ The differential diagnosis includes other papulosquamous diseases (Table 9-1).
- ✓ **Atopic dermatitis:** Atopic children and to some degree adults may have scaly lesions in the scalp; however, they usually have areas of involvement on the extremities, particularly in the flexural regions.
- ✓ **Tinea capitis:** *Trichophyton tonsurans* fungal infections in children, especially in African American children, may be indistinguishable from seborrheic dermatitis. Fungal cultures or potassium hydroxide (KOH) examinations are needed to clarify the diagnosis.
- ✓ Other common diseases include rosacea and contact dermatitis.
- ✓ **Uncommon diseases:** Dermatomyositis and Langerhans cell histiocytosis (children).

Management

- Mild scalp seborrheic dermatitis can usually be controlled with over-the-counter shampoos containing zinc pyrithione (Head and Shoulders), selenium sulfide (Selsun), coal tar (Neutrogena T-Gel), salicylic acid (Neutrogena T-Sal), or ketoconazole (Nizoral A-D). Patients should be instructed to shampoo 3 to 5 times a week.
- Moderate to severe scalp disease can be treated with prescription shampoos that contain selenium sulfide 2.5% (Selsun), ketoconazole (Nizoral) 2%, fluocinonide acetate 0.01% (Capex), or clobetasol (Clobex) 0.05%. Topical steroid solutions such as fluocinonide 0.05% can be used sparingly twice a day.¹¹
- Facial involvement can be managed with sparing use of hydrocortisone 1% cream daily and/or topical antifungal agents such as clotrimazole 1% cream, miconazole 2% cream, and ketoconazole 2% cream. Tacrolimus ointment and pimecrolimus cream are commonly used for facial disease. However, they only are FDA approved for use in atopic dermatitis.^{6,11}

Seborrheic dermatitis usually responds well to treatment, but it is a chronic condition requiring long-term therapy.

Indications for Consultation

Severe or persistent disease that does not respond to treatment, especially in children in whom the presence of persistent seborrheic dermatitis could indicate more serious underlying disease.

Patient Information

PubMed Health: www.ncbi.nlm.nih.gov/pubmedhealth/PMH0001959/

PITYRIASIS ROSEA

Introduction

Pityriasis rosea is an acute, self-limited papulosquamous exanthem that, generally, lasts between 6 and 8 weeks (average 45 days), resolving on its own. Cases are frequently noted in clusters, with no seasonal preference. Patients are typically young adults, average age at presentation is 10 to 35 years, and females are slightly more affected (1.5:1).¹²

Pathophysiology

The etiology of pityriasis rosea remains an area of debate. Several factors suggest an infectious agent based on clustering of cases, self-limited nature, and rare recurrences. The current proposed pathogen is human herpes virus (HHV)-6 and/or HHV-7 with either a reactivation or primary infection.^{12,13} Some support for this theory has come from the increased incidence in pregnancy, a relative immunosuppressed state, as well as studies identifying HHV-6 and HHV-7 using polymerase chain reaction (PCR) in affected individual's skin. Pregnant women who develop pityriasis rosea within 15 weeks of gestation may have an active HHV-6 infection and may have a premature delivery with neonatal hypotonia or even fetal death.¹²

Clinical Presentation

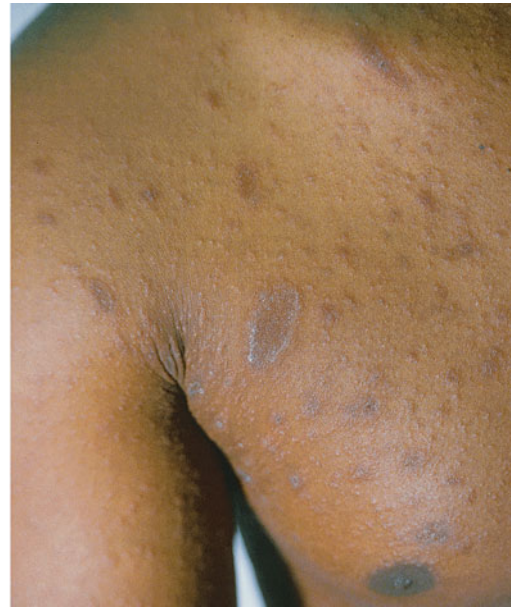History

The most commonly reported symptom is itch. Occasionally a viral-like constitutional prodrome or symptoms of an upper respiratory infection may precede the onset of cutaneous lesions.

Physical Examination

Pityriasis rosea typically presents initially with a single herald patch, which is a pink-salmon-colored, oval, 2 to 10 cm plaque with central fine collarette scale (Figure 9-9).

The subsequent lesions are smaller (1-2 cm) pink-salmon-colored papules and plaques on the trunk and extremities. They also have fine central or a collarette of scale. They typically develop in the lines of cleavage (Langer's), symmetrically, and result in a "Christmas tree" distribution. The face, scalp, hands, and feet are usually spared. Lymphadenopathy may be present. Pigmented skin alters the color of lesions with a violet-gray color spectrum as opposed to pink. It is more common to see involvement on the head in darker pigmented individuals as well.



▲ **Figure 9-9.** Pityriasis rosea. Herald patch with collarette scale and multiple smaller lesions with similar morphology.

Reported variants include papular, vesicular, urticarial, purpuric, inverse pityriasis rosea, and absent or numerous herald patches.

Laboratory Findings

As pityriasis rosea is a clinical diagnosis made by history and physical examination, laboratory studies are usually unnecessary. However, if there is diagnostic uncertainty, a skin biopsy or a KOH scraping should be done to aid in the diagnosis. A rapid plasma regain (RPR) should be done in any patient at risk for syphilis.

Diagnosis

The key diagnostic clinical features of pityriasis rosea are an initial herald patch, an oval plaque with a collarette (scale) followed by a symmetric, secondary eruption in a "Christmas tree" pattern.

Differential Diagnosis

- ✓ The differential diagnosis includes other papulosquamous diseases (Table 9-1).
- ✓ **Drug-related eruptions:** Barbiturates, captopril, clonidine, metronidazole, penicillamine, isotretinoin, levamisole, NSAIDs, omeprazole, and terbinafine.
- ✓ **Vaccine-related eruptions:** A handful of vaccinations have rare reported occurrences of pityriasis

rosea like eruptions; these include diphtheria, pneumococcal, hepatitis B, BCG, and smallpox.

- ✓ **Other:** Viral exanthems, pityriasis lichenoides chronica, lichen planus, and erythema dyschromicans perstans.

Management

As pityriasis rosea is a self-healing, self-limited benign eruption, treatment is not required. The most important “intervention” is patient education and reassurance. The diffuse, rapid eruption is often disconcerting to patients and parents. In fact, a study on the impact of PR on quality of life showed that concerns of etiology and infectivity had greater impact than rash severity.¹⁴ Reassurance of the self-limited, noncontagious nature of the eruption is important.

Additionally, no treatments can be recommended on the basis of evidence-based medicine. A recent Cochrane review showed insufficient evidence for nearly all interventions such as emollients, topical antihistamines, steroids, light therapy, and antimicrobials.¹⁵ Based on the proposed correlation with HHV-6 and HHV-7 acyclovir has been studied at both high and low doses, but is not commonly used.¹²

If treatment is needed, it is empiric and focuses on symptomatic relief, namely, controlling pruritus.^{12,13} Regular application of emollients can be helpful. Lotions with camphor, menthol, pramoxine, or oatmeal could provide added antipruritic benefit. Use of sedating (diphenhydramine, hydroxyzine) and nonsedating (cetirizine) antihistamines can also provide relief. Medium-potency topical steroids, such as triamcinolone or fluocinonide, may provide an additional antipruritic benefit as well as improve the inflamed appearance of lesions. In more severe or recalcitrant disease systemic steroids may be considered. Phototherapy (usually narrow-band UVB) may provide symptomatic relief, but requires a referral to a treatment center, and has not been shown to decrease the duration of disease.

Indications for Consultation

Severe or nonresolving case with recalcitrant pruritus. Additionally, in light of the recent question of obstetric complications a referral for pregnant patients to maternal fetal medicine or alerting the patient's obstetrician may be prudent.¹²

Patient Information

- PubMed Health: www.ncbi.nlm.nih.gov/pubmed-health/PMH0001874/
- AFP Review Handout: www.aafp.org/afp/2004/0101/p94.html

LICHEN PLANUS

Introduction

Lichen planus is an uncommon papulosquamous skin disorder. It affects all age groups but is most common between the ages of 30 and 60.¹⁶ Children and infants are not commonly affected. There are no gender or racial predispositions.

Pathophysiology

Lichen planus is thought to occur as a result of an immune dysfunction with altered surface keratinocyte antigen presentation and subsequent cytotoxic T-cell reaction.¹⁷ A genetic susceptibility has been proposed. The skin eruption has been associated with systemic drugs and hepatitis C virus, but a definitive cause has not been identified. Common drugs linked to lichen planus are gold, antibiotics, diuretics, and antimalarials.

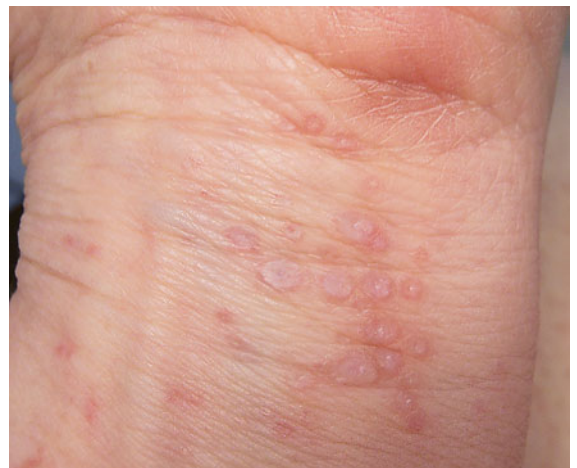Clinical Presentation

History

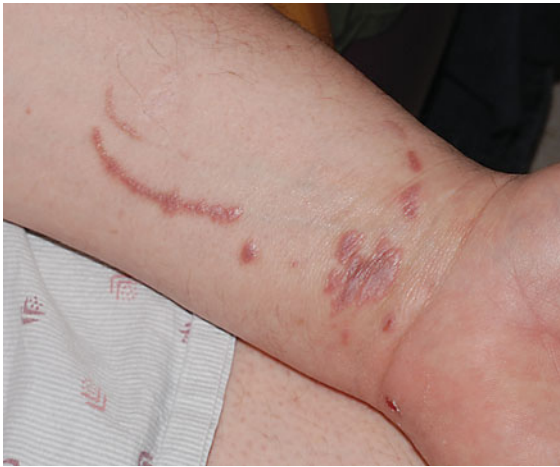Patients usually present with a complaint of itching and onset of red bumps. The pruritus can range from mild to severe with an occasional patient having no symptoms. If LP affects the mouth, symptoms such as burning or stinging on exposure to hot or spicy foods is sometimes elicited.

Physical Examination

The primary lesions of lichen planus are violaceous flat-topped papules (Figure 9-10). These may be scaly, and



▲ **Figure 9-10.** Lichen planus. Violaceous flat-topped papules with fine white lines (Wickham striae) on flexural wrist.



▲ **Figure 9-11.** Lichen planus. Linear streaks of papules demonstrating the Koebner response.

round or polygonal in shape. The lesions are distributed symmetrically, typically on the flexor wrists, forearms, ankles, lower back, and genitals. Mucous membrane lichen planus is often present and appears as net-like white streaks on the buccal mucosa (Wickham striae) (Figure 38-28). Oral ulceration may be present. Scalp lesions with a scarring alopecia may be the only manifestation of the disease. A unique feature of lichen planus is its ability to Koebnerize (Figure 9-11). This phenomenon is triggered by trauma, with resultant lichen planus observed in the area of injury. Sometimes generalized and localized hypertrophic forms occur. Hypertrophic lichen planus most often involves the anterior shins and the papulonodules show marked hyperkeratosis.

► Laboratory Findings

The most useful diagnostic test is a skin biopsy. The biopsy shows a uniform band-like lymphocytic infiltrate at the base of the epidermis. In some instances the histologic finding can suggest drug-induced lichen planus.¹⁶

Diagnosis

The key diagnostic clinical features of lichen planus are pruritic flat-topped papules on the flexor areas, lower back, and ankles.

► Differential Diagnosis

- ✓ The differential diagnosis includes other papulosquamous diseases (Table 9-1).
- ✓ **Scabies:** Presents with tiny excoriated papules and/or vesicles in many of the same areas as lichen planus.

- ✓ **Lichenoid drug rash:** May be indistinguishable from lichen planus.

Management

Removal of the offending agent is the first step, if one is identified. Drug-induced lichen planus and hepatitis C are common conditions that may present with a lichenoid skin eruption.^{16,18} Lichen planus can be treated with medium-potency corticosteroids applied to the affected area 1 to 3 times daily.¹⁸ When the eruption is controlled, the frequency of drug use can be reduced or eliminated. If corticosteroids are used for prolonged periods, care must be taken to avoid drug-induced secondary changes such as atrophy.

Indications for Consultation

Unusual presentations or widespread distribution of a lichenoid eruption should be considered for consultation. Additionally, moderate to severe oral disease may require consultation with a specialist.

Patient Information

- Lichen Planus Support Group: www.mdjunction.com/lichen-planus
- American Academy of Dermatology: www.aad.org/skin-conditions/dermatology

REFERENCES

1. Pusey WA. *The History of Dermatology*. Springfield, IL, Baltimore, MD: C.C. Thomas; 1933.
2. Chandran V, Raychaudhuri SP. Geoepidemiology and environmental factors of psoriasis and psoriatic arthritis. *J Autoimmun*. 2010;34(3):J314–J321. PMID: 20034760.
3. Griffiths CE, Barker JN. Pathogenesis and clinical features of psoriasis. *Lancet*. 2007;370(9583):263–271. PMID: 17658397.
4. Patel RV, Lebwohl M. In the clinic. Psoriasis. *Ann Intern Med*. 2011;155(3):ITC2-1–ICT2-15. PMID: 21810705.
5. Wozel G. Psoriasis treatment in difficult locations: scalp, nails, and intertriginous areas. *Clin Dermatol*. 2008;26(5):448–459. PMID: 18755363.
6. Lin AN. Innovative use of topical calcineurin inhibitors. *Dermatol Clin*. 2010;28(3):535–545. PMID: 20510763.
7. Mehta N, Yu Y, Pinnelas R, et al. Attributable risk estimate of severe psoriasis on major cardiovascular events. *JAMA*. 2011;324(8):775.e1–775.e6. PMID: 21787906.
8. Hsu S, Papp KA, Lebwohl MG, et al. Consensus guidelines for the management of plaque psoriasis. *Arch Dermatol*. 2012; 148(1):95–102. PMID: 22250239.
9. Bae YC, Van Voorhees AS, Hsu S, et al. Review of treatment options for psoriasis in pregnant or lactating women: from the Medical Board of the National Psoriasis Foundation. *J Am Acad Dermatol*. 2012;67(3):459–477. PMID: 22018758.
10. Xu J, Saunders CW, Hu P, et al. Dandruff-associated *Malassezia* genomes reveal convergent and divergent virulence traits

- shared with plant and human fungal pathogens. *Proc Natl Acad Sci U S A*. 2007;104(47):387–396. PMID: 18004291.
11. Naidi L, Rebora A. Clinical practice. Seborrheic dermatitis. *N Engl J Med*. 2009;360(4):387–396. PMID: 19164189.
 12. Drago F, Broccoli F, Rebora A. Pityriasis rosea: an update with a critical appraisal of its possible herpes viral etiology. *J Am Acad Dermatol*. 2009;61(2):303–318. PMID: 19615540.
 13. Gonzalez LM, Allen R, Janniger CK, Schwartz RA. Pityriasis rosea: an important papulosquamous disorder. *Int J Dermatol*. 2005;44(9):757–764. PMID: 16135147.
 14. Chuh AA, Chan HH. Effect on quality of life in patients with pityriasis rosea: is it associated with rash severity? *Int J Dermatol*. 2005;44(5):372–377. PMID: 15869534.
 15. Chuh AA, Dofitas BL, Comisel GG, et al. Interventions for pityriasis rosea. *Cochrane Database Syst Rev*. 2007;18(2):CD005068. PMID: 17443568.
 16. Boyd AS, Neldner KHG. Lichen planus. *J Am Acad Dermatol*. 1991;25(4):593–619. PMID: 1791218.
 17. Sugarman PB, Satterwhite K, Bigby M. Autocytotoxic T-cell clones in lichen planus. *Br J Dermatol*. 2000;142:449–456. PMID: 10735949.
 18. Cribier B, Frances C, Chosidow O. Treatment of lichen planus. *Arch Dermatol*. 1998;134:1521–1530. PMID: 9875189.

Superficial Fungal Infections

Steven Prawer
Scott Prawer
Andrea Bershow

10

Introduction to Chapter / 71
Introduction to Dermatophyte Infections / 71
Tinea Capitis / 72
Tinea Corporis / 74
Tinea Manuum / 77
Tinea Cruris / 78
Tinea Pedis / 79

Onychomycosis (Tinea Unguium) / 81
Introduction to Superficial
Yeast Infections / 83
Tinea Versicolor / 83
Candidiasis / 84
References / 86

INTRODUCTION TO CHAPTER

Most superficial fungal infections of the skin are caused by dermatophytes or yeasts. They rarely cause serious illness, but fungal infections are often recurrent or chronic in otherwise healthy people. The availability of effective over-the-counter antifungal medications has been helpful to people with actual fungal infections, but these medications are frequently used by people who actually have other skin diseases such as dermatitis. One of the main diagnostic problems with fungal infections is that they closely resemble dermatitis and other inflammatory disorders. Both clinicians and patients overdiagnose and underdiagnose fungal infections. A few simple clinical points can help avoid misdiagnoses:

- Many inflammatory skin diseases such as nummular dermatitis present with an annular pattern and are often misdiagnosed as tinea corporis.
- Dermatitis and dermatophyte infections on the feet have a very similar appearance. However, the presence of toe web scale and nail plate thickening is more characteristic of a fungal infection.
- Half of all nail disorders are caused by fungus. The other causes of nail diseases such as psoriasis and lichen planus may appear very similar to fungal infections.

- Fungal infections are rare on the hands, but when they do occur they are almost indistinguishable from irritant contact dermatitis or dry skin.
- Fungal infections on the scalp are rare after puberty.
- The diagnosis of a suspected fungal skin infection should be confirmed with a potassium hydroxide (KOH) examination or fungal culture.

INTRODUCTION TO DERMATOPHYTE INFECTIONS

Dermatophytes can penetrate and digest keratin present in the stratum corneum of the epidermis, hair, and nails. Superficial dermatophyte infections are a common cause of skin disease worldwide, especially in tropical areas. The names of the various dermatophyte infections begin with “tinea,” which is a Latin term for “worm.” The second word in the name is the Latin term for the affected body site:

- Tinea capitis—scalp
- Tinea barbae—beard
- Tinea faciei—face
- Tinea corporis—trunk and extremities
- Tinea manuum—hands
- Tinea cruris—groin

- Tinea pedis—feet
- Tinea unguium (onychomycosis)—nails

Three dermatophyte genera and 9 species are responsible for most infections in North America and Europe.

- *Trichophyton*: *rubrum*, *tonsurans*, *mentagrophytes*, *verrucosum*, and *schoenleii*
- *Microsporum*: *canis*, *audouinii*, and *gypseum*
- *Epidermophyton*: *floccosum*

The species within these genera may be further classified according to their host preferences:

- Anthropophilic—human
- Zoophilic—animal
- Geophilic—soil

Infections can occur by direct contact with infected hosts or fomites.

Dermatophyte infections can mimic many common skin rashes. Therefore, it is important to confirm the diagnosis of a suspected fungal infection with a microscopic examination using KOH or with cultures.

Proper specimen collection is very important (Table 4-1). False-negative results can occur when specimens are taken from the wrong site or when insufficient volume is collected or when the patient has been using antifungal medications.

Most dermatophyte infections can be confirmed by performing a KOH examination (Table 4-1).

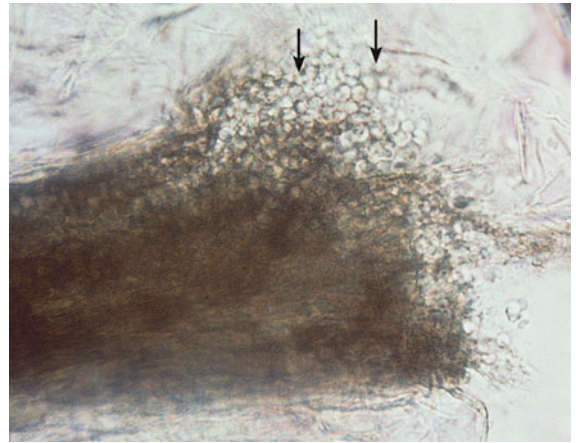
However, fungal cultures may be needed, especially in scalp and nail infections.

Cultures for dermatophytes are usually done on modified Sabouraud agar, such as dermatophyte test media (DTM) or Mycosel™ or Mycobiotic™. DTM contains an indicator dye that turns red within 7 to 14 days in the presence of dermatophytes. Identification of the specific species may be helpful in certain cases of tinea capitis and in the identification of zoophilic infections that may require treatment of the host animal. Specimens for culture can be placed in a sterile Petri dish or in a sterile urine cup and transported to the lab for placement on agar. If agar plates are available at the site of care, the specimens can be placed directly into the agar.

TINEA CAPITIS

Introduction

Tinea capitis (ringworm of the scalp) is a superficial dermatophyte infection of the hair shaft and scalp. It is most common in children 3 to 7 years old and it is uncommon after puberty. One study of 200 urban children showed a 4% overall incidence of asymptomatic colonization and a 12.7% incidence in African American girls.¹ Tinea capitis is endemic in many developing countries, and can be associated with crowded living conditions.



▲ **Figure 10-1.** Fungal spores within hair fiber (endothrix) in KOH preparation of *T. tonsurans* infection.

Pathophysiology

Trichophyton tonsurans causes 90% of the cases in North America and in the United Kingdom.

T. tonsurans fungal spores are confined within the hair shaft (endothrix) (Figure 10-1) and their presence can lead to hair breakage, creating “black dots” on the scalp. The spores are spread by person to person contact and by fomites such as combs, brushes, and pillows.

Microsporum canis is a more common pathogen in Europe, especially in the Mediterranean region.² Its fungal spores are present primarily on the surface of the hair shaft (ectothrix). The spores are spread by contact with an infected animal, such as a dog or cat, or by contact with an infected person.

Clinical Presentation

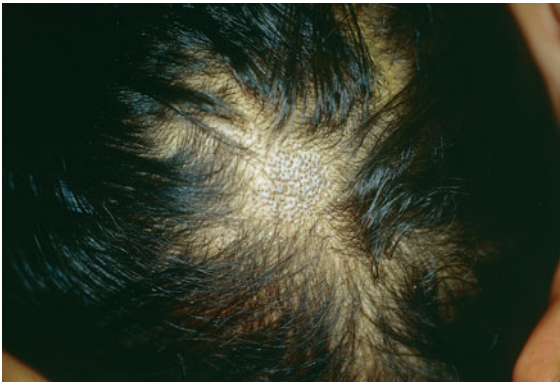
History

The clinical presentation depends on the pattern of tinea capitis. It may vary from mild pruritus, with flaking and no hair loss, to multiple scaly areas of alopecia, with erythema, pustules, or posterior cervical lymphadenopathy.

Physical Examination

There are 6 patterns of tinea capitis:

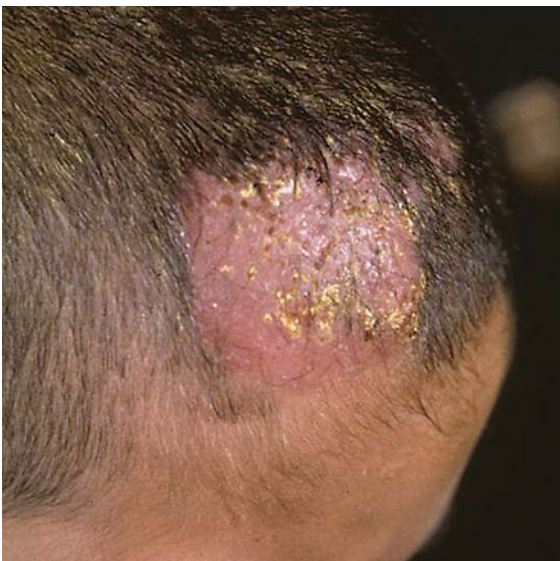- Dandruff-like adherent scale, with no alopecia
- Areas of alopecia dotted with broken hair fibers that appear like black dots (Figure 10-2)
- Circular patches of alopecia with marked gray scales. This is most commonly seen in *Microsporum* infections
- “Moth-eaten” patches of alopecia with generalized scale
- Alopecia with scattered pustules



▲ **Figure 10-2.** Tinea capitis. Area of alopecia with multiple broken hair fibers forming “black dot” pattern.

- Kerion, a boggy, thick, tender plaque with pustules (Figure 10-3) that is caused by a marked inflammatory response to the fungus. This is often misdiagnosed as a tumor or bacterial infection

Occipital lymphadenopathy is often present in tinea capitis. Green-blue fluorescence with Wood's light is seen in *Microsporum* infections, due to the ectothrix nature of the dermatophyte. Wood's light examination of tinea capitis caused by *T. tonsurans* is negative, because the fungal spores are within intact hair fibers.



▲ **Figure 10-3.** Kerion on child's scalp. Thick boggy plaque with pustules.

► Laboratory Findings

KOH examination or cultures of the proximal hair fiber and scalp scales should be performed to confirm the diagnosis. Table 4-1 lists some child-friendly techniques for specimen collection of scalp scales and techniques for collection of the proximal hair shaft.

KOH examination of the proximal hair fiber of *T. tonsurans* infections shows large spores within the hair shaft (endothrix) (Figure 10-1). *Microsporum* infections have smaller spores, primarily on the surface of the hair shaft (ectothrix). KOH evaluation of hair fiber specimens can be difficult, and interevaluator variability is common.

Use of DTM cultures is a nonspecific way of confirming dermatophyte infection. A color change in the media (from yellow to red) is usually noted within 2 weeks if a dermatophyte is present. However, this gives no information on the specific organism. Other agar-based cultures can take up to 4 to 6 weeks. Species identification can also be done if needed, especially if a pet animal is thought to be the source.

Diagnosis

The key diagnostic clinical features of tinea capitis are patches of alopecia (with scale or black dots) or diffuse scaling with no alopecia. It occurs primarily in children and occipital lymphadenopathy is often present.

► Differential Diagnosis

- ✓ **Alopecia areata:** Presents with alopecia, but there is no significant scale.
- ✓ **Seborrheic dermatitis:** Presents with mild pruritus, localized or diffuse scale on the scalp; typically there is no significant hair loss.
- ✓ **Psoriasis:** Presents with red, localized or diffuse silvery scaly plaques on the scalp. Similar plaques on the elbows and knees or elsewhere on the body are usually seen.
- ✓ **Bacterial infections and tumors:** These may closely resemble a kerion. However, tumors are rare in children and when they do occur, they should be biopsied to confirm the diagnosis.
- ✓ **Other:** Head lice, traction alopecia, trichotillomania, and Langerhans cell histiocytosis.

Management

Unlike other superficial fungal infections of the skin, tinea capitis does not respond to topical therapy alone. Systemic therapy is needed to penetrate the hair shaft and eradicate the infectious spores. Oral griseofulvin has been the gold standard of therapy for the past 45 years based on its cost and efficacy, and griseofulvin is the preferred antifungal medication for a kerion infection. It should be taken with

Table 10-1. Griseofulvin pediatric dosing regimen for tinea capitis.

Medication and Formulations	Pediatric Dosage	Duration
Griseofulvin microsize (Grifulvin V) Available in 250 or 500 mg tablets or 125 mg/5 mL oral suspension	Package insert recommends 10-20 mg/kg/day, but 20-25 mg/kg/day in single or divided doses is more commonly used. ^{3,4} Maximum dose is 1 g/day Dosage for children 2 years and younger has not been established	4-8 weeks May need up to 12 weeks if not cleared
Griseofulvin ultramicrosize (Gris-PEG) Available in 125 and 250 mg tablets	Package insert recommends approximately 5-10 mg/kg/day, but 10-15 mg/kg/day is more commonly used. ^{3,4} Maximum dose is 750 mg/day	4 to 6 weeks Up to 12 weeks if not cleared

a fatty meal or with whole milk or ice cream to improve absorption. Common side effects of griseofulvin include rash, headache, diarrhea, nausea, and vomiting. Elevated liver function tests are rare. Table 10-1 contains the recommended pediatric dosage schedule for griseofulvin.

Terbinafine, itraconazole, and fluconazole are alternatives to griseofulvin⁵ (Table 10-2). These medications are more costly, may occasionally be hepatotoxic and have the potential for several drug interactions. However, the duration of treatment with these alternative medications is shorter and in some conditions, they are more effective. A recent meta-analysis suggested that terbinafine is more effective in *Trichophyton* infections, but griseofulvin is more effective in *Microsporum* infections.⁶ Baseline liver enzyme tests and a complete blood count are recommended in pediatric patients.

In addition, 2% ketoconazole (Nizoral) shampoo and 1% or 2.5% selenium sulfide (Selsun) shampoo should be used 2 to 3 times a week for 5 to 10 minutes during therapy to reduce surface fungal colony counts.

It is important to clean combs, brushes, and hats to prevent reinfection. Reinfection can also occur if household contacts or pets remain infected.

The use of oral steroids for a kerion infection remains controversial. However, if significant hair loss is noted, they should be considered, as the inflammation that occurs with a kerion can result in scarring alopecia.

Indications for Consultation

Severe or persistent disease that does not respond to treatment.

Table 10-2. Pediatric dosing regimen for alternative oral antifungal medications for tinea capitis.

Medications and Formulations	Pediatric Dose	Duration
Terbinafine ^{3,4} (Lamisil) 250 mg tablet	62.5 mg daily for body weight of 10-20 kg 125 mg daily for body weight of 20-40 kg 250 mg daily for body weight greater than 40 kg	2-4 weeks, up to 8 weeks for <i>Microsporum</i> infections
Terbinafine (Lamisil) oral granules sprinkled into nonacid foods such as pudding 125 mg in a packet 187.5 mg in packet	125 mg daily for body weight less than 25 kg 187.5 mg daily for body weight 25-35 kg 250 mg daily for body weight greater than 35 kg	6 weeks
Itraconazole ^{3,4} (Sporanox) 100 mg capsule	Capsules: 5 mg/kg/daily	2-6 weeks
Fluconazole ^{3,4} 50, 100, 200 mg tablets or oral powder for suspension	5-6 mg/kg/day	3-6 weeks

Note: None of these medications are U.S. Food and Drug Administration (FDA) approved for tinea capitis, with the exception of terbinafine granules.

Patient Information

PubMed Health: www.ncbi.nlm.nih.gov/pubmedhealth/PMH0001881/

TINEA CORPORIS

Introduction

Tinea corporis (ringworm) is a dermatophyte infection primarily of the skin of the trunk and limbs. It can occur at any age. Outbreaks are more frequent in day care facilities and schools. Epidemics can occur in wrestlers. It is more common in hot and humid areas, farming communities, and crowded living conditions.

Pathophysiology

Tinea corporis is caused most frequently by the anthropophilic fungi, *Trichophyton rubrum* or *Trichophyton mentagrophytes*, or the zoophilic fungus, *M. canis*, which is spread by contact with cats and dogs and other mammals.

These fungi can more easily infect inflamed or traumatized skin.

Clinical Presentation

History

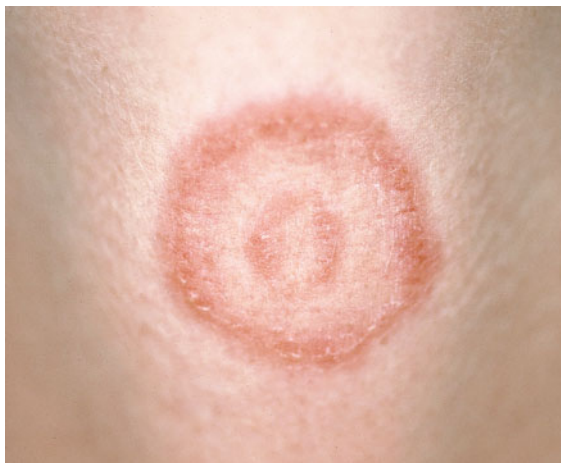The patient usually complains of a mildly itchy, scaly papule that slowly expands to form a ring. Often there is history of another family member with a tinea infection.

Physical Examination

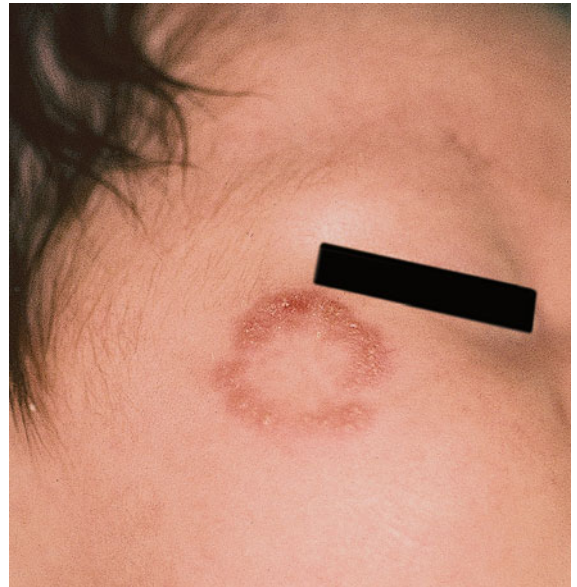Tinea corporis presents initially as a red, scaly papule that spreads outward, eventually developing into an annular plaque with a scaly, slightly raised, well-demarcated border. The center of the lesion may partially clear resulting in a “ring” or “bull’s-eye” appearance (Figure 10-4).

Less common presentations include⁷:

- **Tinea faciei:** This is the term used for tinea infections that occur on the face, most often in children (Figure 10-5).
- **Majocchi granuloma:** In rare instances, tinea corporis does not remain confined to the stratum corneum. Dermal invasion by hyphae following the hair follicle root can produce Majocchi granuloma, which presents as perifollicular granulomatous papules or pustules typically on the shins or arms.
- **Tinea incognita:** This is an atypical presentation of tinea corporis that can occur when a dermatophyte infection has been treated with potent topical steroids or systemic steroids. It is characterized by dermal papules or kerion-like lesions with no inflammation, scaling, or pruritus.



▲ **Figure 10-4.** Tinea corporis on arm. Plaque with sharply defined scaly border with a “bull’s-eye” center.



▲ **Figure 10-5.** Tinea faciei on infant’s cheek. Annular plaque with scaly papules on border and central clearing.

Laboratory Findings

KOH examination (Table 4-1) or cultures of scale from the active border of lesion(s) should be performed to confirm the diagnosis, as there are many diseases that present with red, scaly, annular skin lesions such as nummular dermatitis.

KOH examination of infected scale shows branched septate hyphae (Figure 4-1). DTM cultures are usually positive within 2 weeks. If indicated, a skin biopsy can be done to confirm the diagnosis. A periodic acid–Schiff (PAS) stain will show hyphae in the stratum corneum.

Diagnosis

The key diagnostic clinical features of tinea corporis are annular, ring-like lesions with central clearing and a red, scaling border typically on the trunk or limbs.

Differential Diagnosis

- ✓ **Nummular dermatitis:** Presents with pruritic circular, coin-shaped, scaly plaques that have no central clearing.
- ✓ **Atopic dermatitis:** Presents with pruritic erythematous scaly plaques in patients with atopy.
- ✓ **Tinea versicolor:** Presents with multiple hyperpigmented or hypopigmented asymptomatic macular lesions with very fine powdery scales on the upper trunk with no central clearing. A KOH examination reveals both spores and hyphae.

Table 10-3. Topical medications for dermatophyte skin infections.

Medication	Nonprescription	Trade Name(s) Examples	Formulations	Dosing
Allylamines				
Naftifine	No	Naftin	Cream, gel 1%	QD to BID
Terbinafine	Yes	Lamisil	Cream, spray 1%	BID
Imidazoles				
Clotrimazole	Yes	Lotrimin, Mycelex	Cream, lotion, solution 1%	BID
Econazole	No	Spectazole	Cream 1%	QD
Ketoconazole	No	Nizoral	Cream, shampoo 2%	BID
Miconazole	Yes	Micatin, Desenex, Monistat	Cream, ointment, lotion, spray Solution, powder 2%	BID
Oxiconazole	No	Oxistat	Cream, lotion 1%	QD to BID
Sertaconazole	No	Ertaczo	Cream 2%	BID
Sulconazole	No	Excelderm	Cream, solution 1%	QD to BID
Miscellaneous				
Butenafine	No	Mentax	Cream 1%	QD
Ciclopirox	No	Loprox	Cream, gel, solution 0.77%	BID
Tolnaftate	Yes	Tinactin	Cream, lotion, solution, spray, gel 1%	BID

- ✓ **Granuloma annulare:** Presents as skin-colored, smooth, dermal papules in a circular distribution that may coalesce into annular plaques. These plaques can vary from 1 to several centimeters and they typically occur on the dorsum of the hands and feet, and lower extremities. They usually spontaneously resolve over 1 to 2 years. The lack of scale is an important differentiating feature.
- ✓ **Other:** Candidiasis, psoriasis, pityriasis rosea, erythema multiforme, fixed drug eruption, subacute cutaneous lupus, secondary syphilis, and erythema migrans (Lyme disease).

Management

Topical antifungal medications (Table 10-3) are effective for isolated lesions of tinea corporis.

Topical antifungal medications should be applied at least 1 to 2 cm beyond the visible advancing edge of the lesions and treatment should be continued for 1 to 2 weeks after the lesions resolve. If the infection is extensive, or if it does not respond to topical therapy, oral griseofulvin can be used⁸ (Table 10-4).

Bedding, towels, and clothing should be laundered and should not be shared with infected individuals. Children with active infections should not participate in contact sports, until the infection is treated and resolved. For those infected with zoophilic fungi, especially in cases of tinea

faciei, it is important to identify the infected animal and have the animal treated appropriately by a veterinarian. Tinea corporis usually responds well to treatment, but can recur with repeated contact with the source of the organism.

Table 10-4. Griseofulvin dosing regimen for tinea corporis.

Medication and Formulations	Adult Dosing	Pediatric Dosing
Microsized griseofulvin (Grifulvin V) Available in 250 and 500 mg tablets or 125 mg/5 mL oral suspension	500 mg daily for 2-4 weeks	Approximately 125-250 mg/day for 2-4 weeks for body weight of 14-23 kg Approximately 250-500 mg/day for 2-4 weeks for body weight greater than 23 kg
Ultramicrosized griseofulvin (Gris-Peg) Available in 125 and 250 mg tablets	375 mg daily for 2-4 weeks	Approximately 125-187.5 mg/day for 2-4 weeks for body weight of 16-27 kg Approximately 187.5-375 mg/day for 2-4 weeks for body weight greater than 27 kg

Indications for Consultation

Severe or persistent disease that does not respond to topical and oral treatment.

Patient Information

PubMed Health: www.ncbi.nlm.nih.gov/pubmedhealth/PMH0001880/

TINEA MANUUM

Introduction

Tinea manuum is a dermatophyte infection that affects the palmar and dorsal aspects of the hands. It is more common in men and is rare in children. In most cases, there is preexisting tinea pedis.

Pathophysiology

Predisposing factors include manual labor, preexisting inflammatory conditions of the hands, hyperhidrosis, heat, and humidity. These can lead to a breakdown in the protective stratum corneum barrier of the epidermis allowing the dermatophytes to penetrate. Tinea manuum may be acquired by direct contact with an affected person or animal, or from autoinoculation from fungal infections on the feet or groin. *T. rubrum*, *Trichophyton mentagrophytes*, and *Epidermophyton floccosum* are the species that commonly cause tinea manuum.

Clinical Presentation

History

Patients typically complain of chronic dryness on the palms or redness and scaling on the dorsa of the hands.

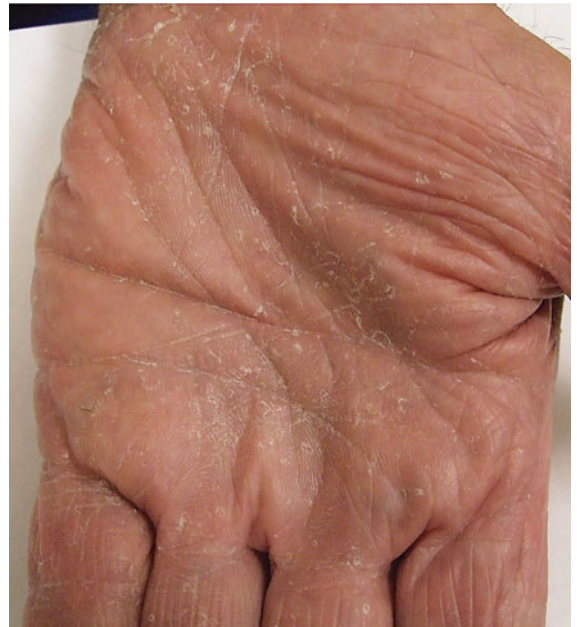Physical Examination

Tinea manuum can present with 2 patterns.

- Tinea on the palms presents with diffuse, fine scale (Figure 10-6). It frequently is associated with the moccasin type of tinea pedis. It is unilateral in about 50% of the cases. In some cases there is a concomitant fungal infection of the fingernails.
- On the dorsal surface, it usually presents in a ringworm pattern with an annular plaque with a red, scaly border. Vesicles and red papules may be present.

Laboratory Findings

KOH examination (Table 4-1) or cultures of scale should be performed to confirm the diagnosis as tinea manuum may be clinically indistinguishable from dermatitis. KOH examination of infected scale shows branched septate hyphae. DTM cultures are usually positive within 2 weeks.



▲ **Figure 10-6.** Tinea manuum on the palm. Subtle diffuse fine scale.

Diagnosis

The key diagnostic clinical feature of tinea manuum is an asymptomatic, fine, subtle, diffuse scale on one or both palms.

Differential Diagnosis

- ✓ **Irritant or allergic contact dermatitis:** Usually bilateral and presents with erythematous, nonexpanding pruritic plaques on the dorsum of the hands. Fissures, erosions, and scales may also be present on the palms.
- ✓ **Psoriasis:** Presents with thick silvery plaques on the dorsum of the hands, usually associated with plaques elsewhere, such as the elbows and knees.

Management

Tinea infections of the dorsum of the hands usually respond to the use of topical antifungal medications (Table 10-3). Tinea infections of the palms usually do not resolve with topical antifungal medications and may require oral griseofulvin⁸:

- Griseofulvin, microsize, adult dose is 500 mg to 1,000 mg per day for 4 to 8 weeks.

- Griseofulvin, ultramicrosized, adult dose is 750 mg per day for 4 to 8 weeks.

It is also important to treat any accompanying tinea infection of the feet and nails.

Indications for Consultation

Severe or persistent disease that does not respond to treatment.

TINEA CRURIS

Introduction

Tinea cruris (jock itch) is a dermatophyte infection of the inguinal and perianal areas. It is 3 times more prevalent in men than in women. It rarely occurs in children. It is more common in hot and humid environments. Obesity and activities that cause increased sweating are risk factors.

Pathophysiology

Tinea cruris is usually caused by *T. rubrum*, *T. mentagrophytes*, and *E. floccosum*. Sweating and tight or damp clothing produces maceration of the skin allowing the dermatophytes to easily penetrate into the epidermis. Autoinoculation commonly occurs from tinea pedis or tinea unguium. The organisms may also be transmitted from fomites such as towels and sheets.

Clinical Presentation

History

Patients usually complain of itching or redness in the groin area.

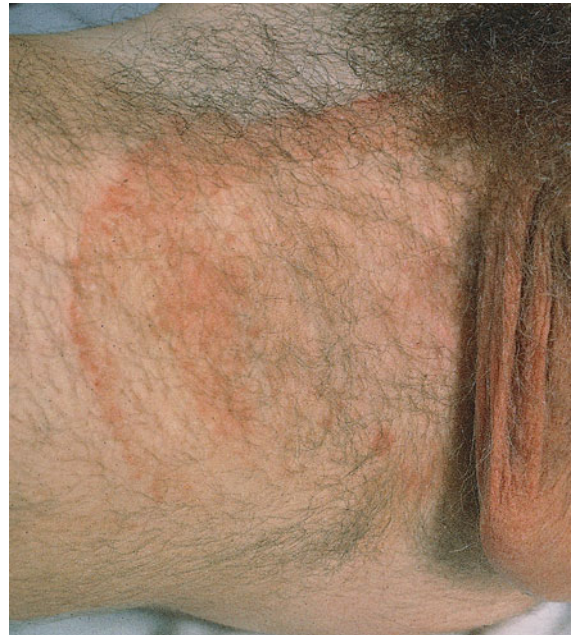Physical Examination

Patients present with pruritic, semicircular plaques with sharply defined scaly borders in the inguinal folds and the upper inner thighs (Figure 10-7). In more acute infections, the lesions may be moist or have an eczematous appearance. Chronic infections with *T. rubrum* usually present with a dry, annular plaque with small follicular papules.

The penis and scrotum are **not** involved in contrast to candidiasis that can involve the penis and scrotum. The infection can spread to the lower abdomen, suprapubic area, perianal area, and buttocks (Figure 10-8). In those areas it has the appearance of a symmetrical, typical tinea corporis infection.

Laboratory Findings

It is helpful, but not essential, to confirm the diagnosis of tinea cruris with a KOH examination or fungal cultures. Collection of scale for laboratory testing may be difficult in the groin area because of moisture on the skin surface in that region.

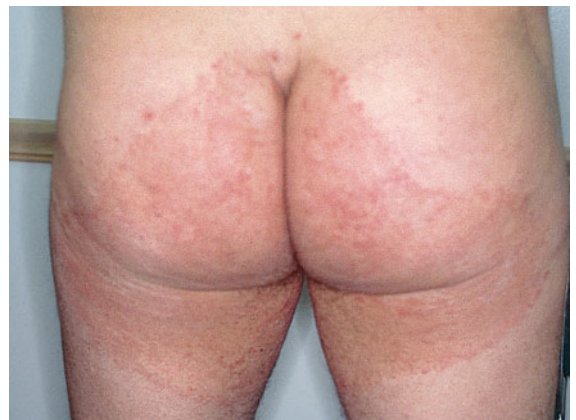

▲ **Figure 10-7.** Tinea cruris. An arc of erythema with scale on border, scrotum is not involved.

KOH examination of infected scale shows branched septate hyphae. DTM cultures usually are positive within 2 weeks.

Diagnosis

The key diagnostic clinical features of tinea cruris are circular or semicircular, pink, annular plaques with a distinct scaly border, most commonly found in the inguinal folds and the upper inner thighs.



▲ **Figure 10-8.** Tinea cruris. Extension to posterior thighs and buttocks.

► Differential Diagnosis

- ✓ **Candidiasis:** Presents as a deep red, moist plaque with satellite pustules. There is no central clearing. The scrotum is commonly affected and occasionally the penis is affected.
- ✓ **Erythrasma:** This is caused by *Corynebacterium minutissimum*. It appears as uniform, red to brown, macular lesions with no scale or central clearing. Borders are sharply demarcated, but not elevated. The lesions exhibit a bright coral red fluorescence with a Wood's light.
- ✓ **Seborrheic dermatitis:** Presents with symmetrical, confluent, salmon pink, slightly scaly plaques on the inner thighs. Usually the scalp and central face are involved.
- ✓ **Other:** Psoriasis and lichen simplex chronicus.

Management

Most cases of tinea cruris can be successfully treated with topical antifungal medications, preferably a cream or lotion (Table 10-3). Absorbent powders such as miconazole (Zearob AF) powder are very helpful treatment adjuncts and can help prevent recurrences. Oral griseofulvin is reserved for refractory widespread or more inflammatory lesions:

- Griseofulvin, microsize, adult dose is 500 mg per day for 2 to 4 weeks.
- Griseofulvin, ultramicrosize, adult dose is 375 mg per day for 2 to 4 weeks.

Coexisting tinea pedis and tinea unguium should be treated to prevent reinfection. Men should be instructed to wear loose-fitting pants and boxer shorts. Tinea cruris usually responds well to treatment, but recurrences are common.

Indications for Consultation

Severe or persistent disease that does not respond to treatment.

Patient Information

PubMed Health: www.ncbi.nlm.nih.gov/pubmedhealth/PMH0001879/

▼ TINEA PEDIS

Introduction

Tinea pedis (athlete's foot) is one of the most common superficial fungal infections of the skin in developed countries. At least 10% of the world population is affected at

any given time. It is more common in males and is uncommon in females and children. Risk factors include the use of communal pools and showers and occlusive shoes.

Pathophysiology

The skin of the soles has a thick keratinized layer and numerous eccrine sweat glands. The combination of abundant keratin, sweat, and occlusion with shoes creates a perfect environment for dermatophyte infections. Chronic noninflammatory tinea pedis is usually caused by a *T. rubrum* infection. There may be a genetic predisposition for this type of tinea pedis. Vesiculobullous tinea pedis is usually caused by *T. mentagrophytes*.

Clinical Presentation

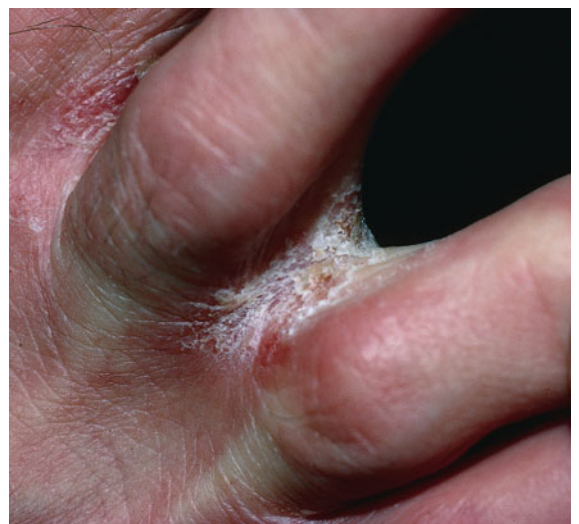► History

Patients usually complain of itching and persistent scaling or less commonly blisters usually on the plantar surface or in the toe webs.

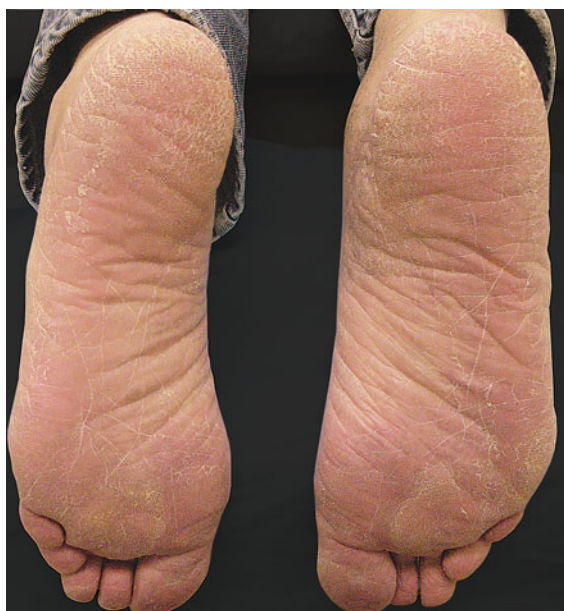► Physical Examination

Patients may present with 3 patterns of tinea pedis:

- Interdigital pattern with scales, fissures, or maceration or malodor usually in the fourth and fifth web spaces (Figure 10-9). Secondary infection with gram-negative or gram-positive organisms may be present. The tinea infection may spread to the dorsum of the foot, creating scaly, annular plaques.

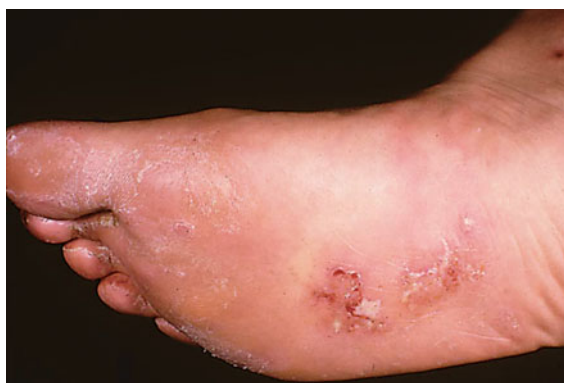

▲ **Figure 10-9.** Interdigital tinea pedis. Scale and small fissures.



▲ **Figure 10-10.** Moccasin pattern tinea pedis. Subtle diffuse scale bilaterally.

- Moccasin pattern with diffuse, dry, silvery white scale on the soles extending up to the sides of the foot (Figure 10-10). In its mildest form, tiny scattered arcs of scale are seen. Concomitant onychomycosis and tinea manuum may be present.
- Vesiculobullous pattern with vesicles and/or bullae on the plantar surface, especially instep areas, accompanied by inflammation and tenderness (Figure 10-11). Secondary bacterial infection in the blisters may progress into cellulitis or lymphangitis. A vesicular “id” reaction may occur on the palms or other body sites. This is



▲ **Figure 10-11.** Vesiculobullous pattern tinea pedis. Vesicles on the instep of the foot with cellulitis.

often misdiagnosed as dermatitis because of the presence of vesicles.

Accompanying fungal infections of the toenails are common in chronic tinea pedis. Concomitant tinea manuum may also be present.

► Laboratory Findings

KOH examination (Table 4-1) or cultures of scale or the roof of a vesicle should be performed to confirm the diagnosis, as tinea pedis may be clinically indistinguishable from dermatitis. The one exception is toe web scale or fissures, which are almost always caused by fungus and can be diagnosed on the basis of clinical findings. KOH examination of infected skin shows branched septate hyphae. DTM cultures are usually positive within 2 weeks.

Diagnosis

The key diagnostic clinical features of tinea pedis are scaly plaques and/or blisters on the feet.

► Differential Diagnosis

- ✓ **Contact dermatitis:** Presents with symmetrical erythematous plaques on the dorsa of the feet, usually caused by an allergy to one or several components in rubber, leather, or metal in shoes.
- ✓ **Dyshidrotic eczema (pompholyx):** Presents with numerous pruritic, symmetrical vesicles that resemble “tapioca pudding” on the sides of the soles and/or palms. It is more common in patients with hyperhidrosis.
- ✓ **Psoriasis:** Presents with 2 patterns on the feet—erythematous scaly plaques or painful symmetrical pustules. Nail dystrophy may be present in both patterns.
- ✓ **Other:** Interdigital soft corns, erythrasma, and atopic dermatitis.

Management

Treatment options for tinea pedis include:

- Interdigital toe web infections will usually respond to various topical antifungal medications (Table 10-3). Lamb’s wool padding (eg, Dr Scholl’s) in the web spaces and wider shoes may also be needed to keep the web spaces dry.
- The dry, moccasin form of tinea pedis may respond to topical antifungal medications, but usually requires an oral antifungal medication to clear the infection. Recurrences are common.
- Acute vesiculobullous tinea pedis may be treated with Burow’s wet dressings (Table 6-5) and topical or oral

antifungal medications. Secondary bacterial infections should be treated with topical or oral antibiotics.

- Griseofulvin can be used if tinea pedis does not respond to topical antifungal medications:
 - Griseofulvin, microsize, adult dose is 500 to 1,000 mg per day for 4 to 8 weeks.
 - Griseofulvin, ultramicrosize, adult dose is 750 mg per day for 4 to 8 weeks.

Patients with hyperhidrosis should use products such as aluminum chloride hexahydrate solution (Drysol), tol-naftate powder, or miconazole (Zeasorb AF) powder. These powders should be sprinkled on the feet, in the shoes, or in the socks daily. Patients should be advised to thoroughly dry their feet (especially in the toe webs) with a towel or hair dryer after bathing. Sandals should be worn in communal showers and swimming pools.

Recurrence of tinea pedis is common, especially if onychomycosis is present, as it may act as a reservoir of infection. It is important to treat recurrences and prevent reinfection in diabetic and immunocompromised patients. Fissures and erosions caused by tinea pedis can be a portal for the entry of bacteria that may cause cellulitis.

Indications for Consultation

Severe or persistent disease that does not respond to therapy.

Patient Information

PubMed Health: www.ncbi.nlm.nih.gov/pubmedhealth/PMH0001878/

ONYCHOMYCOSIS (TINEA UNGUIUM)

Introduction

Onychomycosis is a very common nail disorder and accounts for about 50% of nail diseases. The prevalence of onychomycosis in North Americans and Europeans is reportedly between 2% and 13% with the prevalence increasing with age.^{9,10} Onychomycosis is rare in prepubertal children. In contrast, 60% of patients older than 70 are affected.^{11,12} Nondermatophyte molds are responsible for 1.5% to 6% of cases of onychomycosis.¹²

Onychomycosis is more common in patients who are male, immunosuppressed, diabetic, infected with human immunodeficiency virus (HIV), or who have poor circulation. Trauma or nail dystrophy also predisposes patients to fungal infection.¹²

Pathophysiology

The most common organisms that cause fungal infection of the nail include¹²:

- Dermatophytes: *T. rubrum*, *T. mentagrophytes*, and *E. floccosum*
- Nondermatophyte molds: *Acremonium*, *Aspergillus* species, *Cladosporium carrionii*, *Fusarium* species, *Onychocola canadensis*, *Scopulariopsis brevicaulis*, *Scytalidium dimidiatum*, and *Scytalidium hyalinum*
- Yeasts: *Candida albicans*

Clinical Presentation

History

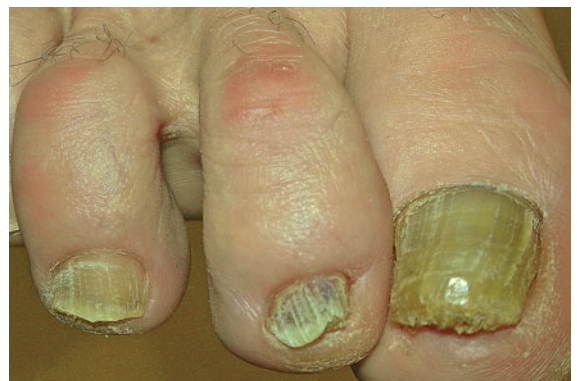Patients usually complain of thickening or discoloration of the nail plate. Pain or tenderness may be present. Patients often have a history of other fungal skin infections, especially tinea pedis and tinea manuum.

Physical Examination

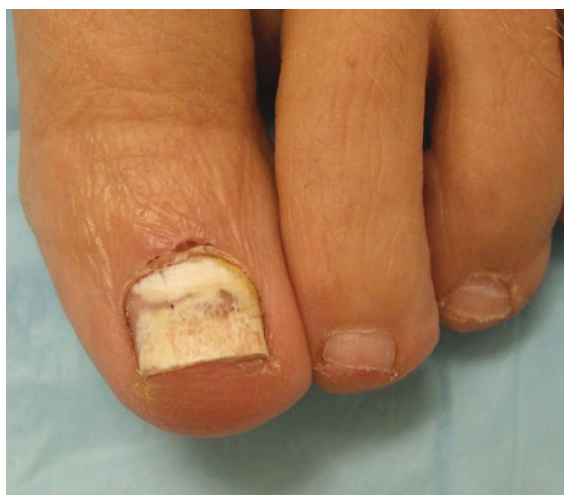The initial findings are white/yellow or orange/brown streaks or patches under the nail plate. As the infection progresses, subungual hyperkeratosis, onycholysis (separation of the nail plate from the nail bed), and a thickened nail plate may develop.

There are 4 major patterns of infection:

- Distal subungual: Nails are dystrophic and thickened (Figure 10-12). Color changes are present (white, yellow, orange, or brown).
- Proximal subungual: Proximal portion of nail appears white, but not crumbly or chalky.
- White superficial: Nail plate appears white, and chalky (Figure 10-13).¹⁰
- *Candida*: Mild cases may produce nothing more than diffuse leukonychia (white spot[s] under the nail plate). Severe cases may present with a yellow-brown discoloration, with a thick nail bed and lateral and proximal nail



▲ **Figure 10-12.** Onychomycosis. Thick discolored nail plate and subungual hyperkeratosis.



▲ **Figure 10-13.** White superficial onychomycosis.

fold swelling. Onycholysis is common and subungual hyperkeratosis can occur.^{12,13}

► Laboratory Findings

It is important to confirm the diagnosis of fungus prior to initiating treatment. Fungal cultures are not always necessary, but can be helpful in distinguishing between dermatophytes, molds and yeasts. A fungal culture is the least sensitive, but most specific, method for demonstrating a fungal infection. The most sensitive method to detect fungus is to clip the distal portion of the nail plate, place it in formalin, and send it for histopathologic examination.

Fungal elements stain positive with PAS. A KOH preparation can be done in clinic (Table 4-1) and should demonstrate septate hyphae or spores. However, false negatives are common. These tests are not sensitive; they may need to be repeated serially, if negative and clinical suspicion is high.¹³

Diagnosis and Differential Diagnosis

Nail disorders can be difficult to differentiate from one another based only on their clinical findings. It takes practice, and some investigation, to determine the correct diagnosis. To add to the confusion, many nail disorders can also be complicated by secondary infection, either fungal or bacterial. The most common differential diagnosis for fungal nail disease would include trauma and psoriatic nail changes. Suspect mold as the cause of onychomycosis when periungual inflammation is present and/or tinea pedis is absent.¹³

See page 190 for differential diagnosis of nail disorders in Chapter 20.

Management

For many patients nontreatment is a viable option. Patients may prefer not to risk the potential side effects of oral antifungal medications. See Table 10-5 for treatment of onychomycosis due to dermatophytes. Liver function tests should be done prior to the initiation of terbinafine and itraconazole and once a month during treatment.

It takes 4 to 6 months for a fingernail and 12 to 18 months for the great toenail to grow out completely. As a result, patients will not see a completely normal nail plate until that length of time has passed. The first sign that treatment is working will be a transition to normal nail plate growth from the proximal nail fold, which, for

Table 10-5. Treatment for onychomycosis caused by dermatophytes.

Medication	Adult Dosing	Notes
Terbinafine (Lamisil) 250 mg tablet	250 mg PO daily for 12 weeks for toe nail infection 250 mg PO daily for 6 weeks for fingernail infection	50% cure rate, few drug interactions, infrequent hepatotoxicity
Itraconazole (Sporanox) 100 mg tablet	200 mg PO daily for 12 weeks for toenail infection Two treatment pulses, each consisting of 200 mg PO daily for 1 week separated by 3 weeks of no treatment for fingernails only infection	40% cure rate Black box warning: Should not be used in patients with evidence of or a history of ventricular dysfunction such as congestive heart failure; a potent cytochrome P450 3A4 isoenzyme (CYP3A4) inhibitor, so it may have many potential drug interactions, occasional hepatotoxicity
Ciclopirox olamine 8% nail lacquer (Penlac)	Apply to affected nails daily for 6-12 months	Only for mild <i>T. rubrum</i> onychomycosis without involvement of the lunula May be used in combination with oral therapy for increased efficacy
Physical removal	Avulse affected nail plates	Most effective in combination with oral or topical therapy

the fingernails, can usually be seen within a few months of starting treatment.

Onychomycosis is recurrent in 10% to 53% of previously “cured” patients.^{14,15} One study showed that there was a lower recurrence rate in patients initially treated with oral terbinafine (12%) than in those treated with itraconazole (36%).¹⁵ The same study showed no benefit from the long-term use of amorolfine nail lacquer (not available in the United States) on rate of relapse; however, most experts recommend continuing use of topical antifungal products to prevent reinfection. Patients should continue to use antifungal creams on their feet, or powders inside their shoes, at least 3 times a week after treatment with oral medications is completed.

Proximal subungual onychomycosis should prompt investigation for immunosuppression, specifically HIV infection. Candidal onychomycosis is usually considered a sign of immunosuppression.¹³

Indications for Consultation

- Patient not responding to treatment
- Patient preference for physical removal of the diseased nail plates
- Underlying nail disease such as psoriasis that requires treatment

Patient Information

PubMed Health: www.ncbi.nlm.nih.gov/pubmedhealth/PMH0002306/

INTRODUCTION TO SUPERFICIAL YEAST INFECTIONS

Tinea versicolor and *Candida* infections are caused by yeasts, which are ubiquitous organisms on the skin and in the environment. Cutaneous *Candida* infections generally do not cause significant medical problems, but they can be the source for disseminated candidiasis in immunocompromised patients.

TINEA VERSICOLOR

Introduction

Tinea versicolor (pityriasis versicolor) is a common fungal infection caused by *Malassezia*, a lipophilic, dimorphic yeast. It is more prevalent in young adults, but can occur at any age. It is more common in the summer months and in tropical areas.

Pathophysiology

Tinea versicolor is caused by *Malassezia furfur* and *Malassezia globosa*, which are saprophytes that normally colonize the skin.¹⁶ After converting to their mycelial form,

they spread into the superficial epidermis, resulting in the appearance of the rash. In humans, the seborrheic areas (scalp, face, back, and trunk) are always colonized by one or several species of the *Malassezia* genus.

Clinical Presentation

History

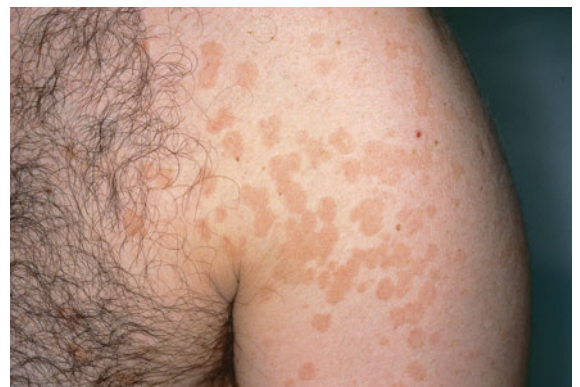Patients usually present during the summer months with a history of asymptomatic, hypopigmented or hyperpigmented, scaly areas on the trunk. The patient’s chief complaint is usually cosmetic, because these lesions do not tan with sun exposure.

Physical Examination

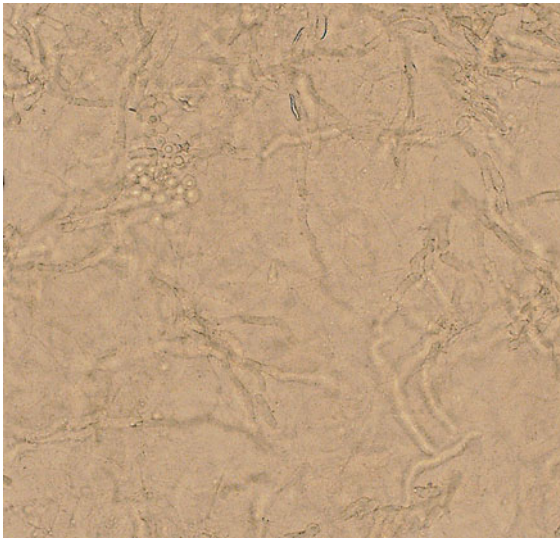
Macules with a fine powdery scale are seen on the upper arms, upper chest (Figure 10-14), back, and occasionally on the face. The initial lesions are 3 to 5 mm, oval or round macules. Over the course of time, they may coalesce and cover more extensive areas of the body creating large irregularly shaped patches. The color of lesions varies from white to reddish-brown to tan-colored. Other areas that can be affected include the neck, abdomen, pubis, and intertriginous areas. Facial lesions may be present primarily in children. Hypopigmentation is very conspicuous in dark-skinned individuals and the hypopigmentation may last for weeks or months until the area has repigmented through sunlight exposure.

Laboratory Findings

Wood’s light shows a characteristic yellow/orange fluorescence. KOH examination of infected scale shows numerous strands of fungal hyphae (mycelia) and numerous spores commonly referred to as “spaghetti and meatballs” (Figure 10-15). Cultures are rarely done as it is difficult to grow the fungus on standard fungal culture media.



▲ **Figure 10-14.** Tinea versicolor on shoulder. Tan-colored macules with subtle scale.



▲ **Figure 10-15.** KOH examination of tinea versicolor demonstrating nonseptated fungal hyphae (mycelia) and spores, referred to as “spaghetti and meatballs.”

Diagnosis

The key diagnostic clinical features of tinea versicolor are white, reddish-brown or tan macules and patches with fine powdery scale on upper trunk and upper arms.

Differential Diagnosis

- ✓ **Seborrheic dermatitis:** Presents with scaly, pink patches on the central trunk; usually the scalp and central face are involved. KOH examination is negative.
- ✓ **Pityriasis rosea:** Presents initially with a pink herald patch with a very fine peripheral scale (collarette scale). Approximately 1 week later, multiple similar but smaller lesions develop on the chest and back, usually in a “Christmas tree” pattern. KOH examination is negative.
- ✓ **Vitiligo:** Presents with macular areas of complete pigment loss, with no scale or other surface changes.
- ✓ **Other:** Secondary syphilis and lupus erythematosus.

Management

- 2.5% selenium sulfide lotion and 2% ketoconazole shampoo are cost-effective first-line treatments. Ketoconazole shampoo lather should be applied to damp skin of all involved areas and left on for 5 minutes, and then showered off. Selenium sulfide lotion

should be applied to involved areas and left on for 10 minutes, and then showered off and reapplied in the same manner for 7 days. In warmer humid weather, the application of these medications may need to be repeated biweekly or monthly to prevent recurrence.

- Clotrimazole, miconazole, and ketoconazole creams are inexpensive treatment options.¹⁷ The creams are applied nightly for 2 to 3 weeks and then repeated on a once a month basis to prevent recurrences. Oral antifungals could be used for extensive cases in adults that do not respond to topical treatments. These have a higher incidence of adverse effects and are more expensive¹⁸:
 - Ketoconazole 200 mg daily for 7 to 10 days
 - Itraconazole 200 mg daily for 7 days or 100 mg daily for 2 weeks
 - Fluconazole 300 mg as a pulse 1 day a week for 2 to 4 weeks

Oral terbinafine and griseofulvin are not effective therapies.

Clinical improvement is not evident until 3 to 4 weeks after treatment. Patients should be advised that pigmentation changes will resolve slowly over several weeks with the aid of exposure to sunlight.

Indications for Consultation

The patient should be referred to dermatology for severe or persistent disease that does not respond to treatment.

Patient Information

American Academy of Dermatology: www.aad.org/skin-conditions/dermatology-a-to-z/tinea-versicolor

CANDIDIASIS

Introduction

C. albicans is often present as part of the normal flora in the mouth, gastrointestinal tract, and vagina. However, it can become a pathogen, especially in the vaginal tract and intertriginous areas. Risk factors for superficial candidiasis include infancy, pregnancy, aging, occlusion of epithelial surfaces (dentures, occlusive dressings), maceration, immunodeficiency, diabetes, obesity, and use of medications such as oral glucocorticoids and antibiotics.

Pathophysiology

Candida is a dimorphic yeast that has the ability to transform from a budding yeast phase to an invasive mycelia growth phase, which is necessary for tissue infection.

The most common cause of superficial candidiasis is *C. albicans*. Occasionally, other species such as *Candida glabrata*, *tropicalis*, *krusei*, and *parapsilosis* can be pathogenic.¹⁹

Clinical Presentations of Intertriginous Candidiasis

History

Patients usually complain of redness and itching in body fold areas or in moist areas.

Physical Examination

Primary lesions appear as moist, erythematous plaques with maceration. Cutaneous candidiasis has a predilection for moist, warm, or macerated areas of the body. Common sites include inframammary, axillary (Figure 10-16), and abdominal folds of the body, interdigital and groin/diaper region (Figure 10-17), and the head of the penis of uncircumcised men.

The periphery can show scaling and satellite pustules. The area is often pruritic.

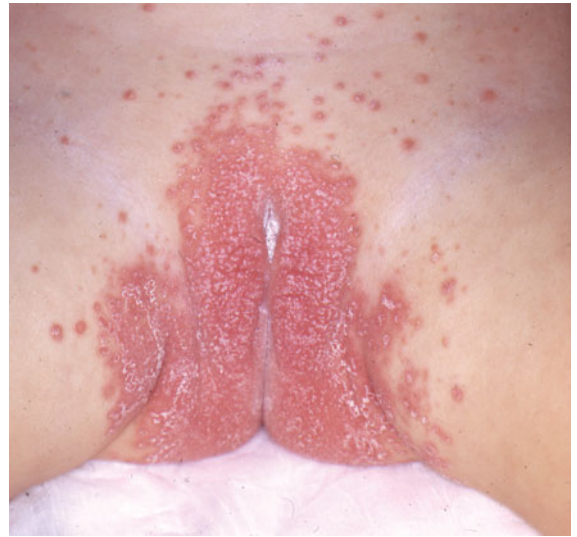Clinical Presentation of Candidal Paronychial Infections

History

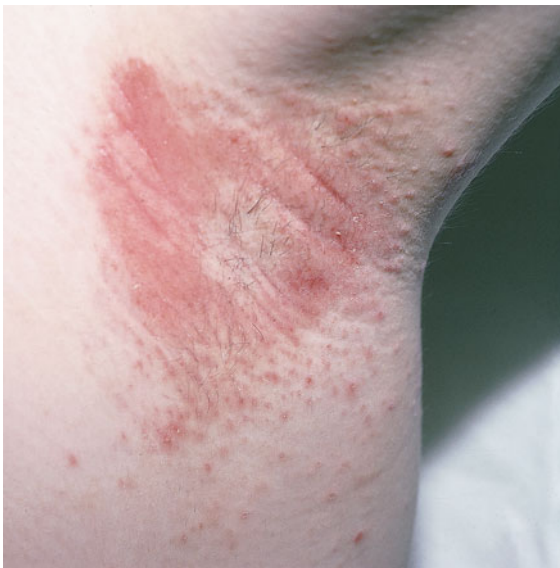Patients complain of swelling and pain in the cuticle. Chronic immersion of the hands in water is a risk factor.

Physical Examination

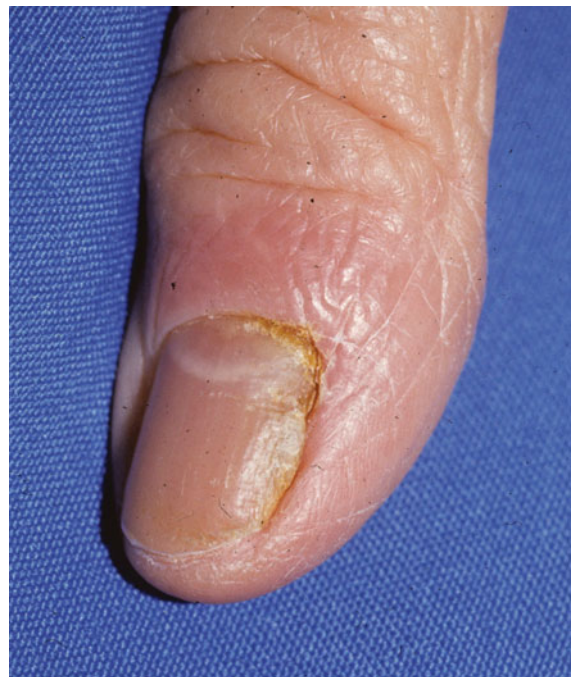Cutaneous findings include erythema, and swelling and pain of the nail fold along with retraction of the cuticle (Figure 10-18). Acute paronychial infections are often



▲ **Figure 10-17.** *Candida* skin infection in diaper area of child. Erythematous plaque over the labia and inner thighs surrounded by satellite pustules.



▲ **Figure 10-16.** *Candida* skin infection in axilla. Pink plaque surrounded by satellite pustules.



▲ **Figure 10-18.** Candidal paronychial infection. Erythema and swelling of cuticle.

bacterial, but chronic infection often involves a combination of bacterial and *Candida* species.

Clinical Presentation of Angular Cheilitis

History

The patient typically complains of redness and sometimes pain in the corners of the mouth. It is more common in circumstances that result in increased moisture at the oral commissures, for example, lip lickers, elderly patients, or those with poorly fitting dentures.

Physical Examination

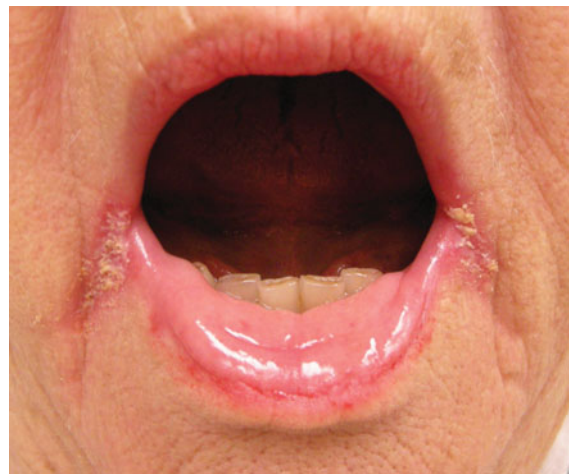Angular cheilitis presents with painful, erythematous, scaly fissures in the oral commissures usually bilaterally (Figure 10-19). Angular cheilitis usually represents a combination of fungal and bacterial infection, for example, *C. albicans* and *Staphylococcus aureus*.²⁰

Laboratory Findings in Candida Infections

C. albicans grows on bacterial media, but Sabouraud agar is usually recommended. KOH examination shows numerous spores and pseudohyphae.

Diagnosis

The key diagnostic clinical features of *Candida* skin infections are moist, erythematous plaques with satellite pustules usually in a body fold area.



▲ **Figure 10-19.** Angular cheilitis. Erythema, scale, and fissures.

Differential Diagnosis

Differential diagnosis of cutaneous candidiasis:

- ✓ **Dermatophyte infection:** In men, dermatophyte infections do not involve the penis and scrotum, while in candidiasis these areas may be affected.
- ✓ **Erythrasma:** Presents with erythema, coral red fluorescence with Wood's light examination and no satellite pustules.
- ✓ **Other:** Contact dermatitis and inverse psoriasis.

Differential diagnosis for candidal paronychia includes bacterial or herpes viral paronychia.

Management

It is important to keep the affected areas dry and free of moisture. Powders such as 2% miconazole (Zeosorb AF) may be helpful in body fold areas. Mild cases of cutaneous candidiasis and paronychia can be treated with topical imidazole medications (Table 10-3) or nystatin cream.

Indications for Consultation

Severe or persistent disease that does not respond to therapy.

Patient Information

Centers for Disease Control and Prevention: www.cdc.gov/ncezvd/divisions/difbmd/diseases/candidiasis/

REFERENCES

- Sharma V, Hall JC, Knapp JF, Sarai S, Galloway D, Babel DE. Scalp colonization by *Trichophyton tonsurans* in an urban pediatric clinic. *Arch Dermatol.* 1988;124(10):1511–1513. PMID: 3421726.
- Ginter-Hanselmayer G, Weger W, Ilkit M, Smolle J. Epidemiology of tinea capitis in Europe: current state and changing patterns. *Mycoses.* 2007;50(suppl 2):6–13. PMID: 17681048.
- Kakourou T, Uksal U. Guidelines for the management of tinea capitis in children. *Pediatr Dermatol.* 2010;27(3):226–228. PMID: 20609140.
- Ali S, Graham TA, Forgie SE. The assessment and management of tinea capitis in children. *Pediatr Emerg Care.* 2007;23(9):662–665. PMID: 17876261.
- Gonzalez U, Seaton T, Berugs G, Jacobson J, Martinex-Monzon C. Systemic anti-fungal therapy for tinea capitis in children. *Cochrane Database Syst Rev.* 2007;4:CD004685. PMID: 17943825.
- Tey HL, Tan AS, Chan YC. Meta-analysis of randomized, controlled trials for comparing griseofulvin and terbinafine in the treatment of tinea capitis. *J Am Acad Dermatol.* 2011;64(4):663–670. PMID: 21334096.

7. Degreef H. Clinical forms of dermatophytosis (ringworm infection). *Mycopathologia*. 2008;166(5–6):257–265. PMID: 18478364.
8. Gupta AK, Cooper E. Update in antifungal therapy of dermatophytosis. *Mycopathologia*. 2008;166(5–6):353–367. PMID: 18478357.
9. Scher RK, Tavakkol A, Sigurgeirsson B, et al. Onychomycosis: diagnosis and definition of cure. *J Am Acad Dermatol*. 2007;56(6):939–944. PMID: 17307276.
10. Welsh O, Vera-Cabrera L, Welsh E. Onychomycosis. *Clin Dermatol*. 2010;28(2):151–159. PMID: 20347657.
11. Daniel CR III, Jellinek NJ. Commentary: the illusory tinea unguium cure. *J Am Acad Dermatol*. 2010;62(3):415–417. PMID: 20159309.
12. Scher RK, Daneil CR III. *Nails: Diagnosis Therapy Surgery*. 3rd ed. China: Elsevier Saunders; 2005:123–125, 130–131.
13. Tosti A, Piraccini BM, Lorenzi S, Iorizzo M. Treatment of nondermatophyte mold and candida onychomycosis. *Dermatol Clin*. 2003;21(3):491–497. PMID: 12956201.
14. Iorizzo M, Piraccini BM, Tosti A. Today's treatment options for onychomycosis. *J Dtsch Dermatol Ges*. 2010;8(11):875–879. PMID: 20738460.
15. Piraccini BM, Sisti A, Tosti A. Long-term follow-up of toenail onychomycosis caused by dermatophytes after successful treatment with systemic antifungal agents. *J Am Acad Dermatol*. 2010;62(3):411–414. PMID: 20159308.
16. Crespo-Erchiga V, Florenco VD. Malassezia yeasts and pityriasis versicolor. *Curr Opin Infect Dis*. 2006;19(2):139–147. PMID: 16514338.
17. Hu SW, Bigby M. Pityriasis versicolor: a systematic review of interventions. *Arch Dermatol*. 2010;146(10):1132–1140. PMID: 20956647.
18. Stratman EJ. Failure to use available evidence to guide tinea versicolor treatment: comment on “pityriasis versicolor”. *Arch Dermatol*. 2010;146(10):1140. PMID: 20956648.
19. Hay RJ. The management of superficial candidiasis. *J Am Acad Dermatol*. 1999;40(6):S35–S42. PMID: 10367915.
20. Giannini PJ, Shetty KV. Diagnosis and management of oral candidiasis. *Otolaryngol Clin North Am*. 2011;44(1):231–240. PMID: 21093632.

11

Viral Infections of the Skin

Bruce Bart

Introduction to Chapter / 88
Herpes Simplex / 88
Herpes Zoster / 90

Molluscum Contagiosum / 92
Warts / 93
References / 96

INTRODUCTION TO CHAPTER

Despite all the advances in antiviral therapy and the body's efficient immune system, the viruses that cause common skin infections continue to evade complete destruction. The herpes simplex and herpes zoster virus can persist in a dormant state in the ganglia. The viruses that cause verrucae vulgaris (common warts) and molluscum contagiosum can persist for months to several years in the epidermis.

Herpes simplex and herpes zoster infections can cause significant illness and death, especially in immunocompromised patients if the infection spreads to other organs. Common nongenital warts and molluscum contagiosum rarely cause significant problems in immunocompetent patients, but for various reasons most patients want treatment for these conditions. Genital warts are often asymptomatic and may be clinically undetectable; however, patients with oncogenic wart virus infections are at increased risk for anogenital and oropharyngeal cancers.

HERPES SIMPLEX

Introduction

Herpes simplex viruses (HSV) cause primary, latent, and recurrent infections. Human herpes virus-1 (HSV-1) primarily infects the oral cavity, lips, and perioral skin. Human herpes virus-2 (HSV-2) primarily infects the genital area. However, HSV-1 is becoming a common cause of genital herpes infections in young women. HSV has a worldwide

distribution and is more common in less developed countries. Antibodies to HSV-1 are present in up to 85% of adults, and antibodies to HSV-2 are present in 20% to 25% of adults.¹ However, many patients who have antibodies to HSV do not recall having an infection.

Pathophysiology

HSV-1 and HSV-2 are human herpesviruses (HHV) that have double-stranded DNA and replicate within the nuclei of infected cells. HSV infects mucocutaneous tissue after direct contact or by way of secretions, mainly saliva in the case of HSV-1. The virus is transmitted via sensory nerves to the ganglia, where it may reside in a latent stage. Recurrent infections are caused by reactivation of the virus which travels back to the skin or mucous membranes resulting in an active infection. Immune mechanisms suppress the virus with clearing of the lesions in 1 to 2 weeks, but latency in the ganglia persists. Recurrent mucocutaneous infection may occur every few weeks to months to years. Viral shedding may continue after the infection has clinically resolved.

Clinical Presentation

► History

Patients with orolabial HSV may complain of “fever blisters” or “cold sores” on the lips or perioral area or sores within the oral cavity. Patients with genital herpes may complain of pain or tingling in the genital area in the

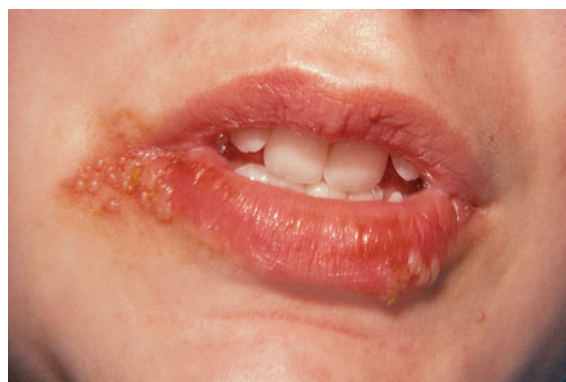prodromal and active phase of the infection. Primary infection occurs 3 to 7 days following exposure. Localized pain, tenderness, and burning may be accompanied by fever, malaise, and tender lymphadenopathy. Vesicles develop, progressing to pustules and/or erosions. The eruption resolves in 1 to 2 weeks. Recurrent infection tends to be milder, with fewer vesicles and absent, or minimal systemic symptoms. Fever, sun exposure, and possibly stress may trigger recurrence of infection. Many individuals harboring HSV are asymptomatic.

► Physical Examination

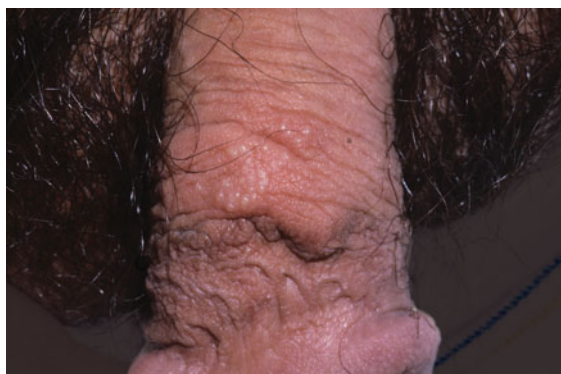HSV infections present with vesicles that tend to be grouped in clusters with underlying and surrounding erythema.

There are several presentations of HSV infections:

- HSV-1 most frequently affects the lip area (Figure 11-1), but may involve the buccal mucosa, gingiva, and oropharyngeal membranes. Primary infection may present as a gingivostomatitis in children, with fever, sore throat, and painful vesicles and ulcerative erosions on the tongue, palate, gingiva, buccal mucosa, and lips. Patients may develop lymphadenopathy and an inability to eat. Recurrent eruptions are less severe, mostly affecting the vermilion border of the lip, and, less frequently, the perioral skin, nose, and cheeks. Patients may develop concomitant impetigo.
- HSV-2 usually affects the genital area and is the most common cause of genital ulcerations. The primary infection may be extremely painful with erosive vulvitis or vaginitis. The cervix, perineum, and buttocks may be involved with accompanying inguinal lymphadenopathy and dysuria. Affected men may develop an erosive balanitis. Recurrent genital infections can be subclinical or mild with few vesicles (Figure 11-2), clearing in 1 to 2 weeks. Most individuals found to be seropositive for HSV-2 have



▲ **Figure 11-1.** Herpes simplex on lips and oral commissure. Grouped vesicles.



▲ **Figure 11-2.** Recurrent herpes simplex on shaft of penis. Grouped vesicles.

no reported history of genital herpes symptoms, yet shed the virus and can transmit the virus to a partner.

- Fingers (herpetic whitlow) may be affected in children who suck their fingers or in healthcare workers from exposure to secretions.
- Herpes simplex keratitis is the second most common cause of corneal blindness in the United States. It presents with pain, redness, blurred vision, and photophobia.
- Primary neonatal infection usually develops after exposure to HSV in a mother's vaginal secretions during delivery, less commonly the virus is transmitted in utero. This is much more likely to occur when the mother has a primary infection. Infected healthcare workers can also transmit the virus to the neonate. Vesicles, if present, appear 4 to 7 days after birth and may be localized or widespread. The central nervous system and visceral organs can be affected, sometimes in the absence of skin lesions. Infected neonates may have significant morbidity and mortality.
- Patients with atopic dermatitis are at risk of developing eczema herpeticum, which is disseminated cutaneous HSV infection (Figure 8-10). This may begin as an orolabial HSV infection, which rapidly spreads, or may develop after exposure to an individual with HSV infection.

► Laboratory Findings

Tzanck smears can be done by scraping the base of a lesion with a number 15 scalpel blade and spreading the contents on a glass slide (Table 4-2). Microscopic examination after staining with the Wright or Giemsa stain reveals multinucleated epithelial giant cells (Figure 4-4). A skin biopsy will show changes in the nuclei of keratinocytes characteristic of a viral infection. Viral cultures and polymerase chain reaction (PCR) are sensitive and specific tests and

can differentiate HSV-1 from HSV-2. The Western blot is a 99% sensitive and specific test for serologic status.

Diagnosis

The key diagnostic clinical features of herpes simplex are painful, grouped vesicles, or erosions on the face or genital area.

► Differential Diagnosis

For orolabial herpes

- ✓ **Impetigo:** Presents with flaccid vesicles with a honey-colored crust, usually not recurrent in the same area.
- ✓ **Aphthous stomatitis:** Presents with painful 4 to 8 mm oral ulcers with white centers and sharp red borders.
- ✓ **Other:** Behcet's disease, diphtheria, herpangina (coxsackie virus infection), Epstein-Barr Virus (EBV) infection, oral candidiasis, and drug-induced mucositis.

For genital herpes

- ✓ **Syphilitic chancre:** Presents most commonly with a single, nontender, indurated ulcer.
- ✓ **Other:** Trauma, aphthae, chancroid, and granuloma inguinale.

Management

Mild and limited orolabial HSV in immunocompetent patients does not require therapy; however, moderate to severe disease can be treated with topical or oral medications as listed in Tables 11-1 and 11-2. Treatment should be initiated quickly after onset of symptoms, as these medications may not be helpful if started 72 hours after onset of symptoms.

The Centers for Disease Control and Prevention (CDC) has updated information for clinicians on the

Table 11-2. Oral medications for primary genital herpes and recurrent orolabial and genital herpes infections in immunocompetent adults.

Generic & Brand Names	Selected Dosing Options	Duration (days)
Acyclovir (Zovirax)	Primary: 400 mg 3 times a day Recurrent genital: 400 mg 3 times a day or 800 mg twice a day	7-10 5
Famciclovir (Famvir)	Primary: 250 mg 3 times a day Recurrent orolabial: 1500 mg one dose Recurrent genital: 125 mg twice a day Recurrent genital: 1000 mg twice a day	7-10 1 5 1
Valacyclovir (Valtrex)	Primary: 1 g twice a day Recurrent genital: 500 mg twice a day Recurrent orolabial: 2 g every 12 h	10 3 1

treatment of immunocompromised patients and for chronic suppressive treatment for genital herpes.² Immunocompromised individuals require higher doses of oral antiviral medications or may require intravenous therapy. Recurrent episodes of HSV-1 are less common after age 35. Recurrent episodes of genital herpes can have a major psychosocial impact on an affected individual. The American Social Health Association (www.ashstd.org) and the CDC have patient-oriented information on these issues.

Indications for Consultation

Patients with ocular or systemic involvement and immunocompromised patients with widespread disease should be referred to the appropriate specialist.

Patient Information

- Centers for Disease Control and Prevention: www.cdc.gov/std/Herpes/STDFact-Herpes.htm
- American Academy of Dermatology: www.aad.org/skin-conditions/dermatology-a-to-z/herpes-simplex

Table 11-1. Topical medications for orolabial herpes simplex.

Generic & Brand Names	Dosing	Duration
5% Acyclovir ointment (Zovirax)	Every 3 h, 6 times a day	7 days
10% Docosanol cream (Abreva) OTC	5 times a day	Up to 10 days
1% Penciclovir cream (Denavir)	Every 2 h while awake	4 days

HERPES ZOSTER

Introduction

Herpes zoster (shingles) represents reactivation of latent varicella (chicken pox) infection. Persons with a history of primary varicella have a 20% to 30% lifetime risk of developing herpes zoster. Herpes zoster seldom affects children or adolescents. Incidence and severity increase after age 60 and in immunocompromised individuals.³

Pathophysiology

The varicella-zoster virus is a double-stranded DNA virus. Following a varicella infection, varicella-zoster virus may be retained in dorsal root ganglia in a latent form. Reactivation of the virus, leading to the cutaneous eruption in the distribution of the affected sensory nerve(s), may be induced by trauma, stress, fever, radiation therapy, or immunosuppression. Direct contact with vesicular fluid can result in varicella in a susceptible person.

Clinical Presentation

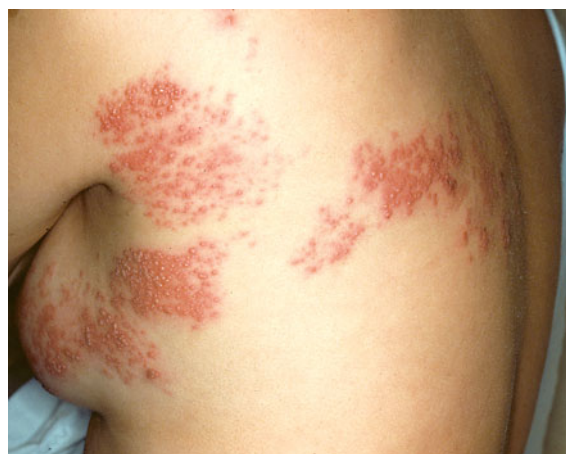History

Herpes zoster often begins with intense pain, which may precede the eruption by one or a few days. Pruritus, tingling, tenderness, or hyperesthesia may also develop.

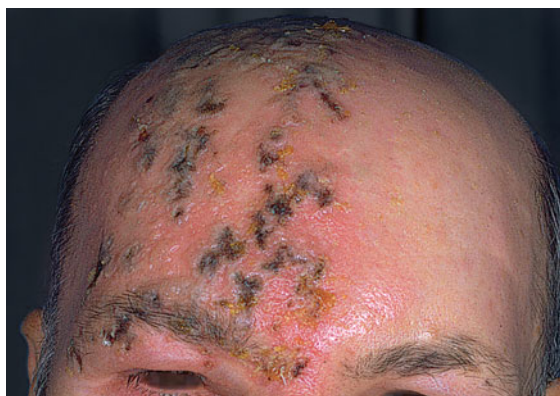Physical Examination

The eruption presents as grouped vesicles within the dermatome of the affected nerves, usually within a single unilateral dermatome. Any area of the body may be affected, but it is seen most frequently on the trunk (Figure 11-3).

Involvement of the trigeminal nerve, particularly the 1st (ophthalmic) division (Figure 11-4), occurs in 10% to 15% of patients. When vesicles develop on the tip or side of the nose, indicating involvement of the nasociliary branch (Hutchinson's sign), the eye is more likely to be affected, sometimes resulting in blindness. Herpes zoster affecting the 2nd and 3rd division of the trigeminal nerve may cause symptoms, vesicles, and erosions in the mouth, ears, pharynx, or larynx. Facial palsy may develop



▲ **Figure 11-3.** Herpes zoster in a thoracic dermatome. Grouped vesicles on erythematous plaques.



▲ **Figure 11-4.** Herpes zoster in distribution of the ophthalmic branch of the trigeminal nerve. Crusts at sites of resolving vesicles on an erythematous plaque.

with involvement of the ear and/or tympanic membrane with or without tinnitus, vertigo, and deafness (Ramsay Hunt Syndrome). Herpes zoster may involve adjacent dermatomes or become disseminated in immunocompromised patients.

The rash associated with herpes zoster usually resolves in 3 to 5 weeks, but symptoms may persist for a longer time, sometimes for many months or years (postherpetic neuralgia). This may occur in 5% to 20% of patients, but is rarely seen in those less than 40 years of age. Incidence increases with age.³ Symptoms resolve in 3 months in 50% of patients and in 1 year in 75% of patients.

Laboratory Findings

A Tzanck smear (Table 4-2) or skin biopsy may reveal characteristic multinucleated giant cells (Figure 4-4), which cannot be differentiated from those seen in herpes simplex infection. Viral cultures and PCR testing are more specific and sensitive tests for herpes zoster.

Diagnosis

The key diagnostic clinical features of herpes zoster are grouped painful vesicles within a dermatome.

Differential Diagnosis

- ✓ **Herpes simplex:** Presents with vesicles that are similar, but the lesions are not as painful and they do not extend over an entire dermatome.
- ✓ The prodromal pain of herpes zoster can mimic headaches, myocardial infarction, pleuritic chest pain, or an acute abdomen.

Management

Oral antiviral medications, if given early, may reduce the duration of the eruption and may reduce the risk and severity of acute pain and perhaps postherpetic neuralgia. The treatments should be started within 72 hours of onset of symptoms. Recommended dosing for immunocompetent adults is as follows:

- Acyclovir (Zovirax) 800 mg 5 times a day for 7 days.
- Famciclovir (Famvir) 500 mg 3 times a day for 7 days.
- Valacyclovir 1000 mg (Valtrex) 3 times a day for 7 days.

Appropriate treatment for acute pain may be needed. Persistent postherpetic neuralgia can have a negative impact on a patient's health and quality of life. It is associated with insomnia, anorexia, and depression especially in the elderly.³ Treatments may include topical lidocaine or capsaicin, antidepressants (such as amitriptyline, desipramine, and nortriptyline), and anticonvulsants (such as carbamazepine and gabapentin). Acupuncture and biofeedback may also be helpful.^{4,5}

Vaccination with live zoster vaccine (Zostavax) may reduce the risk of development of herpes zoster.⁶ It is recommended for persons 60 years of age or older. It is not indicated in patients with active herpes zoster infection or postherpetic neuralgia. The vaccine has been shown to reduce the risk of developing herpes zoster by 51% and the risk of postherpetic neuralgia by 67%. The vaccine is effective for at least 6 years, but may last much longer. It is not yet determined whether booster shots may be needed. Recurrence of herpes zoster is rare, but is more common in immunocompromised patients.

Indications for Consultation

Patients with severe disease or systemic involvement and patients with postherpetic neuralgia who are not responding to treatment should be referred to the appropriate specialist. Patients with eye involvement should be referred to ophthalmology.

Patient Information

- Centers for Disease Control and Prevention: www.cdc.gov/shingles/about/index.html
- American Academy of Dermatology: www.aad.org/skin-conditions/dermatology-a-to-z/herpes-zoster

MOLLUSCUM CONTAGIOSUM

Introduction

Molluscum contagiosum is a benign viral infection of the skin and mucous membranes. The infection has a worldwide distribution and occurs in all ethnicities. Children are

most frequently affected. In adults, it is mostly seen in the genital area and represents a sexually transmitted disease. It is more common and severe in patients with HIV infection, especially in patients with low CD4 counts.

Pathophysiology

Molluscum contagiosum is caused by a member of the pox virus group that contain double-stranded DNA and replicate within the cytoplasm of epithelial cells. The virus is spread by direct skin-to-skin contact.

Clinical Presentation

History

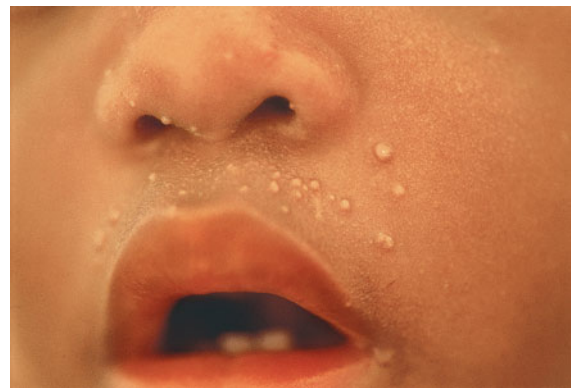Small papules develop on the skin and sometimes on the genital mucous membranes usually within 2 to 7 weeks after contact with an infected individual. The lesions are typically initially asymptomatic, but pruritus and inflammation can develop.

Physical Examination

The typical lesions present as pearly, 2 to 10 mm dome-shaped papules with a waxy surface (Figure 11-5), which often have a central umbilication and erythema around the rim. Papules may be larger and more extensively distributed in immunocompromised patients. The face, upper chest, and upper extremities are most frequently affected in children, whereas the anogenital, suprapubic, and thigh areas are the usual site of infection in adults.

Laboratory Findings

The diagnosis can be confirmed by incising a lesion with a needle and squeezing out the core with gloved fingers or with a small curette. The core should be squashed between two glass slides to flatten the specimen. The



▲ **Figure 11-5.** Molluscum contagiosum on face. 1 to 2 mm dome-shaped papules.

specimen can be stained with Giemsa stain and examined for the presence of large, purple, oval bodies that are the viral inclusion bodies within the cytoplasm of keratinocytes.⁷ These inclusion bodies can also be seen in skin biopsy specimens.

Diagnosis

The key diagnostic clinical features of molluscum are small skin-colored papules with central umbilication.

Differential Diagnosis

- ✓ **Acne:** Presents with papules and pustules and cysts that could appear similar to molluscum. But, comedones should be present and there is no central umbilications of acne lesions.
- ✓ **Folliculitis:** Presents with small papules and/or pustules without umbilication.
- ✓ **Other:** Syringomas, flat warts, and cryptococcosis.

Management

A recent Cochrane review reported that no single treatment has been shown to be convincingly effective.⁸ However, several options for therapy are commonly used.

Molluscum papules can be removed surgically using a small skin curette. They can also be incised with a needle and the contents expressed with gloved fingers or with a comedone extractor. Liquid nitrogen cryotherapy can be used, in a single pulse. 17% salicylic acid nonprescription products that are normally used for common warts can also be used. Spontaneous resolution typically occurs in 6 to 9 months, but may take one to several years.

Public Health Issues

Because molluscum contagiosum is easily spread among children, the parents and the schools should be notified of the infectious nature of the virus and the potential for skin to skin transfer of the virus. There is also frequent spread in certain sports activities, particularly in wrestling. Therefore, coaches and participants should be educated about the infection. Individuals with involvement of the genital region should practice safe sex.

Indications for Consultation

Patients with symptomatic lesions that have not responded to treatment should be referred to dermatology.

Patient Information

American Academy of Dermatology: www.aad.org/skin-conditions/dermatology-a-to-z/molluscum-contagiosum

WARTS

Introduction

Warts (verrucae vulgaris) represent one of the most frequently seen viral mucocutaneous infections. All age groups can be affected; the incidence is higher in children and young adults. In immunocompromised individuals, warts are more common and widespread, more resistant to treatment and more frequently progress to intraepithelial neoplasms. Wart infections can be seen worldwide and affect all ethnicities.

Pathophysiology

Warts are caused by the human papillomavirus (HPV), a double-stranded DNA virus with over 100 genotypes. Some HPV genotypes are found on normal skin and mucous membranes, sometimes inducing wart development when patients become immunocompromised. Other HPV genotypes, such as 16, 18, 31 and 33, may be oncogenic, inducing malignant transformation to squamous cell carcinoma in the anogenital and oropharyngeal areas.⁹ The virus infects keratinocytes in skin and mucous membranes by direct skin-to-skin contact or less commonly via fomites such as floors. Autoinoculation frequently occurs. Warts can spontaneously resolve after months to a few years. In two-thirds of infected individuals, warts regress within 2 years.

Clinical Presentation

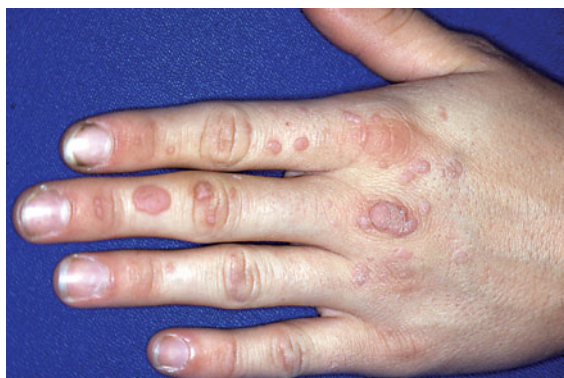History

Warts may develop on any skin or mucous membrane surface, most frequently affecting the hands, feet, and genitalia. Trauma to the skin may encourage inoculation of the virus. Widespread infection can be seen in immunocompromised individuals. There may be an inherited susceptibility to wart infections.

Physical Examination

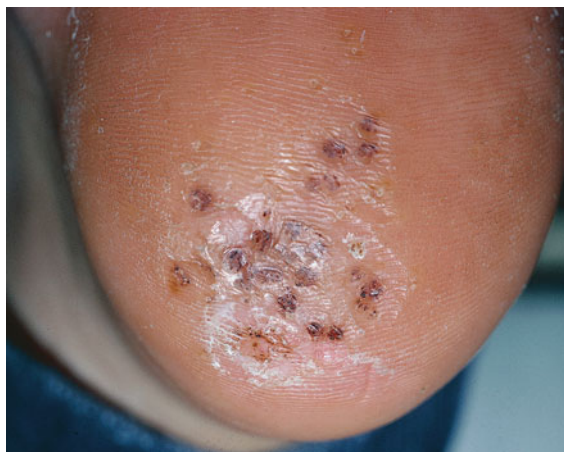There are several clinical presentations for warts, which depend on location and genotype.

- **Verrucae vulgaris (common warts):** Skin-colored, hyperkeratotic, exophytic dome-shaped papules ranging in size from 1 to 10 mm. Mild erythema may be seen around the borders (Figure 11-6). The papules can be in a linear configuration, due to inoculation of the virus in an excoriation. Warts are most frequently seen on the hands, but may involve other skin areas.
- **Verrucae plantaris (plantar warts):** Verrucous or endophytic papules, 1 to 10 mm, affecting the plantar surface of the foot. Black or brown dots created by thrombosed capillaries may be seen on the surface or after paring the wart (Figure 11-7).

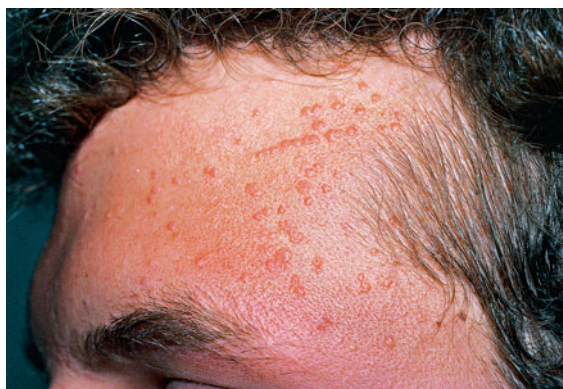

▲ **Figure 11-6.** Verrucae vulgaris on hands. Multiple hyperkeratotic papules and plaques.

- **Mosaic warts:** Localized confluent collection of small warts, usually seen on the palms and soles (Figure 11-7). Brown dots are commonly seen.
- **Verrucae planae (flat warts):** Small, 1 to 3 mm, slightly elevated, flat-topped papules with minimal scale, frequently seen on the face and hands (Figure 11-8).
- **Filiform/digitate warts:** Pedunculated papules with finger-like projections arising from the skin's surface, frequently seen on the face and neck.
- **Condylomata accuminata (genital or venereal warts):** Sessile, smooth-surfaced exophytic papillomas that may be skin-colored, brown, or whitish (Figure 11-9). The papillomas may be pedunculated or broad-based, sometimes coalescing to form confluent plaques. There may be extension into the vagina, urethra, or anal canal.



▲ **Figure 11-7.** Plantar warts. Multiple warts in mosaic pattern with brown dots caused by thrombosed capillaries.



▲ **Figure 11-8.** Flat warts on forehead. Multiple 1 to 2 mm papules, note the linear streak of warts from a scratch.

Laboratory Findings

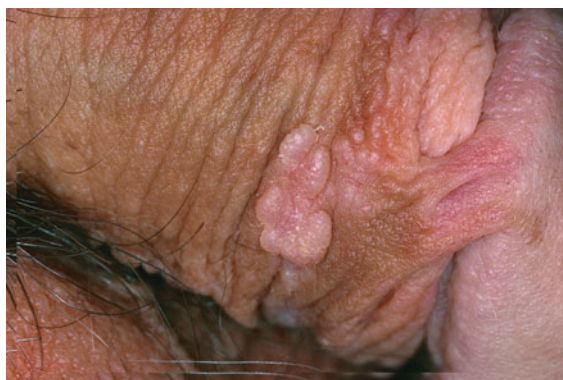A skin biopsy may be done, especially if a carcinoma is suspected, or if the diagnosis is unclear. Histopathologic examination of a skin biopsy of an active wart infection is usually diagnostic.

Diagnosis

The key diagnostic clinical features of warts are 2 to 10 mm verrucous or smooth papules, usually present on the hands, feet, or genitals.

Differential Diagnosis

- ✓ **Squamous cell carcinoma:** Typically presents as an isolated papule or plaque that may ulcerate or appear inflamed. It usually occurs on sun-exposed areas of older patients. It can also occur on the genitals.



▲ **Figure 11-9.** Genital warts on penis. Polyploid skin-colored papule.

- ✓ **Seborrheic keratoses:** Presents with verrucous tan to dark brown papules or plaques and is commonly seen in older adults. Skin-colored lesions on the dorsum of the hand may closely resemble warts.
- ✓ **Corns and calluses:** These lesions have no red or brown dots (thrombosed capillary loops) when pared.
- ✓ **Pearly penile papules:** These are often confused with HPV warts on the penis. They present with numerous 1- to 3-mm smooth papules (angiokeratomas), in a linear arrangement, on the corona and are seen in up to 10% of males.

Management of Nongenital Warts

There are multiple treatments for warts, none showing consistent efficacy in controlled studies, with the exception of topical salicylic acid products.¹⁰ Existing modalities mostly aim at destruction or removal of visible lesions or induction of an immune response to the virus. Choice of treatment depends on the location, size, number, and type of wart, as well as the age and cooperation of the patient. Induction of pain and the risk of scarring need to be considered. The patient and the treating clinician need to be persistent with therapy as it may take up to 4 to 6 months for the warts to resolve.

- **Topical Therapies:** Salicylic acid preparations are available as nonprescription solutions, gels, plasters, or patches. Compound W wart remover, Dr. Scholl's Clear Away, Duofilm, Mediplast, Occlusal, Trans-Ver-Sal, and Wart-Off are examples of some available products with salicylic acid. The patients should follow the package instructions. Most preparations are applied at bedtime, after the wart(s) has been soaked in warm water. Surface thick layers of keratin should be removed with an emory board. The induced irritation causes an inflammatory immune response, which speeds resolution of the wart. Treatment may take up to 4 to 12 weeks to be effective.
- **Cryotherapy:** Liquid nitrogen is applied to the wart by a healthcare provider using a Q-tip or a spray canister for 10 to 20 seconds or until a 2-mm rim of white frost appears beyond the border of the wart. The treatment can be repeated 2 or 3 times during a visit (see Chapter 7 for instructions). Repeat treatments can be done every 2 to 3 weeks if improvement is noted. Over-the-counter cryotherapy kits are available. Although the agent is not as cold as liquid nitrogen, these home kits can sometimes be successful in destroying warts. Patients must carefully follow the package insert directions for use, to avoid injury.
- **Procedures:** Surgical excision, electrosurgery, and laser surgery may be used to remove or destroy warts, but these may result in significant scarring and recurrence of the wart within or adjacent to the scar.

Management of Genital Warts

- **Imiquimod 5% cream** (Aldara cream) is an immune response modifier, used primarily for genital warts.⁹ A thin layer of the cream is applied by the patient 3 times a week (eg, Monday, Wednesday, and Friday) sparingly to warts at bedtime and washed off in 6 to 10 hours for a maximum of 16 weeks. The cream may induce an inflammatory response prior to clearing of the warts.
- **25% podophyllin in tincture of benzoin** is an antimitotic agent applied every 1 to 3 weeks to external genital warts by a healthcare provider. It should be washed off in 20 minutes to 2 hours. It should not be used in pregnant or lactating women.
- **0.5% podophyllotoxin** (Condylox gel or solution) is a prescription medication that can be used at home by the patient. It is applied to external genital warts twice a day for 3 consecutive days per week, for up to 4 weeks. It should not be used in pregnant or lactating women.
- **15% sinecatechins** (Veregen) ointment, a green tea extract, is applied 3 times a day to external genital warts until the warts are clear. It should not be used longer than 16 weeks. It should not be used in pregnant or lactating women or in children.
- **HPV vaccine:** Two HPV vaccines are currently available, Gardasil and Cervarix. Both protect against the two HPV genotypes (HPV-16 and 18) that cause 70% of cervical cancers. Gardasil also protects against the 2 HPV genotypes (HPV 6 and 11) that cause 90% of genital warts. Vaccination is recommended for young women to prevent cervical intraepithelial neoplasia and cervical carcinoma. Gardasil has also been shown to be effective in preventing genital warts in males. The CDC has up to date information on these vaccines.

Prevention

Patients with anogenital warts need to use safe-sex practices. Sexual partners should be examined and treated, if necessary. Infected women should undergo evaluation of the uterine cervix to rule out neoplasia.

Indications for Consultation

Widespread warts that have not responded to therapy should be referred to dermatology or to gynecology, in cases of female genital warts.

Patient Information

For Nongenital Warts

American Academy of Dermatology: www.aad.org/skin-conditions/dermatology-a-to-z/warts

► For Genital Warts

Centers for Disease Control and Prevention: www.cdc.gov/std/hpv/common-clinicians/InsertGW.pdf

REFERENCES

1. Fatahzadeh M, Schwartz RA. Human herpes simplex virus infections: epidemiology, pathogenesis, symptomatology, diagnosis, and management. *J Am Acad Dermatol.* 2007;57(5):737–762. PMID: 17939933.
2. Workowski KA, Berman S. Sexually transmitted diseases treatment guidelines. *MMWR Recomm Rep.* 2010;59(60):22–25. PMID: 21160459.
3. Weinberg JM. Herpes zoster: epidemiology, natural history, and common complications. *J Am Acad Dermatol.* 2007;57(6 suppl):S130–S135. PMID: 18021864.
4. Sampathkumar P, Drage LA, Martin DP. Herpes zoster (shingles) and postherpetic neuralgia. *Mayo Clin Proc.* 2009;84(3):274–280. PMID: 19252116.
5. Christo PJ, Hobelmann G, Maine DN. Post-herpetic neuralgia in older adults: evidence-based approaches to clinical management. *Drugs Aging.* 2007;24(1):1–19. PMID: 17233544.
6. Oxman MN, Levin MJ, Johnson GR, et al. A vaccine to prevent herpes zoster and postherpetic neuralgia in older adults. *N Engl J Med.* 2005;352(22):2271–2284. PMID: 15930418.
7. Leftheriou LI, Ker SC, Stratman EJ. Diagnosis of atypical molluscum contagiosum: the utility of a squash preparation. *Clin Med Res.* 2011;9(1):50–51. PMID: 20974889.
8. van der Wouden JC, van der Sande R, van Suijlekom-Smit LW, Berger MY, Butler CC. Interventions for cutaneous molluscum contagiosum. *Cochrane Database Syst Rev.* 2009;CD004767. PMID: 19821333.
9. Dunne EF, Friedman A, Datta SD, Markowitz LE, Workowski KA. Updates on human papillomavirus and genital warts and counseling messages from the 2010 Sexually Transmitted Diseases Treatment Guidelines. *Clin Infect Dis.* 2011;53(suppl 3):S143–S152. PMID: 22080267.
10. Kwok CS, Holland R, Gibbs S. Efficacy of topical treatments for cutaneous warts: a meta-analysis and pooled analysis of randomized controlled trials. *Brit J Dermatol.* 2011;165(2):233–246. PMID: 21219294.

Bacterial Infections

Scott Prawer
Bruce Bart

12

Introduction to Chapter / 97
Impetigo / 97
Boils / 98

Cellulitis / 99
Syphilis / 101
References / 103

INTRODUCTION TO CHAPTER

Most common bacterial skin infections are caused by coagulase-positive *Staphylococcus aureus* or group A beta-hemolytic streptococci. Before the widespread availability of antibiotics, many common skin infections resulted in serious illness and even death. In the 1950s following the widespread use of antibiotics, most staphylococcal and streptococcal skin infections responded well to the use of the penicillins. However, scattered cases of methicillin-resistant *Staphylococcus aureus* (MRSA) were already being reported by the early 1960s. From late 1960s to the mid-1990s, MRSA infections became a major problem especially in large urban hospitals. In the past decade, hospital-acquired MRSA infections began to decrease as hospitals instituted more aggressive infection control measures, but during that same time community-acquired MRSA infections increased.

Syphilis has been called “the great masquerader” and “the great imitator” based on the many varied presentations of the cutaneous and other organ system findings. Patients with secondary syphilis usually present with rashes that mimic common papulosquamous skin diseases, but can present with skin findings that mimic almost any cutaneous disorder.

IMPETIGO

Introduction

Impetigo is a common, highly contagious, superficial skin infection that presents with either a bullous or nonbullous

appearance. Nonbullous impetigo accounts for the majority of cases. It occurs in children of all ages, as well as adults, whereas the bullous form is most common in newborns. Impetigo is limited to the epidermis.

Pathophysiology

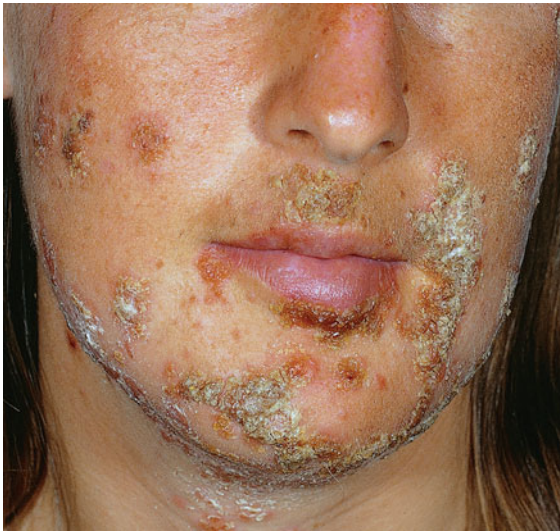Coagulase-positive *Staphylococcus aureus* is the most common cause of bullous and nonbullous impetigo. Group A beta-hemolytic streptococci including the nephritogenic strains may also cause impetigo.^{1,2}

Nonbullous impetigo represents a host response to the infection, whereas staphylococcal toxin causes bullous impetigo and no host response is required to manifest clinical disease.³

Clinical Presentation

▶ History and Physical Examination

- Nonbullous impetigo begins as a single lesion typically manifesting as a red macule or papule that quickly becomes a vesicle. The vesicle ruptures, forming an erosion and the contents dry to form the characteristic honey-colored crust commonly seen with impetigo (Figure 12-1). Nonbullous impetigo usually occurs on the face or extremities. Impetigo may occur concomitantly with herpes simplex and atopic dermatitis.
- Bullous impetigo begins as a superficial vesicle that rapidly progresses to a flaccid bulla, with sharp margins



▲ **Figure 12-1.** Extensive impetigo on face. Multiple yellow white crusts.

and no surrounding erythema. When the bulla ruptures, a moist yellow crust forms. Impetigo is often spread to surrounding areas by autoinoculation. Bullous impetigo usually arises on grossly normal skin and favors moist intertriginous areas, such as the diaper area, axillae, and neck folds.

- Ecthyma is an uncommon variant of impetigo that initially presents as a typical impetigo infection that spreads into the dermis. It usually presents on the lower legs with thick crusts overlying superficial ulcers. It is more common in young children, immunosuppressed patients, and in patients with poor hygiene.

► Laboratory Findings

Bacterial cultures from the infected areas are usually positive for *S. aureus* or streptococci.

Diagnosis

The key diagnostic clinical features of impetigo are honey-colored crusts or bullae.

► Differential Diagnosis

- ✓ **Herpes simplex:** Presents with grouped vesicles on the lips, perioral, and genital region.
- ✓ **Atopic dermatitis:** Presents with pruritic, scaly, or crusted papules and plaques in patients with a history of atopy.
- ✓ **Varicella (chicken pox):** Presents with fever and widespread vesicles with surrounding erythema.

- ✓ **Other:** Perioral dermatitis, insect bites, tinea infections, abrasions, lacerations, thermal burns, erythema multiforme, dermatitis herpetiformis, burns, bullous fixed drug eruptions, staphylococcal scalded skin syndrome, bullous tinea pedis, and bullous insect bites. In adults, bullous pemphigoid and pemphigus are in the differential.

Management

The superficial crusts should be removed with gentle cleansing with an antibacterial soap. Wet dressings could also be applied to remove thicker crusts (Table 6-5). Localized impetigo can be treated with topical medications including:

- Bacitracin ointment 3 times a day for 3 to 5 days.
- Mupirocin (Bactroban) ointment 3 times a day for 3 to 5 days.
- Retapamulin (Altabax) ointment twice a day for 5 days.

Severe or more widespread impetigo may require oral antibiotics, such as first-generation cephalosporins, dicloxacillin, amoxicillin/clavunate, or azithromycin.^{1,3} Impetigo usually responds well to treatment, but may be recurrent.

Indications for Consultation

Severe or persistent disease that does not respond to therapy.

Patient Information

PubMed Health: www.ncbi.nlm.nih.gov/pubmedhealth/PMH0001863/

BOILS

Introduction

A boil (furuncle) is a deep-seated inflammatory nodule that develops around a hair follicle, often from a preceding more superficial folliculitis. A carbuncle is two or more confluent boils.

Pathophysiology

Coagulase-positive *Staphylococcus aureus* (SA) is the most common cause of boils and carbuncles. The organism may be methicillin sensitive (MSSA) or methicillin resistant (MRSA).

MRSA infections may be acquired in health care facilities such as hospitals and nursing homes or now more commonly in the community. In one study of 12 United States' emergency departments, MRSA infections were responsible for 38% to 84% of purulent skin and soft tissue infections.⁴

Clinical Presentation

History

Patients usually give a history of a rapidly enlarging tender “pimple” or boil. The patient may give a history of risk factors such as crowded living conditions, infected family members, diabetes, obesity, atopic dermatitis, or inherited or acquired immune deficiency.

Physical Examination

A boil starts as a hard, tender, red, follicular centric nodule. The nodule enlarges and becomes painful and fluctuant after several days (Figure 12-2). Rupture may occur, with extrusion of pus.

Laboratory Findings

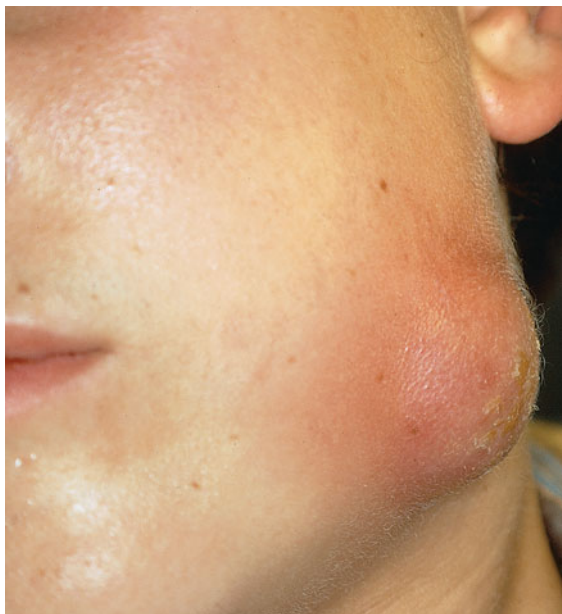Cultures from pus within the lesion or from drainage are usually positive for MSSA or MRSA.

Diagnosis

The key diagnostic clinical feature of a boil is a tender, fluctuant cyst or nodule.

Differential Diagnosis

- ✓ **Ruptured epidermal inclusion cyst:** This may very closely resemble a staphylococcal boil, but when lanced, the cyst contains thick white keratinous material.



▲ **Figure 12-2.** Staphylococcal boil on jawline.

- ✓ **Acne cyst:** This may also closely resemble a staphylococcal boil, but other signs of acne such as comedones should be present.
- ✓ **Hidradenitis suppurativa:** Presents with cysts limited to intertriginous areas of the body.
- ✓ **Other:** Deep fungal infections, dental abscess, kerion.

Management

The primary and most important management of boils and carbuncles is simple incision with a number 11 scalpel blade and drainage with evacuation of the pus, probing the cavity to break up loculations. Bacterial cultures may also be performed if a MRSA infection is suspected. The wound can be packed with iodoform gauze to encourage further drainage. The surgical site should be covered with a dry dressing.

Patients with central facial disease, multiple lesions, immunosuppression, lesions greater than 5 cm, or with surrounding cellulitis or fever may require systemic antibiotics. Patients who are very young or very old may also require systemic antibiotics. Recommended oral antibiotics for MSSA infections include dicloxacillin, cephalexin, clindamycin, doxycycline, minocycline, and trimethoprim sulfamethoxazole.⁵ Medications recommended for MRSA include clindamycin, doxycycline, minocycline, and trimethoprim sulfamethoxazole.⁵

In addition, carriers of MSSA and MRSA should be treated with intranasal mupirocin (Bactroban) ointment twice a day for 5 days and 4% chlorhexidine (Hibiclens) wash daily.

Indications for Consultation

Severe or persistent or recurrent disease that does not respond to therapy.

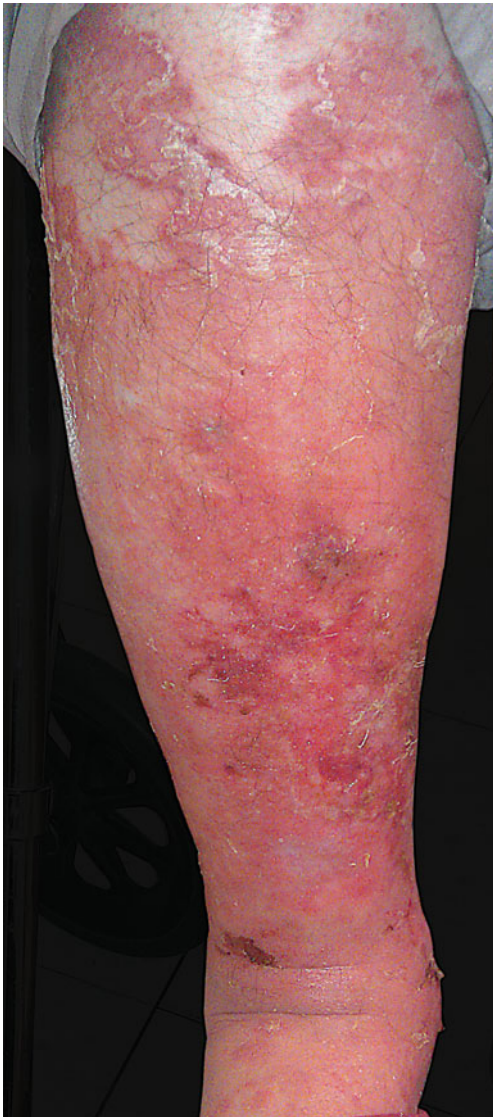Patient Information

- Centers of Disease Control and Prevention: www.cdc.gov/mrsa/
- MedlinePlus/carbuncles: www.nlm.nih.gov/medlineplus/ency/article/000825.htm
- MedlinePlus/boils: www.nlm.nih.gov/medlineplus/ency/article/001474.htm

CELLULITIS

Introduction

Cellulitis is an acute infection of the dermis and subcutaneous tissue. It is a common cause of inpatient hospital admissions, accounting for 10% of infectious disease-related US hospitalizations from 1998 to 2006.⁶



▲ **Figure 12-3.** Cellulitis on leg of diabetic patient. Warm tender areas of erythema on foot and leg.

Pathophysiology

Most cases of cellulitis are caused by *S. aureus* and group A *Streptococcus*.⁷ However, in certain situations other organisms may be involved, such as gram-negative organisms in cellulitis originating from a toe web fissure or *Hemophilus influenza* in young infants.

Risk factors for cellulitis include skin trauma or an underlying lesion such as a leg ulcer or fissured toe webs that can serve as a portal of entry for pathogenic bacteria. Other risk factors include chronic venous or arterial insufficiency, edema, surgery, intravenous drug use, body

piercing, human and animal bites, diabetes, hepatic cirrhosis, immunosuppression, and neutropenia.^{6,8}

Clinical Presentation

History

Cellulitis typically presents with rubor (erythema), dolor (pain), calor (warmth), and tumor (edema).

Physical Examination

Cellulitis typically begins with the acute onset of localized erythema and tenderness. The borders may be ill-defined and surface crusts may develop (Figure 12-3). Other symptoms include fever, malaise, and chills. Less common findings include ascending lymphangitis and regional lymphadenopathy. Cellulitis usually presents in a unilateral distribution. Some other clinical presentations of less common types of cellulitis are listed in Table 12-1.

Laboratory Findings

The diagnosis of cellulitis is generally made in the clinical setting. If indicated, cultures from exudate or blistered areas can be done with a culturette swab or cultures can be obtained by aspirating the affected skin. A skin punch biopsy of affected skin may also be cultured. However, these techniques often do not isolate the pathogenic organism.⁹ If cultures are positive, they usually show gram-positive microorganisms, primarily *Staphylococcus aureus*, group A or group B streptococci, *Streptococcus viridans*, *Streptococcus pneumoniae*, *Enterococcus faecalis*, and, less commonly, gram-negative organisms such as *Hemophilus influenzae* and *Pseudomonas aeruginosa*.^{8,9}

Diagnosis

The key diagnostic clinical feature of cellulitis is a painful, warm, red, edematous plaque.

Differential Diagnosis

- ✓ **Acute allergic contact dermatitis:** Usually presents with pruritic, but not painful red plaques, with more than one area involved.
- ✓ **Stasis dermatitis:** Presents with bilateral chronic dermatitis on the lower legs, with red/brown pigment.
- ✓ **Thrombophlebitis/deep vein thrombosis (DVT):** Presents with calf pain, erythema, usually no fever or chills, abnormal ultrasound of the leg veins.
- ✓ **Other:** Insect bite, erythema migrans, erythema nodosum, Sweet's syndrome, panniculitis, eosinophilic cellulitis, fixed drug eruption, lipodermatosclerosis, and polyarteritis nodosum.

Table 12-1. Less common types of cellulitis.

Types of Cellulitis	Presentation	Organism(s)
Erysipelas	Sharply defined red, edematous plaque, usually on face or legs	Group A, or less commonly B, C, or G streptococci or rarely <i>S. aureus</i>
Periorbital (preseptal) cellulitis	Painful erythema and edema on the eye lids and periorbital area, more common in children	<i>S. aureus</i> , <i>Streptococcus pyogenes</i> , <i>Hemophilus influenzae</i>
Ecthyma gangrenosum	Painful blue-grey thick eschar over an ulcer in an immunocompromised patient	<i>Pseudomonas aeruginosa</i>
Perianal cellulitis (dermatitis)	Sharply margined bright red, painful erythema surrounding the anus. More common in young children	<i>Streptococcus pyogenes</i>
Streptococcal intertrigo	Similar presentation to perianal strep cellulitis, but it occurs in body fold areas such as the axillae and inguinal area	<i>Streptococcus pyogenes</i>
Crepitant cellulitis (gas gangrene)	Rapid development of edema, crepitus, and bullae	<i>Clostridia</i> species usually <i>C. perfringens</i>
Gangrenous cellulitis (necrotizing fasciitis)	Indurated painful erythema with bullae (Figure 12-4) quickly progressing into a large black eschar and necrosis of the skin, fascia, or muscle	Polymicrobial including Group A <i>Streptococcus</i> and anaerobes

Management

Treatment for the most common forms of cellulitis that is likely caused by methicillin-sensitive *Staphylococcus aureus* includes empiric treatment with a penicillinase-resistant penicillin, first-generation cephalosporin, amoxicillin-clavulanate, a macrolide, or a fluoroquinolone antibiotic.^{8,9} Treatment for MRSA and other organisms and other forms of cellulitis are summarized in references 8 and 9.

Localized disease can be treated in the outpatient setting, whereas extensive disease requires intravenous administration in an inpatient setting. Ancillary measures include elevation and immobilization of the involved limb to reduce swelling. One should also identify and treat the underlying portal of entry of the cellulitis (eg, tinea pedis,

leg ulcer). Imaging studies may be needed, if crepitant or necrotic cellulitis is suspected.

Indications for Consultation

Severe or persistent disease that does not respond to treatment. Patients with high fevers, crepitant, or necrotic cellulitis should be hospitalized.

Patient Information

PubMed Health: www.ncbi.nlm.nih.gov/pubmedhealth/PMH0001858/

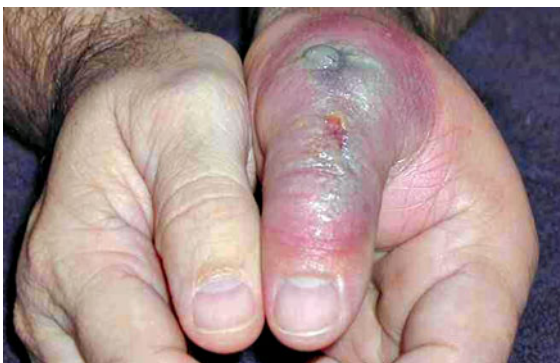SYPHILIS

Introduction

Syphilis is a sexually transmitted disease with worldwide distribution. Incidence dropped dramatically after introduction of penicillin as a treatment, but the CDC has reported resurgence in recent years, mostly in black and hispanic populations and in men who have sex with men.¹⁰ The skin eruption may manifest various morphologies, often mimicking other skin conditions, such as pityriasis rosea, psoriasis, lichen planus, exanthems, etc., giving cutaneous secondary syphilis the name “the great masquerader.”

Pathophysiology

Syphilis is caused by *Treponema pallidum*, a spirochetal bacterium. Approximately one-third of persons who come in contact with a lesion become infected. After inoculation through skin or mucous membranes, the bacterium spreads throughout the body via the lymphatic system and blood.



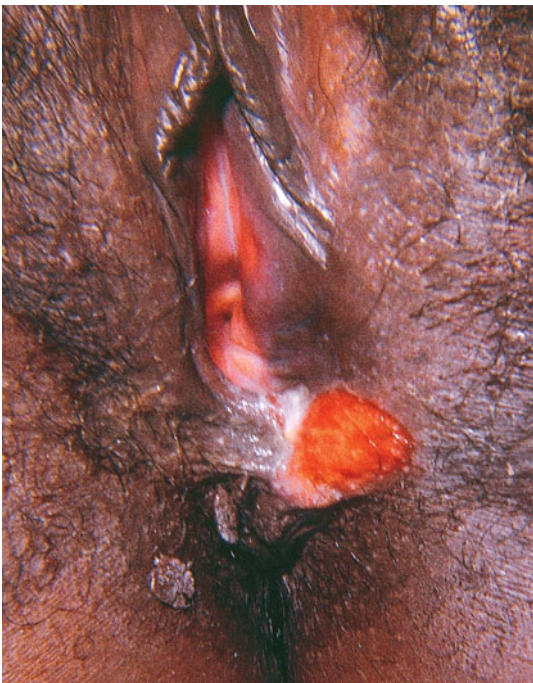▲ **Figure 12-4.** Necrotizing fasciitis on hand. Sudden onset of painful area with erythema, edema, and bullae.

Clinical Presentation

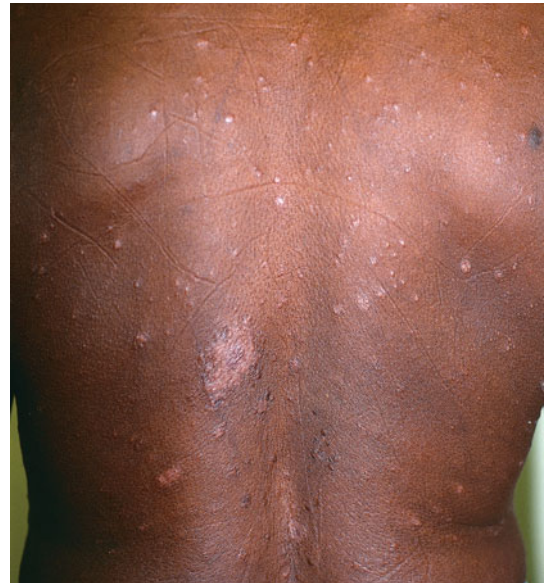► History and Physical Examination

Syphilis progresses through active and latent stages and in some cases progresses to a tertiary stage.

- **Primary stage:** At the site of entry, 10 to 90 days (average 3 weeks) after infection, a dusky red macule appears and evolves into a papule. Surface necrosis occurs with progression to a nontender, indurated, firm ulcer (chancre), with a raised border (Figure 12-5). Prominent regional lymphadenopathy may be present. The ulcer spontaneously heals in 2 to 10 weeks.
- **Secondary stage and latent stages:** Systemic symptoms such as fever, malaise, sore throat, generalized lymphadenopathy, myalgia, and headache develop 4 to 10 weeks after onset of infection. Within a few days, a pink, violaceous or red-brown macular, papular or more typically a papulosquamous eruption appears on the face, trunk (Figure 12-6), and extremities; often including the palms and soles (Figure 12-7). The eruption may become follicular, pustular, annular, nodular, or plaque-like and may be pruritic. A patchy, “moth-eaten” and/or diffuse alopecia may develop. Superficial erosions (mucous patches) are seen in the mouth, throat, and genitalia. Wart-like moist papules (condylomata lata) may appear in the anogenital area. Without treatment, the symptoms



▲ **Figure 12-5.** Syphilis. Primary chancre on vulva presenting as a superficial ulcer.



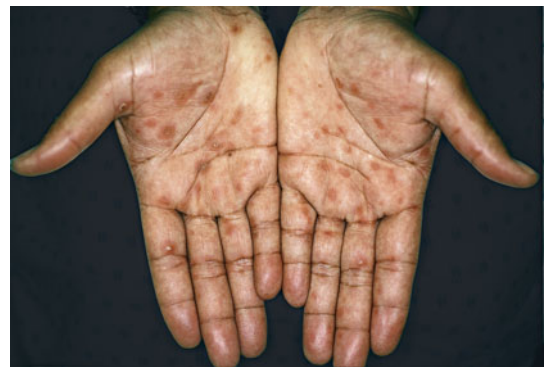▲ **Figure 12-6.** Secondary syphilis on back. Multiple scaly papules.

and eruptions clear within 3 to 12 weeks, but may relapse at a later time. Most relapses occur within 1 year (early latent stage). After 1 year (late latent stage), relapse is unlikely.

- **Tertiary syphilis:** Only a small percentage of patients with syphilis go on to develop tertiary syphilis that primarily affects the central nervous system and the cardiovascular system.

► Laboratory Findings

Nontreponemal blood tests, such as the rapid plasma regain (RPR) or venereal disease research laboratory test (VDRL), are useful for screening, but may be negative



▲ **Figure 12-7.** Secondary syphilis on palms. Pink and tan macules and papules.

in early primary syphilis, or show false-positive results. Biologic false-positive results can occur, usually with a low titer (<1:8). Positive reactions need to be confirmed with a *Treponemal pallidum* particle agglutination assay (TPPA) for IgM and IgG antibodies to *T. pallidum* proteins.¹¹

The spirochete can be detected by dark-field microscopic examination of serous material obtained from a chancre. A skin biopsy of primary or secondary lesions may detect *T. pallidum*, using special stains.

Diagnosis of Primary Syphilis

The diagnostic feature is a painless indurated ulcer on the genitals.

► Differential Diagnosis of Primary Syphilis

- ✓ **Chancroid:** Presents with very painful ulcers or erosions that are not indurated.
- ✓ **Herpes simplex:** Presents with grouped vesicles or erosions. Cultures and Tzanck smear are diagnostic.
- ✓ **Other:** Lymphogranuloma venereum, trauma, fixed drug eruption, and ulcerated genital carcinoma.

Diagnosis of Secondary Syphilis

The diagnostic features are pink to rust colored macules and/or papules on the trunk, palms, and soles.

► Differential Diagnosis of Secondary Syphilis

- ✓ **Pityriasis rosea:** Presents with oval, scaly papules, or plaques with a collarette scale located on the trunk in a parallel sloping arrangement similar to evergreen branches. A larger herald lesion is usually present and palms and soles are not involved.
- ✓ **Guttate psoriasis:** Presents with pink papules or plaques with subtle to silvery scale, primarily on the trunk. Palms and soles are usually not involved with this form of psoriasis.
- ✓ **Other:** Tinea corporis, tinea versicolor, lichen planus, pityriasis lichenoides, drug eruptions, primary HIV infection, erythema multiforme, viral exanthems, nummular dermatitis, folliculitis, and alopecia areata. Mucous membrane lesions may mimic lichen planus, aphthae, hand-foot-mouth disease, herpangina, and angular cheilitis.

Management

A single intramuscular dose of Benzathine penicillin G 2.4 million units is recommended for primary, secondary, and early latent syphilis. See CDC publication for treatment of penicillin allergic individuals or for special cases.¹¹ Follow-up laboratory testing is recommended at 3 and 6 months after treatment, then every 6 months for 2 years. Patients with syphilis often have other sexually transmitted diseases and should be evaluated and treated for these diseases and counseled on safe sex practices. Cases of syphilis should be reported to the local health department for follow up and identification of sexual contacts.

Indications for Consultation

Significant doubt about the diagnosis, immunosuppressed patient, or patient with advanced disease.

Patient Information

Centers for Disease Control and Prevention: www.cdc.gov/std/syphilis/default.htm

REFERENCES

1. Silverberg N, Block S. Uncomplicated skin and skin structure infections in children: diagnosis and current treatment options in the United States. *Clin Pediatr* (Phila). 2008;47(3):211–219. PMID: 18354031.
2. Ruocco E, Donnarumma G, Baroni A, Tufano MA. Bacterial and viral skin diseases. *Dermatol Clin*. 2007;25(4):663–676, xi. PMID: 17903625.
3. Bernard P. Management of common bacterial infections of the skin. *Curr Opin Infect Dis*. 2008;21(2):122–128. PMID: 18317033.
4. Talan DA, Krishnadasan A, Gorwitz RJ, et al. Comparison of *Staphylococcus aureus* from skin and soft-tissue infections in US emergency department patients, 2004 and 2008. *Clin Infect Dis*. 2011;53(2):144–149. PMID: 21690621.
5. Atanaskova N, Tomecki KJ. Innovative management of recurrent furunculosis. *Dermatol Clin*. 2010;28(3):479–487. PMID: 20510758.
6. Bailey E, Kroshinsky D. Cellulitis: diagnosis and management. *Dermatol Ther*. 2011;24(2):229–239. PMID: 21410612.
7. Chira S, Miller LG. *Staphylococcus aureus* is the most common identified cause of cellulitis: a systematic review. *Epidemiol Infect*. 2010;138(3):313–317. PMID: 19646308.
8. Stevens DL, Eron LL. Cellulitis and soft-tissue infections. *Ann Intern Med*. 2009;150(1):ITC11. PMID: 19124814.
9. Swartz MN. Clinical practice. Cellulitis. *N Engl J Med*. 2004;350(9):904–912. PMID: 14985488.
10. Su JR, Beltrami JF, Zaidi AA, Weinstock HS. Primary and secondary syphilis among black and Hispanic men who have sex with men: case report from 27 states. *Ann Intern Med*. 2011;155(3):145–151. PMID: 21810707.
11. Workowski KA, Berman S. Sexually transmitted diseases treatment guidelines. *MMWR Recomm Rep*. 2010;59(RR-12):26–40. PMID: 21160459.

13

Infestations and Bites

Cindy Firkins Smith

Introduction to Chapter / 104
Scabies / 104
Lice (Pediculosis) / 108

Lyme Disease / 110
Bed Bugs / 114
References / 116

INTRODUCTION TO CHAPTER

Arthropods have always feasted on humans and humans have tried countless strategies to keep them from doing so. The societal burden of biting and sucking bugs is significant, costing millions of dollars, tremendous discomfort, and immeasurable emotional distress. They bite, we itch, we scratch, and these facts seem destined to endure.

SCABIES

Introduction

Scabies is a common parasitic infection caused by the mite *Sarcoptes scabiei* var *hominis*. Transmission is primarily person-to-person by direct contact and although anyone is susceptible, situations that result in more skin-to-skin contact, such as parents with small children, sexual activity, overcrowding, and institutional settings, increase the incidence of infestation. Although the scabies mite has not been shown to transmit any significant pathogens, the intense itching associated with the infestation, the risk of superinfection of excoriated skin, and the fact that up to 300 million people may be affected worldwide annually make scabies a significant public health problem.¹

Pathophysiology

Sarcoptes scabiei is an obligate human parasite that completes its entire 30-day life cycle within the epidermis. The fertilized female weaves through the epidermis and leaves

a trail of 60 to 90 eggs and feces (scybala), in her burrow (Figure 13-1). The eggs hatch into larvae that then mature into nymphs and adults. The rash and pruritus of scabies is a result of a hypersensitivity reaction to the mite and its detritus. The incubation period from infestation to pruritus can range from days to months. The first time an individual is infested, it typically takes 2 to 6 weeks to become sensitized and develop symptoms, but in subsequent infestations, the previously hypersensitized individual can begin itching in as little as 1 to 3 days. Some infested individuals never develop hypersensitivity to the mite and never experience symptoms, but can still transmit the infection; these are asymptomatic “carriers.”

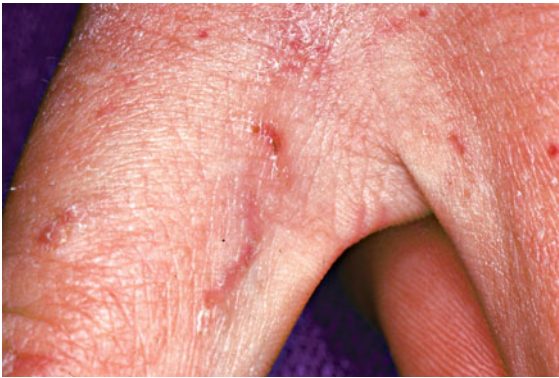Clinical Presentation

History

Intense pruritus is the main presenting complaint, although very young children who cannot verbalize itching are often irritable and eat and sleep poorly. Adults often complain that the pruritus is worse at night. Family members and close contacts frequently report similar symptoms.

Physical Examination

The patient presenting with scabies usually has a non-descript, excoriated, papular dermatitis. The most common physical findings are papules, vesicles, pustules, or nodules. These typically occur on the trunk, arms, hands (Figures 13-2 and 13-3), and genitals in adults and may also

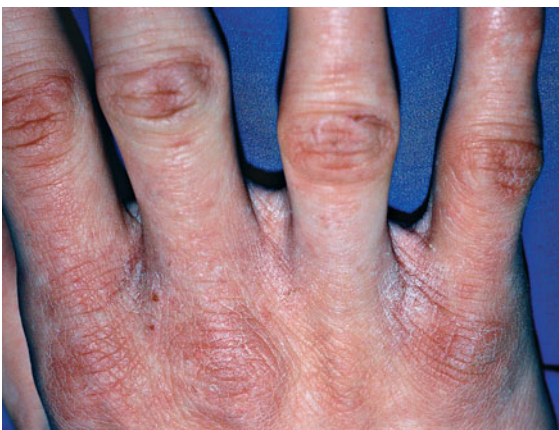

▲ **Figure 13-1.** Burrow in a finger web. Thin curved ridge in the superficial epidermis created by a female mite.

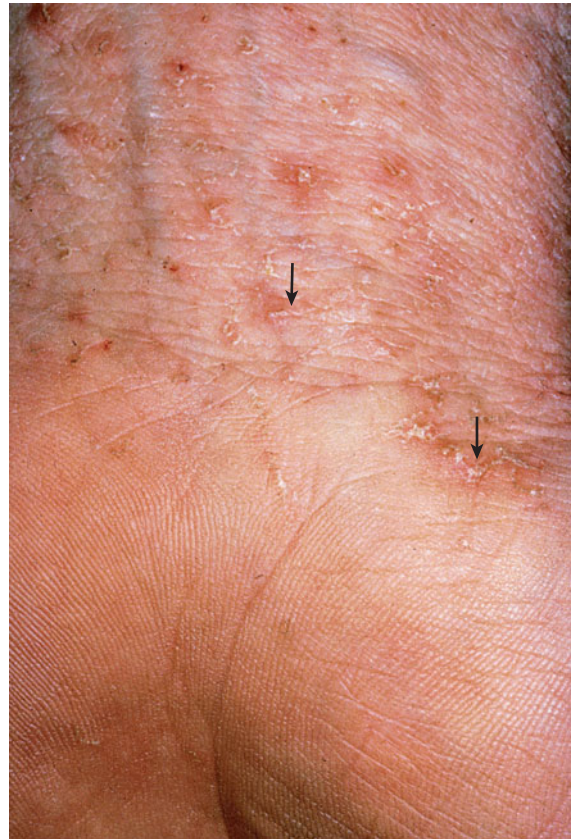involve the head, neck, and feet in infants and young children (Figures 13-4 and 13-5). The burrow, a short, wavy line, is pathognomic of scabies and is typically seen on the wrists, finger webs, and penis (Figures 13-1 and 13-3).

Less common presentations include nodular, bullous, and crusted scabies.²

- **Nodular scabies:** This typically presents with a few salmon-colored pruritic nodules usually seen in the axillae, groin, and male genitalia. Nodular scabies is a hypersensitivity reaction that typically occurs after a successfully treated scabies infestation and does not necessarily indicate active infection.
- **Bullous scabies:** While blisters commonly occur on the palms and soles of infants infested with scabies, bullous



▲ **Figure 13-2.** Scabies in finger webs. Excoriated papules with lichenification of skin due to chronic scratching.



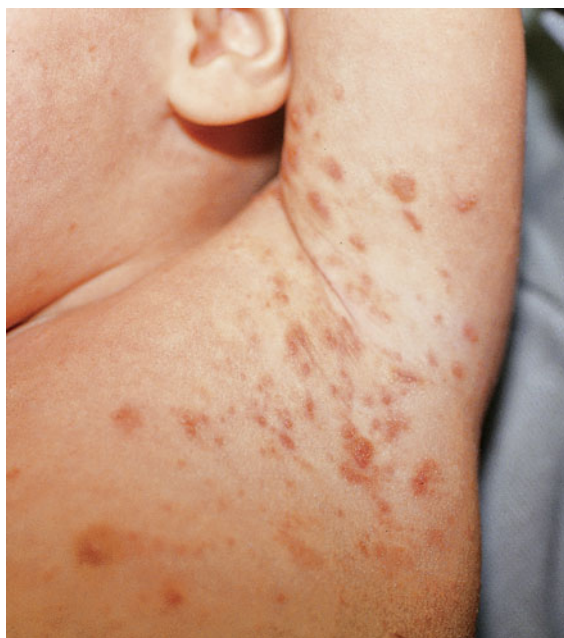▲ **Figure 13-3.** Scabies volar wrist. Tiny papules with many curved and wavy burrows.

scabies is a more extensive bullous eruption, most commonly seen in elderly adults. It is often confused with bullous pemphigoid.

- **Crusted (Norwegian) scabies:** This presents with thick, crusted or scaly plaques and is often confused with psoriasis. Crusted scabies typically affects the immunocompromised, elderly, disabled, or debilitated individuals. These patients often do not exhibit typical pruritus and scratching and are often infested with thousands of mites. They are highly contagious.

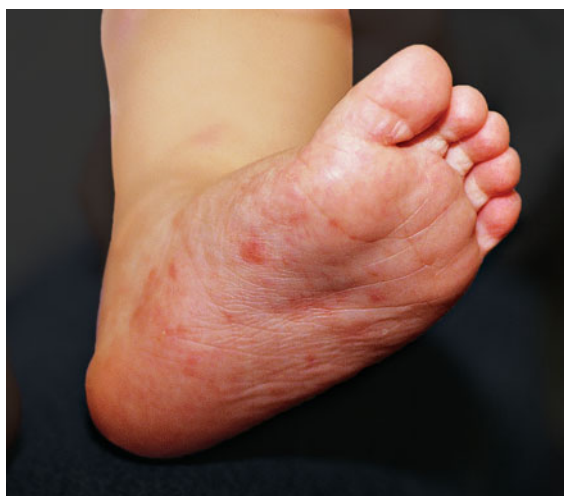► Laboratory Findings

Table 4-3 has instructions for collection and examination of a scabies preparation. The presence of a mite, eggs, or scybala in a scabies preparation confirms the diagnosis (Figures 13-6 and 13-7). Scraping the skin for a scabies specimen is not always easy to do without injuring the patient, particularly if that patient is a squirming child; therefore, other identification techniques have

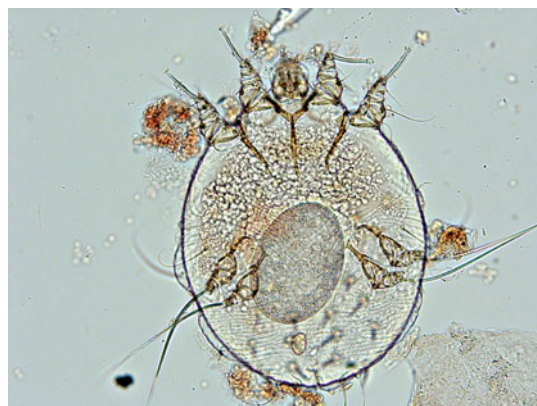

▲ **Figure 13-4.** Scabies in axillae of a child. Papules and nodules.

been suggested. Dermoscopy has shown to be a sensitive tool for mite identification.³ Another method is to firmly apply adhesive tape to a burrow, pull it off rapidly and then transfer the tape to a slide for microscopic identification. This has also been shown to be an inexpensive, easy and relatively sensitive way to identify burrow contents.³



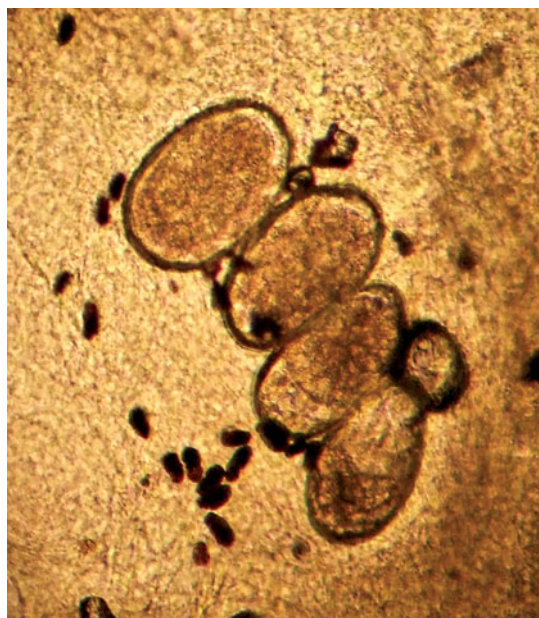
▲ **Figure 13-5.** Scabies on a child's foot. Papules on plantar surface of foot.



▲ **Figure 13-6.** Female *Sarcoptes scabiei* mite with egg. Microscopic (40x) view of skin scrapings of a papule.

Diagnosis

The key diagnostic features of scabies are intensely pruritic papules, vesicles or burrows in the finger webs, wrists, breast, axillae, abdomen, or genitals. In children, the lesions can be in any location including the head, neck, or feet.



▲ **Figure 13-7.** Four eggs and scybala (feces) of female *Sarcoptes scabiei* mite. Microscopic view of skin scraping of a burrow.

Differential Diagnosis

Scabies should be considered in the differential diagnosis of any patient who presents with an intensely pruritic, eczematous rash of recent onset, especially if family members and other close contacts have similar complaints. Scabies is often misdiagnosed as the following diseases.

- ✓ **Atopic dermatitis:** Presents with scaly, often crusted, pruritic papules and plaques on the face, and flexural areas in patients with a personal or family history of atopy. Scabies may be difficult to diagnose in patients who have moderate to severe atopic dermatitis.
- ✓ **Body and pubic lice:** Presents with pruritus and lice on the body or clothing.
- ✓ **Other arthropod bites:** There are no burrows present.
- ✓ **Dermatitis herpetiformis:** Presents with lesions very similar to scabies on the elbows, knees, and lower back. The genitals are not affected.
- ✓ **Other:** Fiberglass dermatitis, tinea corporis, drug rash, lichen planus, contact dermatitis, dyshidrotic dermatitis, prurigo, delusions of parasitosis, acropustulosis of infancy.

Management

Scabies is usually a clinical diagnosis. A patient can be treated based on a suspicious history and clinical presentation. Prescription scabicides are necessary to treat scabies. No over the counter medications are approved for scabies treatment. Table 13-1 outlines scabies treatment options. Permethrin 5% cream is the most effective treatment, according to the Cochrane Review which has the largest review of interventions for treating scabies.⁴ The cream should be applied at bedtime and spread thoroughly from neck to soles, including under the fingernails and toenails. In children under two, permethrin cream should also be applied to the head and neck and mittens or socks should be placed on the hands to avoid rubbing the cream into the eyes. Patients should remove the cream after 8 to 14 hours by showering or bathing. Oral ivermectin, although not approved by the Federal Food and Drug Administration (FDA) for the treatment of scabies, is easier to use and may result in improved treatment compliance. Two doses of ivermectin are required to achieve cure rates equivalent to one application of permethrin cream.⁵ Crusted scabies requires a more aggressive approach, with a combination of 5% permethrin every 2 to 3 days for up to 2 weeks and oral ivermectin in 3 to 7 doses over approximately 1 to 4 weeks, depending on the severity of infection.⁵

Table 13-1. Medications for treatment of scabies.

Generic & Brand Names	Administration	Age Restrictions & Pregnancy Category	Risks	Comments
Permethrin cream 5% (Elimite, Acticin)	Apply from neck down (include head and neck in infants and young children). Include skin folds (but not mucous membranes) and under nails. Wash off in 8-14 h	FDA approved for scabies in infants age ≥ 2 months Pregnancy Category B	Mild transient stinging or burning	Considered treatment of choice for scabies. Efficacy of 1 versus 2 applications has not been established. CDC and others recommend repeat treatment 1 week after the first
Lindane lotion or cream 1% (Kwell)	Apply thin layer from neck down, leave on overnight and wash off	FDA approved for scabies. Infants, children, elderly or those who weigh < 110 lbs are at greater risk for toxicity Pregnancy Category C	Black box warning for risks for seizures and death with repeated use Contraindicated in patients with sores or inflamed skin in application area	Considered a second or third line therapy ²
Crotamiton cream and lotion 10% (Eurax)	Apply for 24 h, rinse off, and then reapply for additional 24 h	FDA approved for scabies in adults Pregnancy Category C	No major safety issues	Frequent treatment failures reported
Ivermectin tablet 3 mg (Stromectol)	Single dose 200 mcg/kg orally Appropriate dose for 50 kg patient is 10 mg Take on empty stomach with water. Total of 2 doses at least 7 days apart may be necessary ⁵	Not FDA approved for scabies Safety in children < 15 kg and in pregnant women has not been established Pregnancy Category C	Most reported toxicity seen in treatment of filarial parasites ⁵	Consider in patients who have failed treatment with or who cannot tolerate FDA-approved topical medications Two doses required to achieve cure rate similar to single application of permethrin ⁵

Fomite transmission is not considered a major problem in typical scabies infestations and scabies mites generally do not survive more than 2 to 3 days off human skin. Bedding, clothing, and towels used by infested persons or their close contacts anytime during the 3 days before treatment should be washed in hot water and dried in a hot dryer, dry-cleaned or sealed in a plastic bag for at least 72 hours. Persons who had close contact with an infested individual should be evaluated and treated appropriately.

The pruritus from scabies is a result of patient hypersensitivity and neither the immune response nor the itching resolves immediately after treatment. Patients should be advised that it takes up to 4 weeks for symptoms to resolve despite effective treatment. If pruritus persists beyond a month, the patient should be reexamined and if evidence of active infestation is present, the possibilities of poor treatment compliance, reinfestation, or mite scabicide resistance should be considered and addressed.

Indications for Consultation

If symptoms persist despite two courses of appropriate therapy, consider dermatologic consultation. A number of eczematous and vesiculobullous conditions can mimic the presenting signs and symptoms of scabies and occasionally scabies treatment can cause secondary dermatologic sequelae that require intervention.

Patient Information

- Scabies. Centers for Disease Control: www.cdc.gov/parasites/scabies/biology.html
- Scabies Tutorial. Medline Plus. National Institutes of Health: www.nlm.nih.gov/medlineplus/tutorials/scabies/hlm/index.htm
- Scabies. American Academy of Dermatology: www.aad.org/skin-conditions/dermatology-a-to-z/scabies

LICE (PEDICULOSIS)

Introduction

Human lice are bloodsucking, wingless insects that have been feeding on mankind for thousands of years.² Head, crab, and body lice remain a bane in modern times, with hundreds of millions of cases of pediculosis worldwide annually.

Head lice are the most common of the three pediculosis and are a ubiquitous nuisance. They are found in people of all age, sex, race, and socioeconomic class. School children ages 3 to 11, especially girls with long hair and a propensity to share hair care tools and accessories, are at greatest risk. African-American children are less commonly affected, perhaps because their hair shape or texture creates a less amenable environment for lice survival and reproduction.⁶

Crab (pubic) lice are transmitted primarily by sexual contact and the highest incidence is seen in men who have sex with men, ages 15 to 40.

Body lice give all lice a bad name. Not only are they associated with poor hygiene, they serve as disease vectors for epidemic typhus, relapsing fever, trench fever, and bacillary angiomatosis or endocarditis.^{2,7}

Pathophysiology

All three lice species are obligate human parasites that feed exclusively on human blood and do not survive for long off their human host. They vary in size, shape, and preference for body area location.

- **The head louse**, *Pediculus capitis*, as the name suggests, favors scalp hair. It is light tan to medium brown and is about the size of a sesame seed (Figure 13-8). Although it is unable to jump or fly, it moves extremely quickly and thus can be difficult to see. The female louse lives about 30 days and lays 5 to 10 eggs a day. Oval egg capsules or *nits* are cemented to hair shafts close to the scalp for warmth (Figure 13-9). Transmission is via direct contact or by fomites such as combs, brushes, hats, helmets, headphones; although static electricity and blow dryers have been shown to launch lice into the air, creating another possible mode of transmission.⁸
- **Crab lice**, *Phthirus pubis*, are smaller and wider than head lice and resemble tiny crabs. (Figure 13-10). Often referred to as pubic lice, this is a misnomer; as crab lice are adapted to ambulate over the entire body surface. The infestation can involve not only pubic hair, but also the scalp, eyebrows, eyelashes, moustache, beard, axillae, and perianal area.
- **The body louse**, *Pediculus corporis*, at 2 to 4 mm long, is slightly larger than the head louse, but otherwise looks



▲ **Figure 13-8.** Head louse (Reproduced with permission from Usatine RP, Smith MA, Chumley H, Mayeaux, Jr. E, Tysinger J, eds. *The Color Atlas of Family Medicine*. New York: McGraw-Hill; 2009. Figure 136-3).



▲ **Figure 13-9.** Nits attached to hair in head lice infestation.

similar. It differs from head and crab lice in that while it feeds on humans it does not live on them; it lives in clothing and lays its eggs along the seams (Figure 13-11).

Clinical Presentation

History

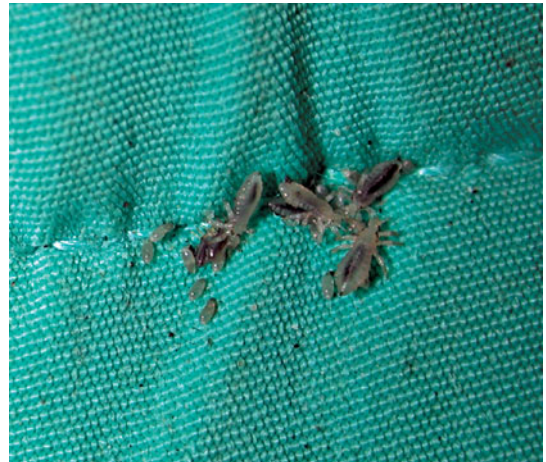A patient with lice will usually present with intense itching in the area of infestation, and a history compatible with exposure.

Physical Examination

Clinical findings are nonspecific eg, erythema, papules, wheals, excoriations, hemorrhagic crusts, and occasionally scale. The occipital scalp, posterior ears, and neck are the



▲ **Figure 13-10.** Crab louse attached to hair fiber (Reproduced with permission from Knoop KJ, Stack LB, Storrow AB, Thurman RJ, eds. *The Atlas of Emergency Medicine*. 3rd ed. New York: McGraw-Hill; 2010. Figure 25-20).



▲ **Figure 13-11.** Body lice in clothing seams (Reproduced with permission from Usatine RP, Smith MA, Chumley H, Mayeaux, Jr. E, Tysinger J, eds. *The Color Atlas of Family Medicine*. New York: McGraw-Hill; 2009. Figure 136-2).

most common sites involved with head lice; lower abdomen, pubic area, and thighs with crab lice; and back, neck, shoulders, and waist with body lice. Pyoderma and regional lymphadenopathy may be present. Macula cerulea, small bluish dots, may be seen at the site of lice and flea bites.

Nits may be seen on examination of proximal hair shafts or on clothing seams in cases of body lice. Identifying a live louse is the only way to make a definitive diagnosis of active infection, but since lice shy away from light and move very quickly, this is not easy to do. Systematically wet-combing detangled and lubricated hair with a specially designed nit comb has been shown to be a sensitive method to harvest and identify live lice.⁹

Laboratory Findings

A skin biopsy demonstrates nonspecific inflammation.

Diagnosis

The key diagnostic features of pediculosis are the presence of lice or nits on hair, skin or clothing seams.

Differential Diagnosis

For body and crab lice

- ✓ Scabies, flea bites, other arthropod bites, atopic dermatitis, and folliculitis.

For head lice

- ✓ Seborrheic dermatitis, residual hair styling products, and hair casts.

Management

- **Body lice** are usually successfully treated by bathing the patient and bagging and discarding infested clothing and bed linen. If clothing cannot be discarded, it can be washed in hot water (at least 149°F) for 30 minutes, dry cleaned or hot ironed (especially in seams). If nits are found on body hair, the best treatment option is a single 8- to 10-hour application of 5% permethrin cream to the entire body, similar to scabies treatment.¹⁰
- **Crab lice** can be treated topically with 1% and 5% permethrin cream or 1% lindane shampoo. The safest and most effective topical treatment is 5% permethrin cream applied overnight to all hair-bearing areas, washed off in the morning, and repeated 1 week later. Topical pediculocides cannot be applied to the eyelashes and treating this area is challenging. If possible, nits and lice can be physically removed with fingernails or a nit comb or ophthalmic-grade petrolatum ointment (only available by prescription) can be applied to the eyelid margins 2 to 4 times a day for 10 days. Regular petrolatum jelly (Vaseline) should not be used in this location because it can irritate the eyes.¹⁰ Oral ivermectin is not FDA-approved for crab lice, but has been suggested for patients with perianal or eyelid involvement or when topical treatment fails. The recommended dose is 200 mcg/kg, repeated 1 week later.¹¹ Individuals with crab lice should be evaluated for sexually transmitted diseases that often occur concomitantly.
- **Head lice** management can be challenging. Pediculocides remain the mainstay of treatment, but increased resistance to therapy, both by parents who are concerned about safety and by lice that have evolved to withstand insecticides, often confounds the health care provider. Pediculocides, currently employed for the treatment of head lice, are reviewed in Table 13-2. Many other treatments have been suggested. Trimethoprim-sulfamethoxazole has been studied in small trials and is recommended in combination with 1% permethrin for use in cases of multiple treatment failures or suspected lice resistance.⁷ Removal by fingers, nit combs, “bug-buster” combs, and commercially available “egg-removal” products, when studied, has been suboptimal in obtaining cure.⁹ Of the home-remedy occlusive agents (eg, petroleum jelly, mayonnaise, margarine, olive oil, etc.), petroleum jelly has shown the most success, although the Centers for Disease Control and Prevention (CDC) has reported that there is no clear scientific evidence that any of these are effective. Shaving the hair has been suggested as a chemical-free treatment option, but it can be emotionally traumatic for the child.⁸ Most studied treatments kill live lice and not nits and need to be repeated a week after the first application to treat newly hatched lice. Although most treatments need to be repeated 1 week after the first, there are two exceptions.

(1) Malathion kills live lice and nits and it should be repeated only if live lice are noted. (2) Lindane which is not a first-line treatment for head lice should be used for one treatment only because of its toxicity. Parents, caregivers, or patients should be instructed to carefully read and follow the patient medication guidelines in the package inserts of pediculocides. Clothing and linen used in the 2 days before treatment should be washed and dried at the hottest temperatures the fabrics can withstand, dry cleaned or sealed in plastic bags for 2 weeks. Hair grooming utensils should be soaked in hot water (130°F) for 5 to 10 minutes and the floor and furniture vacuumed.¹⁰ Although the presence of nits often creates anxiety, current consensus is that affected children may return to school after their first treatment. The presence of nits should **not** exclude school attendance.^{7,8}

Indications for Consultation

Consultation should be considered when live lice persist after two appropriate treatments or when symptoms persist beyond 4 to 6 weeks. Patients should be advised that it may take a number of weeks for symptoms to abate even when the lice have been successfully treated and that the persistence of nits does not imply persistent active infection.

Patient Information

Lice. Centers for Disease Control: www.cdc.gov/parasites/lice/

LYME DISEASE

Introduction

Lyme disease is caused by *Borrelia*, a spirochete transmitted by Ixodes ticks. In North America, 90% of cases occur on the east coast between the states of Maine and Maryland and in Minnesota and Wisconsin.¹³ *Borrelia* species also cause disease in central and eastern Europe and eastern Asia. The incidence of Lyme disease peaks in patients between the ages of 5 to 19 years and 55 to 69 years. The onset of Lyme disease usually occurs from May to November with a peak in June, July, and August. Erythema migrans is the characteristic annular plaque of Lyme disease (Figure 13-12).

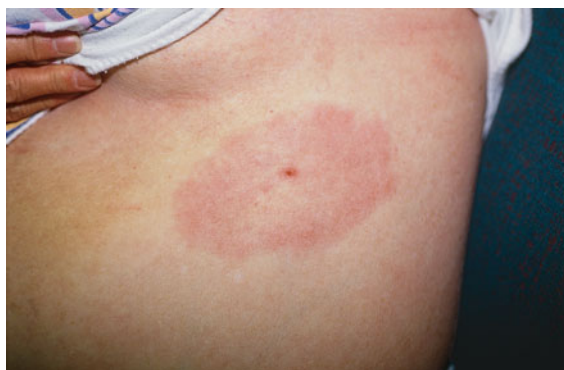Pathophysiology

Borrelia burgdorferi causes most cases of Lyme disease in North America. The deer tick, *Ixodes Scapularis*, is the most common vector for Lyme disease (Figure 13-13). This tick has a 2-year life cycle with larval, nymphal, and adult stages. The ticks feed once during each stage on various hosts and may acquire *B. burgdorferi* while feeding on an infected host.

Table 13-2. Medications for treatment of head lice.

Generic & Brand Names	Administration	Age Restrictions and Pregnancy Category	Risks/Warnings	Comments
Pyrethrins lotion 4% (Piperonyl Butoxide) (A-200, Pronto, RID) OTC	Apply to clean, dry hair. Leave on 10 min, rinse. Repeat in 7-10 days	FDA approved for infants age ≥ 2 months	Rare allergic reactions; do not use if allergic to chrysanthemums or ragweed	Resistance is common. ^{2,8} Kills lice, but not nits
Permethrin lotion 1% (Nix) OTC	Same as above	FDA approved for infants age ≥ 2 months. Pregnancy Category B	Same as above	Kills live lice, not nits. May kill newly hatched lice for several days after treatment
Malathion lotion 0.5% (Ovide)	Saturate clean, dry hair. Leave on 8-12 h, rinse. Repeat in 7-9 days only if live lice are present	FDA approved for children ≥ 6 years. Pregnancy Category B	Irritating to eyes and skin. Alcohol vehicle. Highly flammable. DO NOT use in contact with heat sources (eg, hair dryers, curling irons)	Strong odor, less resistance than with permethrin or pyrethrins. ^{2,8} Kills lice and some nits
Benzyl alcohol lotion 5% (Ulesfia)	Saturate clean, dry hair. Leave on 10 min, rinse. Repeat in 7 days	FDA approved for children ≥ 6 months. Pregnancy Category B	Irritating to skin and eyes. Transient skin numbness	FDA approved in 2009. Kills lice, but not nits
Spinosad suspension 0.09% (Natroba)	Apply to dry hair for 10 min, rinse; repeat in 7 days, if necessary	FDA approved for ages ≥ 4 years. Pregnancy Category B	Irritation of skin and eyes	More effective than permethrin ¹² . Very expensive, FDA approved in 2011. Kills lice, not nits
Ivermectin lotion 0.05% (SKLICE)	Apply to dry hair and leave on for 10 min and rinse off	FDA approved for ages 6 months and older. Pregnancy Category C	Irritation of eyes or skin	FDA approved in 2011
Permethrin cream 5% (Elimite, Acticin)	Apply to clean, dry hair. Occlude with shower cap. Leave on overnight. Rinse. Repeat in 7-10 days, if necessary	Not FDA approved for head lice . Pregnancy Category B	Rare allergic reactions; do not use if allergic to chrysanthemums or ragweed	Suggested in resistant cases but data suggest efficacy not superior to 1% ⁹
Crotamiton cream and lotion 10% (Eurax)	Apply to scalp, leave on 24 h before rinsing. Repeat 2 consecutive nights	Not FDA approved for head lice . Pregnancy Category C	Safety and absorption in children, adults, and pregnant women have not been evaluated	Few studies done on this treatment
Ivermectin tablet 3 mg (Stromectol)	200 mcg per kg PO, single dose. Appropriate dose for 50 kg patient is 10 mcg PO. Repeat in 7-10 days ⁸	Not FDA approved for head lice . Pregnancy Category C	Well tolerated, but not for use in pregnant women or children <15 kg ⁸	Limited studies show good resolution. Kills lice and partially kills nits
Lindane shampoo 1% (Kwell)	Apply to clean, dry hair. Leave on 4 min. Add water, lather, rinse 1 oz per adult treatment. Avoid 2nd treatment	Infants, children, elderly, and those who weigh <50 kg are at greater risk for toxicity. Pregnancy Category C	Black box warning for seizures and death reported after repeated or prolonged use; rarely after single application ⁵	Resistance common. Not recommended by American Academy of Pediatrics; banned in California . Use only as 2nd line, for those who fail or cannot tolerate other therapies

OTC, over the counter.



▲ **Figure 13-12.** Erythema migrans on trunk. Annular plaque with central clearing and central puncta from the bite.

The white-tailed deer and white-footed mouse are common hosts, but other species of birds, mice, rats, raccoons, and rabbits may also be hosts. In humans the affected tick usually has to be attached and feeding for 48 to 72 hours to transmit the *Borrelia* organism.¹⁴ Ixodes nymphs cause most of cases of Lyme disease. The nymphs are the size of a pinhead (2 mm or less), so they may go undetected while attached to human skin.¹⁴

Clinical Presentation

History

Typically patients have a history of being in a wooded or grassy area in an endemic region within the past month. However, many patients will not recall having a tick bite.

Lyme disease can progress through three stages.

- Early localized stage (3 to 30 days after bite): 50% of adults and 90% of children will present with erythema migrans 3 to 30 days (average 7 days) after the bite.¹⁴



▲ **Figure 13-13.** Ixodes scapularis (deer tick) on leaf (Centers for Disease Control and Prevention. PHIL Collection ID#1669).

Influenza like symptoms (headache, fatigue, myalgia, and fever), lymphadenopathy, and conjunctivitis may be present.

- Early disseminated stage (days to weeks later): Neurological symptoms such as severe headaches, neck stiffness, and Bell's palsy may develop. Pain and swelling in large joints and cardiac symptoms may also occur.
- Late disseminated stage (months to years later): About 10% to 20% of patients with Lyme disease will have chronic arthritis or neurological symptoms.¹⁴

Physical Examination

The initial lesion of erythema migrans is a pink macule that rapidly expands to a diameter of about 15 cm, although the range can be from 3 to 68 cm (Figure 13-12). Often there is central clearing, but the lesion may be uniform throughout. The initial lesion is at the site of the bite and is usually located on the legs, trunk, groin, or axillae. In children, common sites include the head and neck. Erythema migrans resolves without treatment within 4 to 6 weeks.¹⁴

Laboratory Findings

Serologic testing may be done in patients who have a high likelihood of Lyme disease. However, false-negative results can occur if the tests are done too early in the course of the disease. False positives can occur in patients who live in endemic areas. The Centers for Disease Control and Prevention (CDC) publishes specific recommendations for serological testing (Figure 13-14).¹⁵

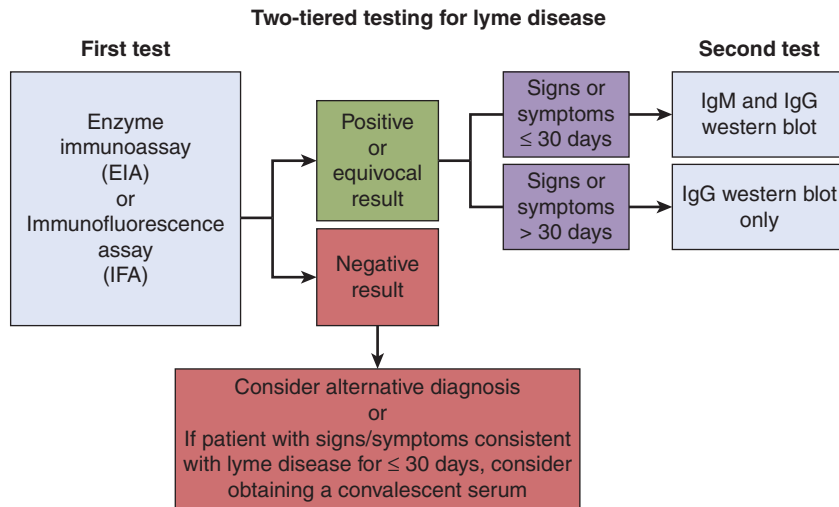
While the histopathologic features of erythema migrans are not specific, a skin biopsy obtained from the periphery of the lesion may be helpful in differentiating it from other similar appearing skin lesions, and a Warthin–Starry stain can sometimes demonstrate *Borrelia* spirochetes in the skin.¹⁶

Diagnosis

The CDC classifies Lyme disease as *confirmed*, *probable*, or *suspected*. *Confirmed* Lyme disease requires

- A case of erythema migrans with known exposure (having been in a woody, brushy, or grassy area in an endemic county ≤ 30 days prior), or
- A case of erythema migrans without known exposure but with a qualified laboratory assay demonstrating evidence of infection, or
- A case with at least one late manifestation that has laboratory evidence of infection.¹⁵

A *probable* case is any other physician-diagnosed Lyme disease that has laboratory evidence of infection and *suspected* Lyme disease is a case of erythema migrans with no known exposure and no supportive laboratory assay, or a case with laboratory evidence but no available clinical information.



▲ **Figure 13-14.** Centers for Disease Control and Prevention (CDC) recommendations for serological testing for Lyme disease (Centers for Disease Control and Prevention. Two-tiered Testing Decision Tree).

► Differential Diagnosis

- ✓ **Bites from ticks, mosquitoes, bees, and wasps:** Typically the erythema associated with these bites does not exceed 5 cm in diameter.
- ✓ **Erysipelas or cellulitis:** The white blood cell count may be elevated and often the area is tender and there is no central clearing.
- ✓ **Herald patch of pityriasis rosea:** The diameter does not usually exceed 5 cm and there is a ring of scale within the lesion.
- ✓ **Other:** Fixed drug rash, tinea corporis, dermatitis, granuloma annulare, and erythema multiforme.

Management

Treatment depends on the stage of the disease, the age of the patient, and relative contraindications associated with the recommended medications. The Infectious Disease Society of America (IDSA) publishes guidelines for Lyme Disease Management (Tables 13-3 and 13-4).¹⁷

Macrolide antibiotics are not recommended as first-line therapy, first-generation cephalosporins are ineffective, and ceftriaxone, while effective, is not superior to oral agents and has more side effects, so is not recommended unless other agents are contraindicated.¹⁷

Table 13-3. Recommended treatment of early Lyme disease and erythema migrans in adults.

Medication	Dosing	Duration	Notes
Doxycycline	100 mg PO twice a day	14 days (range: 10-21 days)	Relatively contraindicated in pregnant and lactating females
Amoxicillin	500 mg PO three times a day	14 days (range: 14-21 days)	
Cefuroxime axetil	500 mg PO twice a day	14 days (range: 14-21 days)	

Table 13-4. Recommended treatment of early Lyme disease and erythema migrans in children.

Medication	Dosing	Duration
Children ≥8 years		
Doxycycline	4 mg/kg per day in 2 divided doses; maximum 100 mg per dose	14 days (range: 10-21 days)
Children <8 years		
Amoxicillin	50 mg/kg per day in 3 divided doses; maximum 500 mg per dose	14 days (range: 14-21 days)
Cefuroxime axetil	30 mg/kg per day in 2 divided doses; maximum 500 mg per dose	14 days (range: 14-21 days)

Instructions for prevention of Lyme disease are as follows:¹⁵

- When possible avoid areas with long grass and bushes in tick-infested locales.
- Wear light-colored shirts and long pants with socks covering the bottom of the pants.
- Use insect repellents with 20% to 30% DEET.
- Perform thorough full body tick checks once or twice a day.
- Check clothing, gear, and pets for ticks.
- If a tick is found on the body, grasp the tick with tweezers as close to the skin as possible and gently pull the tick's body away from the skin. Clean the area with soap and water.
- The CDC site for Lyme disease has additional information on tick removal and landscaping techniques to control ticks.

Indications for Consultation

The diagnosis and treatment of post-treatment Lyme disease syndrome is controversial. When this diagnosis is considered a rheumatologic or infectious disease, consult should be considered before therapy initiated.¹⁵

Patient Information

- Centers of Disease Control and Prevention Lyme disease page: www.cdc.gov/lyme/
- State of Connecticut Department of Public Health Lyme Disease page: www.ct.gov/caes/lib/caes/documents/publications/.../b1010.pdf
- Mayo clinic: www.mayoclinic.com/health/lyme-disease/DS00116

BED BUGS

Introduction

Although the bed bug, *Cimex lectularius*, has been a known human parasite for thousands of years, developed countries experienced a near 50-year hiatus from this pest, when it was almost eradicated from North America as a result of mass treatments with insecticides such as dichlorodiphenyltrichloroethane (DDT), Chlordane, and hexachlorocyclohexane (Lindane).¹⁸ Bed bugs are back for a number of possible reasons, including increased international travel, immigration, changes in pest control practices, and insecticide resistance. Bed bugs can be found in settings from 4-star hotels to homeless shelters. Anyone is a potential target.

Pathophysiology

Adult bed bugs are brown, oval, wingless somewhat flat insects about the size of an apple seed (Figure 13-15). As



▲ **Figure 13-15.** *Cimex lectularius* (bed bug) (Centers for Disease Control and Prevention. PHIL Collection ID#9822).

they feed, they grow in length from about 5 to 9 mm and change from brown to purple red. Young bugs are smaller and nearly colorless. Bed bugs usually hide during the day and feed at night. They are attracted to heat and carbon dioxide and feed on exposed skin. They then move back to their hiding places, typically mattress and box spring seams (Figure 13-16), bed frames, or bedroom furniture, although they can hide almost anywhere.¹⁹ It is in these hiding places where the wary traveler can find evidence of a bed bug infestation, by the presence of dead bugs, feces, and molted skin casings (Figure 13-16). Bed bugs are resilient; they can survive up to a year or more without a blood meal. Although they have been implicated in



▲ **Figure 13-16.** Bed bugs, feces, and molted skin casings on mattress box spring (Used with permission from Stephen Kells PhD).

the transmission of infectious diseases such as Hepatitis B, evidence for disease transmission is equivocal and their significance as disease vectors has yet to be established.¹⁹

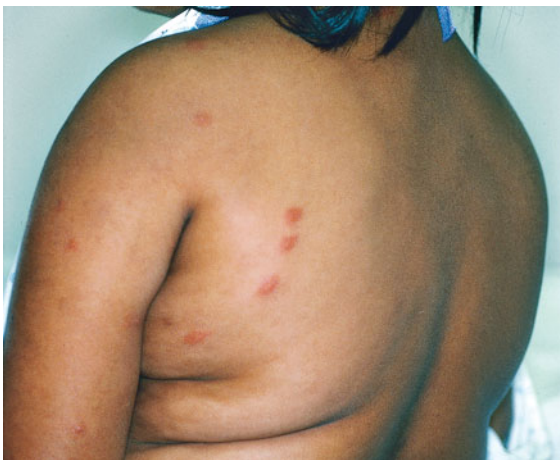Clinical Presentation

History

While anyone can be a victim of bed bug bites, a suggestive history might include living in a known infested environment, recent acquisition of a used mattress or couch, or travel to a potentially infested destination. The pest control company, Terminix compiles an annual list of the Top 15 Most Bed Bug Infested US Cities. In 2012, the top five were Philadelphia, Cincinnati, New York, Chicago and Detroit.²⁰

Physical Examination

Clinical manifestations vary from no reaction to typical appearing insect bites to papular urticaria or bullous reactions. While the bite appearance is not specific, bite distribution is often suggestive of bed bugs. The most commonly involved areas are those that are typically exposed while sleeping such as the scalp, face, neck, and arms (Figure 13-17). The timing between possible exposure and the development of the bites is not always diagnostic. One researcher, using himself as a once-weekly blood meal for bed bugs, noted that the time it took from bug bite to immune response progressed from delayed to immediate over the 7 years he studied his exposure.¹⁹ Occasionally patients present with dermatitis or secondary infection at the bite sites. A few studies have suggested that bed bug bites may cause systemic reactions such as asthma, generalized urticaria, and anaphylaxis.¹⁹



▲ **Figure 13-17.** Bed bugs bites on back in linear distribution.

Laboratory Findings

Lab results are nonspecific, although severe and persistent bed bug infestation has been implicated in the development of iron deficiency anemia.²¹

Diagnosis

The appearance of the insect bite does little to assist in identifying the culprit insect; a mosquito bite looks like a flea bite that looks like a bed bug bite.¹⁹ Bites organized in linear or clustered groups of 3 (breakfast, lunch, and dinner) have been suggested as implicating a flea or bed bug, but this is far from diagnostic.

Differential Diagnosis

- ✓ **Other arthropod bites:** May be indistinguishable from bed bug bites.
- ✓ **Urticaria:** The individual lesions last less than 24 hours.
- ✓ **Delusions of parasitosis:** Can present with similar symptoms, but patients with bed bug infestations often struggle with psychopathology secondary to their infestation, so true infestation should be ruled out.

Management

The patient should be treated symptomatically with oral antihistamines and topical corticosteroids and with topical or oral antibiotics if the bites are infected. Once an infestation is established, bed bugs are extremely difficult to treat. The best advice is to prevent a bed bug infestation before it occurs by being proactive and avoid bringing them home. Suggestions include checking hotel rooms before unpacking, especially bed sheets, linens, and mattress seams, avoiding setting luggage on the floor, and checking the luggage rack for signs of bed bugs.¹⁸ Once at home, clothing and luggage should be carefully examined and if infestation is suspected on these items, bed bugs can be destroyed by freezing (minimum of 23°F (−5°C)) maintained at least 5 days (2 weeks if uncertain of temperature) or heating (minimum target is 2-hour core exposure at 120°F (49°C)).¹⁸

Consultation

A dermatologist might be consulted if the diagnosis is in question. Occasionally a mental health care professional might be needed to help with the psychosocial aspects. If a patient's home is truly infested with bed bugs, the most important consultation will be that of a pest management professional.

Patient Information

- JAMA Patient Page: Bed bugs: www.jama.ama-assn.org/content/301/13/1398.full.pdf
- United States Environmental Protection Agency: www.epa.gov/bedbug
- University of Minnesota Department of Entomology: www.bedbugs.umn.edu

REFERENCES

1. Chosidow O. Clinical practices. Scabies. *N Engl J Med*. 2006;354(16):1718–1727. PMID: 16625010.
2. Chosidow O. Seminar: scabies and pediculosis. *Lancet*. 2000;355(6206):819–826. PMID: 10711939.
3. Walter B, Heukelback J, Fengler G, et al. Comparison of dermoscopy, skin scraping, and the adhesive tape test for the diagnosis of scabies in a resource-poor setting. *Arch Dermatol*. 2011;147(4):468–473. PMID: 2148297.
4. Strong M, Johnstone P. *Interventions for Treating Scabies (Review)*. 2010 The Cochrane Collaboration. Chichester, UK: John Wiley & Sons, Ltd: 1–70.
5. Currie B, McCarthy J. Permethrin and ivermectin for scabies. *N Eng J Med*. 2010;362(8):717–725. PMID: 20181973.
6. Burkhart CN, Burkhart CG. Head lice scientific assessment of the nit sheath with clinical ramifications and therapeutic options. *J Am Acad Dermatol*. 2005;53(1):129–33. PMID: 15965432.
7. Ko CJ, Elston DM. Pediculosis. *J Am Acad Dermatol*. 2004;50(1):1–12. PMID: 14699358.
8. Frankowski B, Bocchini J. Clinical report—head lice. *Pediatrics*. 2010;126(2):392–403. PMID: 20660553.
9. Jahnke C, Bauer E, Hengge U, Feldmeier H. Accuracy of diagnosis of pediculosis capitis: visual inspection vs. wet combing. *Arch Dermatol*. 2009;145(3):309–313. PMID: 19289764.
10. Parasites—Lice. Centers for Disease Control. <http://www.cdc.gov/parasites/lice/>
11. Dourmishev AL, Dourmishev LA, Schwartz RA. Ivermectin: pharmacology and application in dermatology. *Int J Dermat*. 2005;44(12):981–988. PMID: 16409259.
12. Stough D, Shellabarger S, Quiring J, Gabrielsen A. Efficacy and safety of spinosad and permethrin crème rinses for pediculosis capitis (head lice). *Pediatrics*. 2009;124(4):e389–e394. PMID: 19706558.
13. Bacon RM, Kuleler KJ, Mead PS. Surveillance for Lyme disease—United States, 1992–2006. *MMWR Surveill Summ*. 2008;57(10):1–9. PMID: 18830214.
14. Bhatte C, Schwartz RA. Lyme disease: part 1. Advances and perspectives. *J Am Acad Dermatol*. 2011;64(4):619–639. PMID: 21414493.
15. Lyme disease. Centers for Disease Control and Prevention. www.cdc.gov/lyme/
16. Steen CJ, Carbonaro PA, Schwartz RA. Arthropods in dermatology. *J Am Acad Dermatol*. 2004;50(6):819–842. PMID: 15153881.
17. Wormser GP, Dattwyler RJ, Shapiro Ed, et al. The clinical assessment, treatment, and prevention of Lyme disease, Human granulocytic, anaplasmosis and babesiosis: clinical practice guidelines by the Infectious Diseases Society of America. *Clinic Infect Dis*. 2006;43(9):1089–134. PMID: 17029130.
18. Kells S. University of Minnesota Department of Entomology. www.bedbugs.umn.edu. Accessed January 20, 2012.
19. Goddard J, deShazo R. Bedbugs (*Cimex lectularius*) and clinical consequences of their bites. *JAMA*. 2009;301(13):1358–1366. PMID: 19336711.
20. Terminix top 15 rankings show bedbug population growing across the U.S. Memphis, Tenn. June 11, 2012. <http://www.terminix.com/Media/PressReleases.aspx>. Accessed January 2, 2013.
21. Pritchard MJ, Hwang SW. Severe anemia from bedbugs. *CMAJ*. 2009;181(5):287–288. PMID: 19720710.

Urticaria and Drug Rashes

Caleb Creswell

14

Introduction to Chapter / 117
Urticaria / 117

Cutaneous Adverse Drug Reactions / 121
References / 127

INTRODUCTION TO CHAPTER

Urticaria and cutaneous adverse drug reactions are among the most common skin problems seen in the clinic and hospital. They can be associated with urgent medical conditions such as laryngeal edema and toxic epidermal necrolysis. It is important for a clinician to identify the underlying causes for these disorders.

URTICARIA

Introduction

Urticaria (hives) is characterized by the rapid onset of lesions called wheals that consist of a central mid-dermal swelling with or without surrounding erythema, with associated pruritus, lasting anywhere from 1 to 24 hours. Associated angioedema can sometimes be seen, characterized by swelling of the deeper dermis and subcutaneous tissue lasting up to 72 hours.¹ The lifetime prevalence of urticaria is estimated to be approximately 20% and it can present in patients ranging in age from infants to the elderly. Urticaria can be divided into acute and chronic forms and urticaria elicited by physical factors. Acute urticaria is defined as urticaria of less than 6 weeks duration, whereas chronic urticaria lasts more than 6 weeks. Only 5% of patients with urticaria will be symptomatic for more than 4 weeks.

Pathophysiology

The underlying event leading to urticaria is mast cell degranulation, with release of histamine and other pro-inflammatory

molecules. There are numerous stimuli that can lead to mast cell activation through various pathways. The most common cause of acute urticaria is viral infections, particularly of the upper respiratory tract.² Other common causes of acute urticaria are listed in Table 14-1. Food-induced type I hypersensitivity reactions are a rare cause of acute urticaria in adults, but are a more common cause in children.³

Chronic urticaria can be associated with rheumatologic disorders, chronic infections including Hepatitis B and C, sinus infections and *Helicobacter pylori*, as well as parasitic infections (more common in developing countries).¹ In the majority of patients with chronic urticaria, an underlying disease will not be found. Approximately 35% to 40% of cases of chronic urticaria are caused by autoantibodies directed against the IgE receptor of mast cells.⁴

Angioedema occurs with wheals in approximately 40% of cases of urticaria in adults and possibly more frequently in food-induced urticaria.³ Angioedema without urticaria is often related to drug therapy with angiotensin-converting enzyme (ACE) inhibitors, but may be due to hereditary or acquired complement deficiencies.

The physical urticarias are caused by a physical stimulus leading to mast cell degranulation (Table 14-2).

Clinical Presentation

► History

Patients with urticaria usually present with a chief complaint of a sudden onset of itchy spots that they may describe as hives, welts, or welps. A thorough history is important in establishing the diagnosis of urticaria, because the lesions

Table 14-1. Causes of acute urticaria.

- **Infections:** Viral respiratory, especially rhinovirus and rotavirus¹ (cause in 80% of children), *Helicobacter pylori*, mycoplasma, hepatitis, mononucleosis, and parasitic helminths
- **Drugs and intravenous products:** Beta-lactams antibiotics, nonsteroidal anti-inflammatory drugs (NSAIDs), aspirin, ACE inhibitors, diuretics, opiates, contrast media, and blood transfusion
- **Foods:** In adults shellfish, fresh water fish, berries, nuts, peanuts, pork, chocolate, tomatoes, spices, food additives, and alcohol. Additionally in children, milk and other dairy products, eggs, wheat, and citrus
- **Inhalants:** Pollens, molds, dust mites, and animal dander
- **Emotional stress**
- **Systemic diseases:** Lupus erythematosus, Still's disease, thyroid disease, cryoglobulinemia, mastocytosis, and carcinomas

may have disappeared by the time of the office visit. A detailed history is the most effective way to determine an underlying cause of urticaria.⁵ It is important to inquire about the location, associated pruritus, and especially the duration of the lesions. Any lesions that last for longer than 24 hours should raise suspicion of an alternative diagnosis, such as urticarial vasculitis.

To determine the underlying cause of urticaria, one should inquire about associated symptoms, including those of upper respiratory infection, sinus infection, autoimmune disease, and *H. pylori* infection. Any symptoms that point to an anaphylaxis-type reaction or to swelling of the

throat are important as these are rare, but life-threatening complications. A thorough review of recent medications and foods should be done as these can be triggers for urticaria that usually appears 1 to 2 hours after ingestion. Finally, it is important to ask about any physical stimuli that may be causing the urticaria (Table 14-2).

► Physical Examination

Urticaria presents with

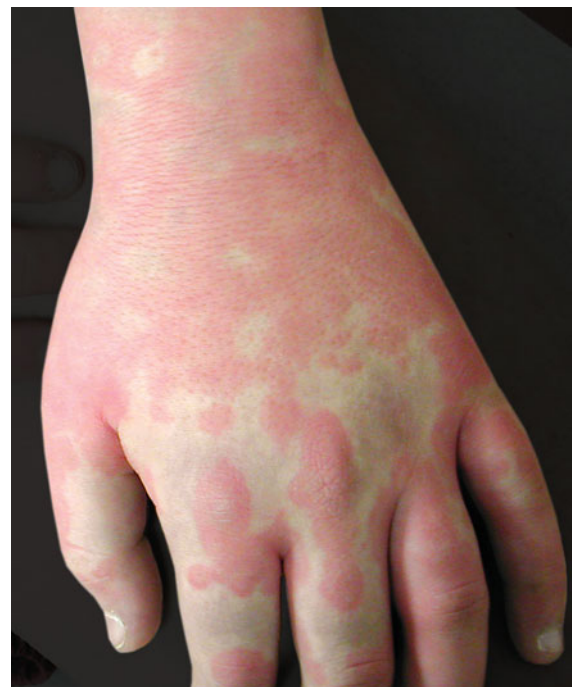- Wheals, which are white to pink, pruritic, edematous papules or plaques that may be round (Figure 14-1), annular (Figure 14-2), or arcuate. The surface of the lesion is smooth because the pathology is in the dermis, not in the epidermis.
- The lesions are usually symmetrically distributed and may be on any location of the body.
- Individual wheals have a rapid onset and last less than 24 hours, but the entire episode of urticaria may last much longer.
- The skin returns to its normal appearance after the wheals have resolved.

Angioedema presents with

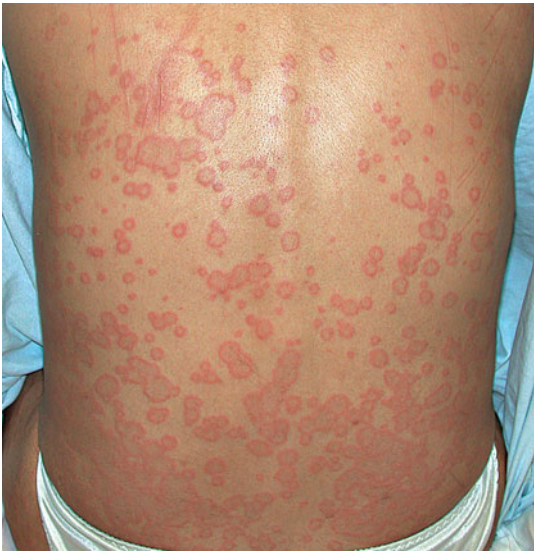- A sudden onset of diffuse swelling of the lower dermis and subcutaneous tissues, typically involving the lips, periorbital area (Figure 14-3), the hands, and the feet.

Table 14-2. The physical urticarias.

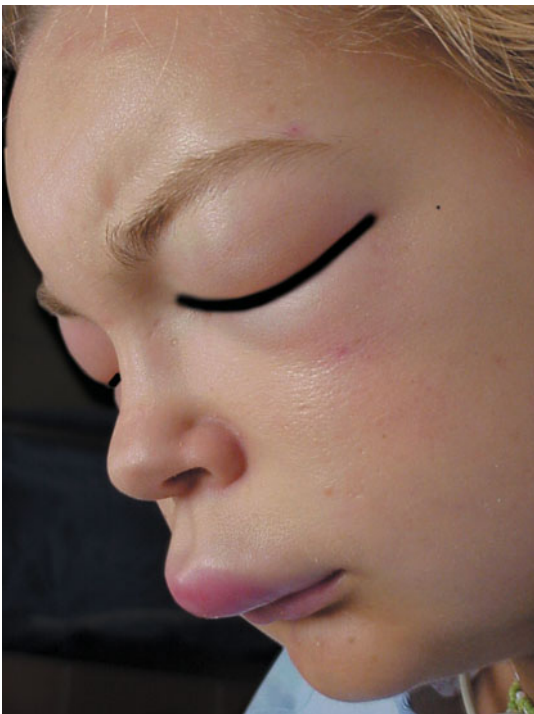Type of Physical Urticaria	Inciting Stimulus
Dermatographism	Shearing forces on the skin. May present as urticarial lesions at the site of scratching
Cold urticaria	Sudden exposure to cold. Rare association with cryoglobulinemia and malignancy
Delayed pressure urticaria	Urticaria appears 4-6 h after prolonged pressure. Most common on the palms and soles
Heat urticaria	Direct contact with a warm object
Cholinergic urticaria	Rise in the core body temperature secondary to exercise, hot water emersion, or stress
Contact urticaria	Contact with chemicals found in foods, plants, and medicines
Solar urticaria	Ultraviolet or visible light
Aquagenic urticaria	Very rare, caused by contact with water of any temperature



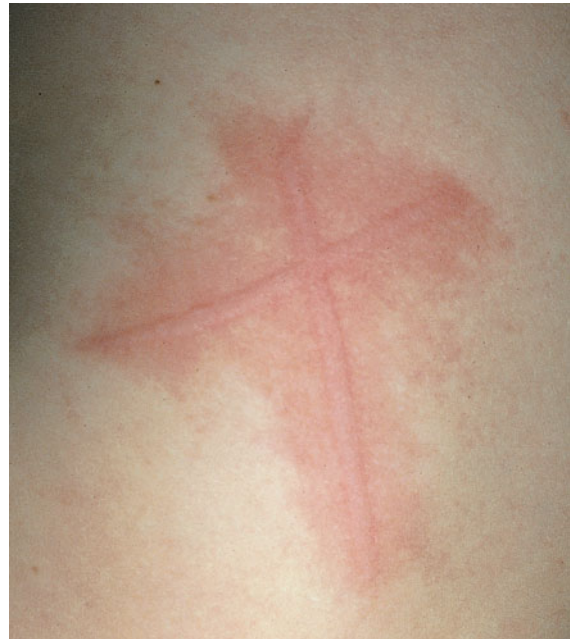▲ **Figure 14-1.** Urticaria on hand. Uniform pink wheals with smooth surface.



▲ **Figure 14-2.** Urticaria on back. Multiple annular wheals with central clearing.



▲ **Figure 14-3.** Angioedema. Swelling of lips and periorbital area (Reproduced with permission from Usatine RP, Smith MA, Chumley H, Mayeaux, Jr. E, Tysinger J, eds. *The Color Atlas of Family Medicine*. New York: McGraw-Hill; 2009. Figure 143-4).



▲ **Figure 14-4.** Dermatographism. Linear wheals appearing 5 minutes after skin was stroked with wooden end of a cotton applicator.

- The tongue, larynx, and the respiratory and gastrointestinal tracts may also be affected.
- The swelling may persist for up to 3 days. The involved skin returns to its normal appearance after the swelling has resolved.

Angioedema without wheals often has differing underlying causes; therefore, it is important to determine if the primary lesions are wheals, angioedema, or both.

Hoarseness can be a sign of laryngeal edema that can be a life-threatening complication due to airway compromise. Dyspnea, wheezing, abdominal pain, dizziness, and hypotension are clues to an anaphylaxis-like reaction.

All patients with suspected urticaria should be evaluated for dermatographism (Figure 14-4) by scratching the skin with a shearing force (the wooden end of a cotton-tip applicator works well) for approximately 10 seconds and examining for the presence of a wheal in 3 to 5 minutes. Tests for other types of physical urticarias listed in Table 14-2 are best left to specialists.

► Laboratory Finding

Unless indicated by history, laboratory examination for acute urticaria is usually not helpful in determining the cause of the outbreak. There is an association between Hashimoto's thyroiditis and chronic urticaria, so it is prudent to check thyroid function studies and thyroid

antibodies in such patients. When indicated by history, tests for autoimmune disease and chronic infections should be performed in patients with chronic urticaria. Several tests to check for autoantibodies against mast cell IgE receptor are available; however, the results can be difficult to interpret. A complement (C4) level can screen for acquired or hereditary complement deficiency in patients with angioedema without wheals who are not on angiotensin-converting enzyme (ACE) inhibitors or nonsteroidal anti-inflammatory drugs (NSAIDs).

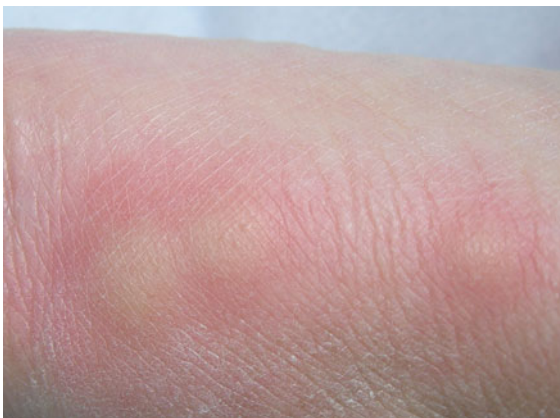Diagnosis

The key diagnostic findings of urticaria are sudden onset of pruritic wheals with individual lesions lasting less than 24 hours.

The key diagnostic findings of angioedema are sudden onset of swelling of the mucous membranes or the hands and/or feet. The swelling lasts less than 72 hours.

Differential Diagnosis

- ✓ **Urticarial vasculitis:** Presents with wheal-like lesions that last for more than 24 hours and may be accompanied by fever, malaise, and arthritis. These findings should prompt a skin biopsy or specialty referral.
- ✓ **Viral exanthems:** May present with urticarial lesions, which can fade quickly, but these lesions typically last for more than 24 hours.
- ✓ **Insect bites:** The papular urticarial lesions of insect bites usually have a blanched center and may have a central crust or puncta at the site of the bite (Figure 14-5). The lesions usually last longer than 24 hours.
- ✓ **Still's disease:** Associated with juvenile rheumatoid arthritis; may present transient urticarial lesions that



▲ **Figure 14-5.** Mosquito bites presenting as papular urticaria. Group of 3 bites with central blanched center.

last less than 24 hours. Symptoms of arthritis as well as an exceptionally high ferritin level can help distinguish this rare disease.

- ✓ **Other:** Drug reactions such as fixed drug eruption, Stevens–Johnson syndrome, drug rash with eosinophilia and systemic symptoms (DRESS).

Management

If an inciting factor can be identified for urticaria, it should be treated or removed. The nonsedating H1 antihistamines are the first line of therapy for urticaria (Table 14-3). Newer agents such as loratadine, cetirizine, fexofenadine, levocetirizine, and desloratadine are all effective. Often these medications need to be taken in higher doses than those used for allergic rhinitis and multiple experts recommend gradually increasing the dose to up to 4 times the allergic rhinitis dose.^{1,2,6,7} Addition of an H2-blocker, leukotriene antagonist, or a sedating H1-blocker such as hydroxyzine at night can sometimes be beneficial (Table 14-1). Because only 5% of patients with urticaria will be symptomatic for more than 4 weeks, an effective antihistamine regimen should be continued for 4 to 6 weeks after controlling symptoms and then gradually tapered off. However, over 50% of patients with the subset category of chronic urticaria will be symptomatic for over a year, so these patients require long-term treatment.⁸ Although prednisone is often effective in controlling urticaria, it is not recommended as a first-line treatment due to the frequency of rebound urticaria and potential serious side effects.

Patients with angioedema without wheals who are on ACE inhibitors should be switched to an alternative class of medication even if they have been on the ACE inhibitor for many years. The rate of angioedema with angiotensin receptor blockers in patients who have angioedema from ACE inhibitors is very low, so these drugs represent an acceptable alternative therapy.

Signs or symptoms of anaphylaxis or throat angioedema require emergent management with a combination of intramuscular epinephrine, securing of an airway, vaso-pressors, and intravenous corticosteroids.

Indications for Consultation

- Patients whose urticaria cannot be managed by an antihistamine regimen should be referred to a specialist for management that may include medications such as cyclosporine, intravenous immunoglobulin (IVIG) psoralen plus ultraviolet light A (PUVA), and omalizumab (an anti-IgE antibody).
- Atypical lesions or a history of lesions lasting for significantly longer than 24 hours may require a skin biopsy for definitive diagnosis.

Table 14-3. Oral antihistamines for treatment of urticaria.

Medications	Brand Name Examples	Nonprescription	Adult Dosing	Notes
H1 nonsedating antihistamines				
Cetirizine	Zyrtec	Yes	10 mg daily	The dosage for these antihistamines may be gradually increased to up to four times the standard dose if needed
Desloratadine	Clarinex	No	5 mg daily	
Fexofenadine	Allegra	Yes	180 mg daily	
Levocetirizine	Xyzal	No	5 mg daily	
Loratadine	Claritin	Yes	10 mg daily	
H1 sedating antihistamines				
Chlorpheniramine	Chlor-Trimeton	No	4 mg q4-6h	These antihistamines may cause drowsiness; patients should be warned of this possibility and cautioned against driving a car or operating dangerous machinery while taking these medications
Cyproheptadine	Periactin	No	4 mg tid	
Diphenhydramine	Benadryl	Yes	25-50 mg q4-6 h	
Hydroxyzine	Atarax, Vistaril	No	25 mg q4-6h	
H2 antihistamines				
Cimetidine	Tagamet	Yes	400 mg bid	Increases blood levels of several medications, eg, warfarin, phenytoin
Ranitidine	Zantac	Yes	150 mg bid	
Leukotriene receptor antagonists				
Montelukast	Singulair	No	20 mg bid	Take on empty stomach
Zafirlukast	Accolate	No	10 mg daily	

- Angioedema without wheals in patients who are not on ACE inhibitors management often requires immunosuppression, plasmapheresis, and anabolic steroids such as stanozolol. Similarly patients with angioedema without wheals who cannot be managed by switching them from an ACE inhibitor should be referred to a specialist for management.
- Testing for physical urticarias can be difficult to interpret; therefore, a history suggestive of a physical urticaria should lead to referral to a specialist such as an allergist or dermatologist.
- Patients who have urticaria with anaphylaxis symptoms are best managed in an emergent care setting with an ability to secure an artificial airway.

Patient Information

- American Academy of Dermatology: www.aad.org/skin-conditions/dermatology-a-to-z/hives
- PubMed Health: www.ncbi.nlm.nih.gov/pubmedhealth/PMH0001848/
- American College of Allergy, Asthma and Immunology: www.acaai.org/allergist/allergies/Types/skin-allergies/hives/Pages/default.aspx

- National Institute of Allergy and Infectious Diseases: www.niaid.nih.gov/topics/allergicDiseases/Pages/Anaphylaxis.aspx

CUTANEOUS ADVERSE DRUG REACTIONS

Introduction

Adverse drug reactions (ADRs) are quite common, especially in hospitalized patients, and cutaneous adverse drug reactions (CADRs) are the most frequently occurring ADRs.^{9,10} CADRs affect 1% to 3% of hospitalized patients.¹¹ Although all patients are at risk for CADRs, factors such as age, female gender, and concomitant viral infections, especially human immunodeficiency virus (HIV) and Epstein Barr-virus (EBV), can increase the risk. Certain drugs cause CADRs more commonly than others; the most frequent offenders are antibiotics, anticonvulsants, and NSAIDs.¹² When confronted with any rash, a CADR should always be in the differential, as virtually every reaction pattern seen in the skin can be drug induced. Approximately 90% of CADRs are morbilliform (maculopapular) eruptions, with an additional 5% being urticarial.^{12,13} Additional CADRs that will be covered in this chapter include drug rash with

Table 14-4. Immunologically mediated adverse cutaneous drug reactions.*

Type of Reaction	Pathogenesis	Examples of Causative Drug	Clinical Patterns
Type I	IgE-mediated; immediate-type immunologic reactions	Penicillin, other antibiotics	Urticaria/angioedema of skin/mucosa, edema of other organs, and anaphylactic shock
Type II	Drug + cytotoxic antibodies cause lysis of cells such as platelets or leukocytes	Penicillin, sulfonamides, quinidine, and isoniazid	Petechiae due to thrombocytopenic purpura, drug-induced pemphigus
Type III	IgG or IgM antibodies formed to drug; immune complexes deposited in small vessels activate complement and recruitment of granulocytes	Immunoglobulins, antibiotics, rituximab, and infliximab	Vasculitis, urticaria, and serum sickness
Type IV	Cell-mediated immune reaction; sensitized lymphocytes react with drug, liberating cytokines, which trigger cutaneous inflammatory response contact sensitivity	Sulfamethoxazole, anticonvulsants, allopurinol	Morbilloform exanthematous reactions, fixed drug eruption, lichenoid eruptions, Stevens-Johnson syndrome, and toxic epidermal necrolysis

*Based on the Gell and Coombs classification of immune reactions (Reproduced with permission from Suurmond D, ed. *Fitzpatrick's Color Atlas & Synopsis of Clinical Dermatology*. 6th ed. New York: McGraw-Hill; 2009. Table 22-1).

eosinophilia and systemic symptoms (DRESS), fixed drug eruption, and acute generalized exanthematous pustulosis (AGEP). Especially with the rarer CADRs, certain drugs are more commonly associated with certain reaction patterns. **The CADRs of the top 60 most prescribed drugs in the United States in Table E14-1.1 can be found at www.LangeClinicalDermatology.com.** Litt's Drug Eruption and Reactions Manual is a good reference for more detailed information.¹⁴

Pathophysiology

Many CADRs are immune mediated. The Gell and Coombs classification divides these into four types (Table 14-4). Drug-induced urticaria, angioedema, and anaphylaxis are caused by a type I reaction involving performed IgE antibodies recognizing drug–protein complexes leading to degranulation of mast cells with release of histamine and other proinflammatory cytokines. This process can occur within a matter of minutes, accounting for the quick presentation of type I CADRs. These types of reactions usually require previous exposure to the offending drug to allow for generation of the specific antibodies; however, environmental agents can occasionally lead to development of cross-reactive antibodies, causing type I reactions upon initial exposure to the drug.¹⁵

Morbilloform drug eruptions, fixed drug eruption, DRESS, and AGEP are all caused by a type IV reaction. In type IV reactions, T cells recognize the drug–protein complex and stimulate an immune response. Concomitant viral infection may increase the likelihood of this T-cell activation taking place. This process takes at least 5 to 7 days, accounting for the delay in these types of eruptions upon exposure

to a medication. Upon subsequent stimulation, the rash may occur much more quickly. There are several types of nonimmune-mediated drug eruptions, often caused by a specific drug or drug-class. Coomb's type II and III reactions are less common causes of CADRs (Table 14-4).

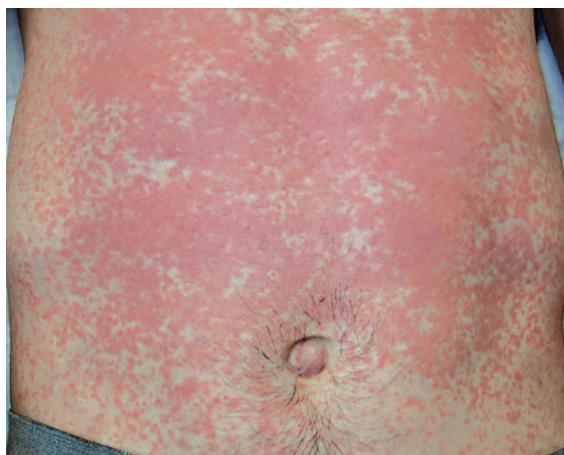Clinical Presentation

History

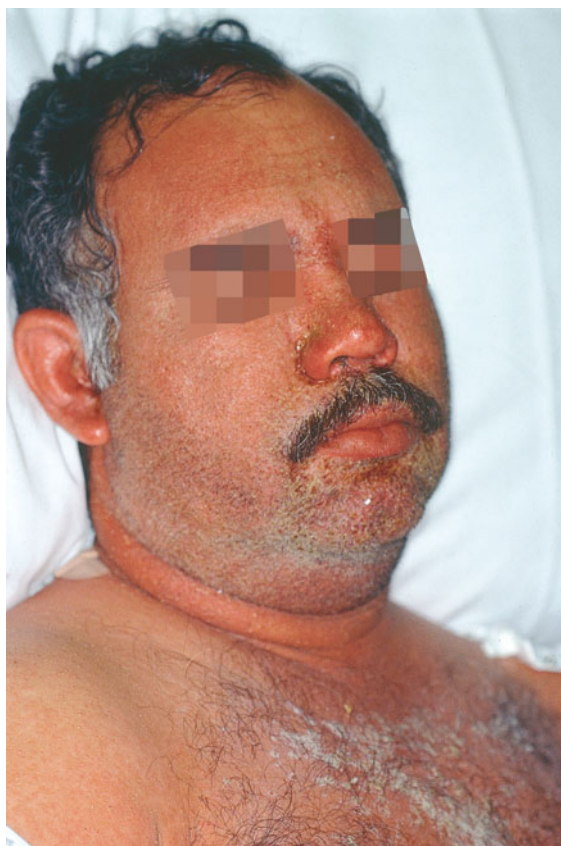The key to making a diagnosis of a CADR is taking a good medication history. Constructing a table listing the date when each drug was started and stopped can help to establish which drug is the most likely culprit. This is especially helpful for patients on multiple medications. A history consistent with mononucleosis should raise suspicion for a CADR, especially from amoxicillin. Similarly, a history of HIV infection should raise suspicion for a CADR, especially from sulfonamide antibiotics.

History and Physical Examination of Selected Adverse Drug Reactions

- **Morbilloform drug eruption:** Morbilloform drug eruptions present insidiously approximately 5 to 7 days after starting the offending agent. The rash is characterized by small pink, pruritic, macules, and papules (Figure 14-6) that start on the trunk and pressure-bearing areas, spreading to other areas of the body, and sometimes becoming confluent.
- **Urticaria/angioedema/anaphylaxis:** Urticaria/angioedema reactions present with an acute onset of pruritic and less commonly, painful lesions within minutes to



▲ **Figure 14-6.** Morbilliform drug eruption due to thiazide diuretic. Discrete and confluent pink macules and papules.



▲ **Figure 14-7.** Drug rash with eosinophilia and systemic symptoms (DRESS) due to carbamazepine. Facial edema with erythema and crusting; pustules on chest.

hours after ingestion of the medication. Urticaria presents with wheals (dermal swellings with or without associated erythema), and the individual wheals resolve within 24 hours (Figures 14-1 and 14-2). Angioedema presents as deeper, sometimes painful swelling, of the mucous membranes, hands and feet (Figure 14-3). The swelling resolves within 72 hours. Hoarseness can be a sign of laryngeal edema, which can be a life-threatening complication due to airway compromise. Dyspnea, wheezing, abdominal pain, dizziness, and hypotension are clues to an anaphylaxis-like reaction.

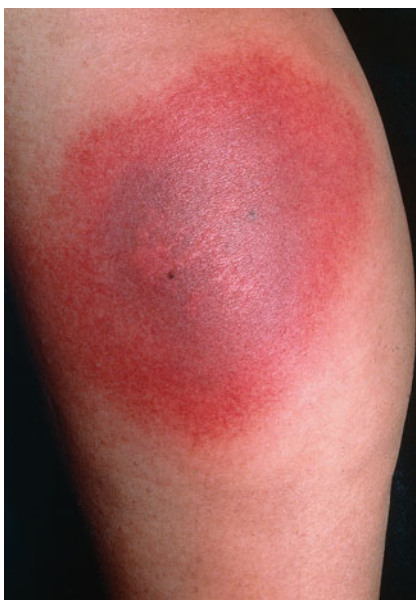- **Drug rash with eosinophilia and systemic symptoms (DRESS)** also known as drug hypersensitivity syndrome: Patients present with malaise and fever usually 2 to 6 weeks after the initiation of the drug, most commonly carbamazepine and allopurinol.¹⁶ The initial rash associated with DRESS is often similar to a morbilliform drug eruption. Subsequent developments of hemorrhagic and bullous lesions are clues to DRESS, as are central facial edema (Figure 14-7) and conjunctivitis. Fever is almost universally present and lymphadenopathy may be present. Eosinophilia is usually present and multiple organ systems may be affected.
- **Acute generalized exanthematous pustulosis (AGEP):** AGEP presents with 1 to 3 mm superficial pustules on an erythematous base.¹⁶ The rash begins in the intertriginous areas, but rapidly spreads and may lead to total body involvement. Fever is often present.
- **Fixed drug eruption:** Fixed drug eruptions present as a solitary dusky erythematous plaque that can at times be edematous and even bullous (Figure 14-8). The lesions develop within hours of ingestion of the medication and usually recur at the same sites. Common sites

include the lips, genitals, and extremities. Occasionally multiple lesions may be present. Typically there is residual hyperpigmentation after the lesion regresses.

- Less common CADR with moderate to high morbidity are listed in Table 14-5.
- Less common CADR with low morbidity are listed in Table 14-6.

▶ Laboratory Findings

For classic cases of morbilliform drug eruption, urticaria/angioedema, and fixed drug eruption, no laboratory workup or biopsy is required. If the diagnosis of fixed drug eruption is in question, the histologic findings of a skin biopsy can be confirmatory. Patients with DRESS may demonstrate a peripheral eosinophilia that can be a clue to the diagnosis. DRESS can affect multiple organs, therefore liver function tests and creatinine should be followed. Imaging may be required to detect rare involvement of the pulmonary or CNS systems. Some patients with DRESS develop



▲ **Figure 14-8.** Fixed drug eruption. Erythematous plaque with dusky grey center.

an autoimmune thyroiditis within several months of the appearance of the rash, therefore following thyroid function studies is prudent. No laboratory workup is required for patients with AGEF; however, peripheral leukocytosis is often noted. The histology of AGEF is characteristic and skin biopsies are frequently performed to confirm the diagnosis.

Diagnosis

Because almost any rash can be caused by a drug (Tables 14-5 and 14-6), the differential diagnosis for CADR is quite broad and a high index of suspicion must be maintained. Having a detailed drug history is very important. The first step is to define the type of CADR that the patient has. The patient's medications should then be carefully examined to see if any of the medications (including over the counter medications and herbal supplements) are known to cause this type of reaction. The timing between the start of the medication and the appearance of the rash should also fit. Further factors that support a diagnosis of a CADR are disappearance of the rash upon cessation of the medication and reappearance of the rash upon re-challenge.¹⁰

Table 14-5. Cutaneous adverse drug reactions with moderate to high morbidity.

Cutaneous Reactions	History and Clinical Findings	Examples of Drug
Anaphylaxis and anaphylactoid	Shortness of breath, hypotension	Antibiotics, antibodies, and radiocontrast
Serum sickness	Fever, urticaria, arthralgia 5-21 days after exposure	Antibodies, cefaclor, bupropion
Vasculitis	Palpable purpura	Propylthiouracil, hydralazine, minocycline, and levamisole
Anticoagulant-induced skin necrosis	Necrotic areas of skin, (Figure 14-9) most common in areas with excess adipose	Coumadin, most common in women, occurs 3-5 days after initiation
Sweet's syndrome	Edematous painful plaques most common on face and upper extremities (Figure 14-10)	Granulocyte-macrophage colony stimulating factors, all trans-retinoic acid, trimethoprim-sulfamethoxazole, and oral contraceptives
Stevens-Johnson/toxic epidermal necrolysis	Desquamative blistering with mucosal involvement	Anticonvulsants, sulfonamides, and allopurinol
Bullous pemphigoid	Firm tense pruritic bullae	Furosemide, nalidixic acid, captopril, penicillamine, and penicillin
Pemphigus vulgaris	Eroded flaccid bullae with extensive mucous membrane involvement	Captopril, penicillamine, piroxicam, and rifampin
Systemic lupus erythematosus	Malar rash, photosensitivity, joint pains, and systemic symptoms	Hydralazine, isoniazid, penicillamine, and procainamide
Scleroderma	Firm, immobile ivory colored plaques	Bleomycin, docetaxel, and gemcitabine
Pseudolymphoma	Exanthem or tumor with histology resembling cutaneous lymphoma	Anticovulsants, antidepressants, and allopurinol
Porphyria cutanea tarda	Noninflammatory bullae on sun-exposed skin	Naproxen, furosemide, tetracyclines, and dialysis
Exfoliative erythroderma	Erythroderma with desquamation (Figure 14-11)	Sulfonamides, antimalarials, phenytoin, and penicillin

Table 14-6. Cutaneous adverse drug reactions with low morbidity.

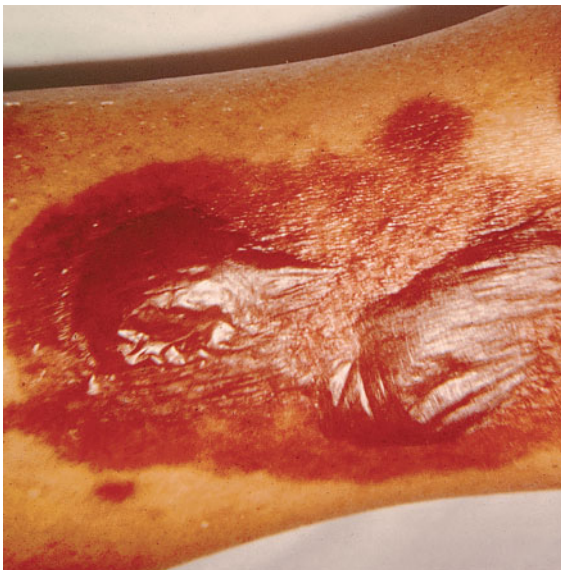Cutaneous Reaction	History and Clinical Findings	Examples of Drugs
Acneiform	Painful erythematous papules and pustules	Anabolic steroids, glucocorticoids, lithium, halogens, oral contraceptives, isoniazid, and epidermal growth factor receptor inhibitors
Alopecia	Hair loss	Beta-blockers, coumadin, oral contraceptives, retinoids, and chemotherapy
Hypertrichosis	Excess hair in nonandrogen-dependent areas	Cyclosporin, minoxidil, and corticosteroids
Hyperpigmentation	Increased pigmentation (Figure 14-12)	Amiodarone, minocycline, clofazimine, zidovudine, antimalarials, and bleomycin
Pruritus	Pruritus without rash	Chloroquine, hydroxyethyl starch (HES) volume expander
Lichenoid eruption	Resemble lichen planus, may be photodistributed	Beta-blockers, hydrochlorothiazide, ACE inhibitors, and gold
Erythema nodosum	Tender nodules most common in pretibial area	Antibiotics, oral contraceptives, and granulocyte-macrophage colony stimulating factors
Phototoxic reaction	Erythema in sun-exposed areas. Occur in everyone with great enough UV exposure	Tetracyclines, psoralens, amiodarone, fluoroquinolones, and hydrochlorothiazide
Photoallergic reaction	Pruritic, eczematous reaction in sun-exposed areas	Amiodarone, piroxicam, fluoroquinolones, and sulfonamides.
Subacute cutaneous lupus erythematosus	Photodistributed polycyclic or psoriasiform plaques	Hydrochlorothiazide, ACE inhibitors, griseofulvin, and statins

► Differential Diagnosis

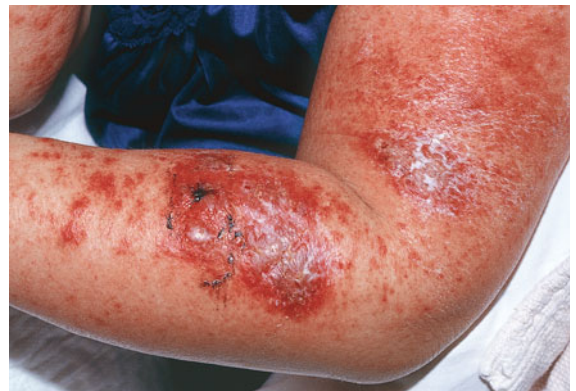- ✓ **Viral exanthems:** Morbilliform drug eruptions can be very similar clinically to viral exanthems. This can be complicated by the fact that many patients with viral

infections may have received antibiotics and the fact that concomitant viral infection can increase the change of a CADR. Pruritus and the presence of eosinophils on biopsy may be more suggestive of a CADR. It is very important to make sure that a patient with a morbilliform drug eruption does not have DRESS. Fever, malaise, hemorrhagic lesions, and facial edema should raise suspicion of DRESS and prompt laboratory studies as noted above.

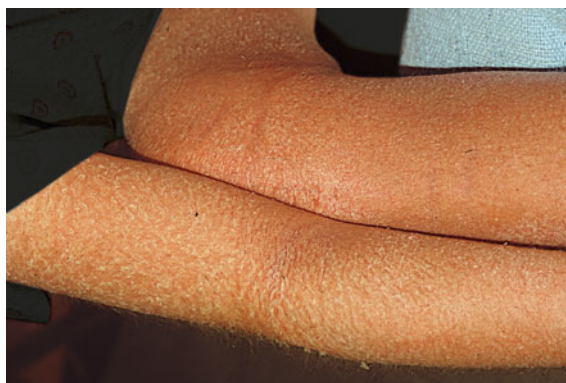- ✓ **Urticaria and angioedema from other causes:** Urticaria can have precipitating factors (eg, infections)



▲ **Figure 14-9.** Coumadin necrosis. Purpura with hemorrhagic bullae.



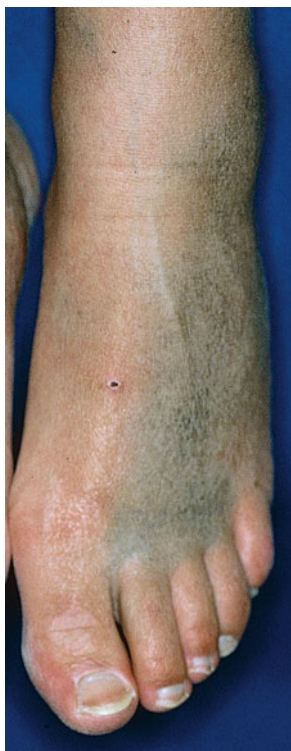▲ **Figure 14-10.** Sweet's syndrome. Edematous red papules and plaques.



▲ **Figure 14-11.** Exfoliative erythroderma due to sulfonamide antibiotic. Erythema with desquamation of skin.

other than medications that should be ruled out before diagnosing a CADR.

- ✓ **Postinflammatory hyperpigmentation:** Fixed drug eruption has a characteristic appearance, however in its rare multifocal form it can be confused



▲ **Figure 14-12.** Hyperpigmentation from use of minocycline. Blue grey patches on foot.

hyperpigmentation disorders. Resolution with hyperpigmentation and re-appearance of lesions in the exact same area suggest a fixed drug eruption.

- ✓ **Pustular psoriasis:** AGEP can look clinically and histologically identical to pustular psoriasis. A history of abrupt onset within several days after starting an antibiotic or other likely offending medication is the key to differentiating AGEP from pustular psoriasis.

Management

The most important step in management of CADRs is identification of the offending drug and abrupt cessation of the drug if possible. This can sometimes be difficult in patients on multiple drugs. Drugs that are most likely to cause an CADR and those where the timing fits best (ie, drugs initiated shortly before the CADR) should be stopped first. Whenever possible an attempt should be made to switch the patient to a medication in a different class or to discontinue any nonessential medications. If there are no suitable alternatives for an essential medication a mild morbilliform eruption could be treated symptomatically.

- Morbilliform drug eruptions and fixed drug eruptions do not require systemic treatment. Mid-potency topical corticosteroids and oral antihistamines (Table 14-3) can be used if there is significant pruritus.
- Urticaria and angioedema usually respond well to oral nonседating H1-blockers (Table 14-3). Often up to 4 times the dose used for allergic rhinitis is required.^{1,7}
- Signs or symptoms of anaphylaxis or throat angioedema require emergent management with a combination of intramuscular epinephrine, securing of an airway, vasopressors, and intravenous corticosteroids.¹⁷
- DRESS requires close laboratory monitoring to detect end organ damage, especially liver and kidney damage.¹⁸ Most sources recommend treatment of DRESS with prednisone at a dose of 1 to 2 mg/kg/day PO for severe cases. This dose should be tapered down as liver function studies and creatinine normalize, but often a low dose of oral corticosteroids is required for months.
- Supportive care is usually all that is needed for AGEP, however in severe cases systemic corticosteroids may be indicated.

Indications for Consultation

CADRs with anaphylaxis symptoms are best managed in an emergent care setting with an ability to secure an artificial airway. AGEP often requires inpatient supportive care and expert consultation is recommended. Any suspected case of DRESS should prompt an urgent expert consultation and possible admission to the hospital as management of end organ damage can require multiple specialists.

Patient Information

Medline Plus: www.nlm.nih.gov/medlineplus/ency/article/000819.htm

REFERENCES

1. Frigas E, Park MA. Acute urticaria and angioedema diagnostic and treatment considerations. *Am J Clin Dermatol*. 2009; 10(4):239–250. PMID: 19489657.
2. Zuberbier T, Maurer M. Urticaria: current opinions about etiology, diagnosis and therapy. *Acat Derm Venereol*. 2007; 87(3):196–205. PMID: 17533484.
3. Mortureux P, Leaute-Labreze C, Legrain-Lifermann V, et al. Acute urticaria in infancy and early childhood. *Arch Dermatol*. 1998;134(3):319–323. PMID: 9521030.
4. Kaplan AP. Chronic urticaria and angioedema. *N Engl J Med*. 2002;346(3):175–179. PMID: 11796852.
5. Kozel MM, Mekkes JR, Bossuyt PM, Bos JD. The effectiveness of a history-based diagnostic approach in chronic urticaria and angioedema. *Arch Dermatol*. 1998;134(12):1575–1580. PMID: 9875196.
6. Komarow HD, Metcalfe DD. Office-based management of urticaria. *Am J Med*. 2008;121(5):379–384. PMID: 18456030.
7. Zuberbier T, Asero R, Bindslev-Jensen C, et al. EAACI/GA LEN/EDF/WAO Guideline: management of urticaria. *Allergy*. 2009;64(10):1427–1443. PMID: 19772513.
8. Kozel MA, Mekkes JR, Bossuyt PM, Bos JD. Natural course of physical and chronic urticaria and angioedema in 220 patients. *J Am Acad Dermatol*. 2001;45(3):387–391. PMID: 11511835.
9. Svensson CK, Cowen EW, Gaspari AA. Cutaneous drug reactions. *Pharmacol Rev*. 2000;53(3):357–379. PMID: 11546834.
10. Kramer MS, Leventhal JM, Hutchinson TA, Feinstein AR. An algorithm for the operational assessment of adverse drug reactions. *JAMA*. 1979;242(18):623–632. PMID: 480646.
11. Hunziker TH, Kunzi UP, Braunschweig S, Zhender D, Hoigne R. Comprehensive hospital drug monitoring (CHDM): adverse skin reactions, a 20-year survey. *Allergy*. 1997;52(4): 388–393. PMID: 9188919.
12. Arndt KA, Jick H. Rates of cutaneous reactions to drugs. A report from the Boston collaborative drug surveillance program. *JAMA*. 1976;235(9):918–922. PMID: 128641.
13. Bigby M. Rates of cutaneous reactions to drugs. *Arch Dermatol*. 2001;137(6):765–770. PMID: 11405768.
14. Litt J. *Litt's Drug Eruption and Reactions Manual*, 16th ed. New York Informa Healthcare, 2010.
15. Pichler WJ, Adama J, Daubner B, et al. Drug hypersensitivity reactions: pathomechanism and clinical symptoms. *Med Clin N Am*. 2010;94(4):645–664. PMID: 20609855.
16. Knowles SR, Shear NH. Recognition and management of severe cutaneous drug reactions. *Dermatol Clin*. 2007;25(2): 245–253. PMID: 17430761.
17. Limsuwan T, Demoly P. Acute symptoms of drug hypersensitivity (urticaria, angioedema, anaphylaxis and anaphylactic shock). *Med Clin N Am*. 2010;94(4):691–710. PMID: 20609858.
18. Cacoub P, Musette P, Descamps V, et al. The DRESS syndrome: a literature review. *Am J Med*. 2011;124(7):588–597. PMID: 21592453.

15

Acne, Rosacea, and Related Disorders

H. Spencer Holmes

Introduction to Chapter / 128
Acne / 128
Rosacea / 133
Perioral Dermatitis / 135

Folliculitis / 136
Hidradenitis Suppurativa / 138
References / 140

INTRODUCTION TO CHAPTER

Acne and related pilosebaceous disorders rarely cause serious systemic problems, but they are among the diseases that can cause significant psychosocial distress. Most of these disorders are chronic and require long-term therapy with topical and if needed, oral antibiotics. However, there are increasing concerns about the development of bacterial resistance to antibiotics, especially in patients with acne and rosacea who may take antibiotics for several years.¹

ACNE

Introduction

The prevalence of acne in adolescents has been reported to be as high as 95% with a 20% to 35% prevalence of moderate to severe acne.² Acne may persist into adulthood in up to 50% of affected individuals.³ Transient acne may occur in newborns and occasionally acne will begin in adulthood.

Quality of life issues are a very important concern for individuals (especially teenagers) with acne. Depression, anxiety, and low self-esteem are more common in patients with acne.⁴ Interestingly, there is no correlation between acne severity and degree of the mental health symptoms. Most clinicians who regularly treat acne (and parents of

teenagers) are aware of the negative emotional impact of even a few “pimples.”

Pathophysiology

The pathogenesis of acne is complex, but there are several major factors that contribute to the development of an acne lesion.^{2,3}

- Hyperproliferation and adhesion of keratinocytes in the distal portion of the hair follicle creates a keratin plug (microcomedone).
- Androgenic hormones stimulate increased sebum production.
- *Propionibacterium acnes* (*P. acnes*), an anaerobic, lipophilic, resident bacteria, proliferates in the sebum-rich environment of the plugged hair follicle.
- *P. acnes* and other factors trigger the release of inflammatory mediators that diffuse through the wall of the follicle into the surrounding dermis resulting in an inflammatory papule or pustule.
- The follicular wall ruptures and bacteria, sebum, and other follicular components are released into the dermis creating an inflamed nodule.

Several other factors such as genetics and emotional stress and affect the development and severity of acne.

Clinical Presentation

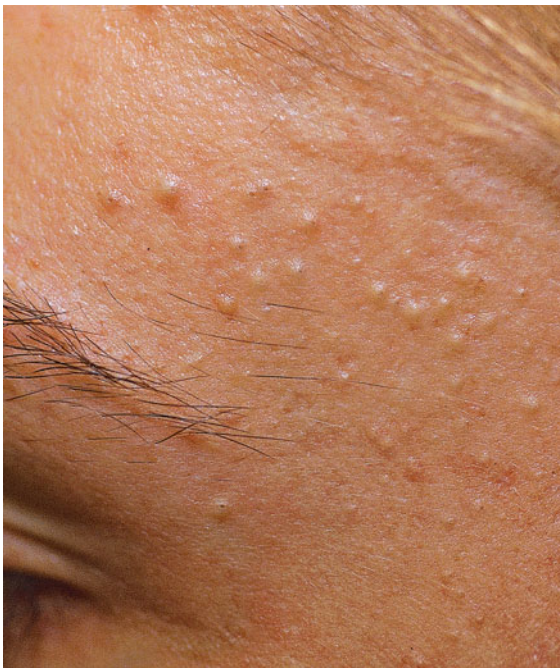History

Acne usually presents at the onset of puberty with comedones on the central face. Inflammatory papules and/or pustules may develop in early to mid-teen years and are usually confined to the face, but the neck and back may be affected. Patients with nodular acne may complain of pain and tenderness. Acne is typically a chronic disorder that does not begin to resolve until the late teens.

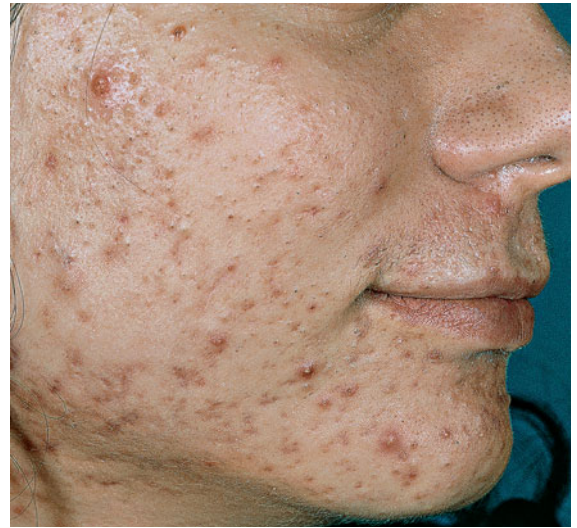Physical Examination

Acne typically presents with 4 types of lesions, comedones, inflammatory papules, pustules, and nodules. In the past the term “cystic acne” was used, but acne does not have true cysts with an epithelial lining. However, large fluctuant nodules do have a cystic appearance. Acne typically is categorized according to the predominant type of lesions seen.³

- **Comedonal acne:** Patients present with open comedones (blackheads) with a central dark keratin plugs and/or closed comedones (whiteheads) with no visible keratin plug (Figure 15-1). These are usually the first lesions of acne seen in early adolescence and are typically on the central face.
- **Papular/pustular acne:** Patients present with inflamed, 2- to 5-mm papules and/or pustules (Figure 15-2).



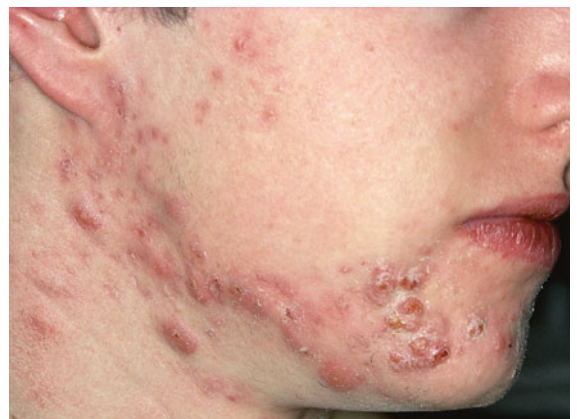▲ **Figure 15-1.** Acne. Open and closed comedones on forehead.



▲ **Figure 15-2.** Acne. Papules, pustules, and open comedones.

- **Nodular acne:** Patients present with red, firm, or fluctuant nodules (cyst like) that may drain or form sinus tracts (Figure 15-3). These lesions may leave permanent scars. When these lesions are extensive and severe, the term “acne conglobata” is used.

Acne lesions are usually primarily on the face, but can also occur on the neck, upper trunk, and shoulders. Patients may have one or multiple types of acne lesions at any one time. As acne lesions resolve they may leave pink macules that may persist for many weeks or areas of hyperpigmentation that may last for months. These macular lesions are often as cosmetically bothersome to a patient as the active acne lesions. Patients often refer to these lesions



▲ **Figure 15-3.** Acne. Large inflammatory nodules with early sinus tract formation.

as “scars,” but they do eventually resolve. Inflammatory lesions may leave permanent scars that may be indented (ice pick scars), atrophic, or hypertrophic.

Acne may be classified as mild, moderate or severe depending on the number and/or size of the lesions and the extent of the lesions.

► Laboratory Findings

Routine laboratory testing is not indicated in most patients with acne.⁵ However patients with evidence of androgen excess (eg, early puberty, hirsutism, alopecia, and infertility) should have an evaluation that could include serum testosterone, dehydroepiandrosterone sulfate (DHEA-S), and luteinizing hormone/follicle stimulating hormone (LH/FSH) ratio. Bacterial cultures of pustules could be done if gram-negative folliculitis is suspected.⁵ This presents with multiple pustules in the perinasal and perioral area.

Diagnosis

The key diagnostic findings are the presence of comedones and inflammatory papules, pustules or nodules typically on the face, neck, or upper trunk.

► Differential Diagnosis

- ✓ **Milia:** Resemble closed comedones and have the appearance of a tiny, white, firm bead. They are more common in young children and older adults.
- ✓ **Keratosis pilaris:** Very common finding in prepubescent children and may persist into adulthood. It presents with 1- to 2-mm keratotic papules typically on the cheeks and upper arms. Inflammatory papules and pustules are usually not seen.
- ✓ Table 15-1 has additional diseases in the differential diagnosis.

Management

There are many factors to consider in the treatment of acne including the following.

- Type, severity, and extent of the acne lesions.
- Efficacy of medications.
- Adverse reactions, risks, and contraindications of medications.
- Age, gender, and risk of pregnancy during treatment.
- Adherence/compliance issues.
- Cost of medications and office visits. In general generic dermatologic medications are much more affordable than branded medications.⁶
- Patient's (and parent's) level of distress with acne and their concerns about potential side effects of medications.

Several topical and oral medications are available for the treatment of acne. Table 15-2 lists formulations and brand names of several of the more commonly used topical medications.

Table 15-3 lists dosage, dosing, and some of the adverse effects of oral antibiotics that are commonly used as first-line treatment for acne when oral antibiotics are indicated.

► Medication used for the Treatment of Acne

Topical retinoids decrease the cohesiveness of the keratinocytes in the follicular opening, reduce the number of visible comedones, and inhibit formation of microcomedones. They are effective as monotherapy for comedonal acne and in combination with other medications for all other forms of acne. Dryness, redness, and peeling are common side effects with initial use, but these often resolve or improve with continued use. It is best to start with a low concentration of a retinoid and increase as tolerated.

Table 15-1. Differential diagnosis of pilosebaceous disorders.

Disease	Clinical Findings	Notes
Acne	Comedones, inflammatory papules, and/or pustules or nodules typically on the face. May also occur on neck and upper trunk	Onset after puberty, but may persist into adulthood
Rosacea	Erythema, telangiectasia, inflammatory papules, and/or pustules on central face. No comedones	Onset usually after age 30. Chronic course
Perioral dermatitis	Perioral erythema with or without scale with papules and/or pustules	Most common in females, ages 20-45. May recur
Folliculitis	Perifollicular inflammatory papules or pustules in hair-bearing areas	Onset after puberty. May recur intermittently or be chronic
Hidradenitis suppurativa	Inflammatory papules and abscesses in axillae and inguinal areas. Sinus tracts and scarring may be present	Onset in early 20s. Chronic course

Table 15-2. Topical medications used in the treatment of acne.

Generic Name	Brand Names Examples	Formulation Examples	Notes
Retinoids			
Tretinoin*	Retin-A, Avita, Refissa, Tretin-X	Cream, 0.025%, 0.05%, and 0.1% Gel, 0.01%, 0.025%, 0.04%, 0.1%	Start treatment with lower concentrations apply nightly. May be drying. Pregnancy category C
Adapalene*	Differin	Cream, 0.1% Gel, 0.1%, 0.3% Lotion, 0.1%	May be better tolerated than tretinoin. Apply nightly. Pregnancy category C
Tazarotene	Tazorac	Cream, 0.1% Gel, 0.1%	More effective, but more irritating than other retinoids. Apply nightly. Teratogenic. Pregnancy category X
Antibiotics and medications with antimicrobial effects			
Benzoyl peroxide*	Benzac, Brevoxyl, Clearasil, Panoxyl	Cream, 5%, 10% Gel, 2.5%, 4%, 5%, 8%, 10% Wash 2.5%	May reduce bacterial resistance to antibiotics. Apply daily. May cause irritant or allergic contact dermatitis. Pregnancy category C
Clindamycin*	Cleocin T, Clindagel, Evoclin	Gel, lotion, foam, pledget, 1%	Most effective of the topical antibiotics. Apply twice daily. Pregnancy category B
Dapsone	Aczone	Gel, 5%	Apply twice daily. May turn skin orange if used with benzoyl peroxide. Pregnancy category C
Erythromycin*	Several generics	Gel, ointment, solution, 2%	Antibiotic resistance may develop. Apply twice daily. Pregnancy category B
Azelaic acid	Azelex	Cream 20%	Has comedolytic effect. Apply twice daily. Pregnancy category B
Sodium sulfacetamide*	Klaron	Lotion 10%	May be drying. Apply twice daily. Pregnancy category C
Sodium sulfacetamide with sulfur*	Clenia Rosula	Cream, 10% sodium sulfacetamide, and 5% sulfur Foam, 10% sodium sulfacetamide, and 4% sulfur	Has antibacterial and keratolytic effects. Apply twice daily. May have a sulfur odor. Pregnancy category C
Combination medications			
Tretinoin + clindamycin	Ziana	Gel, tretinoin 0.025% + clindamycin 1.2%	Apply nightly. Effective for papular/pustular acne. Pregnancy category C
Adapalene + benzoyl peroxide	Epiduo	Gel, adapalene 0.1% + benzoyl peroxide 2.5%	Apply daily. Effective for papular/pustular acne. Pregnancy category C
Benzoyl peroxide + clindamycin*	Duac Benzacclin	Gel, benzoyl peroxide 5% + clindamycin 1%	Apply twice daily. Effective for papular/pustular acne. Pregnancy category C
Benzoyl peroxide + erythromycin*	Benzamycin Gel Pak	Gel, benzoyl peroxide 5% + erythromycin 1%	Apply twice daily. Effective for papular/pustular acne. Pregnancy category C
Benzoyl Peroxide + hydrocortisone	Vanoxide HC	Lotion, benzoyl peroxide 5% + hydrocortisone 0.5%	May be helpful in patients who cannot tolerate benzoyl peroxide without hydrocortisone. Apply 1 to 3 times daily. Pregnancy category C

*Generic availability for some or all formulations.

Published guidelines recommend the use of retinoids for maintenance therapy.^{3,5}

Benzoyl peroxide has antibacterial properties and it reduces the risk of *P. acnes* resistance when used in combination with oral or topical antibiotics.^{1,3,5} Benzoyl peroxide is widely available in many types of vehicles in nonprescription and prescription formulations. As with retinoids,

it is best to start with lower concentrations. Benzoyl peroxide may cause irritant or allergic contact dermatitis and it may bleach fabrics.

Salicylic acid is a mildly keratolytic agent that is present in many nonprescription medications.

Topical antibiotics are effective medications for inflammatory acne lesions when they are combined with

Table 15-3. Oral antibiotics commonly used for acne and other pilosebaceous diseases.

Medication	Formulations	Dosing	Notes
Tetracycline*	250, 500 mg	500 mg once daily to twice daily	Needs to be taken on empty stomach. Pregnancy category D
Doxycycline*	50, 100 mg	50-100 mg once daily to twice daily	May cause photosensitivity and dyspepsia. Pregnancy category D
Minocycline*	50, 100 mg	50-100 mg once daily to twice daily	Can be taken with food. Potential adverse effects include skin discoloration, vertigo and other central nervous system symptoms, hepatitis, and lupus-like syndromes. Pregnancy category D
Erythromycin*	125, 250, 333 mg	250-500 mg once to twice daily	May cause gastric irritation and diarrhea. Bacterial resistance may occur. Pregnancy category B

*Generic availability for some or all formulations.

retinoids and benzoyl peroxide. They are typically not used as a monotherapy for acne.

Azelaic acid has antibacterial and comedolytic effects on acne. It also may decrease postinflammatory hyperpigmentation in acne lesions. It is rated pregnancy category B.

Topical combination acne medications typically contain a retinoid or benzoyl peroxide with an antibiotic or with each other. In general, they are much more expensive than their constituents used separately, but they are easier to use and have better patient acceptance and adherence.³

Oral antibiotics are typically used for moderate to severe papular/pustular or nodular acne. Tetracycline, doxycycline, and minocycline are the most commonly used antibiotics for acne because of their antibacterial and anti-inflammatory effects. These antibiotics should not be used by pregnant or nursing females or by children under age 8. Doxycycline and minocycline are generally recommended in the literature as the antibiotics of first choice.^{3,5} Erythromycin is an alternative in patients who have a contraindication for the use of the tetracyclines. However bacterial resistance often develops during erythromycin therapy.⁵ Dosing commonly recommended in textbooks is included in Table 15-3.⁷ Trimethoprim-sulfamethoxazole (eg, Bactrim, Septra DS) is another alternative, second-line, antibiotic for short-term use that is included in guidelines for acne therapy; however, it has a potential for severe adverse reactions (eg, aplastic anemia, hepatic necrosis, and toxic epidermal necrolysis). Amoxicillin is also occasionally used for patients who have gastrointestinal symptoms with other antibiotics. It is rated pregnancy category B. Candida vaginal infections can occur with chronic use of antibiotics. The development of *P. acnes* and commensal flora resistance to antibiotics used in the treatment of acne is noted in guidelines as an increasing concern.^{1,2,3,5} In general, guidelines recommend that oral antibiotics should be discontinued, when possible, once inflammatory lesions have resolved and if chronic antibiotic therapy is needed, benzoyl peroxide gel or wash should be added to decrease the risk of bacterial resistance to antibiotics.

Oral isotretinoin is US Food and Drug Administration (FDA) approved for patients with severe recalcitrant nodular acne who are unresponsive to conventional therapy, including systemic antibiotics. It is typically prescribed for a 20-week course. Isotretinoin is a teratogen with a very high risk for severe birth defects if taken during pregnancy in any amount, even for a short period of time. Isotretinoin can only be prescribed by clinicians who participate in a special restricted distribution program (iPLEDGE). There are several other potential adverse effects (eg, cutaneous, neurological, skeletal, and lipid disorders) associated with isotretinoin. Typically because of the complexity of the iPLEDGE program and the risks of isotretinoin, most primary care clinicians refer patients who are potential candidates for isotretinoin to dermatology. Evidence-based guidelines still recommend the use of isotretinoin in the appropriate patient.^{2,3,5}

Oral contraceptives may improve acne,⁵ but they have several potential risks including hypertension, thrombophlebitis, and pulmonary embolism. Estrostep, Ortho Tri-Cyclen, and Yaz are FDA approved in the United States for women ≥15 years with moderate acne who also want these medications for contraception. The FDA has issued a warning about a greater increased risk for venous thromboembolism due to drospirenone that is in YAZ.⁸ Oral antiandrogens (eg, spironolactone) may also improve acne, but also have potential risks.⁵ Patients should be evaluated by their primary clinician or gynecologist prior to the use of oral contraceptives.

Several guidelines based on evidence-based medicine have been published for the treatment of acne.^{2,3,5} There are some variations in the recommendations among the various guidelines. The following are treatment options for various types of acne based on these guidelines.

► Treatment Options for Acne^{3,5}

Comedonal acne: Topical retinoids are the first-line treatment for comedonal acne. Therapy is usually initiated

with the lowest strength retinoid to minimize redness and dryness. The strength of the retinoid may be increased if needed. Alternative therapies include benzoyl peroxide, azelaic acid, or salicylic acid. Topical and oral antibiotics are not effective. Some clinicians recommend extraction of comedones. Comedone extractors can be purchased in drugstores.

Papular/pustular acne:

- Mild disease: First-line therapies include a topical retinoid plus a topical antibiotic. Benzoyl peroxide may be added. Azelaic acid is an alternative therapy.
- Moderate to severe disease: Moderate disease can be treated with the same first-line therapy as mild disease. If the patient does not respond or if the patient has severe disease oral antibiotics plus a topical retinoid plus benzoyl peroxide gel or wash are first-line therapies. Alternative therapies include switching to another type of topical retinoid plus another type of antibiotic plus benzoyl peroxide.

Nodular acne: The first-line therapy for nodular acne includes an oral antibiotic plus a topical retinoid plus benzoyl peroxide gel or wash. Patients who do not respond to therapy could be switched to another oral antibiotic or another type of topical retinoid. If the patient still has persistent nodular acne, they may need a referral to dermatology for management that might include the use of oral isotretinoin therapy. Patients with severe nodular acne that is unresponsive to therapy could be left with permanent scars if they receive suboptimal treatment.

► General Guidelines for the Use of Acne Medications

- Topical acne medications should be applied sparingly to all areas of active acne and to areas of chronic past involvement. Patients should wait 15 minutes after washing before applying the medication.
- If irritation develops with the use of a topical acne medication, the frequency of application can be reduced and a noncomedogenic moisturizer can be added.
- Patients with acne should use noncomedogenic skin care products.
- Benzoyl peroxide gel or wash should be used with topical or oral antibiotics to reduce the risk of bacterial resistance to antibiotics.
- Most topical medications will begin to improve acne after 6 to 8 weeks of use. It may take several more weeks before their maximum benefit is reached. Therefore, it is important to not discontinue or switch treatments until it is clear that a medication is not effective.
- When possible oral antibiotics should be discontinued when inflammatory acne lesions resolve, usually within 3 to 4 months.

- Dietary restrictions are generally of little benefit. However limiting milk intake and a low glycemic index diet may be of some benefit in acne.⁹

Patient adherence/compliance issues: In recent years the term adherence has been more commonly used as it implies that there is a willingness to follow a management plan that was formulated and agreed upon by the patient and the clinician.³ In the treatment of teenagers with acne, it is especially important to determine who is most interested in pursuing treatment, the patient or the parents or both. Adherence is generally improved by counseling and education on the cause of acne and proper use of medications, addressing cost issues and other pitfalls of treatment plans, and the use of medication reminders (eg, text messages from the clinic or medication reminder apps). It is also important to address psychosocial issues and work with the patient's primary care clinician and mental health professionals if needed.

Indications for Consultation

Patients with acne who do not respond to therapy or who may be candidates for isotretinoin therapy should be referred to dermatology.

Patient Information

- The American Academy of Dermatology has an excellent, comprehensive online site (AcneNet) for patients with acne: www.skincarephysicians.com/acnet/index.html
- American Academy of Dermatology: www.aad.org/skin-conditions/dermatology-a-to-z/acne
- PubMed Health: www.ncbi.nlm.nih.gov/pubmedhealth/PMH0001876/

ROSACEA

Introduction

Rosacea is a common condition of the central face, which usually begins after age 30 and typically persists with intermittent or continual outbreaks. It is 2 to 3 times more common in women, but men tend to have more severe disease.¹⁰ It is more common in fair-skinned individual with a northern European or Celtic heritage.

Pathophysiology

The exact pathogenesis of rosacea is unknown, but several potential factors have been identified.^{10,11}

- Immune factors: Upregulation of proinflammatory and vasoregulatory genes.
- *Demodex folliculorum*: A mite found in the facial pilosebaceous unit of most adults is sometimes present in larger numbers in patients with rosacea.

- Vascular abnormalities: Include dilation of blood vessels.
- Genetics: Up to one-third of patients have a family history of rosacea.
- Triggers: Sunlight exposure, exercise, hot or cold weather, emotional stress, topical steroids, certain foods, and alcohol, especially wine.

Clinical Presentation

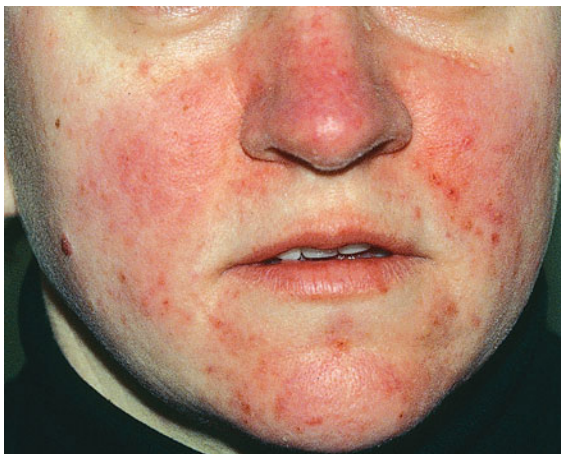History

Patients often report a gradual onset of facial redness and/or flushing or “pimples” on the central face. A history of general sensitivity to skin care products is common, and the patient may have a history of topical steroid use. Burning, stinging, and pruritus of the eyelid are common complaints in ocular rosacea.

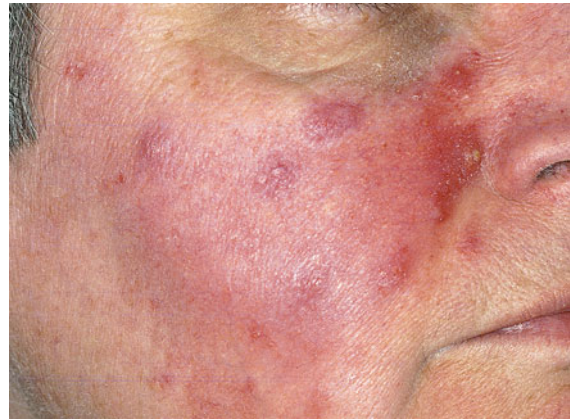Physical Examination

There are four subtypes of rosacea. Patients may present with one or more of these subtypes at any given time.^{10,11}

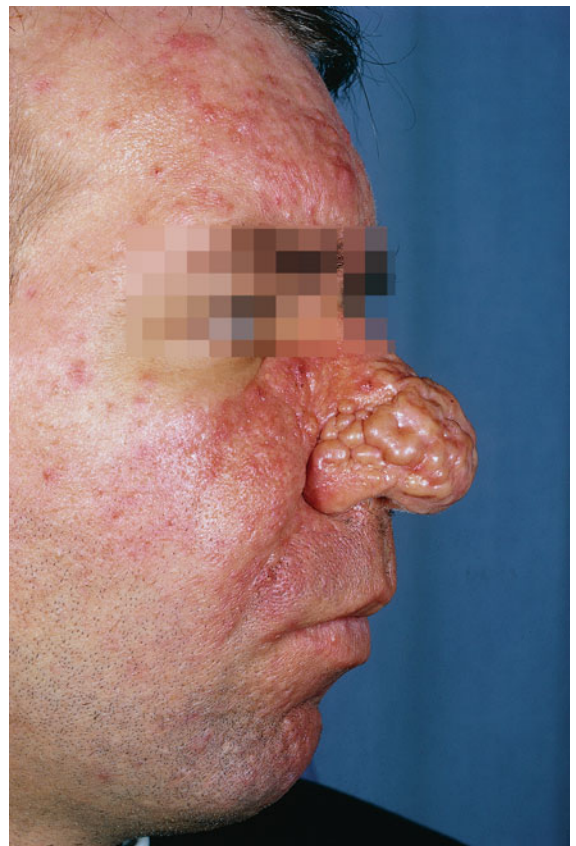- **Erythematotelangiectatic rosacea** presents with episodes of facial flushing and/or persistent erythema typically on the nose and cheeks (Figure 15-4). Visible telangiectasia and small papules may be seen.
- **Papulopustular rosacea** presents with erythematous papules and pustules on the central face including the forehead (Figure 15-5). The lesions may closely resemble acne, but no comedones are seen.
- **Phymatous rosacea** is an uncommon presentation that mostly occurs in men. It develops very slowly and presents with thick, pink, or skin-colored plaques with an irregular surface typically on the nose (Figure 15-6),



▲ **Figure 15-4.** Erythematotelangiectatic rosacea. Erythema on nose, cheeks, and chin with telangiectasia and a few small papules.



▲ **Figure 15-5.** Papulopustular rosacea. Papules and pustules with erythema and telangiectasias on cheek.



▲ **Figure 15-6.** Phymatous rosacea. Rhinophyma with multiple irregular nodules distorting the normal shape of the nose. Erythematous papules are also seen on the central face.

sometimes creating a bulbous nose (rhinophyma). It can also present on the forehead, chin, or ears.

- **Ocular rosacea** presents with conjunctivitis, blepharitis, and sometimes with recurrent chalazion. Twenty percent of patients with rosacea initially present with this form.¹⁰

► Laboratory Findings

Laboratory studies are generally not indicated, but occasionally skin biopsies are needed to confirm the diagnosis in atypical presentations of rosacea.

Diagnosis

The key diagnostic findings are central facial papules or pustules with persistent erythema or flushing.

► Differential Diagnosis

- ✓ **Chronic sun damage:** May very closely resemble and be concomitant with rosacea, but papules and pustules are not present and typically other areas such as the neck are also effected.
- ✓ **Systemic lupus erythematosus (SLE):** The malar “butterfly” rash of SLE may closely resemble erythematotelangiectatic rosacea, but no papules or pustules are seen.
- ✓ Table 15-1 has additional diseases in the differential diagnosis.

Management

Treatment depends on the subtype(s) of rosacea.^{10,12}

- **Papulopustular rosacea:** Most patients with this subtype will usually respond to intermittent or chronic use of topical medications (Table 15-4). Other medications that have been recommended, but not FDA approved for

rosacea, include topical clindamycin, erythromycin, and tretinoin (Table 15-2). Patients who do not respond to topical medications within 4 to 6 weeks could be treated with tetracycline, doxycycline (including a 40-mg dose), or minocycline in doses similar to those used for acne (Table 15-3); however, low once a day dosing is usually sufficient for most patients. Most patients require only 2 to 3 weeks or oral antibiotics given on intermittent basis.

- **Erythematotelangiectatic rosacea:** Although perilesional erythema of rosacea papules and pustules improves with treatment, the background erythema associated with this subtype usually does not respond to topical or oral medications. Intense pulsed light and pulse dye lasers can be effective therapy for the erythema and telangiectasia associated with this subtype of rosacea; however, these treatments are often not covered by insurance.
- **Phymatous rosacea (rhinophyma):** This form of rosacea can be improved with aggressive treatment of the early stages of disease. Electrosurgery is helpful to reshape the nose in advanced disease. Erbium YAG and carbon dioxide lasers can also be used.
- **Ocular rosacea:** Artificial tears, lid hygiene, cyclosporine (Restasis) 0.05% ophthalmic emulsion twice daily, and oral tetracyclines (Table 15-3) can be used for this form of rosacea.

General recommendations for patients with rosacea:

- All topical steroids and any face products perceived to be causing irritation should be discontinued. Patients should be warned that they will experience an initial flare of rosacea when topical steroids are discontinued, but they must not resume them.
- Sun protection with broad-brimmed hats and sunscreens is important.
- When possible, triggers for rosacea should be limited or avoided.

Indications for Consultation

Patients with severe or persistent rosacea or with rhinophyma should be sent to dermatology. An ophthalmology referral may be indicated for patients with ocular rosacea.

Patient Information

- National Rosacea Society: www.rosacea.org
- American Academy of Dermatology: www.aad.org/skin-conditions/dermatology-a-to-z/rosacea/

PERIORAL DERMATITIS

Introduction

Perioral dermatitis is a disorder primarily of women ages 20 to 45, although it sometimes can occur in prepubescent

Table 15-4. Topical medications for the treatment of rosacea.

Generic Name	Formulations	Dosing
Metronidazole*	Gel and Lotion 0.75% Cream 0.75% and 1%	Apply twice daily for 0.75% formulations and once daily for 1% cream
Azelaic acid	Gel 15%	Apply twice daily
Sodium sulfacetamide with sulfur*	Cream, lotion, and cleanser, 10% sodium sulfacetamide with 5% sulfur	Use once or twice a day

*Generic availability for some or all formulations.

boys and girls.¹³ It typically responds to treatment, but may be recurrent. It is commonly misdiagnosed as contact dermatitis and treated with topical steroids that exacerbate the problem.

Pathophysiology

The pathogenesis of perioral dermatitis is unknown, but several factors are suspected triggers. These include topical and inhaled steroids, oral contraceptives, menstruation, pregnancy, certain skin care products, fluorinated toothpaste, and emotional stress.¹³ *Candida* and demodex mites have also been isolated from lesions, but it not clear that these cause the disease.

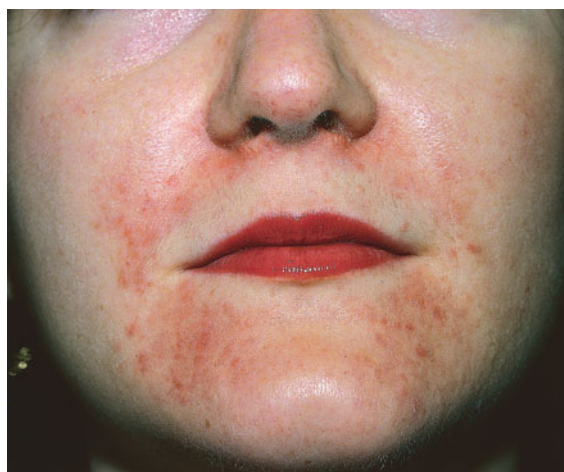Clinical Presentation

History

Patients usually complain of a rash and/or pimples around the mouth. Most patients have a history of using multiple over the counter products in an attempt to treat their rash. They also frequently have a history of using prescription topical steroids.

Physical Examination

Most patients have perioral, subtle, diffuse erythema with or without scale. Papules, pustules, and/ or vesicles may be superimposed on the erythema (Figure 15-7). Often there is a several millimeter wide border of normal skin along the edge of the lips. The lips are not involved. Less commonly the nasolabial folds and skin around the lateral canthal areas are affected.



▲ **Figure 15-7.** Perioral dermatitis. Multiple erythematous papules around the mouth with an area of uninvolved skin along the border of the lips.

Laboratory Findings

Laboratory studies and skin biopsies are not indicated.

Diagnosis

The key diagnostic findings are perioral erythema, papules, vesicles, or pustules in adult females.

Differential Diagnosis

- ✓ **Irritant contact dermatitis:** Presents with perioral erythema and scales, but there are no papules, pustules, or vesicles. Lesions are present on other parts of the face.
- ✓ **Allergic contact dermatitis:** Usually this is due to products applied to the lips, so in contrast to perioral dermatitis the lips are primarily involved.
- ✓ Table 15-1 has additional diseases in the differential diagnosis.

Management

All topical steroids and any skin products that may have caused or flared perioral dermatitis should be discontinued. Patients should be warned that they may have a flare of their rash when they stop topical steroids, but they should not resume them. Topical tacrolimus, pimecrolimus, or 1% hydrocortisone can be used short-term to treat the dermatitis component. However, there have been reports of granulomatous rashes following the use of immunomodulators.¹³ Topical erythromycin, clindamycin, azelaic acid, and metronidazole can be added to treat the papular component. If patients do not respond to topical therapy the oral antibiotics listed in Table 15-2 can be used for 4 weeks or longer if needed. Perioral dermatitis usually responds to therapy and may resolve spontaneously, but triggers especially hormonal ones may cause recurrences.

Indications for Consultation

Severe or persistent disease that does not respond to therapy.

Patient Information

PubMed Health: www.ncbi.nlm.nih.gov/pubmedhealth/PMH0002426/

FOLLICULITIS

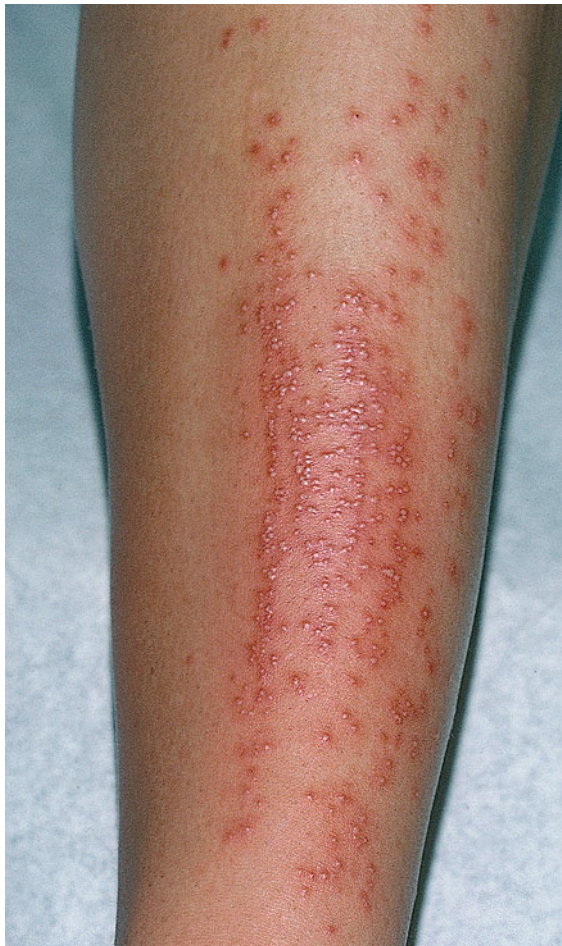Introduction

Folliculitis is very common disorder of the hair follicle that can be seen at any age in hair bearing sites. It is often seen as an incidental finding on physical examination.

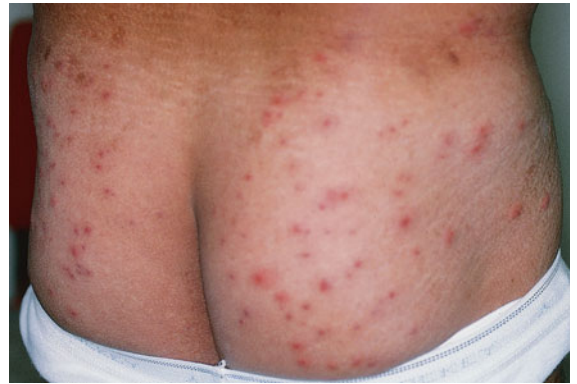Pathophysiology

Folliculitis can be caused by microbes or noninfectious processes.¹⁴

- Bacteria are the most common cause of folliculitis. *Staphylococcus aureus* (Figure 15-8) and less frequently species of *Streptococcus*, *Pseudomonas* (usually acquired in hot tubs and whirlpools) (Figure 15-9), and other gram-negative organisms are most common.
- Fungal folliculitis caused by *Pityrosporum orbiculare* can occur and can be chronic if left untreated.
- *Demodex folliculorum* mites are normally found in hair follicles and sebaceous glands, but when present in high numbers they may cause a follicular rash on the face and other body areas.



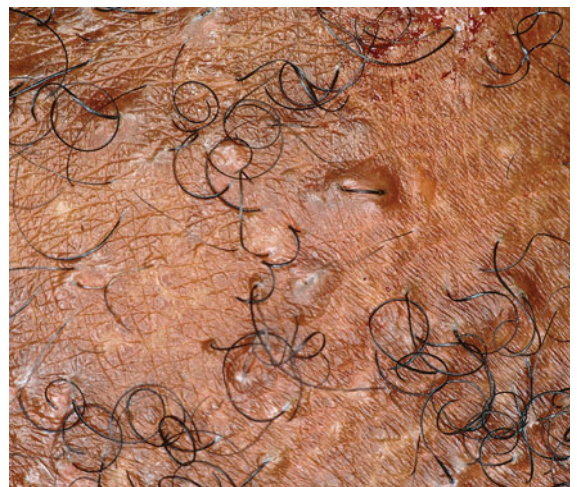▲ **Figure 15-8.** Folliculitis. Multiple pustules in streaks that developed after shaving legs with a razor blade. A culture isolated coagulase-positive *Staphylococcus aureus*.



▲ **Figure 15-9.** *Pseudomonas* folliculitis. Multiple erythematous papules on buttocks after use of a hot tub; usually caused by exposure to contaminated water with inadequate amounts of chlorine.

- Mechanical folliculitis can be caused by the hair being tightly pulled back (traction folliculitis), hair removal (shaving, waxing, and plucking) (Figure 15-8), chronic friction from tight clothing and ingrown hairs (pseudofolliculitis) (Figure 15-10). A secondary folliculitis may develop in patients who scratch areas of dermatoses.
- Eosinophilic folliculitis primarily occurs in individuals with human immunodeficiency virus (HIV) infections and transplant recipients.

Diabetic and immunocompromised patients are more susceptible to folliculitis.



▲ **Figure 15-10.** Pseudofolliculitis barbae. Multiple perifollicular papules in beard of an African-American patient due to curved hair fibers reentering the skin.

Clinical Presentation

History

Patients with folliculitis usually complain of pruritic “pimples”, pustules, or papules.

Physical Examination

Folliculitis typically presents with small 1- to 3-mm perifollicular pustules and/or inflammatory papules on any hair bearing area, but most commonly on the trunk, buttocks, thighs, face, and scalp. Lesions of *staphylococcal* folliculitis may occasionally coalesce into large, painful carbuncles. Gram-negative folliculitis presents with pustules on the central face and may closely resemble acne. *Pseudomonas* folliculitis usually appears within a few hours of exposure and is most prominent in areas covered by a bathing suit. *Demodex* folliculitis closely resembles rosacea and *pityrosporum* folliculitis on the trunk is very similar to bacterial folliculitis. Pseudofolliculitis presents with ingrown hairs and firm papules in the scalp and beard areas typically in African-American individuals.

The postinflammatory hyperpigmentation that may occur in folliculitis in darker skinned individuals is very distressing to patients and since it may be widespread it is usually difficult to treat.

Laboratory Findings

Cultures from intact pustules of bacterial folliculitis may isolate the causative organism. Skin scrapings may identify folliculitis caused by *demodex* or *pityrosporum*, but these are usually diagnosed by skin biopsy.

Diagnosis

The key diagnostic findings are perifollicular papules or pustules.

Differential Diagnosis

- ✓ **Keratosis pilaris:** Very common finding in prepubescent children. It presents with persistent, 1 to 2 mm, keratotic papules typically on the cheeks and upper arms.
- ✓ Table 15-1 has additional diseases in the differential diagnosis.

Management

Mild cases of bacterial folliculitis may be managed by topical disinfectant skin washes (eg, triclosan, benzalkonium chloride, chlorhexidine, and bleach baths. Dilute 0.25% acetic acid wet dressings (¼ cup vinegar in one quart of

water) can be used in *pseudomonas* folliculitis. Moderate or severe bacterial folliculitis often requires 10 to 15 days of the appropriate oral antibiotic. *Pityrosporum* folliculitis will usually respond to topical ketoconazole cream or shampoo.

Indications for Consultation

Patients with severe or persistent disease may benefit from consultation with dermatology or infectious disease.

Patient Information

PubMed Health: www.ncbi.nlm.nih.gov/pubmedhealth/PMH0001826/

HIDRADENITIS SUPPURATIVA

Introduction

Hidradenitis suppurativa is a chronic inflammatory follicular disorder in the apocrine gland bearing areas of the axillary, inguinal, and inframammary areas. The reported prevalence ranges from 1% to 4%.^{15,16} It is more common in women. Onset of disease is in the early 20s with a gradual decrease in activity in the 50s. In its most severe form, hidradenitis can be debilitating and result in considerable discomfort and embarrassment due to malodorous draining abscesses, sinus tracts, painful nodules, and scars.

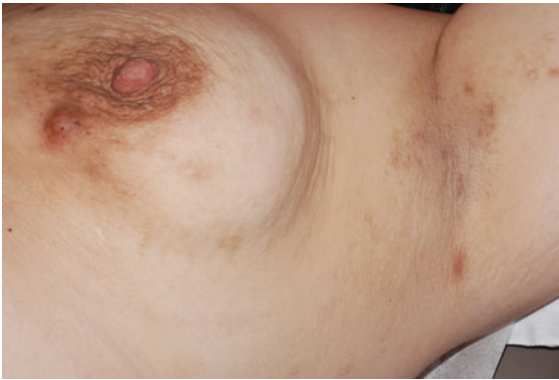
Pathophysiology

The pathogenesis of hidradenitis suppurativa is unknown. However some steps in the formation of lesions are similar to those in acne. Follicular keratin plugs may lead to rupture of hair follicles with follicular contents draining into the dermis.¹⁵ This triggers the formation of inflammatory nodules and abscesses. Lesions may coalesce and sinus tracts may form. Tumor necrosis factor α (TNF- α) and the interleukins may play a part in the inflammatory reaction.¹⁷ Risk factors include obesity, cigarette smoking, and a family history of hidradenitis.

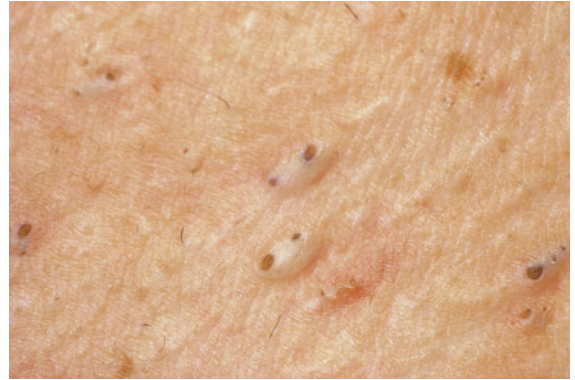Clinical Presentation

History

Patients typically report a gradual onset of persistent or recurrent boil-like lesions in the axillae and/or inguinal area. The lesions may be very painful. At this stage the disease is often misdiagnosed as staphylococcal boils. Individual lesions do heal, but new lesions typically appear often in the same area. With repeated flares multiple sinus tracts and purple or hyperpigmented scars may form.



▲ **Figure 15-11.** Hidradenitis suppurativa. Multiple inflamed nodules in axilla and on breast.



▲ **Figure 15-12.** Hidradenitis suppurativa. Single and double giant comedones.

► Physical Examination

The clinical findings depend on the stage of the disease.

- Stage one: Single or multiple abscesses or nodules (Figure 15-11).
- Stage two: Nonconfluent, recurrent abscesses, or nodules with sinus tracts and scars.
- Stage three: Similar to stage two, but lesions are diffuse and affect an entire region. Only 1% of patients progress to this stage.¹⁶

Single or grouped comedones may be seen (Figure 15-12) and yellow, sometimes odoriferous drainage may be expressed from cyst and sinus tracts. The axillae and inguinal areas are most commonly involved. The breasts, inframammary area, buttocks, inner thighs, and perineal and perianal area may also be involved.

► Laboratory Findings

Bacterial cultures are usually negative for pathogenic bacteria, but secondary infections with *Staphylococcus aureus* and other organisms may occur.

Diagnosis

The key diagnostic findings are inflamed papules, nodules, or sinus tracts with scarring in axillae or inguinal folds.

► Differential Diagnosis

- ✓ **Staphylococcal boils:** These typically have a pointed surface and are more randomly distributed, not necessarily confined to intertriginous areas.
- ✓ Table 15-1 shows additional diseases in the differential diagnosis.

Management

Management depends on the extent and severity of disease.^{15–17} There are relatively few randomized, controlled trials that can assist a clinician's choice of treatment for this disease.

- Stage one disease can be managed with topical clindamycin 1% solution, gel, or lotion twice a day. Antibiotics as listed in Table 15-2 can be intermittently used. In addition oral clindamycin and rifampin have been recommended. Bacterial cultures with sensitivities are sometimes needed in the selection of appropriate oral antibiotics.
- Stage two disease can be managed similar to stage one. Intralesional steroid injections may be effective in some patients. TNF- α inhibitors (eg, infliximab) have been used in some cases. Surgical procedures may be indicated for large fluctuant nodules. With lidocaine anesthesia, abscesses can be lanced and drained manually or the “roof” of the lesions can be removed, allowing the base of the lesion to heal.¹⁵
- Stage three disease rarely improves with medical therapy. At this stage patients are typically referred for extensive excision of the affected area or for laser therapy (eg, carbon dioxide or Nd:YAG lasers).

Other measures that may be of benefit include weight loss, cessation of smoking, antibacterial cleansers, loose fitting cotton clothing.

Indications for Consultation

Patients with moderate to severe disease should be managed by a team approach with primary care, dermatology, and surgery. Coordination of care may be difficult as patients with more severe disease often go to urgent care clinics or emergency departments for management of acute flares.

Patient Information

Hidradenitis Suppurativa Foundation: hs-foundation.org

REFERENCES

1. Chon SY, Doan HQ, Mays RM, Singh SM, Gordon RA, Tying SK. Antibiotic overuse and resistance in dermatology. *Dermatol Ther.* 2012;25(1):55–69. PMID: 22591499.
2. Nast A, Drno B, Bettoli V, et al. European evidence-based (S3) guidelines for the treatment of acne. *J Europ Acad Dermatol Venereol.* 2012;26(suppl 1):1–29. PMID: 22356611.
3. Thiboutot D, Gollnick H, Bettoli V, et al. New insights into the management of acne: an update from the Global Alliance to Improve Outcomes in Acne group. *J Am Acad Dermatol.* 2009;60(5 suppl):S1–50. PMID: 19376456.
4. Barnes LE, Levender M, Fleischer AB, Feldman SR. Quality of life measures for acne patients. *Dermatol Clin.* 2012;30(2):293–300. PMID: 22284143.
5. Strauss JS, Krowchuk DP, Leyden J, et al. Guidelines of care for acne vulgaris management. *J Am Acad Dermatol.* 2007;56(4):651–663. PMID: 17276540.
6. Payette M, Grant Kels JM. Generic drugs in dermatology: part II. *J Am Acad Dermatol.* 2012;66(3):353.e1–e15. PMID: 22342022.
7. Zaenglein AL, Graber EM, Thiboutot DM. Acne vulgaris and acneiform eruptions. In: Goldsmith LA, et al., eds. *Fitzpatrick's Dermatology in General Medicine*. Vol. 1. 8th ed. New York, NY: McGraw-Hill; 2012:908.
8. In brief: FDA warning about drospirenone in oral contraceptives. *Med Lett Drugs Ther.* 2012;54(1389):33–33. PMID: 22538620.
9. Bowe WP, Joshi S, Shalita AR. Diet and acne. *J Am Acad Dermatol.* 2010;63(1):124–141. PMID: 20338665.
10. Baldwin HE. Diagnosis and treatment of rosacea: state of the art. *J Drugs Dermatol.* 2012;11(6):725–730. PMID: 22648219.
11. Crawford GH, Pelle MT, James WD. Rosacea I. Etiology, pathogenesis, and subtype classification. *J Am Acad Dermatol.* 2004;51(3):327–341. PMID: 15337973.
12. van Zuuren EJ, Kramer SF, Carter BR, Graber MA, Fedorowicz Z. Effective and evidence-based management strategies for rosacea: summary of a Cochrane systematic review. *Br J Dermatol.* 2011;165(4):760–781. PMID: 21692773.
13. Lipozencic J, Ljubojevic S. Perioral dermatitis. *Clin Dermatol.* 2011;29(2):157–161. PMID: 21396555.
14. Luelmo-Aguilar J, Santandreu MS. Folliculitis: recognition and management. *Am J Clin Dermatol.* 2004;5(5):301–310. PMID: 15554731.
15. Danby FW, Margesson LJ. Hidradenitis suppurativa. *Dermatol Clin.* 2010;28(4):779–793. PMID: 20883920.
16. Jemec GB. Clinical practice. Hidradenitis suppurativa. *N Engl J Med.* 2012;366(2):158–164. PMID: 22236226.
17. Rambhatla PV, Lim HW, Hamzavi I. A systematic review of treatments for hidradenitis suppurativa. *Arch Dermatol.* 2012;148(4):439–446. PMID: 22184715.

Benign Tumors and Vascular Lesions

Bart Endrizzi

16

Introduction to Chapter / 141
Seborrheic Keratosis / 141
Lentigo / 142
Dermatofibroma (Histiocytoma) / 143
Skin Tag (Acrochordon,
Cutaneous Papilloma) / 144
Sebaceous Hyperplasia / 144
Lipoma / 145
Keloid/Hypertrophic Scar / 145
Epidermal (Epidermoid) Cyst / 146
Pilar Cyst / 147
Milia / 147

Digital Mucous Cyst / 148
Acquired Vascular Lesions (Cherry Hemangioma,
Venous Lake, Spider Angioma) / 149
Pyogenic Granuloma / 149
Vascular Lesions in Infants / 150
Vascular Malformation (Port-Wine Stain,
Stork Bite, Angel Kiss) / 150
Infantile Hemangioma (Superficial, Mixed
or Deep) / 151
Congenital Hemangioma / 152
References / 152

INTRODUCTION TO CHAPTER

For the clinician a clear knowledge of the most common benign tumors and important. Identifying a lesion that falls outside of the spectrum of common benign tumors and requires further evaluation or referral is critical. This fundamental insight will help alleviate the concern of a patient who presents with an otherwise benign lesion. It will also allow the clinician to first screen and differentiate common lesions that may have simple treatments, or no required treatment, from those lesions that are of more concern.

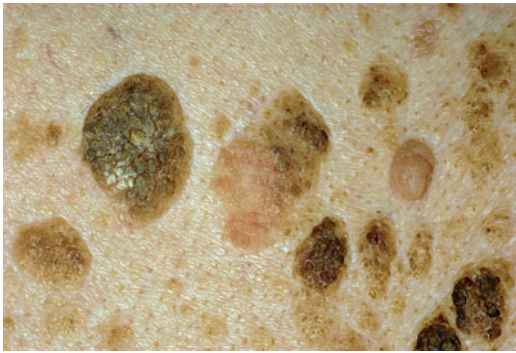
SEBORRHEIC KERATOSIS

Clinical Presentation

History and Physical Examination

Seborrheic keratoses are present in approximately 50% of adult patients. Many patients present with a history of

a changing pigmented “mole” and a concern about melanoma. Patients may complain of pruritus or irritation from clothing. A classic seborrheic keratosis has a predilection for the trunk and presents as a well-defined hyperpigmented papule or plaque with a waxy hyperkeratotic surface, ranging in size from a few millimeters to several centimeters in diameter (Figure 16-1). They are often oval in shape with their long axis following the natural tension lines of the skin. The astute clinician can quickly recognize these lesions and avert the need for a biopsy, but occasionally even with the most trained eye a biopsy is indicated. Variants include the macular seborrheic keratosis of the face and scalp that present as a slightly raised velvety plaque or pigmented macule on the head and neck. These lesions are often misdiagnosed as a lentigo with concern for lentigo maligna melanoma. A facial variant is dermatosis papularis nigra which presents primarily in African Americans with small dark papules (Figure 16-2). Stucco keratosis is another variant and presents as smaller scattered lightly pigmented or white keratotic papules on the distal lower extremities (Figure 16-3).



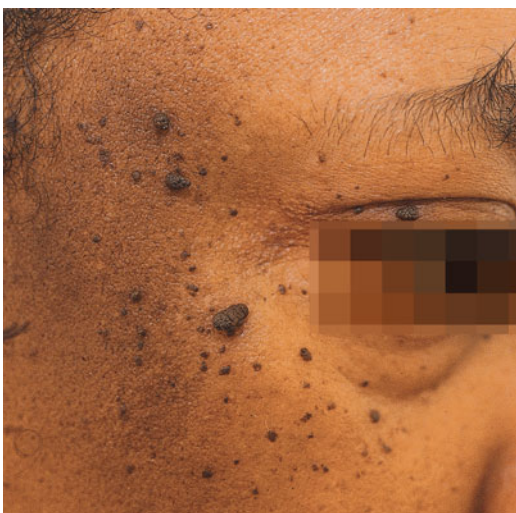▲ **Figure 16-1.** Seborrheic keratosis. Tan to brown plaques with a waxy hyperkeratotic surface.

► Laboratory Findings

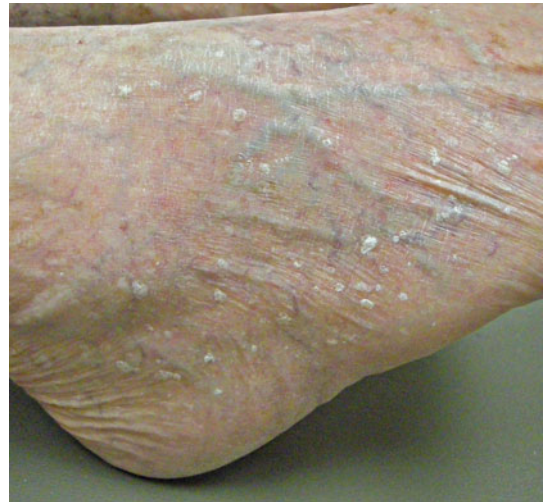Histopathology shows that all variants of seborrheic keratosis are limited to thickening of the epidermis with trapping of keratin in elongated tracks called horn pseudocysts. These can be seen under dermoscopy or by careful observation with the unaided eye.

► Differential Diagnosis

- ✓ **Lentigo:** Macule with even hyperpigmentation and a smooth scalloped border, most commonly on sun-exposed areas of face and hands.
- ✓ **Nevus:** Tan to black macules or papules; surface is not hyperkeratotic or waxy.
- ✓ **Melanoma:** Hyperpigmented macule/papule with irregular color, border, and shape.



▲ **Figure 16-2.** Dermatosi papularis nigra. Variant of seborrheic keratosis seen in African Americans.



▲ **Figure 16-3.** Stucco keratosis. Variant of seborrheic keratosis seen on legs and feet. Presents with small white hyperkeratotic papules.

Management

There is no specific treatment that is required other than differentiated seborrheic keratoses from other lesions that would have malignant potential. For irritated or disfiguring lesions, cryotherapy (Chapter 7) can be beneficial. Care must be taken however to not over-treat as a scar can replace the lesion. Patients must be warned that with any treatment persistent hypo- or hyper-pigmentation may occur. Alternative treatments include electrocautery or desiccation with or without curettage.

Indications for Consultation

Lesions that cannot be clearly defined as benign.

Patient Information

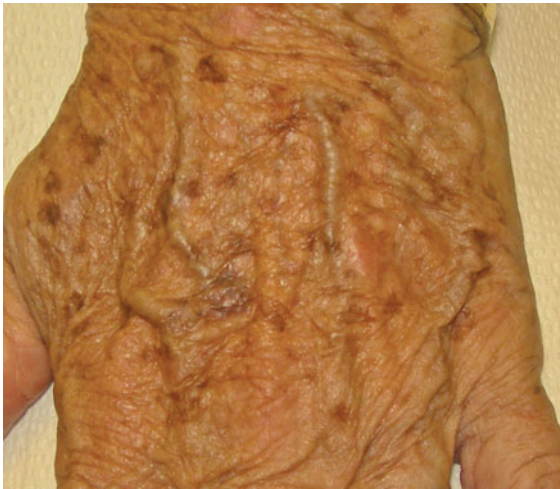American Academy of Dermatology: www.aad.org/skin-conditions/dermatology-a-to-z/seborrheic-keratoses

▼ LENTIGO

Clinical Presentation

► History and Physical Examination

Lentigines are common benign hyperplasias of melanocytes. They are usually acquired, but occasionally are congenital, especially as part of congenital syndromes such as LEOPARD (Moynahan) syndrome and Peutz–Jeghers syndrome. They commonly begin in the third decade of life and present as light or dark brown macules with sharp borders in sun-exposed skin, primarily dorsal hands



▲ **Figure 16-4.** Lentigines. Brown macules on dorsal hand.

(Figure 16-4), forearms, and shoulders. They may also occur on mucous membranes and the nail bed. Lentigo simplex occurs without ultraviolet exposure and can develop as early as the first decade of life. These present as sharply marginated monochromatic light or dark brown macules. Patients rarely bring lentigines to medical attention except in the context of “unsightly” age spots or concern for melanoma.¹

► Laboratory Findings

Histopathology shows an increased number of melanocytes in the basal cell layer of the epidermis.

► Differential Diagnosis

- ✓ **Lentigo maligna:** Macular hyperpigmentation, in a similar distribution, but with variations in color and irregular border, typically in older adults.

Management

Lentigines do not have a medical indication for removal. Common cosmetic management techniques include bleaching creams (eg, hydroquinone) and cryotherapy. Prevention is the best approach to solar lentigines with the regular use of sunscreens. The natural history of lentigines is to persist over time and darken with age and sunlight exposure.

Indications for Consultation

Cosmetically bothersome lentigines can be referred for laser and intense pulsed light treatment (monochromatic noncoherent light visible light).

DERMATOFIBROMA (HISTIOCYTOMA)

Clinical Presentation

► History and Physical Examination

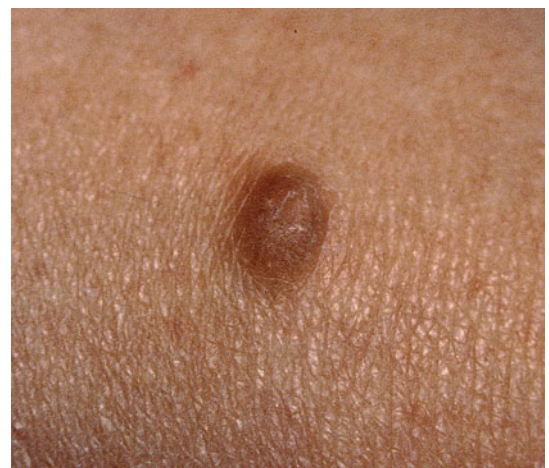Most patients present with concern over a symptomatic “mole.” The classic presentation of a dermatofibroma is a firm 3- to 10-mm papule or nodule on the distal lower extremities that may have an associated increase in pigmentation (Figure 16-5). The etiology of these lesions is not certain, but is thought to be related to a healing process from a minor traumatic event that leads to proliferation of dermal fibroblasts. The pigmentation of these lesions is symmetrical often with a lighter central area and a collaret of darker pigmentation. Horizontal compression, or pinching of the lesion, leads to dimpling due to the deep collagen connection (dimple sign). Dermatofibromas can entrap nerves within the scar leading to sensations of itch or sensitivity.

► Laboratory Findings

Histopathology shows a localized area of spindle cell proliferation of fibroblasts in the dermis.

► Differential Diagnosis

- ✓ **Nevus:** Tan to dark, brown, soft macule or papule. Dimple sign is negative.
- ✓ **Dermatofibrosarcoma protuberans:** Firm nodule similar to a dermatofibroma, but larger in size and has progressive growth with time.
- ✓ **Melanoma:** Flat or raised lesion with variable pigment and irregular borders.



▲ **Figure 16-5.** Dermatofibroma. Tan firm papule.

Management

Treatment options are limited. Intralesional triamcinolone injections and cryotherapy can be used, but may have limited success. Reassurance of the benign nature of the lesions with no treatment is appropriate for asymptomatic lesions. Those lesions with prominent itch or tenderness can be surgically removed with the caveat that the patient is trading the round scar of a dermatofibroma for a linear scar of the excision.

Indications for Consultation

Lesions with continued growth, poorly defined lesions.

Patient Information

British Association of Dermatologists: www.bad.org.uk/site/809/Default.aspx

SKIN TAG (ACROCHORDON, CUTANEOUS PAPILLOMA)

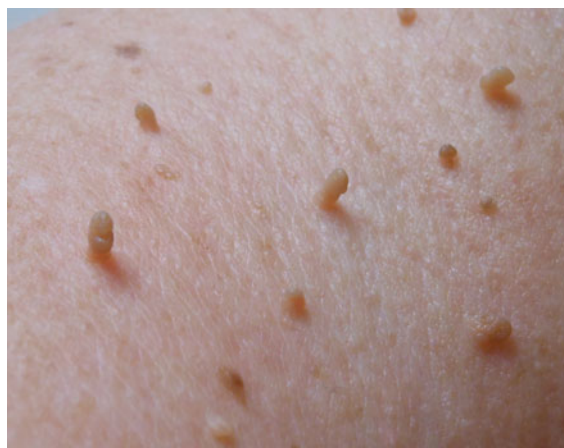Clinical Presentation

History and Physical Examination

Skin tags are very common skin-colored papules with a thin stalk (Figure 16-6). The stalk contains a central blood vessel. They most commonly present in patients in their mid-40s to late 60s in sites of friction such as the neck, axillae, and groin. Weight gain correlates with an increased incidence.

Laboratory Findings

Histopathology shows loose fibrous tissue in the dermis of a polyp with a thin epidermis.



▲ **Figure 16-6.** Skin tags. Polypoid papules.

Differential Diagnosis

- ✓ **Neurotized nevus:** Very similar appearance to skin tags, but presents as single lesion.
- ✓ **Neurofibroma:** May be polypoid, but typically are larger than skin tags, and may present within the context of a genetic syndrome.

Management

Cryotherapy can be useful in treating multiple skin tags, but success is limited to lesions that have a narrow stalk. Broad-based lesions are best treated with thin shave excision. Electrodesiccation and removal with iris scissors can be used for smaller lesions. Any treatment often leaves behind a small hypopigmented macule.

Indications for Consultation

Numerous lesions.

Patient Information

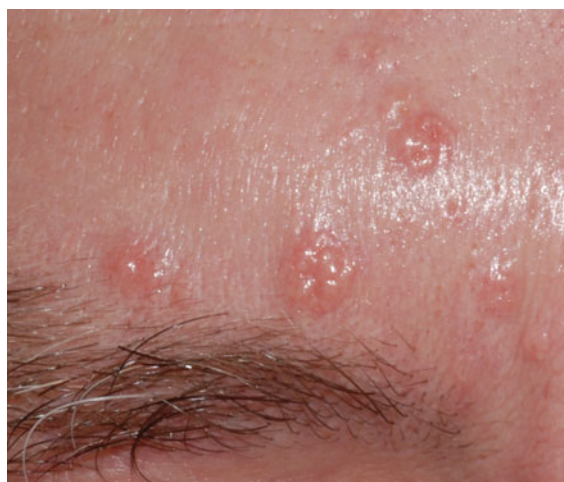PubMed Health: www.ncbi.nlm.nih.gov/pubmedhealth/PMH0001851/

SEBACEOUS HYPERPLASIA

Clinical Presentation

History and Physical Examination

Sebaceous hyperplasia presents as a 2- to 4-mm yellow- to skin-colored papule(s) on the central face and forehead (Figure 16-7). They represent a hyperplasia of sebaceous glands. They often have a central depression.



▲ **Figure 16-7.** Sebaceous hyperplasia. Pink to yellow papules with central depression above eyebrow.

► Laboratory Findings

Histopathology shows hyperplasia of sebaceous glands.

► Differential Diagnosis

- ✓ **Milia:** 1- to 2-mm white cyst with no central depression.
- ✓ **Basal cell carcinoma:** Small basal cell carcinomas, have a similar appearance, but grow continuously.
- ✓ **Acne:** Transient erythematous inflammatory papules lasting less than 2 months.

Management

Lesions that are progressive or show symptoms of tenderness or bleeding should be biopsied to rule out basal cell carcinoma. Observation is sufficient for stable lesions. Cosmetically bothersome lesions can be treated with shave removal with or without electrodesiccation. Electrodesiccation on its own can be used as well for smaller lesions. A small scar is often left after treatment.

Indications for Consultation

Lesions with progressive growth.

LIPOMA

Clinical Presentation

► History and Physical Examination

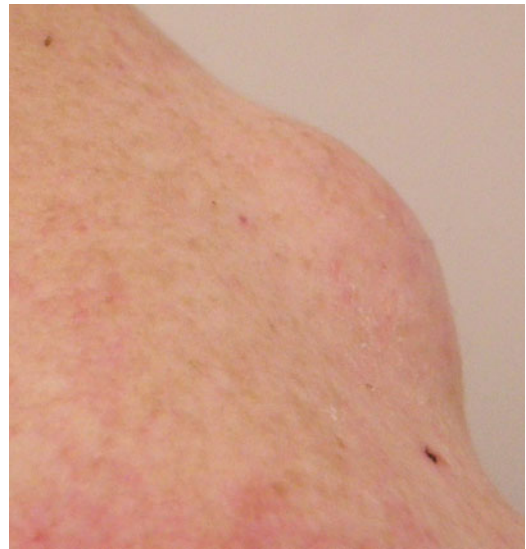
A lipoma represents a localized overgrowth of fat cells. A lipoma often presents as a rubbery nodule in areas of potential inadvertent trauma (Figure 16-8). The tendency to form lipomas appears to run in families and a number of syndromes present with multiple lipomas that may number from a few to hundreds. Lipomas come in two main variants, classic and angiolipoma. The angiolipoma variant clinically is similar to the classic lipoma but may have an associated tenderness. These lesions lead to a deep aching sensation with minor pressure or trauma and can be quite distressing to the patient.

► Laboratory Findings

Histopathology shows adipose tissue surrounded by a fibrous capsule.

► Differential Diagnosis

- ✓ **Liposarcoma:** Similar presentation to a standard lipoma, but much more aggressive history of growth.
- ✓ **Epidermal cyst:** Firm cyst with a central puncta.



▲ **Figure 16-8.** Lipoma. Soft skin-colored nodule on back.

- ✓ **Neurofibroma:** Can present as exophytic skin-colored papules or more rarely, as in this differential, a plexiform subcutaneous mass with a firm consistency.

Management

Options for management include observation or surgical removal.² During surgical excision of a lipoma, the cells that make up the lipoma can often be identified as a cluster of “grape like”, slightly more firm or rubbery fat cells. Classic lipomas have a tendency to have a deeper yellow color than surrounding normal fat cells.

Indications for Consultation

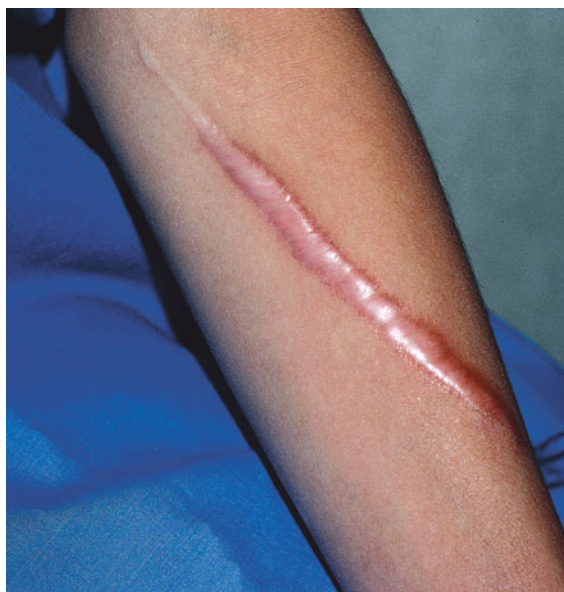Symptomatic or large lesions may be referred for surgical removal.

KELOID/HYPERTROPHIC SCAR

Clinical Presentation

► History and Physical Examination

The terms keloid and hypertrophic scar are often used synonymously. However there is a key difference in these two entities that has major clinical implications. A hypertrophic scar arises in a site of injury and is limited by the borders of the original injury (Figure 16-9). It may be symptomatic and increase in firmness with time but will not extend beyond the border of the original injury.



▲ **Figure 16-9.** Hypertrophic scar. Thick pink scar following laceration on arm.

A keloid scar is not limited by the borders of the original injury and will extend well beyond the wound to form a fibrous mass that greatly exceeds the initial injury region. The threshold for injury that leads to keloid scarring appears to be much lower than that for hypertrophic scarring as well.

► Laboratory Findings

Histopathology is similar for keloids and hypertrophic scars. A keloid shows whorls of fibroblasts in the dermis. Histopathology of a keloid may show thicker bands of collagen in the dermis.

► Differential Diagnosis

- ✓ **Sclerotic basal cell carcinoma:** Very similar appearance, but with progressive growth.
- ✓ **Dermatofibrosarcoma protuberans:** Firm tan nodule with progressive growth.
- ✓ **Foreign body granuloma:** Reactive process at site of injury or previous surgery. Firm nodule with red to brown hyperpigmentation.

Management

Hypertrophic scars will usually improve with time. It may take years, but most scars will become flatter and

less firm, however, their overall dimensions will not change. This process can be expedited with the use of intralesional triamcinolone injections.³ It may take multiple sessions spaced 1 to 2 months apart to achieve the desired reduction, and alleviate symptoms of itch or tenderness. Keloid scars can also be treated in a similar manner but may have a more limited response and are much more likely to reoccur once therapy has been discontinued. Surgical correction of hypertrophic scars is often successful. However any attempt at surgical correction of keloid scarring should be approached with extreme caution. It is often the case that the surgical excision only leads to more extensive damage and larger keloid formation.

Indications for Consultation

Lesions that fail to respond to intralesional steroid therapy may improve with laser therapy.⁴

Patient Information

PubMed Health: www.ncbi.nlm.nih.gov/pubmedhealth/PMH0001852/

EPIDERMAL (EPIDERMOID) CYST

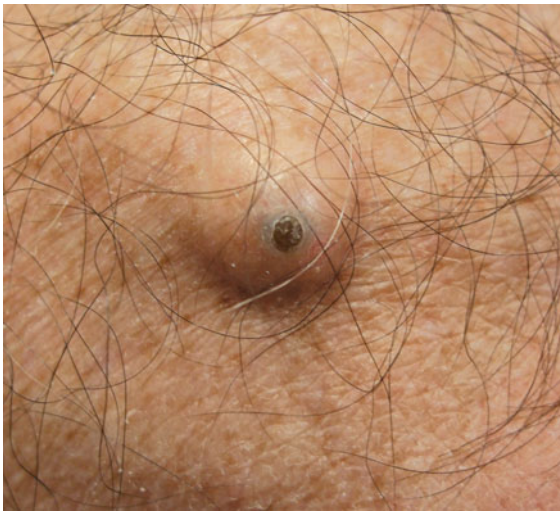Clinical Presentation

► History and Physical Examination

Epidermal (epidermoid) cyst, also sometimes called sebaceous cyst (a misnomer as they have no relationship to sebaceous glands), can occur in almost any area of the body, but are most common on the central trunk and face. They present as a firm skin-colored cyst with a central punctum. These cysts arise from the infundibulum of the hair follicle. These cells form a layer that is very analogous to that of the epidermis. The cells that form the cyst lining are constantly being sloughed into the center of the cyst and undergo degradation leading to soft keratin with a necrotic center. There is often a rudimentary connection to the epidermal surface that presents as an indentation overlying the center of the cyst (Figure 16-10). This connection can be patent and at times may lead to extrusion of cyst contents. A strong odor is usually associated with this soft “cheesy” material. Patients will often complain of “infection” of a cyst, which most likely represents rupture of the cyst contents into the dermis. The keratin content and cellular debris lead to a robust inflammatory reaction with swelling and tenderness as its hallmark.

► Laboratory Findings

Histopathology shows a cyst in the dermis lined with squamous epithelium and filled with keratin.



▲ **Figure 16-10.** Epidermal cyst. Cyst with central punctum.

► Differential Diagnosis

- ✓ **Pilar cyst:** Similar to epidermal cyst, but with no central punctum.
- ✓ **Boil or acne cyst:** More acute and inflammatory.

Management

Postrupture inflammatory reaction can lead to resolution in a limited number of cases. However, the cyst is more likely to recur. Surgical removal is the standard of care, and should be performed when the cyst is not inflamed and is well formed.⁵ Removal of the entire lining of the cyst is critical to minimize the risk for recurrence.

Indications for Consultation

Need for more complex surgical removal, multiple lesions.

Patient Information

PubMed Health: www.ncbi.nlm.nih.gov/pubmedhealth/PMH0001845/

▼ PILAR CYST

Clinical Presentation

► History and Physical Examination

Pilar cysts are relatively common, presenting in approximately 10% of the population as firm nodules that are generally limited to the scalp. They arise from cells in the hair follicle. As with epidermal cysts, the lining of the cyst is the

critical component to the cyst formation. Cells lining the cyst continue to produce keratin, but without connection to a hair. Thus the compact laminate keratin forms a hard sphere within the dermis. The patient may relate a family history of these lesions.

► Laboratory Findings

Similar to epidermal cysts, but with no granular layer in the epidermis.

► Differential Diagnosis

- ✓ **Epidermal cyst:** Very similar, but with no central punctum.

Management

Smaller lesions can be observed as they may not grow. Simple removal of the keratin center will not alleviate further formation or recurrence. As in epidermal cysts, complete removal of the cyst lining is required for successful cure.

Indications for Consultation

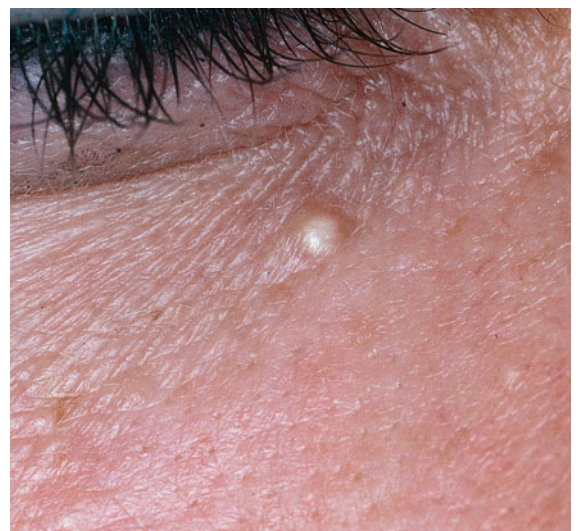Tender enlarging lesions requiring surgical removal.

▼ MILIA

Clinical Presentation

► History and Physical Examination

These small 1- to 2-mm white papules which are commonly found around the eyes and on the upper face (Figure 16-11)



▲ **Figure 16-11.** Milia. A 2-mm white cyst below eye.

and represent a smaller variant of epidermal cyst.⁶ They have similar pathology to epidermal cysts; however, milia are more likely to stay small and less likely to be recurrent after removal. They are more common in infants and will often resolve spontaneously. In adults, they are more likely to be persistent or recurrent.

► Laboratory Findings

Histopathology shows the same findings as an epidermal cyst, but the diameter of the cyst is smaller.

► Differential Diagnosis

- ✓ **Closed comedones:** More common in teenagers and adults with acne.
- ✓ **Syringoma:** Skin-colored to clear papules, 1 to 3 mm in diameter primarily present on the lower eyelids.
- ✓ **Trichoepithelioma:** Multiple skin-colored papules that typically occur in the area of the medial canthus, but may extend onto the eyelids and dorsal nose.

Management

Observation is often best, but the cyst's contents can be extracted by simple thin incision overlying the lesion with a #11 blade. Care should be taken not to go deeper than the keratin contents, less than 1 mm in depth. Careful removal of the cyst wall may be possible through the incision once the keratin contents have been extracted. Care should be taken not to cause undue trauma which will lead to scar formation.

Indications for Consultation

Multiple lesions, enlarging or recurrent lesion for surgical removal.

Patient Information

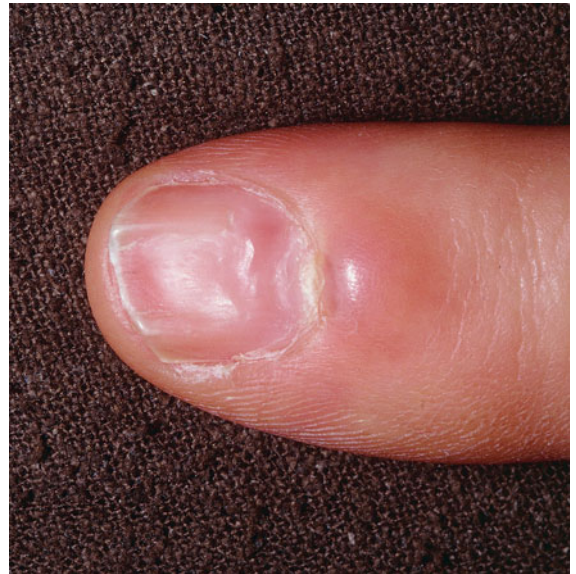PubMed Health: ncbi.nlm.nih.gov/pubmedhealth/PMH0002343/

DIGITAL MUCOUS CYST

Clinical Presentation

► History and Physical Examination

Digital mucous cysts are pseudocysts, because they do not have a cellular lining. They represent an extrusion of contents from a local joint space into the surrounding dermis. They may have a lining that mimics a cell-based lining of a true cyst, but this only represents a compression of cells



▲ **Figure 16-12.** Digital mucous cyst. Translucent cyst overlying the proximal matrix of the nail producing a groove in the nail plate.

within the dermis to the margin of the extruded contents. They most commonly present as a translucent skin-colored cyst on the distal aspect of a digit of the hand either overlying the proximal matrix of the nail or underlying the nail bed (Figure 16-12). They may cause distortion of nail formation due to pressure exerted on the matrix of the nail.⁷ As the nail plate grows distally it maintains the shape of the distended matrix.

► Laboratory Findings

Histopathology shows a focal area of mucin in the dermis.

► Differential Diagnosis

- ✓ **Glomus tumor:** Rare benign bluish, neoplasm, usually solitary, around or often under the fingernail plate. It is one of the painful tumors of the skin.
- ✓ **Osteoma:** Solid, non-compressible nodule that most often develops in a site of previous trauma.

Management

These lesions will often resolve after rupture of the cyst, but may recur. Extrusion of cyst contents can alleviate pressure on the matrix and pain.⁷ Treatment of the sinus tract with cautery or ligation leads to a greater rate of success with less recurrence.

Indications for Consultation

Multiple lesions, recurrent lesions for surgical excision.

Patient Information

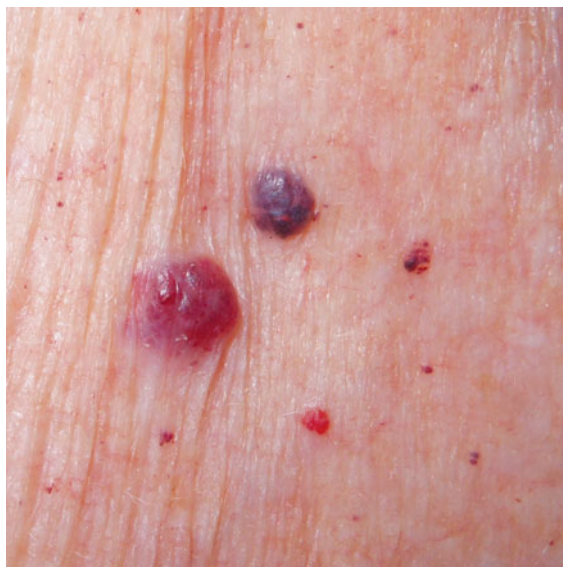British Association of Dermatologists: www.bad.org.uk/site/1248/default.aspx

ACQUIRED VASCULAR LESIONS (CHERRY HEMANGIOMA, VENOUS LAKE, SPIDER ANGIOMA)

Clinical Presentation

History and Physical Examination

These 3 vascular lesions are given names according to the site of presentation and extension above the surface. (1) Cherry angiomas which present as small bright red papules on the trunk are the most common (Figure 16-13). They have a strong family tendency with presentation in the late 30s and increase in number through the 40s and 50s. (2) A venous lake is a deeper lesion localized to the lower lip. These lesions represent dilation of the venules of the lip. Due to the depth of these lesions they are often misdiagnosed as a pigmented lesion, with the patient presenting with a concern for melanoma. (3) Spider angiomas are small macular lesions on the face that present with a central feeder vessel and peripheral dilated vessels (Figure 24-12). These lesions will blanch with pressure,



▲ **Figure 16-13.** Cherry angiomas. Red to purple papules.

which can be readily observed with pressure under a glass slide.

Laboratory Findings

Histopathology shows dilated capillaries in the dermis.

Differential Diagnosis

- ✓ **Traumatic blister:** Transient, resolves within days to weeks.
- ✓ **Melanocytic lesion:** A dark purple cherry angioma or venous lake may appear to be black and mimic nevi. However their underlying color is revealed when pressed with a glass slide or with the use of dermoscopy.

Management

Once diagnosed, no treatment is required. However some lesions will be treated either due to inadvertent trauma leading to bleeding or for cosmetic purposes. Pulsed dye laser (PDL) therapy can lead to resolution of most lesions. Larger lesions on the trunk respond better to shave removal with cautery of the underlying vessels. For lesions of the central face, PDL therapy or fine needle cautery of central feeder vessel will lead to resolution.

Indications for Consultation

Lesions in frictional sites that sustain trauma leading to tenderness or bleeding. Cosmetic treatment.

Patient Information

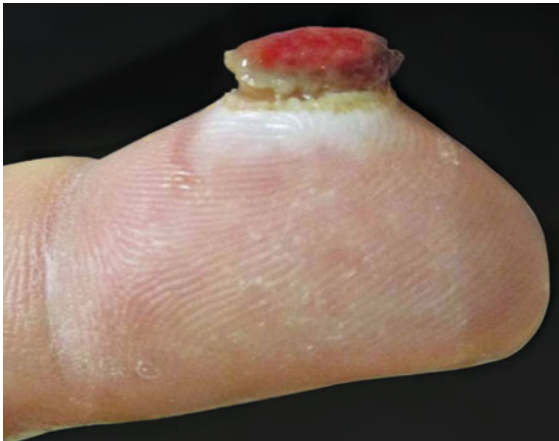
Cherry angioma; PubMed Health: www.nlm.nih.gov/pubmedhealth/PMH0002413/

PYOGENIC GRANULOMA

Clinical Presentation

History and Physical Examination

Most often a pyogenic granuloma presents as a quickly growing sessile red to purple exophytic papule that bleeds with minimal trauma (Figure 16-14). The term pyogenic granuloma is a misnomer since the growth does not represent a granuloma and it is not related to infection. The lesions tend to evolve in presentation from a small erythematous papule to an exophytic nodule up to 2 cm in diameter over a few weeks. They are most common on the head, neck, and extremities. A subset also present in the oral mucosa. Lesions typically occur in young adults and with pregnancy.



▲ **Figure 16-14.** Pyogenic granuloma. Exophytic bright red papule with rim of thickened skin on finger.

► Laboratory Findings

Histopathology shows proliferation of capillaries in the dermis.

► Differential Diagnosis

- ✓ **Infantile hemangioma:** Table 16-1.
- ✓ **Squamous cell carcinoma:** May present as a similar growth in older adults, but is not usually exophytic.
- ✓ **Other:** metastatic carcinoma of the skin.
- ✓ Glomus tumor.

Treatment

Surgical excision is indicated as these lesions have a high tendency for bleeding that is difficult to control. Shave

removal with cautery of the base may be sufficient. Deeper excision may be required for recurrent lesions.

Indications for Consultation

Surgical excision, recurrent lesions.

Patient Information

PubMed Health: www.ncbi.nlm.nih.gov/pubmedhealth/PMH0002435/

▼ VASCULAR LESIONS IN INFANTS

In general vascular lesions present with a violaceous to purple color, but dark purple hues can also be seen and mistaken for melanin pigment. Lesions may present at birth or develop soon thereafter, or may be acquired later in life. Differentiating between these tumors can be difficult even for the experienced clinician.

▼ VASCULAR MALFORMATION (PORT-WINE STAIN, STORK BITE, ANGEL KISS)

Clinical Presentation

► History and Physical Examination

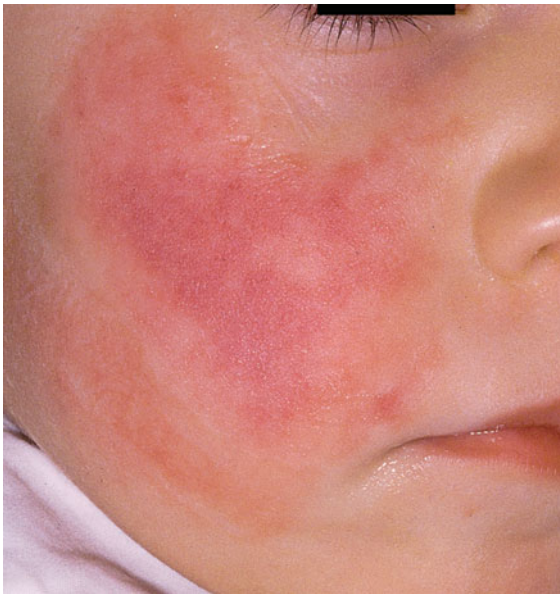A vascular malformation is the most common vascular lesion of infancy and is present in greater than one-third of infants. The most common presentation is a focal area of macular erythema on the posterior neck or mid-forehead (stork bite or angel kiss) that fades within the first year of life, but can still be evident with physical exertion including crying.

A congenital capillary malformation is more persistent and forms a nevus flammeus (port-wine stain). These lesions enlarge over many years rather than months and do not have a natural involution phase. These lesions often start with an erythematous patch (Figure 16-15), or slightly raised plaque that evolves to become more exophytic and

Table 16-1. Vascular lesions of infants.

Vascular Disorder	Identifying Features	Age at Presentation and Course
Vascular malformation	Often presents with a dark pink to purple patch. Lesions of concern develop a deeper nodularity	Erythema may be present at birth which accentuates with exertion (crying), variable slow progression in thickness and extent. Port-wine stain variant does not involute
Infantile hemangioma	Soft red to purple plaque or nodule. GLUT-1 stain is positive	Rarely present at birth, undergoes a growth phase in first 6–12 months, prior to slow involution
Congenital hemangioma (RICH or NICH)	Uncommon, soft red to purple plaque or nodule	Fully formed at birth. RICH involute in 12–14 months; NICH do not involute

GLUT, Glucose transporter-1; NICH, noninvoluting congenital hemangiomas; RICH, rapidly involuting congenital hemangiomas.



▲ **Figure 16-15.** Port-wine stain. Erythematous patch on cheek.

forms vascular blebs over time. There are a number of syndromes that are associated with port-wine stains such as Sturge–Weber syndrome which presents with a port-wine stain in the trigeminal nerve distribution and may be accompanied by seizures or glaucoma. Larger vascular malformations on the extremities are associated with Klippel–Trenaunay and Parkes Weber syndromes.⁸

► Laboratory Findings

Histopathology shows dilated capillaries in the dermis with no proliferation of endothelial cells. Vascular malformations can be subdivided into capillary, venous, arterial or lymphatic or combinations of these structures.

► Differential Diagnosis

✓ See Table 16-1.

Treatment

The skin manifestations of a port-wine stain can be treated with pulse dye light therapy. Multiple sessions are required as the laser can only penetrate to a limited depth. Early treatment is advised by some clinicians. Recurrence is common, but may respond to additional treatments in a similar manner.

Indications for Consultation

Large lesions with potential for underlying hamartomatous growth and lesions on the face.

Patient Information

Vascular Birthmarks Foundation: www.birthmark.org/node/23

INFANTILE HEMANGIOMA (SUPERFICIAL, MIXED OR DEEP)

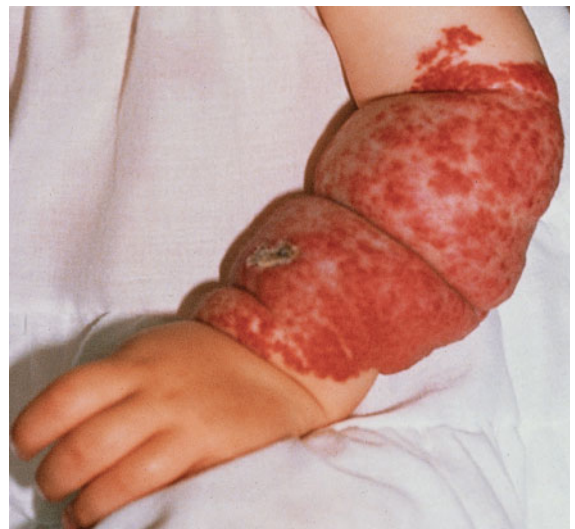Clinical Presentation

► History and Physical Examination

Approximately 2% of live births will have a form of hemangioma. This increases to approximately 10% by 1 year of age. There is an up to 3-fold risk for female infants.⁹ Infantile hemangiomas are not usually present at birth, but early signs of their development such as pallor, or telangiectatic macules may be present in up to 50% of infants who go on to have an infantile hemangioma. At its peak size an infantile hemangioma typically presents as nodule which typically is 1 to 8 cm, but may range from pinpoint size to greater than 25 cm in diameter (Figure 16-16). The natural history for infantile hemangiomas is a period of growth followed by a drawn out involution phase. The growth phase is usually complete by 1 year of age. The involution phase is variable and can last between 2 and 10 years or greater. As the tumor resolves it develops a white-grey area and may ulcerate.

► Laboratory Findings

An infantile hemangioma is a vascular tumor, as it demonstrates cellular hyperplasia. While biopsy is not indicated,



▲ **Figure 16-16.** Infantile hemangioma. Large erythematous superficial and deep mass with grey areas of resolution and superficial ulceration on arm.

these lesions can be differentiated from congenital hemangiomas by positive staining for transporter-1 (GLUT-1). Histopathology shows proliferation of endothelial cells in the dermis and/or subcutaneous region.

► Differential Diagnosis

- ✓ Vascular malformation (Table 16-1).
- ✓ Lipoma—see above.
- ✓ Pyogenic granuloma—see below.

Management

In the past, patient observation was the rule. However, particular attention needs to be paid to lesions involving cosmetically sensitive areas or areas that may cause disruption of normal development or anatomy. These sites include the nasal tip, periorbital region, ears, lips, genitalia, airway, or beard distribution.¹⁰ Also treatment is recommended for ulcerating lesions. Historically, treatment when indicated was limited to topical or oral steroids with the adjuvant use of pulsed dye laser (PDL) therapy.¹¹ Recently it has been discovered that these lesions respond remarkably well to oral administration of propranolol.¹² This should only be attempted by a very experienced clinician in a controlled setting as this treatment can lead to hypoglycemia¹³ and bradycardia. PDL therapy is still indicated in ulcerative lesions or thin cosmetic lesions.

Indications for Consultation

Lesions in cosmetic or structurally sensitive areas of the nasal tip, lips, visual field, or beard region. Lesions in the groin have a higher incidence of ulceration and pain that warrants referral.

Patient Information

Vascular Birthmarks Foundation: www.birthmark.org/node/24

CONGENITAL HEMANGIOMA

Clinical Presentation

► History and Physical Examination

These uncommon vascular lesions are fully formed at birth. These lesions are designated as rapidly involuting congenital hemangiomas (RICH) or noninvoluting congenital hemangiomas (NICH) depending on their subsequent history.¹⁴ RICH are present at birth and undergo rapid involution early in life, often completed by 12 to 14 months.

They may leave behind atrophy of the dermis and subcutaneous tissue. NICH are also referred to as nonprogressive hemangiomas. In contrast to RICH, these lesions do not undergo involution. These two entities generally are difficult to differentiate at birth. NICH often show a peripheral rim of pallor with more prominent surface telangiectasia when compared to RICH.

► Laboratory Findings

Histopathology shows proliferation of endothelial cells in the dermis and/or subcutaneous region.

► Differential Diagnosis

- ✓ See Table 16-1.

Management

Cautious observation for the first 18 months. Surgical removal may be indicated for NICH at about age 6.

Indications for Consultation

Evaluation of structural or cosmetically sensitive sites. Surgical treatment.

REFERENCES

1. Stankiewicz K, Chuang G, Avram M. Lentigines, laser, and melanoma: a case series and discussion. *Lasers Surg Med.* 2012;44(2):112–116. PMID: 22334294.
2. Salam GA. Lipoma excision. *Am Fam Physician.* 2002;65(5):901–904. PMID: 11898962.
3. Juckett G, Hartman Adams H. Management of keloids and hypertrophic scars. *Am Fam Physician.* 2009;80(3):253–260. PMID: 19621835.
4. Bouzari N, Davis SC, Nouri K. Laser treatment of keloids and hypertrophic scars. *Int J Dermatol.* 2007;46(1):80–88. PMID: 17214728.
5. Zuber TJ. Minimal excision technique for epidermoid (sebaceous) cysts. *Am Fam Physician.* 2002;65(7):1409–12, 1417. PMID: 11996426.
6. Berk DR, Bayliss SJ. Milia: a review and classification. *J Am Acad Dermatol.* 2008;59(6):1050–1063. PMID: 18819726.
7. Zuber TJ. Office management of digital mucous cysts. *Am Fam Physician.* 2001;64(12):1987–1990. PMID: 11775765.
8. Melancon JM, Dohil MA, Eichenfield LF. Facial port-wine stain: when to worry? *Pediatr Dermatol.* 2012;29(1):131–133. PMID: 22256997.
9. Haggstrom AN, Drolet BA, Baselga E, et al. Prospective study of infantile hemangiomas: demographic, prenatal, and perinatal characteristics. *J Pediatr.* 2007;150(3):291–294. PMID: 17307549.
10. Frieden IJ, Eichenfield LF, Esterly NB, Geronemus R, Mallory SB. Guidelines of care for hemangiomas of infancy. American Academy of Dermatology Guidelines/Outcomes Committee. *J Am Acad Dermatol.* 1997;37(4):631–637. PMID: 9344205.

11. Poetke M, Philipp C, Berlien HP. Flashlamp-pumped pulsed dye laser for hemangiomas in infancy: treatment of superficial vs mixed hemangiomas. *Arch Dermatol*. 2000;136(5):628–632. PMID: 10815856.
12. Price CJ, Lattouf C, Baum B, et al. Propranolol vs corticosteroids for infantile hemangiomas: a multicenter retrospective analysis. *Arch Dermatol*. 2011;147(12):1371–1376. PMID: 21844428.
13. Holland KE, Frieden IJ, Frommelt PC, et al. Hypoglycemia in children taking propranolol for the treatment of infantile hemangioma. *Arch Dermatol*. 2010;146(7):775–778. PMID: 20644039.
14. Krol A, MacArthur CJ. Congenital hemangiomas: rapidly involuting and noninvoluting congenital hemangiomas. *Arch Facial Plastic Surg*. 2005;7(5):307–311. PMID: 16172338.

17

Actinic Keratosis, Basal, and Squamous Cell Carcinoma

Peter K. Lee

Introduction to Chapter / 154
Actinic Keratosis / 154
Basal Cell Carcinoma / 156

Squamous Cell Carcinoma / 159
References / 162

INTRODUCTION TO CHAPTER

Actinic keratoses (AKs) are one of the most common skin findings in dermatology. AKs are benign neoplasms of the epidermis and are considered precursor lesions to non-melanoma skin cancers. They are very common in sun-exposed areas of the skin, especially in the elderly patient. Ultraviolet light exposure is the main cause of AKs.

Basal cell carcinomas (BCCs) and squamous cell carcinomas (SCCs) are the most common types of skin cancers and the most common cancers in the United States.¹ Both are commonly seen in sun-exposed areas of the skin and are readily treatable if detected early. BCCs are the most common type of skin cancer and rarely metastasize. SCCs are the second most common skin cancer and can metastasize to regional lymph nodes if not treated early. Sun avoidance, use of proper clothing and sun screens, and routine examinations are important for prevention of nonmelanoma skin cancers.

ACTINIC KERATOSIS

Introduction

Actinic keratoses (AKs) are precancerous lesions of the keratinocytes and are very common in the elderly Caucasian population. They typically occur on sun-exposed areas such as the head and neck areas, as well as the distal extremities. Ultraviolet (UV) light exposure is the most common cause of AKs, with a genetic predisposition

also being important. An AK is a precursor lesion to SCC and should be treated with appropriate therapy.²

Pathophysiology

Actinic keratoses develop after intense or long-term exposure to UV light (natural or artificial). Chronic sun exposure may lead to p53 tumor suppressor gene mutation of individual keratinocytes in the epidermis.² The same genetic mutations are seen in AKs and SCCs. The mutations will lead to propagation of the abnormal keratinocytes leading to faster division of these cells and development of a clinically visible lesion. If left untreated, approximately 10% of actinic keratosis may become SCCs.

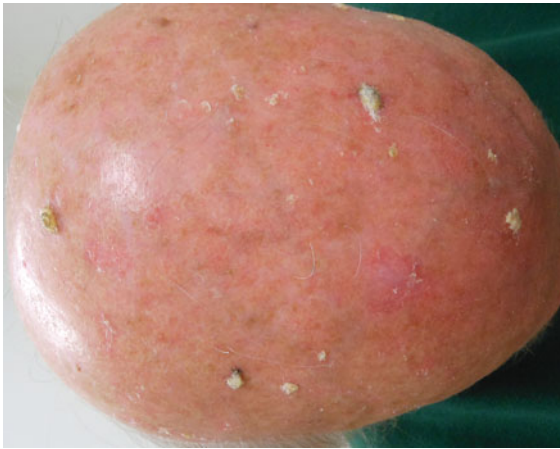Clinical Presentation

History

Patients typically complain of a scaly rough lesion(s) on frequently sun-exposed areas such as the face, scalp, and ears. Dorsal hands and forearms in men and lower legs in women are also commonly affected areas. The lesions usually do not have any symptoms such as itching or pain. Patients often try to scratch off the overlying crust, only to have the scaly surface reform.

Physical Examination

Actinic keratoses can present as a solitary lesion or as a larger, diffuse plaque. Solitary lesions often appear as an



▲ **Figure 17-1.** Actinic keratoses. Hypertrophic and plaque-type actinic keratoses on scalp.

ill-defined, scaly, rough, red plaque that is approximately 3 to 6 mm in diameter. The lesions can be slightly sensitive to touch. Solitary AKs can also present as a more keratotic papule with a thicker stratum corneum above the base of the lesion (Figure 17-1). This type of a lesion can resemble a cutaneous horn and is frequently referred to as a hypertrophic actinic keratosis. The plaque-type AKs are very common in chronically sun-exposed areas such as the scalp in balding men. These lesions are very ill-defined and seemingly appear to involve a larger area. They are also scaly and rough feeling and can be associated with subclinical SCCs.

► Laboratory Findings

Histopathology of AKs exhibits partial thickness atypia of the epidermis of the skin. The abnormal keratinocytes may also involve the appendageal structures of the skin such as hair follicles. These lesions are described histologically as “actinic keratoses with appendageal involvement” and may need more aggressive and deeper penetrating treatments to reach the involved appendages or follicular structures.

Diagnosis

Actinic keratoses typically present as hyperkeratotic papules or as a scaly red plaque(s) in chronically sun-exposed areas of the face, scalp, ears, and dorsal hands and arms. They have a rough, gritty surface.

► Differential Diagnosis

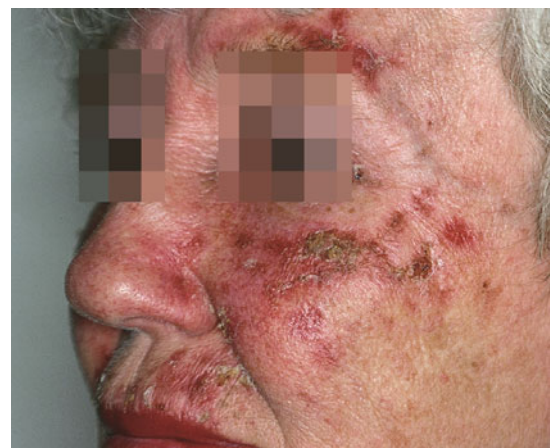- ✓ **Seborrheic keratosis:** Presents as tan or brown well-defined papule or plaque without a gritty surface.
- ✓ **Viral wart:** Presents as a hyperkeratotic papule often with black dots representing thrombosed blood vessels.

- ✓ **SCC:** Presents as a larger more indurated lesion. A skin biopsy may be needed to differentiate these lesions if the clinical exam is not diagnostic.

Management

There are many available options for treatment of actinic keratosis. These treatment modalities are often combined to offer the patients the most effective treatment options.

- **Cryotherapy** (Chapter 7) is the most commonly used treatment for AKs.³ Liquid nitrogen is applied to the lesions using a spray dispenser or a cotton applicator until a 1- to 2-mm rim of frost develops around the actinic keratosis. This method may lead to blister formation in the lesions and surrounding skin. The blister heals and desquamates with resolution of the AKs.
- **Field therapy** is used for more diffuse and numerous AKs. Several topical creams are available. 5-Fluorouracil (5-FU) (eg, Efudex, Carac) is a topical cream that has been available for decades and is commonly used for treatment of widespread lesions. 5-FU is a pyrimidine analog and incorporates into DNA and RNA of keratinocytes, leading to cell death and inflammation.⁴ Another common topical treatment is imiquimod (eg, Aldara) that works by stimulating T lymphocytes against the abnormal keratinocytes.³ In 2012 ingenol mebutate (Picato) was approved for actinic keratosis. This medication causes necrosis of AKs within 2 to 3 days of use.⁵ All topical field therapies caused intense inflammation in the treated sites (Figure 17-2).³



▲ **Figure 17-2.** Actinic keratoses after 4 weeks of treatment with 5-fluorouracil cream. Typical response to treatment with erythema, crust, and erosions in treated areas on the face.

- **Photodynamic therapy (PDT)** has gained greater popularity for treatment of AKs. In PDT, a chemical such as aminolevulinic acid is applied to the AKs and with exposure to light of the proper wavelength, the molecule is converted into protoporphyrin IX, a powerful photosensitizer, inside the abnormal keratinocyte. An energy-rich singlet oxygen species is generated causing membrane disruption and cell death.⁶

If an AK does not resolve or recurs after treatment, a biopsy may be indicated to rule out an underlying SCC or BCC.

Sunscreen with SPF 30 or greater should be applied to all areas not covered by hats or clothing.

Indication for Consultation

Actinic keratosis that involve a large surface area or that do not respond to therapy should be referred to dermatology for field treatment options such as topical treatments and/or PDT.

Patient Information

- American Academy of Dermatology: www.aad.org/skin-conditions/dermatology-a-to-z/actinic-keratosis
- PubMed Health: www.ncbi.nlm.nih.gov/pubmedhealth/PMH0001830/

BASAL CELL CARCINOMA

Introduction

Basal cell carcinoma (BCC) is by far the most common type of cancer and skin cancer in the United States. It is estimated that there are 1.2 to 1.5 million new cases each year in the United States with incidence rising annually.¹ Fortunately, these are slow-growing, localized tumors with only rare metastatic potential. BCCs are more common in the elderly Caucasian population, but can be seen in the younger age group including patients in their twenties and thirties. Intense sun exposure or artificial UV light especially prior to age 18 is the primary cause of BCCs with family history and light-colored skin, hair, and eyes being important risk factors. Although less common, BCCs can appear in non-Caucasian patients.

Pathophysiology

Basal cell carcinomas are cancers of the epidermal keratinocytes of the hair follicles and the epidermis. They develop after intense or chronic UV light exposure. Ionizing radiation from therapeutic radiation therapy can also promote development of BCCs. Exposure to intense UV light leads to DNA mutation in the tumor suppressor genes of the sonic hedgehog pathway in keratinocytes. Mutations in the

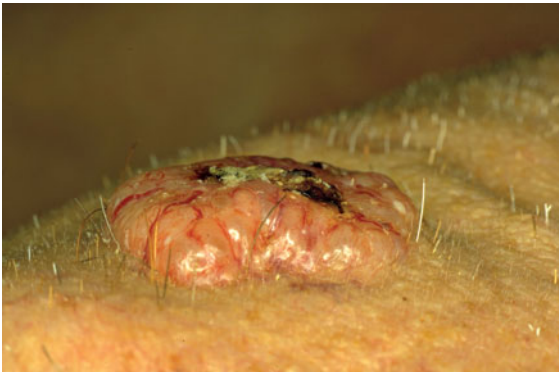PTCH (patched) gene and in the tumor suppressor gene, p53 gene, are also important in the development of BCCs.² Patients with basal cell nevus syndrome (Gorlin's syndrome) develop hundreds of BCCs due to a genetic mutation in the sonic hedgehog pathway.

Clinical Presentation

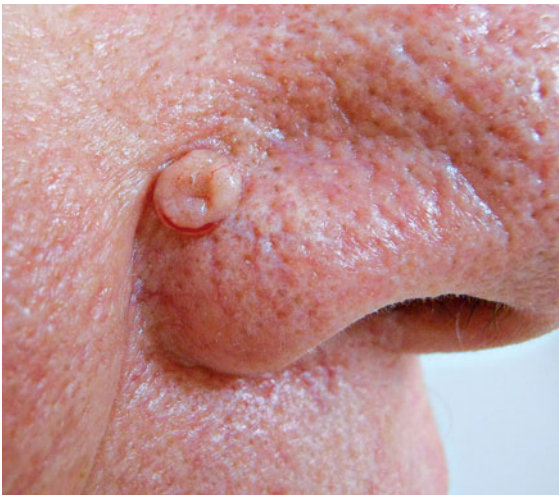History and Physical Examination

There are several types of BCCs, thus, the history and clinical presentations can vary depending upon the subtype. BCCs most commonly occur on frequently sun-exposed areas such as the head and neck.

- **Nodular basal cell carcinoma:** Nodular BCC is the most common type subtype of BCCs. Patients often complain of a pimple-like lesion that does not heal or heals and then bleeds again. The lesions are often sore when touched or scratched. They typically appear as a translucent pearly papule with erythema, telangiectasia, and well-defined rolled borders most commonly on the head and neck region, especially the central face (Figure 17-3A and B). As the tumor grows, the center of the tumor often ulcerates creating a crater-like appearance. Thus, these lesions have been referred to as a “rodent ulcer” in the past. Occasionally, a nodular BCC can be pigmented giving an appearance of a melanoma or suspicious pigmented lesion (Figure 17-4).
- **Superficial basal cell carcinoma:** This is the second most common subtype of BCC. Patients often complain of a chronic area of “eczema.” The lesions may be pruritic or sensitive to touch, but they typically do not bleed. These lesions appear as an erythematous patch or flat topped plaque with well-defined borders typically on the head and neck area, but also commonly appear on the trunk or extremities (Figure 17-5). They are often misdiagnosed and treated as eczema or psoriasis. Unlike nodular, superficial BCCs lack the translucent and telangiectatic appearance, but can have a slightly raised, rolled border.
- **Sclerotic/morpheaform basal cell carcinomas:** This is the most aggressive subtype of BCC. Patients often complain of a chronic “scar” or the lesion goes unnoticed for years. Clinically, they appear as a scar-like plaque (Figure 17-6) that often lacks other features of nodular or superficial BCCs. Therefore, they can grow to be a large and deep tumor before clinical detection. Morpheaform BCCs can be slightly erythematous, but can also be lighter colored than the surrounding normal skin. The borders are very ill-defined making the diagnosis and treatment more difficult. They typically affect the head and neck region, but can appear anywhere on the body. Recurrent BCCs from a previously treated BCCs can often develop into sclerotic and morpheaform BCCs.



A



B

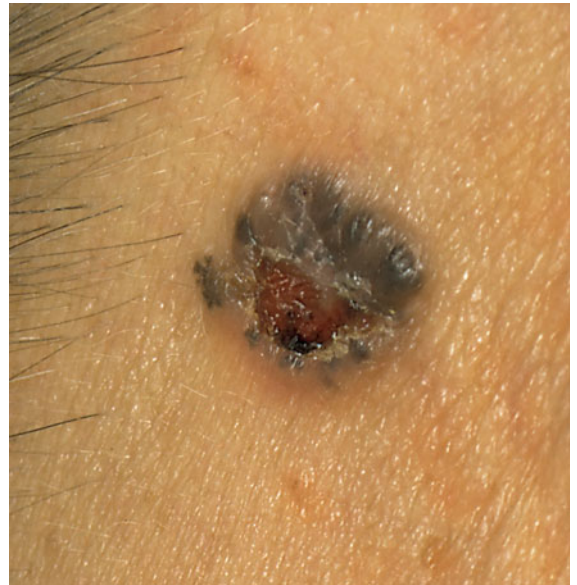▲ **Figure 17-3.** (A, B) Nodular basal cell carcinoma. Papule with shiny, translucent, “pearly” surface, telangiectasia, and well-defined borders. Superficial erosion with crust is seen in (A).

► Laboratory Findings

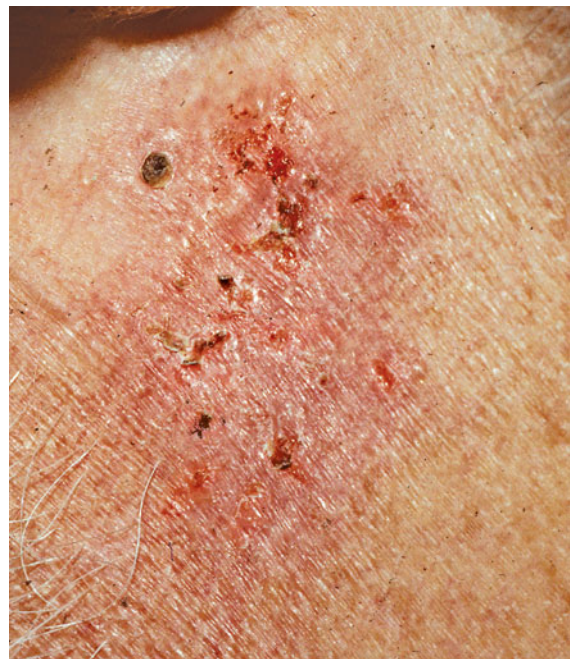The histopathology of a nodular BCC shows aggregates of basophilic, uniform, hyperchromatic cells clumped together in nests in the dermis and subcutis; in a superficial BCC the nests are superficial with limited dermal invasion. In sclerotic/morpheaform BCCs, the cells appear in an infiltrative and poorly differentiated pattern with only a few cell layers that resemble more of a scar than a typical BCC.

Diagnosis

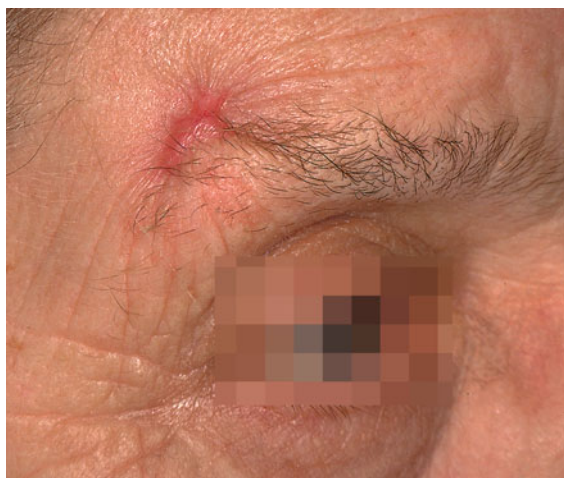The most common presentation of a nodular BCC is a pearly shiny papule with telangiectasia. A superficial BCC presents as a flat erythematous patch or plaque. A sclerotic BCC resembles a scar with very ill-defined borders.



▲ **Figure 17-4.** Pigmented nodular basal cell carcinoma. Grey-black papule with erosion giving the appearance of a melanocytic lesion.



▲ **Figure 17-5.** Superficial basal cell carcinoma. Erythematous plaque with erosions and slightly raised border.



▲ **Figure 17-6.** Sclerotic basal cell carcinoma. Scar-like plaque above eyebrow.

► Differential Diagnosis

For nodular BCC

- ✓ **Intradermal nevus:** Presents as a well-circumscribed skin-colored papule without telangiectasia or pearly surface.
- ✓ **Inflamed seborrheic keratosis:** Presents as a red-dish scaly papule that can be shiny, but lacks the telangiectasia.
- ✓ **SCC:** Tends to be more of a keratotic red papule.
- ✓ **Melanoma or dysplastic nevus:** Pigmented nodular BCCs may have very dark pigmentation that closely mimics a melanocytic lesion.

For superficial BCC

- ✓ **Large actinic keratosis:** Tends to be more scaly or keratotic and less contiguous.
- ✓ **SCC in situ:** Similar to an actinic keratosis, tends to be more keratotic or scaly.
- ✓ **Dermatitis:** Should respond to topical steroids.

For sclerotic/morpheaform BCC

- ✓ **Scar:** Scars have well-defined borders while a sclerotic BCC typically has ill-defined borders.

Management

Treatment of BCCs can vary depending on multiple factors including the BCC subtype, location, previous treatment, size, and the patient's overall health.

► Standard Excision

A BCC can be excised in a fusiform or elliptical technique. The tumor is identified and excised with the recommended 4 mm margins. The specimen is sent to pathology for processing and evaluation of margins and the defect is reconstructed. Vertical sectioning is performed, therefore not all of the margins are evaluated. The cure rate for standard excisions is 90% to 95% using 4 mm margins. This is a common and effective method for treatment of basal cell skin cancers of the trunk and extremities where tissue sparing is not as critical.⁷

► Electrodesiccation and Curettage

In this procedure, the tumor is curetted aggressively and then treated with electrodesiccation. For a proper technique, this cycle is repeated three times. This is an effective treatment for treatment of superficial BCC where the tumor is superficially located. The cure rate for electrodesiccation and curettage treatment of BCCs is near 90%. This technique can be used for nodular BCCs if the tumor is small and well defined. It is not recommended for treatment of sclerotic or morpheaform BCCs.⁷

► Mohs Micrographic Surgery

Mohs Micrographic Surgery (MMS) is the most effective method of treatment of BCCs.⁷ In MMS, the dermatologic surgeon acts as the surgeon and the pathologist. The tumor is excised with narrow (1 to 2 mm) margins and is processed using the Mohs-specific horizontal frozen technique. This allows for visualization of the complete deep and lateral margins of a single section on a glass slide. The specimen is stained using hematoxylin and eosin, then examined carefully for any evidence of tumor. If tumor is present at a margin, the Mohs surgeon will remove further tissue only in the direction of where the tumor is present. Once the tumor has been successfully removed, the defect can be reconstructed safely knowing that the margins are clear.

This rapid and efficient method of tumor removal has the highest cure rate (nearly 99%) for treatment of BCCs. Mohs micrographic surgery is most commonly used for following indications as listed in Table 17-1.^{8,9}

► Topical Treatments

Imiquimod has been reported to be effective in the treatment of some types of BCCs. In the United States, imiquimod and 5% topical fluorouracil are approved for treatment of superficial BCCs. This is an option for patients not willing or unable to undergo a surgical procedure.⁷

► Photodynamic Therapy

PDT is approved for treatment of BCC in Europe and Australia, but not in the United States. However, PDT is

Table 17-1. Most common indications for Mohs micrographic surgery in basal and squamous cell carcinomas.

- Tumor in high-risk areas such as the face and genitalia
- Aggressive histologic subtypes such as morpheaform basal cell carcinoma or infiltrative or spindle cell squamous cell carcinomas
- Tumors with perineural invasion
- Incompletely excised tumors
- Recurrent tumors
- Large (>2 cm diameter) tumors
- Tumors with clinically indeterminate margins
- Tumors in immunocompromised patients

becoming more widely used for treatment of superficial BCC on the trunk and extremities.⁷

► Systemic Therapy

Oral vismodegib (Erivedge), a Hedgehog pathway inhibitor, was approved in 2012 for patients with metastatic BCC or locally advanced BCC that has recurred following surgery, or who are not candidates for surgery or radiation therapy.¹⁰

Indications for Consultation

The majority of BCC are treated by dermatologists and dermatologic surgeons in the United States. Once the diagnosis of BCC has been confirmed, the patient should be referred to an appropriate specialist for the definitive treatment unless the primary care provider has previous experience and adequate knowledge of these tumors and treatments.

Patient Information

- American Academy of Dermatology: www.aad.org/skin-conditions/dermatology-a-to-z/basal-cell-carcinoma
- Skin Cancer Foundation: www.skincancer.org/skin-cancer-information/basal-cell-carcinoma
- PubMed Health: www.ncbi.nlm.nih.gov/pubmedhealth/PMH0001827/

SQUAMOUS CELL CARCINOMA

Introduction

Cutaneous squamous cell carcinoma (SCC) is the second most common skin cancer after BCC with over 400,000 new cases annually in the United States. Generally, the incidence ratio of BCCs over SCCs is 4:1. However, this ratio is reversed in solid organ transplant patients where SCCs are more common than BCCs by a 4:1 ratio.² Unlike BCCs, SCCs have the potential for local and distant metastasis. UV exposure is the most common cause of SCC.

Pathophysiology

SCCs are malignant tumors of epidermal keratinocytes. AKs are often precursor lesions for SCC. Intense UV exposure or cumulative UV DNA damage may lead to p53 tumor suppressor gene mutations and development of AKs and ultimately SCC.¹¹ Other factors that have been associated with SCC development include human papillomavirus (HPV), burns and scars, ionizing radiation, chronic inflammation, arsenic exposure, and tobacco use. Certain genetic syndromes can also promote SCC development, including xeroderma pigmentosum, oculocutaneous albinism, and dystrophic epidermolysis bullosa.¹¹

Clinical Presentation

► History and Physical Examination

As with BCCs, patients may complain of a wart or pimple-like lesion on sun-exposed skin that grows slowly with episodes of bleeding and tenderness. Most SCCs occur on sun-exposed areas such as the face, scalp in balding men, dorsal hands and forearms, and lower legs especially in women. SCCs commonly arise from an area of extensive photodamage with diffuse AK. They typically resemble wart-like lesions that occasionally bleed and are tender to the touch.

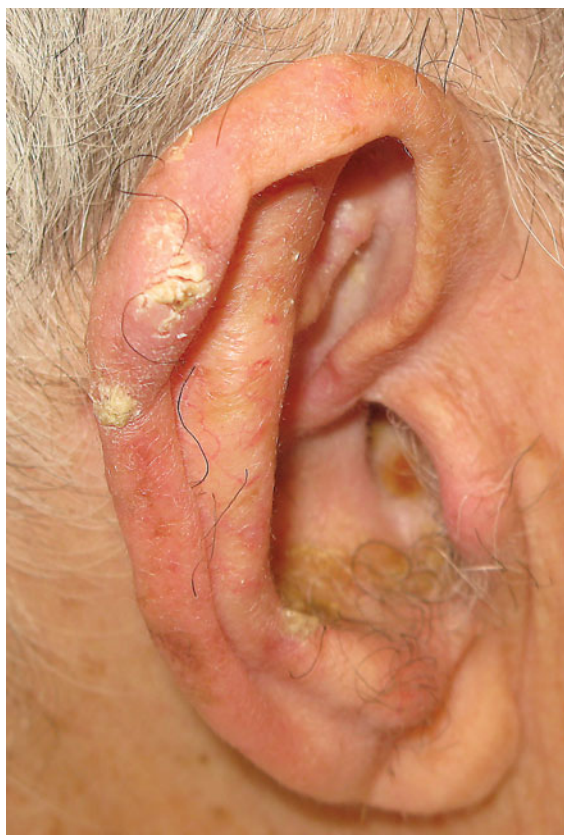There are several subtypes of SCC:¹¹

Squamous cell carcinoma in situ is limited to the epidermal layer without dermal invasion. Unlike an actinic keratosis that has partial thickness atypia, SCC in situ has full thickness atypia and often is described as an intraepidermal carcinoma. SCC in situ typically occurs on sun-exposed areas with extensive photodamage. It appears as a rough, erythematous, keratotic papule or plaque that often resembles an AK, but with more induration or tenderness (Figure 17-7). SCC in situ and AKs may be present on the same lesion with gradual transition from partial atypia to full thickness atypia.

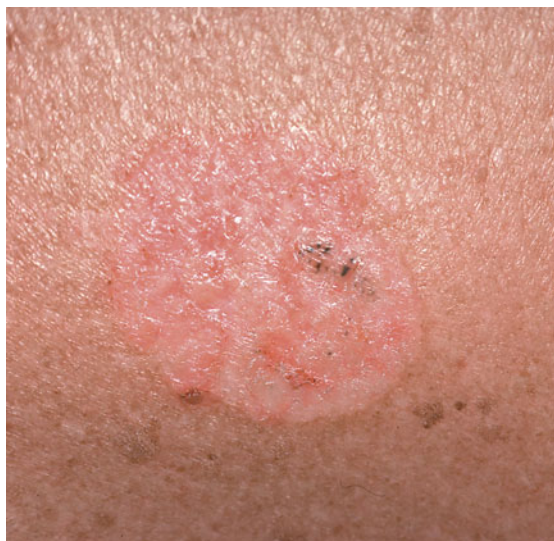Bowen's disease is a SCC in situ that presents as a well-demarcated, erythematous plaque with minimal scale and is often located on the lower extremities particularly in women (Figure 17-8). This lesion is often misdiagnosed as eczema or psoriasis or even superficial BCC. Any SCC in situ has potential for becoming invasive if not treated appropriately.

Erythroplasia of Queyrat is a SCC in situ on the penile shaft, usually in uncircumcised men. This lesion appears as a non-scaly, erythematous, thin plaque on the shaft or corona of the penis (Figure 17-9) that may be present for years and is often misdiagnosed as dermatitis or a candida infection.

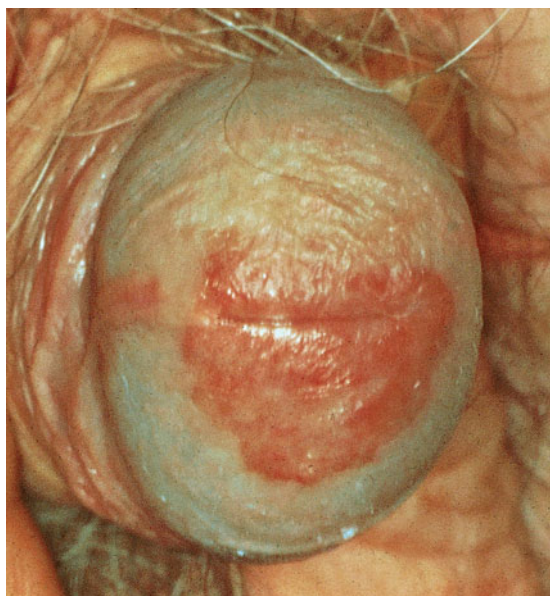
Invasive SCCs have extension into the dermis and beyond and are typically categorized histologically by the grade of keratinocyte differentiation (well, moderate, poor, and infiltrative). Clinically, invasive SCC appears as



▲ **Figure 17-7.** Squamous cell carcinoma in situ. Hyperkeratotic plaque on the helix of the ear.



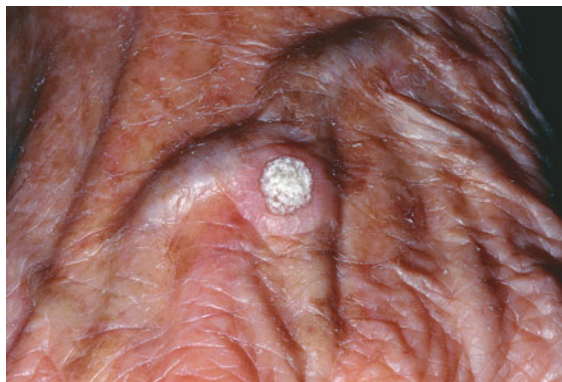▲ **Figure 17-8.** Bowen's disease. Erythematous well-demarcated plaque.



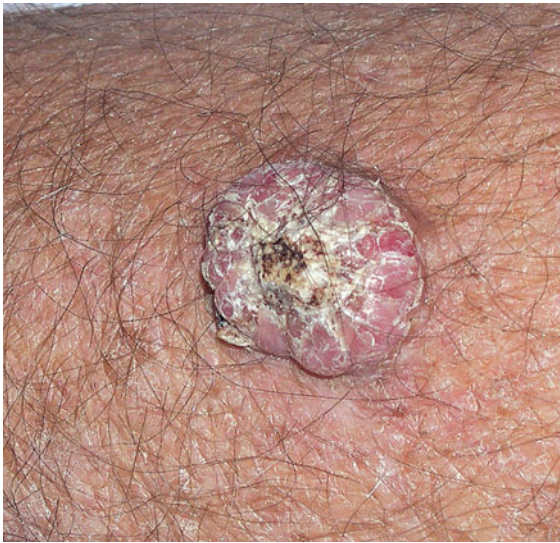▲ **Figure 17-9.** Erythroplasia of Queyrat. Erythematous thin plaque around the urethral meatus.

a solitary hyperkeratotic pink nodule or papule on sun-exposed areas (Figure 17-10). An invasive SCC has the potential for metastasis, especially if there is perineural invasion or if the lesions are histologically aggressive with poor differentiation or infiltrative pattern. Lower lips and ears are particularly susceptible areas for SCC development with potential risk for regional lymph node metastasis. Solid organ transplant patients can develop SCCs in all areas with risk for metastasis and local recurrence.

Keratoacanthomas are invasive SCC with a unique clinical history and presentation. They appear and grow quickly in matter of weeks and appear as a solitary



▲ **Figure 17-10.** Invasive squamous cell carcinoma. Hyperkeratotic nodule on the dorsal hand.



▲ **Figure 17-11.** Keratoacanthoma. Erythematous nodule with a central hyperkeratotic core.

symmetrical erythematous nodule with a central hyperkeratotic core that resembles a larger molluscum contagiosum lesion (Figure 17-11).

Verrucous Carcinomas are invasive SCCs that present as verrucous warty-like plaques usually on plantar feet or on distal fingers. These long-standing lesions are often treated for years as common warts without resolution. Verrucous carcinomas are thought to arise from HPV-induced abnormal keratinocytes.

► Laboratory Findings

The histopathology of SCC in situ shows abnormal keratinocytes involving the entire thickness of the epithelium. Invasive SCCs are graded based on degree of keratinocyte differentiation. Well-differentiated SCCs have a higher level of keratinization and are more localized. Poorly differentiated SCCs have no or very limited keratinization and less differentiation. These lesions may have a more spindle cell appearance with higher risk of metastasis and local recurrence. They may have perineural invasion and involve deeper layers of the skin with wider subcutaneous extension. Infiltrative SCC have a desmoplastic scar-like appearance with single cell strands infiltrating the dermis and subcutis. These lesions may be missed with typical hematoxylin and eosin (H&E) staining and may need specialized immunohistochemical stains.

Diagnosis

A SCC typically presents as a hyperkeratotic erythematous papule or plaque on sun damaged skin.

► Differential Diagnosis

- ✓ **Viral wart:** Presents as a hyperkeratotic papule, but with less redness, typically on palmar and plantar surfaces.
- ✓ **BCC:** Tends to be less scaly and have a more pearly surface with telangiectasia.
- ✓ **Seborrheic keratosis:** Tends to be more well defined with a verrucous pigmented keratotic surface.
- ✓ **Dermatitis:** Tends to have a less well-defined border than a SCC and responds to topical steroids.

Management

Suspected lesions should be biopsied for confirmation of the diagnosis of SCC as well as histologic grading if indicated. Shave biopsy is sufficient if the lesion is adequately sampled into the superficial dermis. An invasive SCC may be under diagnosed as a SCC in situ or an AK if the biopsy transects through the atypical epithelium only.

Most SCCs are treated by surgical removal either by fusiform excision or Mohs micrographic surgery. For fusiform excision, the typical margin is 4 mm as in excision of BCCs. Mohs micrographic surgery indications are listed in Table 17-1. For SCC with poor differentiation or spindle cell features, the risk for metastasis is higher and proper staging with sentinel lymph node biopsy or lymph node dissection as well as radiologic examination is recommended.¹¹

Electrodessication and curettage, topical treatments such as imiquimod, and PDT have been successful in the treatment of SCC in situ lesions. However, the clinician must be aware of the risk of recurrence and metastatic disease and should limit the usage of these treatments for selected SCCs.

Indications for Consultation

Generally, a well-differentiated SCC may be excised appropriately by a surgically trained healthcare provider. Any SCC in high-risk area or a tumor with more aggressive features should be evaluated by a dermatologist and dermatologic surgeon for proper diagnosis, staging, and treatment.

Patient Information

- American Academy of Dermatology: www.aad.org/skin-conditions/dermatology-a-to-z/squamous-cell-carcinoma
- PubMed Health: www.ncbi.nlm.nih.gov/pubmedhealth/PMH0001832/
- Skin Cancer Foundation: www.skincancer.org/skin-cancer-information/squamous-cell-carcinoma
- American College of Mohs Surgery: www.skincancer-mohssurgery.org/mohs-surgery/faqs.php

REFERENCES

1. Kim RH, Armstrong AW. Nonmelanoma skin cancer. *Dermatol Clin*. 2012;30(1):125–139, ix. PMID: 22117874.
2. Madan V, Lear JT, Szeimies R. Non-melanoma skin cancer. *Lancet*. 2010;375(9715):673–685. PMID: 20171403.
3. de Berker D, McGregor JM, Hughes BR. Guidelines for the management of actinic keratoses. *Br J Dermatol*. 2007;156(2):222–230. PMID: 17223860.
4. Sachs DL, Kang S, Hammerberg C, et al. Topical fluorouracil for actinic keratoses and photoaging: a clinical and molecular analysis. *Arch Dermatol*. 2009;145(6):659–666. PMID: 19528421.
5. Lebwohl M, Swanson N, Anderson L, Melgaard A, Xu Z, Berman B. Ingenol mebutate gel for actinic keratosis. *N Engl J Med*. 2012;366(11):1010–1019. PMID: 22417254.
6. Lee Y, Baron ED. Photodynamic therapy: current evidence and applications in dermatology. *Semin Cutan Med Surg*. 2011;30(4):199–209. PMID: 22123417.
7. Ceilley RI, Del Rosso JQ. Current modalities and new advances in the treatment of basal cell carcinoma. *Int J Dermatol*. 2006;45(5):489–498. PMID: 16700779.
8. Drake LA, Dinehart SM, Goltz RW, et al. Guidelines of care for Mohs micrographic surgery. American Academy of Dermatology. *J Am Acad Dermatol*. 1995;33(2):271–278. PMID: 7622656.
9. Connolly SM, Baker DR, Coldiron BM, et al. AAD/ACMS/ASDSA/ASMS 2012 appropriate use criteria for Mohs micrographic surgery: a report of the American Academy of Dermatology, American College of Mohs Surgery, American Society for Dermatologic Surgery Association, and the American Society for Mohs Surgery. *J Am Acad Dermatol*. 2012;67(4):531–550. PMID: 22959232.
10. LoRusso PM, Rudin CM, Reddy JC, et al. Phase I trial of hedgehog pathway inhibitor vismodegib (GDC-0449) in patients with refractory, locally advanced or metastatic solid tumors. *Clin Cancer Res*. 2011;17(8):2502–2511. PMID: 21300762.
11. Alam M, Ratner D. Cutaneous squamous-cell carcinoma. *N Engl J Med*. 2001;344(13):975–983. PMID: 11274625.

Nevi and Melanoma

David L. Swanson

18

Introduction to Chapter / 163
Acquired Melanocytic Nevi / 163
Atypical Nevi / 166

Congenital Melanocytic Nevus / 168
Melanoma / 169
References / 173

INTRODUCTION TO CHAPTER

Melanocytic nevi (moles) are common benign skin tumors. In most people, these are primarily of cosmetic significance. However, nevi can occasionally become irritated or subjected to trauma and may need to be removed. Most nevi are benign, but, atypical nevi have some features that resemble malignant melanoma, and in certain circumstances the presence of atypical nevi is a marker for an increased risk of developing malignant melanoma.

Melanoma is a potentially deadly cancer whose incidence is on the rise. It is unique among most serious cancers, because it can be detected by both patients and clinicians with a simple skin examination. The clinician can provide a great service to patients by providing a few simple guidelines for the early detection of melanoma.

ACQUIRED MELANOCYTIC NEVI

Introduction

Melanocytic nevi (moles) are among the most common benign tumors in humans. Nevi are more common in Caucasians. They are less common in Asians and Black individuals. But when they do occur they are more likely to be on the palms and soles. Interestingly, nevi are also less common in patients with the melanocortin-1 receptor (MC1-R) gene pigment variant (red hair, fair skin, always burns).

Nevi appear in early childhood reaching a maximum number in the 3rd to 4th decade of life, with a subsequent

decline in number.¹ They are more common on sun-exposed skin, as natural sunlight and artificial ultraviolet light are factors in their induction.

Pathophysiology

Nevi are benign hamartomas of melanocytic nevus cells. They are thought to arise from cells delivered from the neural crest to the skin during embryologic development.

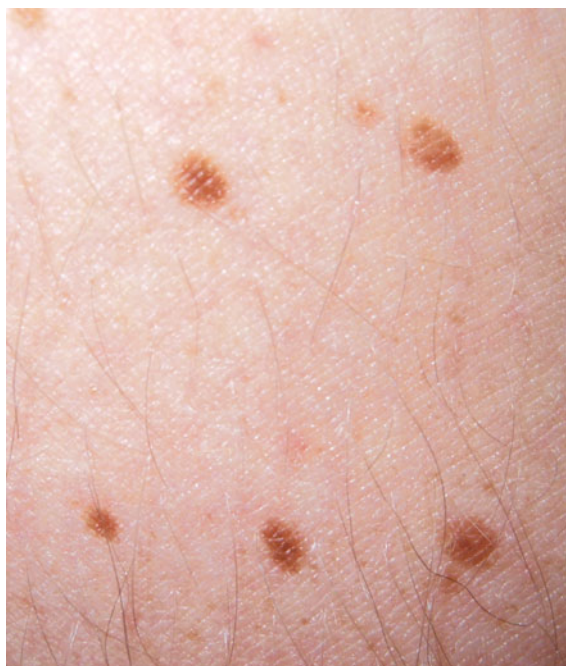Clinical Presentation

History

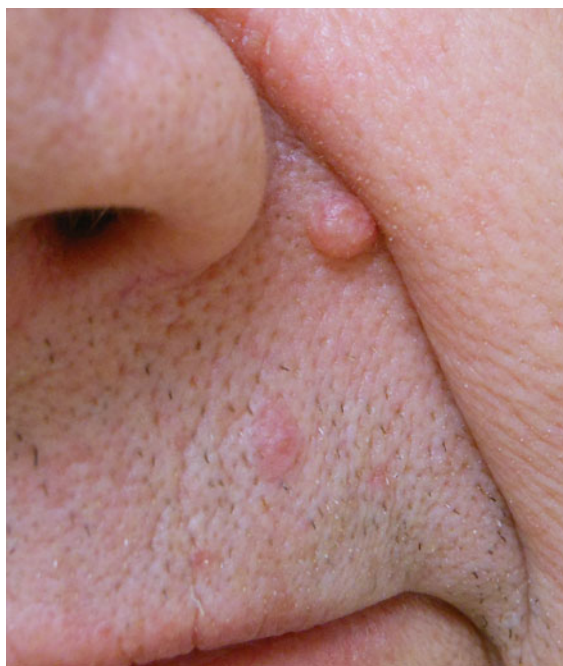Nevi are usually asymptomatic. Patients may bring nevi to a clinician's attention because of new onset, growth, symptoms of pain or itch, interference with activities of daily living, or alarming appearance. They may also bring them to attention because of a cosmetically unacceptable appearance.

Physical Examination

Nevi are small, circumscribed macules, papules, or nodules. They range in color from blue/black through brown, pink to skin colored. Acquired nevi are almost always less than 1 cm in diameter. Melanocytic lesions greater than 1 cm may be congenital nevi, atypical nevi, or melanoma. Nevi may occur anywhere but there is a predilection to sun-exposed skin.



▲ **Figure 18-1.** Junctional nevi. Tan macules with uniform colors and borders.



▲ **Figure 18-2.** Intradermal nevi. Skin-colored dome-shaped papules.

Common presentations of nevi:

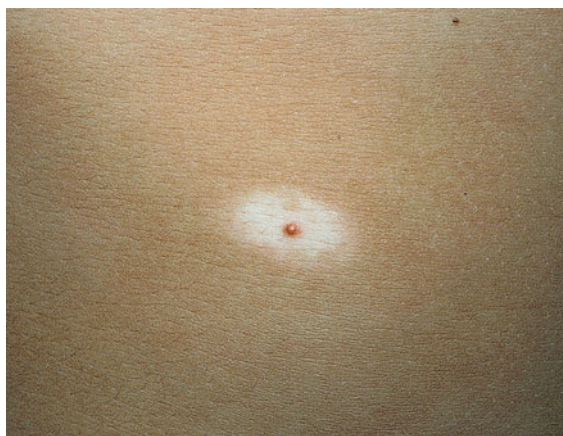
- Junctional nevi arise at the skin dermal–epidermal junction; they are typically macular (Figure 18-1).
- Intradermal nevi present with nevus cells confined to the dermis of the skin and are papular (Figure 18-2).
- Compound nevi have both junctional and dermal components and are usually papular.

Less common presentations of nevi:

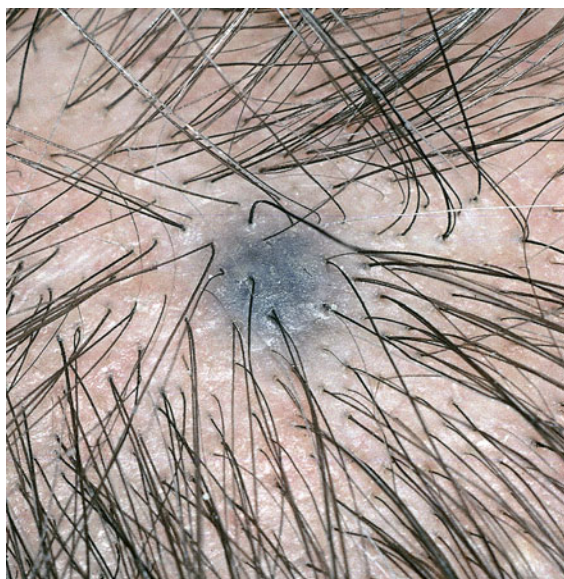- Halo nevus (Sutton nevus): These are usually benign melanocytic nevi surrounded by a halo of depigmentation (Figure 18-3), which may be due to a direct cytotoxic effect of lymphocytes surrounding the nevus. The halo usually heralds involution of the nevus over months to years. These lesions most commonly occur in childhood. Patients may have associated vitiligo. Melanoma can masquerade as a halo nevus, and melanomas in other sites may precipitate halo nevi. The presence of a halo nevus warrants a total skin examination and any atypical feature of the nevus itself justifies removal and histopathological examination.
- Blue nevus: These are acquired nevi that range in color from blue to black (Figure 18-4). The onset is usually in childhood, with predominance in Asians. These nevi are benign, but melanoma, especially nodular melanoma may masquerade as a blue nevus.

Indications for biopsy include atypical features such as size >1 cm or irregular shape or color, late onset, or a changing lesion.

- Spitz nevus: These are small, typically pink or tan nevi that appear suddenly, primarily in children. They have characteristic dermoscopic and histopathological features. Spitz nevi are unusual in patients over the age



▲ **Figure 18-3.** Halo nevus. Macule with hypopigmented halo.



▲ **Figure 18-4.** Blue nevus. Blue-grey papule on scalp.

of 40; therefore, skin lesions with the dermoscopic features of Spitz nevi are best removed in this age group to exclude melanoma with Spitzoid features.

Features in a nevus that are signs that may indicate a melanoma are listed in Table 18-1.

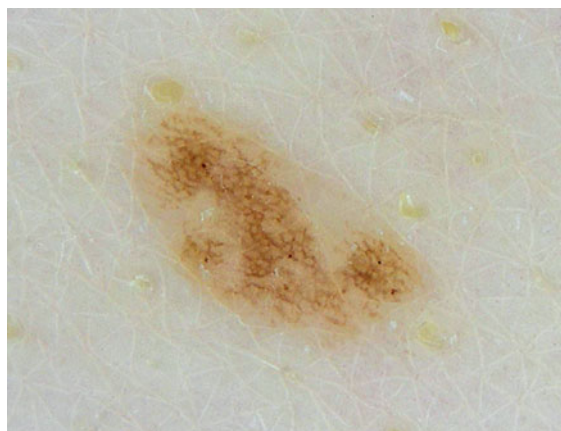► Laboratory Findings

The histopathologic findings of common acquired melanocytic nevi show mature melanocytes arranged as individual cells or in nests. The margin of the nevus is discrete.

Diagnosis

Common acquired melanocytic nevi present as tan, brown, or black macules or papules or skin-colored papules with uniform colors and borders.

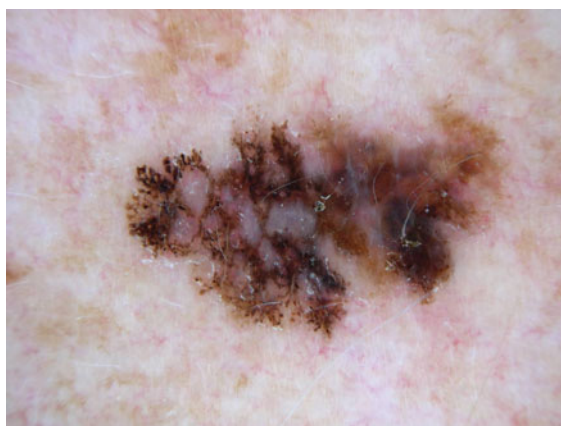
The adoption of dermoscopy has enhanced the ability of the clinician to differentiate normal nevi from atypical nevi and melanomas (Figures 18-5 and 18-6).² Dermoscopy uses an illuminated, high quality 10×-magnifying lens coupled



▲ **Figure 18-5.** Dermoscopic image of a benign nevus showing a typical pigment network and structural symmetry.

to a device to remove surface reflection. This is done either using a set of cross-polarizing filters (polarized dermoscopy) or by direct contact with the skin using a coupling liquid such as an alcohol-based hand cleansing gel. The limitation of dermoscopy is that it is learning intense, but there are a number of algorithms that have been designed to assist clinicians in making the decision to biopsy suspicious lesions.

The easiest is the 3-point algorithm that uses 3 simple criteria for the analysis of a melanocytic neoplasm: (1) the presence of an atypical pigment network; (2) asymmetry of any structure; and (3) the presence of any structure that is blue or white. The presence of 2 or more criteria warrants



▲ **Figure 18-6.** Dermoscopic image of a malignant melanoma showing an atypical pigment network, structural asymmetry, a white veil, and regression changes.

Table 18-1. ABCDE rule for features of melanoma.

A: Asymmetry
B: Border is irregular, notched, or blurred
C: Color is variable or irregularly distributed
D: Diameter is greater than 6 mm
E: Evolving or changing lesion or exceptional nevus that appears different from other nevi

a removal of the lesion for histopathologic examination.² A full body dermoscopic examination typically takes about 2 to 3 minutes.

► Differential Diagnosis

- ✓ Table 18-2 lists the differential diagnosis for common acquired nevi, which primarily includes other pigmented tumors.

Management

Nevi are usually asymptomatic. Patients who have more than 50 nevi are at increased risk for developing melanoma and they should have a full body skin examination annually.³ They should be counseled on sun precautions and how to perform self-examination.

If feasible, clinically suspicious nevi should always be removed in their entirety so that the entire lesion can be examined histopathologically. Clinically suspicious lesions often have one or more of the following features of the ABCDE rule (Table 18-1). Melanocytic lesions are also

suspicious for melanoma if they are painful or pruritic or if the lesion becomes eroded in the absence of trauma. Dermoscopy aids in the evaluation of nevi and other cutaneous neoplasms.

Indications for Consultation

Consideration for referral for regular screening should be given in patients with multiple nevi, especially if the clinician is uncomfortable with dermoscopy.

Depending on the surgical skills of the clinician, patients may be referred for excision of particularly large nevi or nevi in cosmetically sensitive areas.

Patient Information

American Academy of Dermatology: www.aad.org/skin-conditions/dermatology-a-to-z/nevi

ATYPICAL NEVI

Introduction

Atypical nevi (dysplastic nevi) may occur sporadically as isolated “ugly ducklings” (nevi that appear different from other nevi on the body) or as multiple lesions as in the case of atypical nevus syndrome. They can appear in adulthood or childhood and are not uncommon, occurring in up to 5% of Caucasians. They are present in virtually every patient with familial cutaneous melanoma and in 30% to 50% of patients with sporadic primary cutaneous melanoma. Risk factors include a history of sun exposure, but atypical nevi can occur in sun-protected skin. Unlike common acquired nevi, new atypical nevi continue to appear throughout a patient’s lifetime.

Atypical nevus syndrome describes an autosomal dominant phenotype of patients with multiple nevi of different sizes and colors. Patients with atypical nevi have an increased risk for melanoma. The general population has a 1.93% life-time risk for melanoma. The following are the approximate life-time risks (%) of melanoma for patients with atypical nevi.

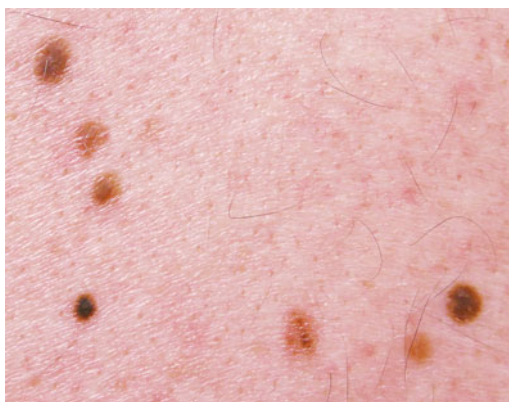- 5% for one atypical nevus with increasing risk for additional atypical nevi
- 18% for atypical nevus syndrome
- 100% for atypical nevus syndrome with two blood relatives with melanoma

Pathophysiology

Atypical nevi are often thought of as melanoma precursors, but this concept is controversial. Most authorities consider atypical nevi as potential markers for an increased risk for developing melanoma *de novo*. The other important significance of atypical nevi is the

Table 18-2. Differential diagnosis of pigmented tumors.

Pigmented Lesion	Clinical Findings
Benign nevus	Symmetric, uniform color and border, size usually <6 mm, resembles other nevi on a patient (Figures 18-1 and 18-2)
Atypical nevus	Size >6 mm, asymmetric, irregular color or border, appears different than other moles on a patient (Figure 18-7)
Congenital nevus	Present at birth. Often greater than 1 cm in size by adulthood (Figure 18-8)
Melanoma	Features similar to atypical nevus. Changing or symptomatic lesion (Figures 18-9 to 18-13)
Lentigo	Evenly colored, sharply margined, resembles other lentigos in sun-damaged skin (Figure 16-4)
Seborrheic keratosis	Warty, with typically a “stuck-on” appearance, sharp round border (Figure 16-1)
Pigmented basal cell cancer	May be indistinguishable from melanoma (Figure 17-4)
Dermatofibroma	Even color or lighter center, puckers when pinched (Figure 16-5)
Becker’s nevus	Large unilateral brown patch on shoulder or chest, may have increased hair



▲ **Figure 18-7.** Atypical nevi. Macules with variable colors and indistinct borders.

potential histopathologic ambiguity and the risk of under diagnosis of melanoma.

Clinical Presentation

► History

Patients often have a history of multiple acquired nevi. There may be a family history of melanoma or removal of nevi.

► Physical Examination

Atypical nevi present as pink to black macules or papules with variegated color, variable shape, and irregular borders (Figure 18-7). Table 18-3 lists the clinical presentation of atypical nevi as contrasted with common typical nevi. The difficult patient is one without a “signature nevus,” meaning a specific type of mole pattern that most if not all nevi adhere to. Some patients have multiple, even hundreds of atypical nevi ranging in size

from millimeters to centimeters and having a variety of colors ranging from pink to black. In these patients, every nevus is an exceptional nevus (an ugly duckling).

► Laboratory Findings

The histopathological findings of atypical nevi may be the same as benign common nevi, but typically will include degrees of mild to severe architectural disorder and/or mild to severe cytological atypia.

Diagnosis

Atypical nevi present as pink to black macules or papules with variegated color and irregular borders. They are usually greater than 6 mm in diameter.

► Differential Diagnosis

- ✓ The differential diagnosis for atypical nevi is listed in Table 18-2.

Management

Nevi that are changing in shape, border, size, or pigmentary features should be biopsied. The observation of these changes often originates from the patient,⁴ but ideally originates from baseline photographs, such as from total body photography or digital dermoscopy.

Patients with atypical nevus syndrome have an increased risk for melanoma and require regular skin examinations, preferably with baseline full body photography to reduce unnecessary biopsies over time.⁵ Patients with atypical nevi and familial melanoma should be examined every 3 months. Close family members should also be examined once the diagnosis of atypical nevus syndrome is established.

Because of the possibility of ambiguity on histopathology, atypical nevi with moderate to severe degrees of architectural disorder or cytological atypia should be excised with at least 5 mm margins, especially in the case of severe architectural disorder or cytological atypia.

Patients should be given color-illustrated pamphlets that depict the clinical features of atypical moles and malignant melanoma. These brochures are available through the Skin Cancer Foundation and the American Academy of Dermatology. Patients with atypical nevi should be instructed to monitor their nevi monthly. Patients should not sunbathe and should use sunscreens and sun protective clothing when outdoors. They should not use tanning salons.

Indications for Consultation

Patients with atypical nevi should be referred for regular screening by a dermatologist skilled in dermoscopic

Table 18-3. Characteristics of typical and atypical nevi.

Features	Typical Nevus	Atypical Nevus
Color	Brown or black, Uniform color	Pink to black, variegated color
Diameter	6 mm or less	May be up to several centimeters in size
Shape and outline	Symmetric	Variable shape or irregular borders
Histological changes	Atypia is absent	Mild to severe architectural disorder and/or cytological atypia

Table 18-4. Categories and size of congenial nevi.

Category	Size
Small	<1.5 cm
Medium	1.5-19.9 cm
Large	>20 cm
Giant	Occupy the major part of a major anatomic site, such as an extremity

examination. In addition, full body photography should be performed as a base-line benchmark for future examinations.

Patient Information

Skin Cancer Foundation: www.skincancer.org/skin-cancer-information/dysplastic-nevi

CONGENITAL MELANOCYTIC NEVUS

Introduction

Congenital melanocytic nevi (CMN) are nevi present at birth or that appear very shortly after birth (tardive CMN). They are present in 1% of Caucasian infants and have no gender predilection. They vary widely in size and incidence (Table 18-4). Five percent of patients with congenital nevi have multiple congenital nevi. CMN are benign tumors, but they do have a limited risk for developing melanoma.

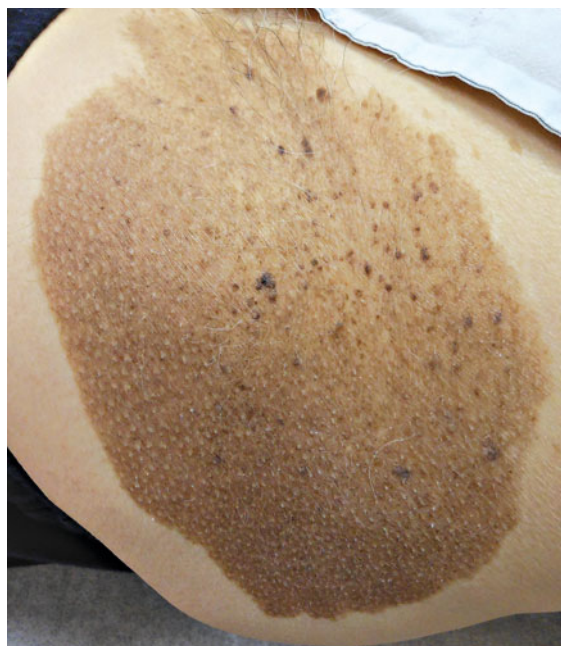
Clinical Presentation

History

Most CMN are present at birth and they grow in proportion to the rest of the body. They are usually asymptomatic, but often visually disconcerting to parents.

Physical Examination

CMN are brown or black. They are usually palpable with well-defined borders, but may have irregular contours. The surface can be smooth (Figure 18-8) but may also have a pebble-like surface. Lesions may also be cribriform, lobular, rugose, or bulbous. They commonly have dark terminal hairs. Giant CMN are often surrounded by smaller satellite nevi. Dermoscopy of CMN is often difficult because atypical features are common. Giant CMN involving the scalp or midline can be associated with deep involvement including muscle, bone, dura mater, and leptomeninges.⁶ Neurocutaneous melanocytosis may be complicated by seizures, focal neurologic defects, or obstructive hydrocephalus. Melanoma most often arises in giant CMN, and



▲ **Figure 18-8.** Congenital melanocytic nevus. Large 22 cm plaque with dark papules on lateral aspect of hip.

is usually advanced because of the difficulty following these lesions through observation.

Laboratory Findings

The histopathological findings of CMN include benign features of junctional and dermal nevi, and in some instances a “neural” component with neuroid tubes and corpuscles. There may also be melanocytic aggregates resembling blue nevi.

Diagnosis

CMN present at birth with brown to black plaques usually with well-defined borders.

Differential Diagnosis

- ✓ **Common acquired melanocytic nevi:** Small CMN are virtually indistinguishable clinically from common acquired nevi except for their size
- ✓ **Other melanocytic nevi:** Congenital blue nevi have a deep blue color and nevus spilus presents with multiple 2- to 3-mm dark brown nevi on a large light brown patch
- ✓ **Other pigmented congenital lesions:** Becker’s nevus, pigmented epidermal nevus, and café-au-lait spots

Management

Melanoma that develops in a large CMN has a poor prognosis because it usually is detected late. The lifetime risk of developing a melanoma in a small CMN is estimated to be as high as 1% to 5%. However, this risk estimate comes from retrospective data and the actual risk is unknown. The risk is higher in large or giant CMN and has been estimated to be as high as 6.3%. Half of patients who develop melanomas in congenital nevi will develop the melanoma between the ages of 3 and 5 years. For this reason, many advocate prophylactic staged excision of the CMN early in life.⁷ However, the value of excision of CMN has been questioned because it is usually impossible to remove all the nevus, poor cosmetic results are common, and there are attendant medical and psychological risks to repeated large excisions.⁶

Indications for Consultation

Patients with atypical nevi and congenital nevi should be referred to dermatology for evaluation and long-term monitoring of their nevi.

Patient Information

The Association for Large Nevi and Related Disorders: www.nevus.org

MELANOMA

Introduction

Malignant melanoma is a cancer of melanocytes. The cancer incidence is on the rise, afflicting over 68,000 people in the United States annually and causing 8000 annual deaths.⁸ It is the fifth most frequently diagnosed cancer in men (lifetime risk of 2.67%) and the sixth most common in women (lifetime risk of 1.79%).⁸ Malignant melanoma attracts a great amount of publicity, because it is one of the most common potentially lethal malignancies of young adults. From 1970 to 2009 in Olmsted County, Minnesota, the incidence of melanoma increased by 8-fold among young women and 4-fold among young men (although there was no increase in mortality).⁹ It is the easiest malignancy to diagnose early, and there are national educational campaigns in most countries emphasizing the importance of self-examination of the skin.

Melanoma can occur at any age but is rare in childhood. Lifetime risk factors (in roughly decreasing risk) include genotypes with specific risk enhancement (eg, CDKN2A), atypical nevus syndrome (especially if two immediate family members have a melanoma history), family history of melanoma in first-order relatives, prior personal history of melanoma, one or more atypical nevi, large numbers of common nevi, advancing age, outdoor

occupations or aviation flight occupation, fair skin, history of blistering sunburn, and a history of commercial tanning.³

Pathophysiology

Most melanomas begin as de novo lesions, although some authors state up to 30% arise in preexisting nevi. The cancer genetics for melanoma are complex, but certain oncogenes have become important because of their frequencies and because of potential therapeutic implications for targeted therapy (eg, vemurafenib for BRAF mutation). Other mutations in addition to BRAF (most common in superficial spreading melanoma) include KIT (most common in lentigo maligna melanoma and acral-lentiginous melanoma), NRAS, and CDKN2A (the most common specific mutation in familial melanoma).¹⁰ About 20% to 40% of familial melanoma cases are associated with a CDKN2A mutation.

Clinical Presentation

History

Patients often have a history of a change in size, shape or color or pruritus in a new or existing nevus.

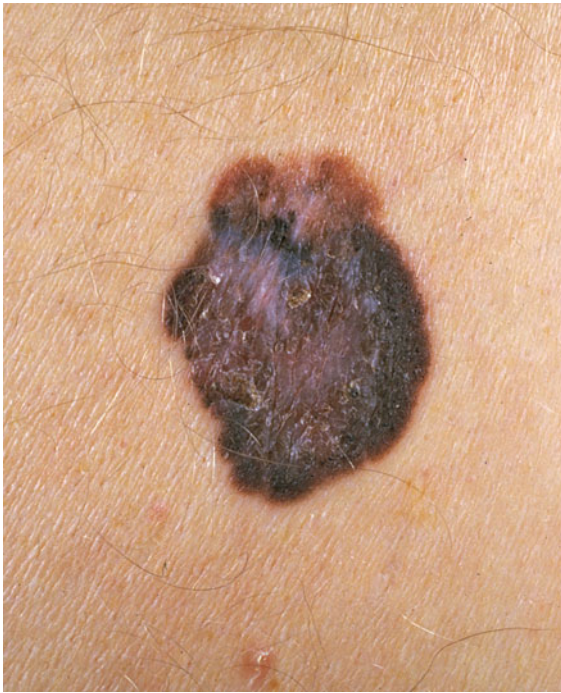Physical Examination

Melanoma can occur on any skin surface irrespective of sun exposure. The most common locations in men are the trunk (55%), especially the upper back, followed by the legs, arms, and face; in women, the most common location is the legs (42%), followed by the trunk, arms, and face.⁸

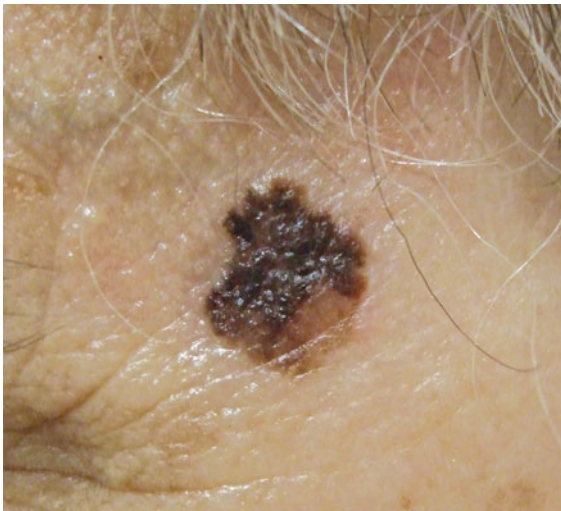
Melanomas typically have the features as listed in Table 18-1. Figure 18-9 demonstrates many of these features.

Main Types of Melanoma

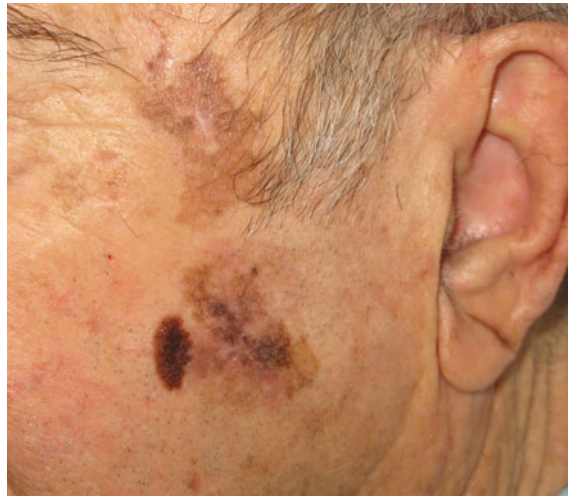- **Superficial spreading melanoma** can occur in sun-exposed or nonexposed skin. It is characterized by a superficial radial growth phase that occurs before an invasive vertical growth phase (Figure 18-10). These melanomas account for about 70% of melanomas and have an excellent prognosis when detected early.
- **Lentigo maligna melanoma** occurs most commonly in sun-damaged skin of the head and neck of elderly patients (Figure 18-11). These account for 10% to 30% of melanomas, depending on the patients' age demographics and latitude.¹¹ These are very often diagnosed as in situ lesions.
- **Nodular melanoma:** These melanomas, representing 10% to 15% of melanomas, lack a radial growth phase (Figure 18-12). They grow rapidly over months and are often advanced at the time of diagnosis.



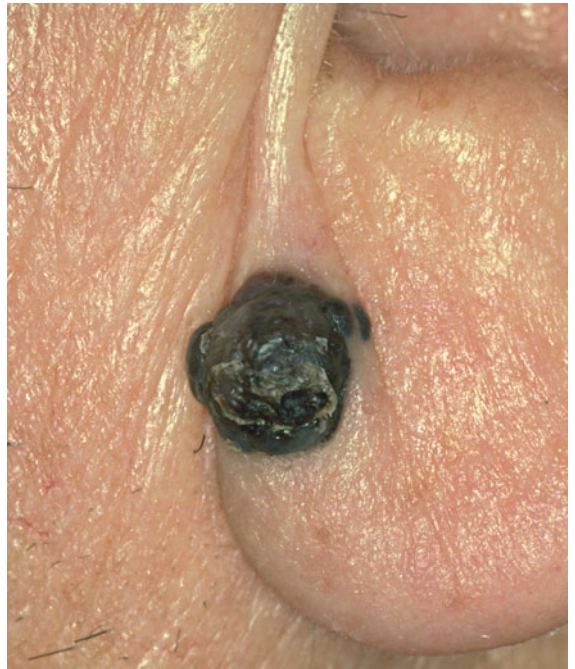▲ **Figure 18-9.** Melanoma. Demonstrating the ABCD rule with asymmetry, irregular border, variable color, and diameter >6 mm.



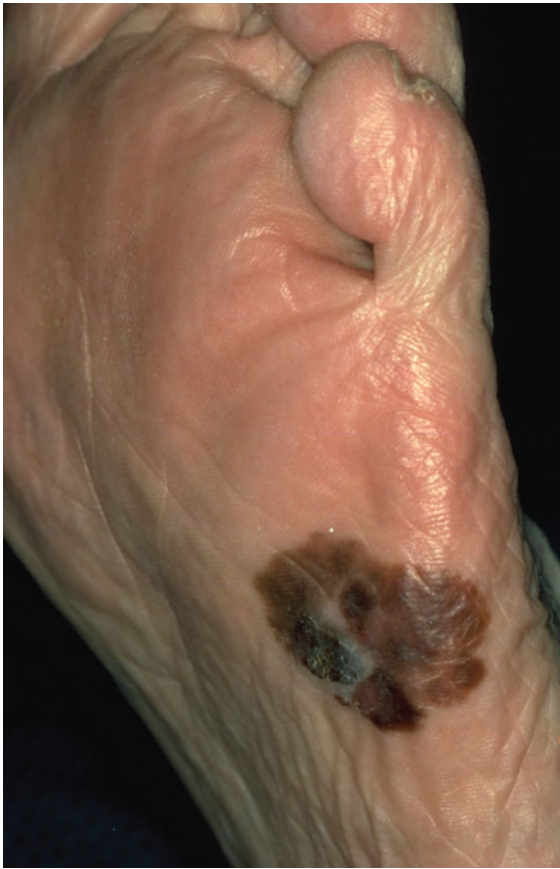▲ **Figure 18-10.** Superficial spreading melanoma. Dark brown plaque with variable colors and irregular borders on temple.



▲ **Figure 18-11.** Lentigo maligna melanoma. Four centimeter lentigo maligna on cheek with indistinct and irregular borders and variable colors with an invasive melanoma component on medial border. A benign lentigo is above the melanoma.



▲ **Figure 18-12.** Nodular melanoma. Black-dark grey papule with crust and superficial ulcer on earlobe.



▲ **Figure 18-13.** Acral lentiginous melanoma. Dark brown patch with variable colors and irregular border with crust and superficial ulceration on the plantar and lateral aspect of the foot.

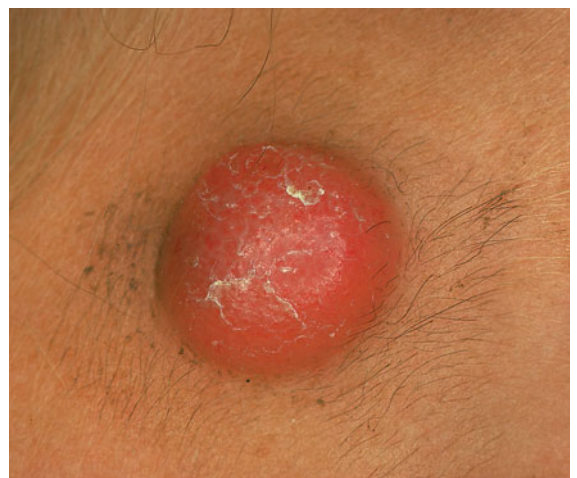- **Acral lentiginous melanoma** occurs on the palms and soles (Figure 18-13). It accounts for only about 5% of melanomas in Caucasians, but is the most common cause of melanomas in Asians and Blacks. It is often advanced at diagnosis because of patients' inattentiveness to the sole of the foot.

► Other Presentations of Melanoma

- **Melanoma in situ (MIS)** is a proliferation of malignant melanocytes confined to the epidermis. The American Cancer Society estimated that 46,770 cases of MIS occurred in the United States in 2010. The most common subtype of MIS is lentigo maligna which occurs in sun-exposed skin and accounts for 80% of MIS.¹¹
- **Metastatic melanoma from an unknown primary:** This occurs in about 3% to 5% of all melanoma patients. If the metastasis is limited to skin or lymph nodes, the

prognosis is actually better than patients with visceral metastases from a known primary.

- **Primary mucosal melanoma of the head and neck:** This rare subtype occurs in about 1% of melanomas.
- **Vulvo/vaginal melanoma:** These account for a small number of melanomas. However, melanoma in this location is important because the detection is often delayed.
- **Subungual melanoma:** Subungual melanoma accounts for up to 3% of melanomas. It most commonly presents with pigmentary changes of the nail bed. The diagnosis is aided by dermoscopy. Early diagnosis is essential as the prognosis is otherwise poor compared to other melanoma locations.
- **Primary ocular melanoma:** Ocular melanoma is extremely rare. Lesions may be uveal, ciliary, or choroidal and are not amenable to biopsy. Patients usually present with visual loss or pain. The diagnosis is based on physical findings.
- **Pediatric melanoma:** Accounts for 1% to 4% of melanoma. Thirty percent of pediatric melanomas arise in association with a giant congenital melanocytic nevus.¹² In two-thirds of the cases the melanomas develop within the congenital nevus.¹³
- **Amelanotic melanoma** is a variant of melanoma. It usually presents as a pink lesion (Figure 18-14). Dermoscopy will sometimes show a pigment network or globules not apparent on clinical examination. These lesions usually are outliers (ugly ducklings) but sometimes are masked by other pink lesions, particularly in patients with atypical nevus syndrome. They are often nodular and may be confused with pyogenic granulomas.



▲ **Figure 18-14.** Amelanotic melanoma. Pink dome-shaped nodule on temple. The lesion has scale on the surface and crust on the periphery.

- **Desmoplastic melanomas** account for 1% of melanoma. These most commonly present as flesh-colored or pink papules or nodules, most commonly on the head, neck, palms, and soles. Although often invasive at the time of diagnosis, the prognosis is better than for comparably thick nodular melanomas. The cell of origin is controversial and this tumor may in fact be a soft tissue sarcoma.
- **Familial melanoma:** 5% to 10% of melanomas occur in familial clusters. Up to 40% of patients with familial melanoma have a gene mutation in the CDKN2A suppressor gene. These patients also are at increased risk for pancreatic cancer. Indications for genetic screening include individuals with three or more primary melanomas or family members affected by two melanomas or two pancreatic cancers.¹⁰

► Laboratory Findings

The histopathological findings of a melanoma include an irregular distribution of atypical cells in nests and individually with disruption of normal architecture, violation of boundaries, and a host response evident by an inflammatory infiltrate.

A report of melanoma should include the Breslow depth, which is a measurement of thickness of the tumor measured from the surface of the skin to the deepest level of tumor invasion. Tumor staging is based on the Breslow depth, with 1.0, 2.0, and 4.0 mm being thresholds for T category staging.¹⁴ Other features important for staging include the number of mitoses and the presence of ulceration. Additional prognostic factors not incorporated into the current American Joint Committee on Cancer (AJCC) staging classification, which have shown prognostic significance in some studies, include radial and vertical growth phases, regression, angiolymphatic invasion, angiotropism, perineural invasion, and tumor-infiltrating lymphocytes. The Clark classification, which is an older measurement of tumor invasion, is not used any more. Atypical melanocytic hyperplasia is a term that describes lesions that are ambiguous histopathologically and may be difficult to distinguish from melanoma. Most experts treat these lesions as MIS.

Diagnosis

Most melanomas present with one of more features as listed in the ABCDE rule (Table 18-1).

Dermoscopy is of limited usefulness in patients with nevi that have borderline dermoscopic features or are completely featureless structurally. In these patients if there is clinical uncertainty one is obligated to remove the lesion. An alternative is to follow the patient with serial photography,⁵ an approach that many experts suggest as standard of care for patients with atypical nevus syndrome.

► Differential Diagnosis

- ✓ Table 18-2 lists the differential diagnosis for pigmented lesions.

Management

The first step in management of a suspected melanoma is confirmation of the diagnosis with a skin biopsy. The purpose of the biopsy for a suspected melanoma is to make the diagnosis and to provide staging information. The most important staging information is thickness.¹⁴ Ideally a suspicious lesion should be excised in its entirety with at least 2 mm of normal appearing skin at the margin (allowing the pathologist to examine the lesion margin).¹⁵

Partial biopsies are subject to sampling error and should be avoided except in limited circumstances such as in a large facial lesion in which a total excision may result in an unacceptable scar. Even in that circumstance best practice would be to obtain multiple biopsies from several parts of the lesion.

Shave biopsies are acceptable if the lesion is suspected to be thin (less than 1 mm in thickness) and the biopsy method can remove the entire lesion to a depth of more than 1 mm and include at least 2 mm of normal skin at the margin. This results, in effect, in more of a saucerization biopsy than a shave biopsy.

► Surgical Management

Melanoma in situ: This is typically treated with surgical excision. Lentigo maligna (the most common subtype of melanoma in situ) should be excised with a wide local excision with 5 to 7 mm margins after verifying margins using a Wood's lamp or dermoscopy. Mohs micrographic surgery is often used for ill-defined or large lesions of lentigo maligna. The advantage of Mohs surgery is that 100% of the peripheral margin is examined following the excision. Disadvantages are unique technical problems resulting from freeze artifacts and the presence of benign melanocytic hyperplasia common to sun-damaged skin. Alternative therapies for lentigo maligna include radiotherapy, cryosurgery, and topical treatment with imiquimod, or long-term close observation.¹⁶

Invasive melanoma: In areas where there are cosmetic or anatomic limitations, the margin of excision may deviate from the standard resection margins. The National Comprehensive Cancer Center guidelines stipulate surgical margins based on tumor thickness (Table 18-5).¹⁵ The depth of excision is typically down to fat, but preserving muscular fascia.

Sentinel node biopsy: The AJCC Melanoma Staging Committee has recommended that patients with more advanced stages of melanoma (Table 18-5) and with clinically uninvolved regional nodes have sentinel node biopsy

Table 18-5. Primary surgical management of melanoma.

Breslow Depth (Thickness)	Indications for a Sentinel Node Biopsy	Clinical Surgical Margin (cm)
Melanoma in situ	No	0.5-1.0
Less than 0.76 mm	No	1.0
0.76-1.0	If poor prognostic features are present age, eg, <40 years of age, ulceration, mitotic rate >1/mm ² , angiolymphatic invasion	1.0
1.0-2.0 mm	Yes	1-2
>2 mm	Yes	2.0

performed.¹⁴ The sentinel node status is of prognostic value, even if only microscopic metastases are seen.¹⁴ However, at the time of this writing, there is no proven therapeutic benefit from sentinel node biopsy, and there is potential morbidity and opportunities for misdiagnosis and therapeutic misadventures.

► Monitoring of Patients with Asymptomatic Melanoma

There are no clear data to guide clinicians regarding follow up and laboratory testing.¹⁵ It is reasonable to recommend an annual history and physical examination with attention to skin and lymph nodes. In addition, patients should be educated on the importance of interval self-examination of skin and lymph nodes. Baseline laboratory tests and imaging studies are not recommended, nor is there a clear role for surveillance laboratory testing or imaging studies.

Melanoma survival depends on early diagnosis. Most melanomas begin as thin lesions and early diagnosed melanoma with a thickness of less than 0.75 mm has a 5-year survival prognosis exceeding 98%.¹⁷ Patients with melanomas with thicknesses between 1 mm and 2 mm have 10-year survival rates of less than 70% and those with melanomas greater than 4 mm in thickness have 10-year survival rates of less than 20%. The web site www.melanomaprognosis.org has more detailed information for prognosis based on the AJCC melanoma data base.

► Primary Prevention and Detection

Ultraviolet radiation exposure, including radiation from commercial tanning beds, increases the risk of malignant melanoma. For this reason as well as for primary prevention of other skin cancers patients should be counseled on the value of sun safe behavior, including sun protective clothing, shade, and use of sun screens.

Indications for Consultation

Patients with melanoma who are candidates for sentinel node lymph biopsies should be referred to a surgeon that has expertise in the procedure. Patients should also be referred to dermatology for a total body examination and follow-up examinations. Patients with positive sentinel lymph nodes or with melanomas with a poor prognosis should be referred to oncology.

Patient Information

- American Academy of Dermatology: www.aad.org/skin-conditions/dermatology-a-to-z/melanoma
- Skin Cancer Foundation: www.skincancer.org/skin-cancer-information/melanoma
- Melanoma Research Foundation: www.melanoma.org
- American Society of Clinical Oncology: www.cancer.net/patient/Cancer+Types/Melanoma/ci.Melanoma.printer

REFERENCES

1. MacKie RM, English J, Aitchison TC, Fitzsimons CP, Wilson P. The number and distribution of benign pigmented moles (melanocytic naevi) in a healthy British population. *Br J Dermatol.* 1985;113(2):167–174. PMID: 4027184.
2. Braun RP, Rabinovitz HS, Oliviero M, Kopf AW, Saurat J. Dermoscopy of pigmented skin lesions. *J Am Acad of Dermatol.* 2005;52(1):109–121. PMID: 15627088.
3. Psaty EL, Scope A, Halpern AC, Marghoob A. Defining the patient at high risk for melanoma. *Int J Dermatol.* 2010; 49(4):362–376. PMID: 20465687.
4. Soares TF, Laman SD, Yiannias JA, et al. Factors leading to the biopsy of 1547 pigmented lesions at Mayo Clinic, Scottsdale, Arizona, in 2005. *Int J Dermatol.* 2009;48(10):1053–1056. PMID: 19775399.
5. Rademaker M, Oakley A. Digital monitoring by whole body photography and sequential digital dermoscopy detects thinner melanomas. *J Prim Health Care.* 2010;2(4):268–272. PMID: 21125066.
6. Alikan A, Ibrahimi OA, Eisen DB. Congenital melanocytic nevi: Where are we now? Part I. Clinical presentations, epidemiology, pathogenesis, histology, malignant transformation, and neurocutaneous melanosis. *J Am Acad Dermatol.* 2012; 67(4):495.e1–e17. PMID: 22980258.
7. Ibrahimi OA, Alikan A, Eisen DB. Congenital melanocytic nevi: Where are we now? Part II. Treatment options and approach to treatment. *J Am Acad Dermatol.* 2012;67(4):515.e1–e13. PMID: 22980259.
8. Tuong W, Cheng LS, Armstrong AW. Melanoma: epidemiology, diagnosis, treatment, and outcomes. *Dermatol Clin.* 2012;30(1):113–124. PMID: 22117873.
9. Reed KB, Brewer JD, Lohse CM, Bringe KE, Pruitt CN, Gibson LE. Increasing incidence of melanoma among young adults: an epidemiological study in Olmsted County, Minnesota. *Mayo Clin Proc.* 2012;87(4):328–334. PMID: 22469345.
10. Leachman SA, Carucci J, Kohlman W, et al. Selection criteria for genetic assessment of patients with familial melanoma.

- J Am Acad of Dermatol.* 2009;61(4):677.e1–677.e14. PMID: 19751883.
11. Swetter SM, Boldrick JC, Jung SY, Egbert BM, Harvell JD. Increasing incidence of lentigo maligna melanoma subtypes: Northern California and national trends 1990–2000. *J Invest Dermatol.* 2005;125(4):685–691. PMID: 16185266.
 12. Huynh PM, Grant-Kels JM, Grin CM. Childhood melanoma: update and treatment. *Int J Dermatol.* 2005;44(9):715–723. PMID: 16135138.
 13. Krengel S, Hauschild A, Schafer T. Melanoma risk in congenital melanocytic naevi: a systematic review. *Br J Dermatol.* 2006;155(1):1–8. PMID: 16792745.
 14. Balch CM, Gershenwald JE, Soong S, Thompson JF. Update on the melanoma staging system: the importance of sentinel node staging and primary tumor mitotic rate. *J Surg Oncol.* 2011;104(4):379–385. PMID: 21858832.
 15. Bichakjian CK, Halpern AC, Johnson TM, et al. Guidelines of care for the management of primary cutaneous melanoma. American Academy of Dermatology. *J Am Acad Dermatol.* 2011;65(5):1032–1047. PMID: 21868127.
 16. Erickson C, Miller SJ. Treatment options in melanoma in situ: topical and radiation therapy, excision and Mohs surgery. *Int J Dermatol.* 2010;49(5):482–491. PMID: 20534080.
 17. Balch CM, Soong SJ, Gershenwald JE, et al. Prognostic factors analysis of 17,600 melanoma patients: validation of the American Joint Committee on Cancer melanoma staging system. *J Clin Oncol.* 2001;19(16):3622–3634. PMID: 11504744.

Hair Disorders

Maria K. Hordinsky

19

Introduction to Chapter / 175
Pathophysiology / 175
Examination of the Patient with a Hair Disorder / 176
The Nonscarring Alopecias / 177
Androgenetic Alopecia: Male and Female Pattern Alopecia / 177

Alopecia Areata / 180
Telogen Effluvium / 181
Cicatricial (Scarring) Alopecias / 183
Hirsutism / 185
References / 186

INTRODUCTION TO CHAPTER

The hair follicle is a complex structure which produces the hair fiber consisting of a cortex, medulla, and cuticle (Figures 19-1 and 19-2). Hair follicles demonstrate the unusual ability to completely regenerate themselves. Hair grows, falls out, and then regrows. In the normal human scalp, up to 90% of hair follicles are in the growth phase called anagen, 1% in the transition phase catagen, and up to 10% in telogen or the loss phase. The anagen phase lasts approximately 3 years, catagen 2 to 3 weeks, and telogen 3 months.¹

Hair disorders are broadly grouped into the following categories:

- The nonscarring alopecias associated with hair cycle abnormalities.
- The scarring or cicatricial alopecias associated with inflammation and injury to the stem cell region of the hair follicle.

Hair loss is common and can occur with a variety of medical conditions. The workup of a patient with a hair disorder starts with a thorough history and physical examination as outlined in Tables 19-1 and 19-2, respectively.

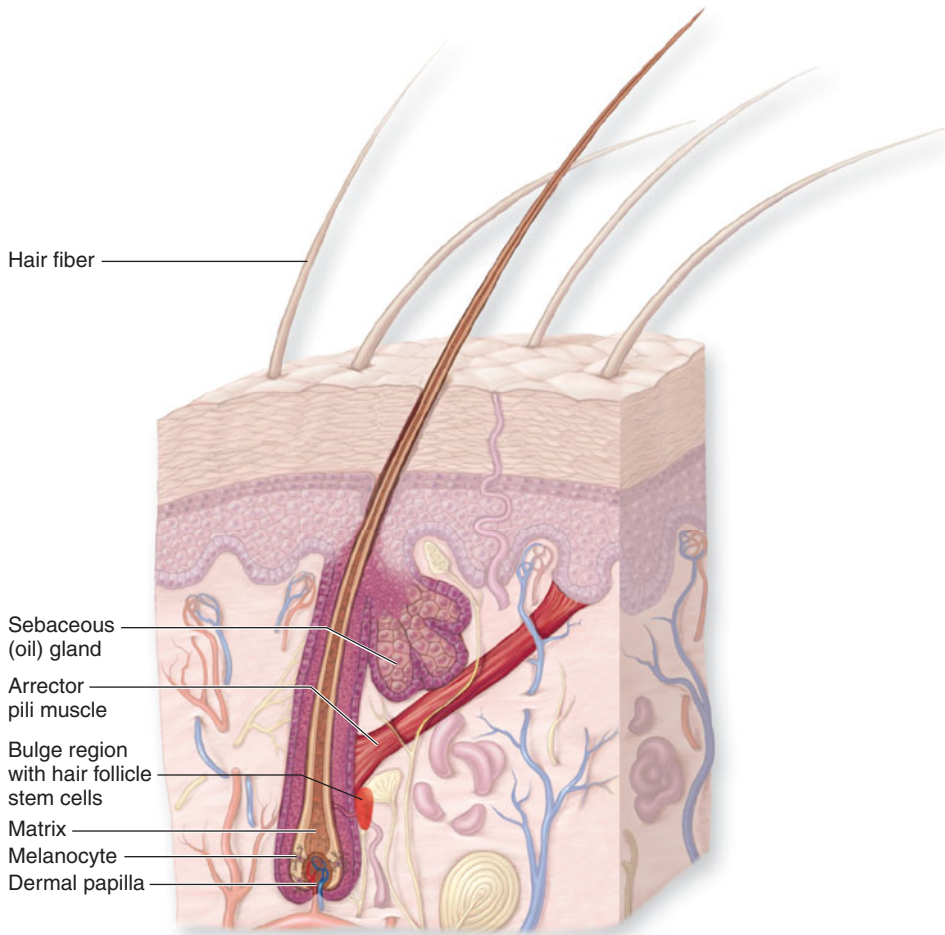
PATHOPHYSIOLOGY

The nonscarring hair disorders associated with abnormalities in the hair cycle include three very common hair disorders:

- Androgenetic alopecia (AGA, with or without androgen excess)
- Alopecia areata (AA)
- Telogen effluvium (TE)

Androgenetic alopecia occurs in genetically susceptible individuals in response to the conversion of testosterone to dihydrotestosterone (DHT) by 5- α reductase at the level of the hair follicle resulting in miniaturization and a shortened anagen phase of the hair cycle. AGA may be associated with hirsutism in women who have excess androgen production from the adrenal glands or ovaries or only in the end organ, the hair follicle.

Alopecia areata is an immune-mediated disease that targets the bulb region of anagen hair follicles resulting in a shortened anagen cycle. **Telogen effluvium** results when more follicles than usual transition to the telogen or loss phase of the hair cycle in response to a trigger. Two less commonly seen disorders of the hair cycle include



▲ **Figure 19-1.** Pilosebaceous Unit (Reproduced with permission from Mescher AL, ed. *Junqueira's Basic Histology: Text & Atlas*. 12th ed. New York: McGraw-Hill; 2010. Figure 18-12A).

hypertrichosis and generalized atrichia (absence of hair), a condition caused by a mutation in the hairless gene that results in normal hair follicle development but abnormal cycling in catagen. Hypertrichosis is defined as elongation of hair in nonandrogen-dependent areas and is commonly seen in patients treated with topical minoxidil or taking cyclosporine.

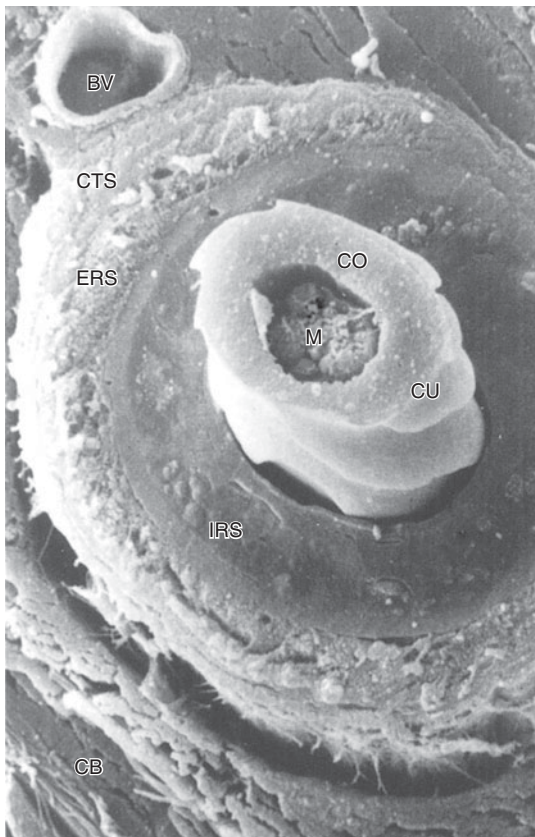
The scarring alopecias are characterized by lymphocytic, neutrophilic, or mixed inflammatory infiltrates that involve the bulge or stem cell region of the hair follicle, leading to fibrosis and permanent hair loss (Figure 19-1). The scarring alopecias may be primary or secondary as in the case of a burn or radiation injury, but in either case permanent loss of hair follicles occurs.

Hair loss may also occur with inherited or acquired structural hair abnormalities. When present, hair fibers break easily resulting in the chief complaint of “hair loss.”

EXAMINATION OF THE PATIENT WITH A HAIR DISORDER

Examination of the patient presenting with a hair disorder and the chief complaint of “hair loss” should focus on assessing the presence or absence of the following:

- Vellus, indeterminate and terminal fibers ideally using scoring systems such as the Ludwig or Hamilton Norwood classification systems, or the Severity of Alopecia Scoring Tool (SALT score).^{2–4} Vellus fibers are short, fine, light-colored, and barely noticeable. Terminal fibers are long, have a wider diameter, and are pigmented. Indeterminate fibers are somewhere in between vellus and terminal fibers.
- Scale, erythema, folliculitis, scarring, or atrophy in the affected area.



▲ **Figure 19-2.** Hair follicle and fiber. Scanning electron microscopic image demonstrating layers of the hair fiber including the medulla (M), cortex (CO), and cuticle (CU) within the hair follicle. Major components of the hair follicle including the inner root sheath (IRS) and external root sheath (ERS) with surrounding connective tissue sheath (CTS) blood vessel (BV) and collagen bundles (CB) are also demonstrated (Reproduced with permission from Kessel RG, Kardon RH. *Tissues and Organs: A Text-Atlas of Scanning Electron Microscopy*. 1979).

- Eyebrow, eyelash, or body hair loss.
- Nail abnormalities, which if present can be a clue to an underlying medical problem associated with the chief complaint of hair loss.
- Findings of androgen excess.

THE NONSCARRING ALOPECIAS

The following disorders are the most common causes of nonscarring alopecia.

- Androgenetic alopecia: Male and female pattern alopecia
- Alopecia areata
- Telogen effluvium

Table 19-1. Questions for the patient presenting with the chief complaint of “hair loss.”

Ask about the following:

- Is the hair loss related to “thinning” or “shedding”?
- Hair care habits
- Use of prescription and nonprescription medications
- Symptoms—pain, itch, burning, is there a hair care product relationship
- Body hair—is there too much or too little?
- Nail abnormalities
- Use of supplements, herbals/botanicals, and any other chemicals
- Family history of hair diseases
- Signs of androgen excess
- History of autoimmune/endocrine diseases
- Recent or chronic illnesses
- Recent surgical procedures
- For females, query about the menstrual cycle/pregnancies

ANDROGENETIC ALOPECIA: MALE AND FEMALE PATTERN ALOPECIA

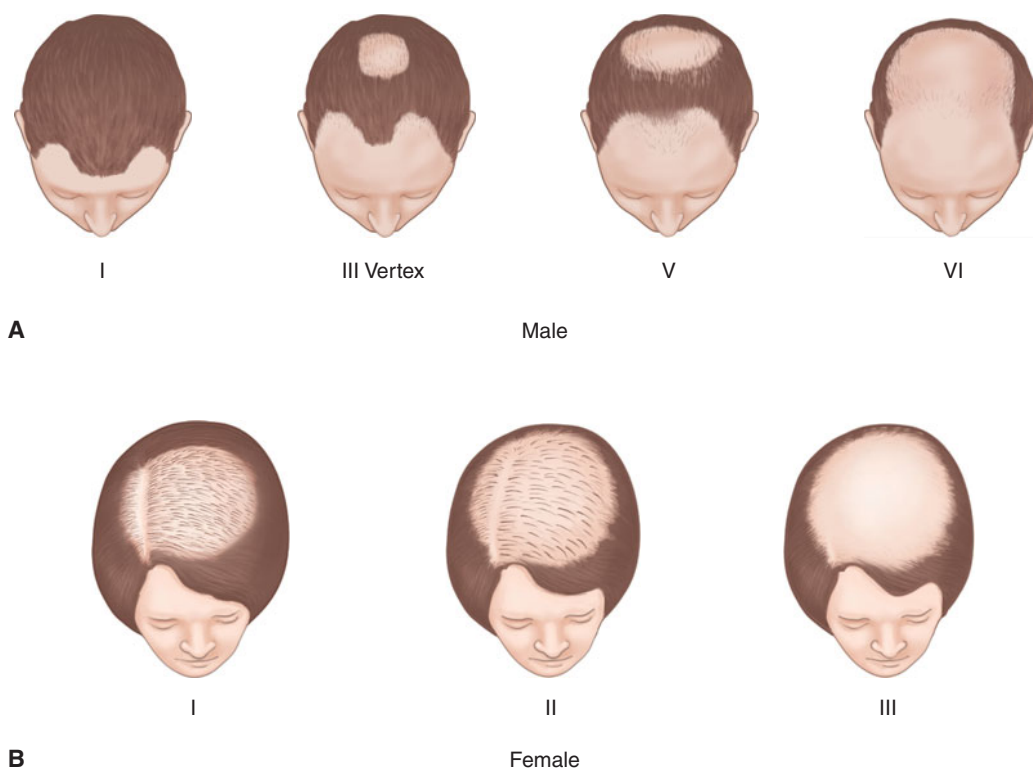
Introduction

Androgenetic alopecia (AGA) in males is commonly called male pattern baldness and is the most common type of hair loss in men, affecting approximately 50% of Caucasian men by age 50.⁵⁻⁷ AGA is characterized by the progressive miniaturization of terminal hairs or shortening of the anagen phase and transition to “baby” vellus fibers on the scalp in a characteristic distribution frequently classified using the Hamilton–Norwood Scale (Figure 19-3A). AGA is considered to be an androgen-dependent trait and the mode of inheritance polygenic with variable penetrance. Balding usually starts in the late teens or early twenties. However, approximately 10% of males will bald in a pattern that resembles female AGA.

Androgenetic alopecia in females is also commonly called female pattern baldness and can be classified using the Ludwig classification scale (Figure 19-3B). Classic AGA

Table 19-2. Physical examination of the patient with a hair disorder and the chief complaint of “hair loss.”

- Closely examine the scalp
- Document
 - Erythema
 - Scale
 - Folliculitis
 - Evidence of scarring
- Look for new hair growth (fibers with tapered ends) or hair breakage
- Pull test
- Note body hair density and distribution
- Document any nail abnormalities
- Use scales—Ludwig, Hamilton/Norwood, SALT, or Ferriman–Gallwey



▲ **Figure 19-3.** Androgenetic alopecia in males and females. **A:** Hamilton-Norwood scale. Types I, III, V, and VI progressive patterns of male androgenetic alopecia (Modified from Olsen EA, Weiner MS, Delong ER, Pinnell SR. Topical minoxidil in early male pattern

baldness. *J Am Acad Dermatol.* 1985;13(2):185–192).

B: Ludwig Classification Scale for females (Reproduced with permission from *Fitzpatrick's Color Atlas & Synopsis of Clinical Dermatology*. 6th ed. New York: McGraw-Hill; 2009. Figure 32-2).

in women is also polygenic and androgen dependent with full expression usually by the mid-twenties. This pattern of alopecia may also occur in the perimenopausal and menopausal periods and may be a presenting feature of ovarian or adrenal gland abnormalities. A clinically useful classification system for women with pattern thinning is as follows:

- Early onset
 - With androgen excess
 - Without androgen excess
- Late onset
 - With androgen excess
 - Without androgen excess

Clinical Presentation

History

Patients usually report increased hair shedding and a noticeable decrease in hair density following one of the patterns described previously.

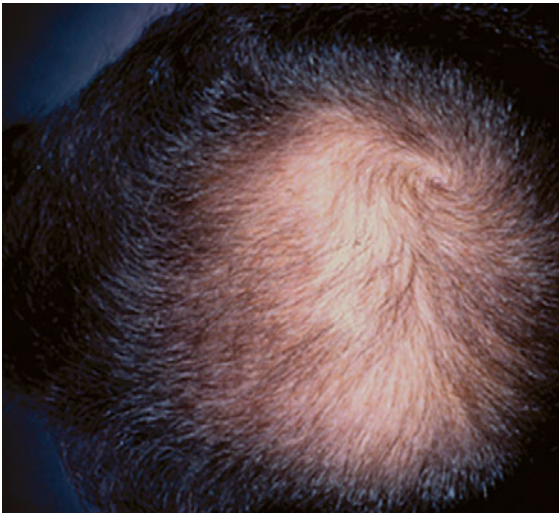
Physical Examination

Males may present with balding initially in the bitemporal regions, followed by the vertex region and when extensive, the two areas are no longer separated as demonstrated in Type VI Hamilton balding (Figure 19-3A). Males may also bald with the thinning process occurring from the anterior scalp to the vertex. Females present with thinning in the frontal scalp region accompanied by an increase in the part width and retention of the frontal hairline. Some patients will also exhibit a “Christmas tree” pattern in the anterior scalp region.

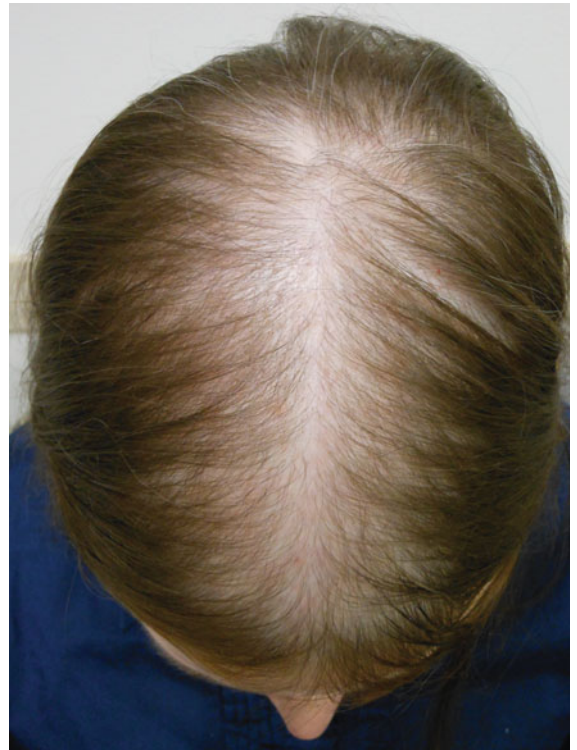The Hamilton Norwood or Ludwig classification systems can be used to document the extent of the pattern alopecia, respectively (Figure 19-4A and B). The physical examination should focus on the areas noted in Table 19-2.

Laboratory Findings

Usually no laboratory studies are required in the evaluation and management of male AGA. Women who present with



A



B

▲ **Figure 19-4.** **A:** Male androgenetic alopecia. The patient demonstrates Hamilton Type IV balding with prominent thinning in the vertex region. **B:** Female androgenetic alopecia. The patient demonstrates retention of the frontal scalp hairline and pattern thinning centrally.

pattern alopecia should be evaluated for associated medical conditions or nutritional deficiencies. A summary of recommended laboratory tests is presented in Table 19-3.

Diagnosis and Differential Diagnosis

The diagnosis of male AGA is usually straightforward. The diagnosis of female AGA /female pattern alopecia may be slightly more complicated as pattern thinning is common in women with metabolic or nutritional disorders.

The differential diagnosis includes diffuse alopecia areata and telogen effluvium both of which will be discussed next. A scalp biopsy may be needed if there is difficulty making a diagnosis.

Management

Medical, surgical, cosmetic, and device treatments can be used to treat AGA. Medical treatments for male AGA include 5% topical minoxidil (Rogaine) in a foam or solution and finasteride (Propecia), an oral inhibitor of dihydrotestosterone (DHT) production. One ml of topical minoxidil should be applied twice daily to the affected area. Clinical response can vary with some men attaining significant hair regrowth while others experience only a reduction in hair loss. Treatment needs to be continued to maintain the result.

Two percent topical minoxidil is approved by the Food and Drug Administration (FDA) in the United States for women. In a double-blind controlled study using oral finasteride, 1 mg daily, no efficacy was demonstrated in postmenopausal women.⁶ For women with early- or late-onset pattern thinning and evidence of androgen excess, the use of antiandrogens may be beneficial.

A minimum of 6 months therapy is recommended to assess efficacy. The success of a therapeutic response is linked to a healthy scalp and any dermatitis or folliculitis should be managed concurrently.

Table 19-3. Basic laboratory evaluation of the patient presenting with a hair disorder and the chief complaint of “hair loss.”

- Thyroid stimulating hormone
- Complete blood count (CBC), ferritin, and iron profiles
- If indicated by history and physical examination, ie, presence of hirsutism
 - Non-cycle dependent hormones such as DHEA-S and total/free testosterone
 - FANA, other autoantibodies
 - Other: zinc, vitamin D, vitamin A, vitamin E, total protein, and other hormones

Other treatment options include the use of the laser comb, a device that was recently approved in the United States for the management of male and female pattern thinning. Hair transplantation is also an option for patients with stable disease. Use of a scalp prosthesis or camouflaging agents such as hair fibers, powder cakes, scalp lotions, or scalp sprays may also be recommended.

ALOPECIA AREATA

Introduction

Alopecia areata (AA) is considered to be a complex genetic, immune-mediated disease that targets anagen hair follicles.^{8,9} It is estimated that AA affects between 4 and 5 million individuals in the United States. In AA, the hair follicle is not destroyed and maintains its potential to regrow hair. The presence of severe nail abnormalities, atopy (asthma, allergic rhinitis, and atopic dermatitis), onset of extensive disease in children less than 5 years of age as well as alopecia totalis or universalis lasting more than 2 years, have all been implicated as negative prognostic indicators. Both males and females of all ages can be affected and there is no known race or ethnic preponderance. AA reportedly affects 1% to 2% of the population and has a lifetime risk of 1.7%. Up to 80% of cases are considered to be sporadic. AA has been reported to occur in all age groups, males and females, and all races.

Clinical Presentation

History

Patients typically complain of asymptomatic patchy hair loss from any hair-bearing area. However, some patients may report a tingling or pruritic sensation with hair loss or hair regrowth.

Physical Examination

The key diagnostic features are round or oval patches of hair loss, loss of all scalp hair (alopecia totalis), loss of all body hair (alopecia universalis), or ophiasis pattern hair loss (Figure 19-5A to D). AA may target any hair-bearing area as well as the nail matrix resulting in benign (ie, pitting) to severe nail disease (ie, onychodystrophy). Some patients may also present with a diffuse decrease in scalp hair density. Patches may resolve spontaneously, persist or recur. Episodes may last for days to months to years.

The Severity of Alopecia Scoring Tool (SALT) can be used to provide an assessment of scalp hair loss and can be used as a tool to monitor therapy.⁴ Disease activity can be assessed by doing light hair pull tests (Figure 19-6). Describing the types of fibers present on the scalp may be helpful with setting treatment expectations. A complete examination as outlined in Table 19-2 should be done and any dermatitis present should be treated.

Laboratory Findings

AA may occur with other immune-mediated diseases so in addition to the laboratory studies noted in Table 19-3, additional autoantibody and immune studies may be indicated based on the history and physical examination.

Diagnosis and Differential Diagnosis

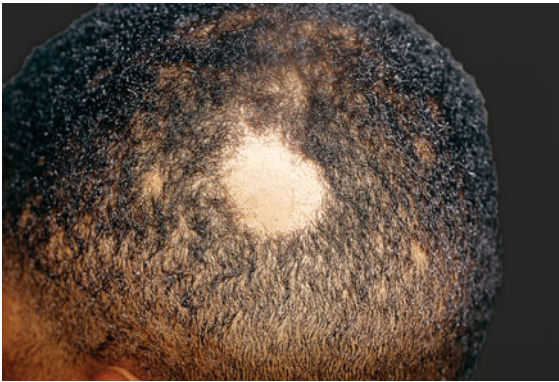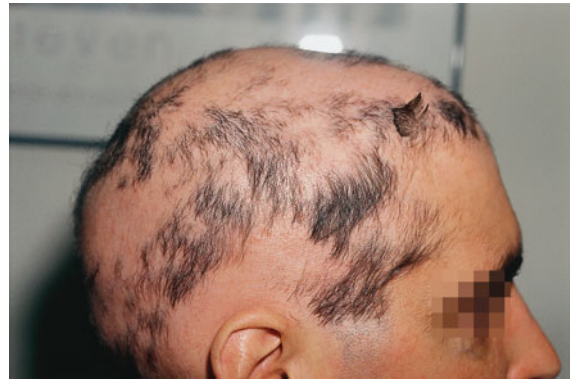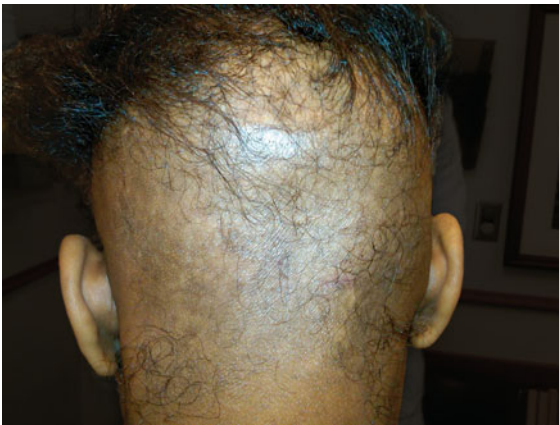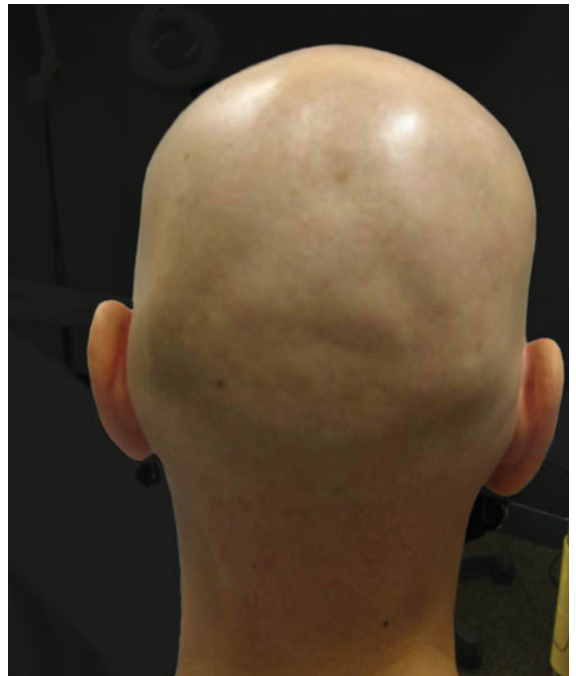AA is usually quite easy to diagnose. Hair diseases in the differential diagnosis for patchy disease include tinea capitis and trichotillomania, a hair disorder characterized by hair pulling in unique shapes. The differential diagnosis for extensive AA includes papular atrichia as well as an ectodermal dysplasia. For patients with the diffuse variant of AA, the clinical picture may be confused with telogen effluvium or in some cases, pattern alopecia. If the diagnosis is not straightforward, examination of a 4-mm scalp biopsy specimen may be beneficial and will demonstrate peribulbar lymphocytes around affected anagen follicles.

Management

No drug is currently approved by the FDA in the United States for the treatment of AA. Many therapies are available and current treatment choices are frequently based on disease extent, duration, and age of the patient. In some situations, patients may choose “no treatment.” Spontaneous remission can occur as is seen with other autoimmune diseases. Commonly used treatments for patchy disease include application of topical class I steroids or intralésional triamcinolone acetonide (Kenalog) up to 10 mg/cc, 4 cc per session every 6 weeks. Topical minoxidil is commonly added if there are vellus or indeterminate fibers present. Topical anthralin is another option. Steroid side effects need to be monitored and irritation from anthralin may prevent its use. For active disease characterized by positive hair pull tests and progressive hair loss, oral corticosteroids may be given in a tapering course over several weeks in an attempt to halt disease activity and in some cases, therapy may also be associated with hair growth. A problem with oral corticosteroid therapy is that treatment may be associated with sustained hair regrowth in only about a third of treated patients. Other patients will be steroid nonresponders or require ongoing treatment to maintain hair growth.

Extensive AA (alopecia totalis and alopecia universalis) in both children and adults can be very challenging to treat and many treatments are available. These include not only oral prednisone but also other immunosuppressive drugs, pulse methylprednisolone, narrow band ultra violet B-light, and combination therapy.

Assessing efficacy of treatments for patchy and extensive AA is complicated by the fact that there are few published randomized controlled trials. There are many published uncontrolled trials and reports with nonideal criteria to evaluate treatment. Long-term follow-up is unfortunately

**A****B****C****D**

▲ **Figure 19-5.** Alopecia areata. **A:** Limited patchy. **B:** Extensive patchy. **C:** Ophiasis pattern. Hair loss in a band-like distribution above the ears and lower posterior scalp. **D:** Extensive—alopecia totalis.

not included in most of the published works. More clinical and translational research is forthcoming.

TELOGEN EFFLUVIUM

Introduction

Telogen effluvium (TE) is a very common hair loss condition that can be seen in all races and ethnic groups.^{10–12} The chief complaint is increased hair shedding that is the result of a shortened anagen phase and premature conversion to telogen (Figure 19-7A). TE has been categorized into

different subsets, which may be helpful in explaining the process to patients. Some examples are given below.

- Immediate anagen release occurs after a high fever or illness.
- Delayed anagen release occurs in the postpartum period.
- Short anagen is seen in patients who report not having to cut their hair frequently or that their hair does not grow.
- Immediate telogen release is typically seen after beginning topical minoxidil.
- Chronic TE is commonly reported in middle-aged women in their fourth to sixth decades (Figure 19-7B).



▲ **Figure 19-6.** Light hair pull test. Several fibers are grasped and pulled lightly. Presence of six or more fibers on a light hair pull test is considered to be positive.

Clinical Presentation

History

The chief complaint is increased scalp hair shedding related to a trigger. TE can be associated with the onset of AGA, the postpartum period, medications, weight loss, endocrine disorders, physiological and metabolic stress, nutritional

deficiencies, acute and chronic illness, after surgeries, and with scalp inflammation. When the inciting trigger can be identified and be removed or treated, hair shedding may diminish and regrowth may occur.

Physical Examination

The assessment of telogen hair loss may be made using several methods, two common methods include:

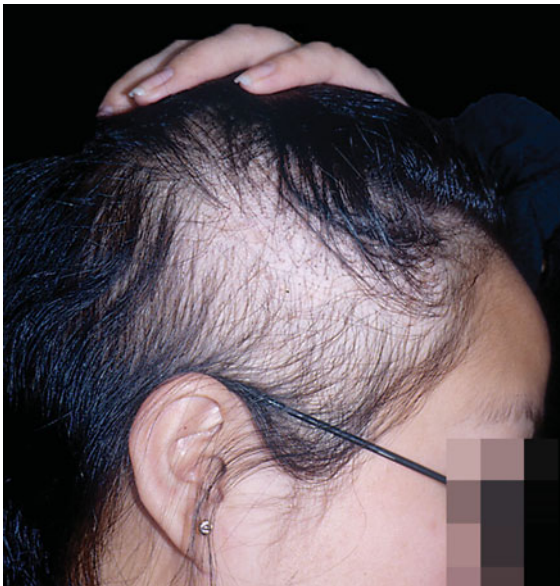- **Hair pluck.** Approximately fifty hairs are plucked using a rubber-tipped hemostat and the anagen–telogen ratio is assessed by examination of the hair bulbs.
- **Collection of fibers shed daily** for at least 1 to 2 weeks. The scalp should be shampooed daily and fibers collected daily after shampooing and put into dated, labeled envelopes. Anagen and telogen fibers are then qualitatively assessed. If shampooing is less frequent, it is to be expected that there will be a greater number of shed telogen fibers in the sample collected on a shampoo day as hair cycling continues on a daily basis and telogen fibers “rest” in follicles and are then released with the shampoo process.

Laboratory Findings

If a patient is taking several supplements, additional laboratory studies to those outlined in Table 19-3 may need to be ordered. For example, high levels of Vitamin A or E may be associated with scalp hair shedding.

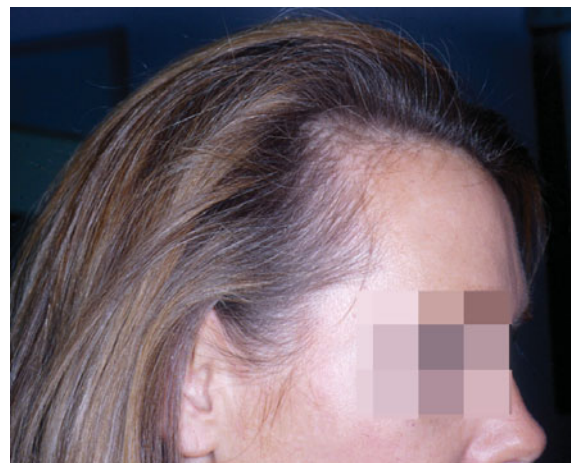Diagnosis and Differential Diagnosis

The diagnosis of TE can be established with the hair pluck test or sample collection as described previously. A scalp biopsy may also be done to confirm the shift to telogen.



A

▲ **Figure 19-7.** Telogen effluvium. **A:** Female patient with diffuse hair thinning secondary to a severe telogen effluvium. Hair regrowth is expected with



B

removal of the inciting trigger. **B:** Female patient with chronic telogen effluvium. Clinical clue is the significant thinning in the temporal regions.

The differential diagnosis includes diffuse AA, AGA, and possibly an inflammatory alopecia such as central centrifugal alopecia or lichen planopilaris, especially when the hair loss is primarily in the central scalp region.

Management

Successful treatment depends on controlling transitions between stages of the hair cycle and moving follicles from telogen to anagen. Topical minoxidil does induce anagen differentiation and may be tried. Currently there are no good tools to easily and safely control hair cycle transitions.

CICATRICAL (SCARRING) ALOPECIAS

Introduction

The pathogenesis of the cicatricial or scarring alopecias is not well understood.^{13,14} The early stages of the cicatricial alopecias may be distinguished clinically, but the end stages are indistinguishable and are all characterized by permanent injury and scarring.

The cicatricial alopecias are unique clinically and histologically. They are broadly characterized by their inflammatory infiltrate, either lymphocytic, neutrophilic, or mixed. Treatments may control signs and symptoms but do not normally influence the underlying disease process and when discontinued, clinical activity frequently recurs.

Clinical Presentation

History

Affected patients will frequently complain not only of hair loss, but also severe pain or burning. Some patients may describe their scalp “being on fire” while others will be almost asymptomatic.

Physical Examination

The cicatricial alopecias are categorized clinically and histologically and are described as lymphocytic or neutrophilic or mixed.

Some of the more common lymphocytic cicatricial alopecias include:

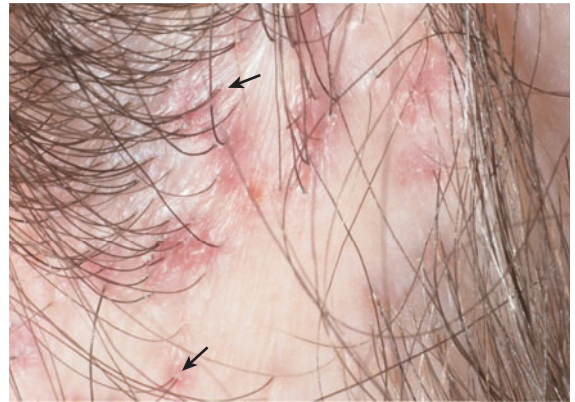- Lichen planopilaris (Figure 19-8)
- Frontal fibrosing alopecia (Figure 19-9)
- Discoid lupus erythematosus (Figure 19-10)
- Central centrifugal scarring alopecia (Figure 19-11)

Common neutrophilic cicatricial alopecias include:

- Folliculitis decalvans (Figure 19-12)
- Dissecting cellulitis (Figure 19-13)

Examples of mixed cicatricial alopecias include:

- Acne keloidalis (Figure 19-14)

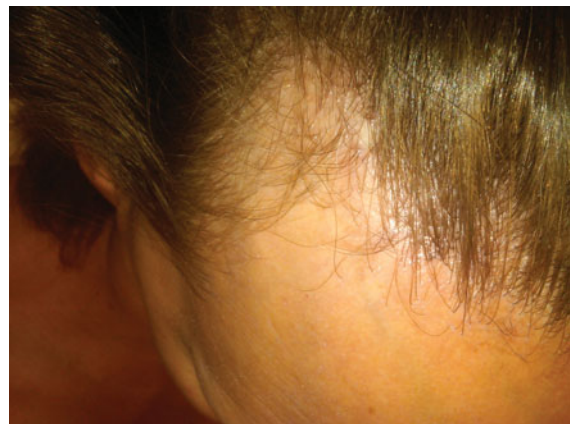

▲ **Figure 19-8.** Lichen planopilaris. Scarring with perifollicular scale and inflammation (Reproduced with permission from *Fitzpatrick's Color Atlas & Synopsis of Clinical Dermatology*, 6th ed. New York: McGraw-Hill; 2009. Figure 32-18).

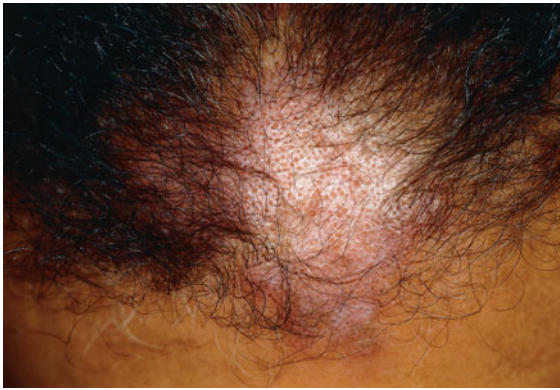- Acne necrotica
- Erosive pustular dermatosis, an idiopathic, chronic, relapsing pustular dermatosis of the scalp that is frequently preceded by a history of trauma.

Laboratory Findings

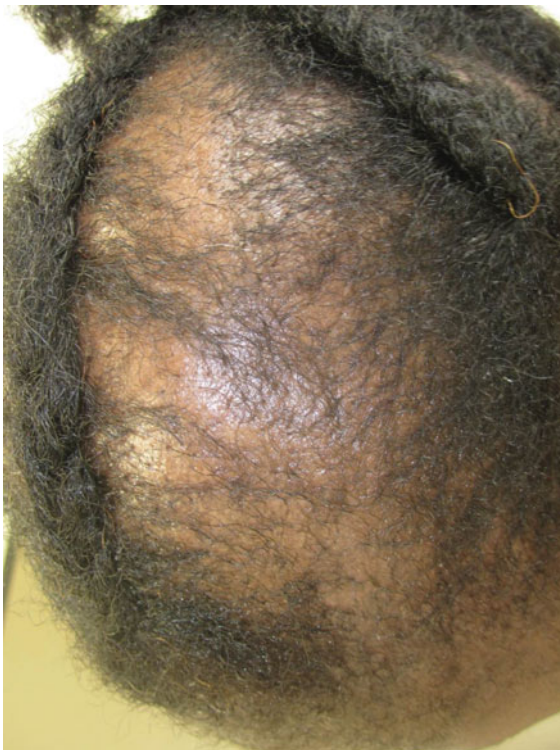There are no required blood tests for patients with cicatricial alopecias. Bacterial cultures may be beneficial if the pustular component does not respond to standard treatment. In some cases, a scalp biopsy for tissue culture will be needed to isolate the organism contributing to the ongoing inflammatory process. *Staphylococcus aureus* is commonly found on tissue culture examination.



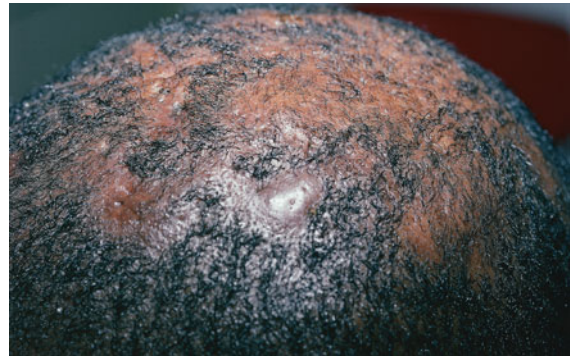
▲ **Figure 19-9.** Frontal fibrosing alopecia. There is regression of the hairline secondary to the scarring process and perifollicular inflammation is present at the active margin.



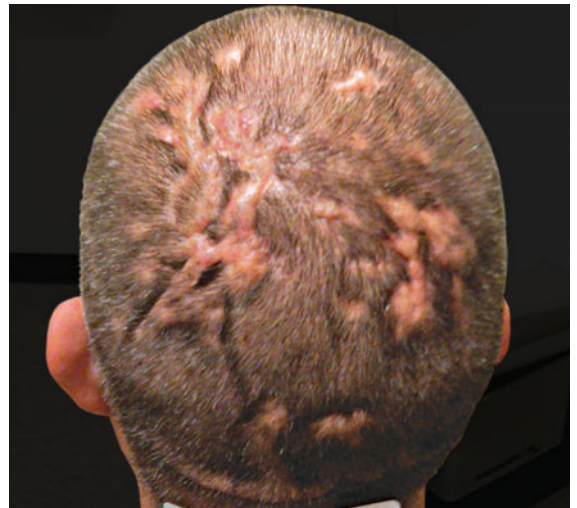▲ **Figure 19-10.** Discoid lupus erythematosus. In contrast to lichen planopilaris, inflammation is present within the affected area rather than the periphery. Hyperkeratosis and accentuation of the hair follicle orifices are noted.



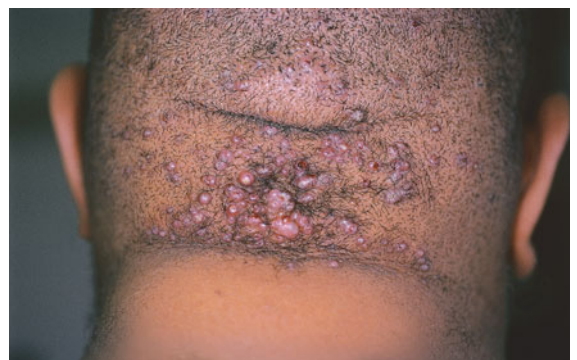▲ **Figure 19-11.** Central centrifugal scarring alopecia. Central scalp scarring with extension to the temporal region and peripheral inflammation.



▲ **Figure 19-12.** Folliculitis decalvans. Follicular papules, patchy scarring alopecia, some crusting from draining pustules.



▲ **Figure 19-13.** Dissecting cellulitis. Nodules, patchy scarring alopecia, and boggy plaques with sinus tract formation.



▲ **Figure 19-14.** Acne keloidalis. Discrete and grouped papules with hypertrophic scars.

Diagnosis and Differential Diagnosis

The diagnosis of a cicatricial alopecia can be made clinically but when in doubt a scalp biopsy from an active area for histologic examination may be done to confirm the diagnosis as well as to assess the degree and extent of inflammation and follicle injury. If the question is whether there are any hair follicles left in the clinically scarred area that can respond to medical therapy, a biopsy may be helpful to confirming the presence or absence of any hair follicles.

Management

The choice of treatment for the lymphocytic cicatricial alopecias is usually based on clinical activity, severity of symptoms, and disease activity. Treatments can be grouped into three tiers.

- Tier 1 treatments for patients with limited active disease include topical high potency corticosteroids or intralesional steroids or topical nonsteroidal anti-inflammatory creams such as tacrolimus or pimecrolimus.
- Tier 2 treatments for patients with moderate disease include hydroxychloroquine, low dose oral antibiotics for their anti-inflammatory effect, or specific antimicrobial effect or acitretin.
- Tier 3 treatments include immunosuppressive medications such as cyclosporine, prednisone, or mycophenolate mofetil.

For patients experiencing a neutrophilic cicatricial alopecia, pustules should be cultured and antibiotic sensitivities determined. Treatment may be needed for months. The addition of prednisone may improve efficacy and the use of retinoids may or may not be helpful. Oral L-tyrosine administration, laser hair removal, and intranasal eradication of *S. aureus* have all also been advocated.

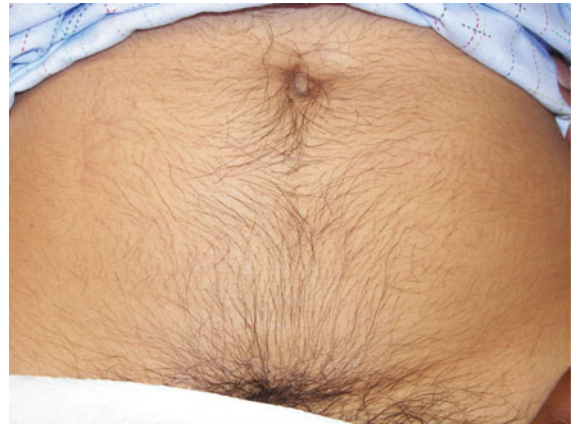Significant scientific breakthroughs related to lipid metabolism abnormalities involving peroxisomes and peroxisome proliferator-activated receptor gamma (PPAR- γ) have been made recently in the cicatricial alopecias. This has opened the opportunity to consider the use of drugs such as pioglitazone hydrochloride in affected individuals.

For patients experiencing a mixed type of cicatricial alopecia, treatments can be any combination of those recommended for the lymphocytic or neutrophilic cicatricial alopecias.

HIRSUTISM

Introduction

Hirsutism is defined as the presence of terminal hair growth following a similar pattern to that developing in androgen-dependent sites in men after puberty (Figure 19-15).^{15,16} Two to eight percent of the American



▲ **Figure 19-15.** Hirsutism. Excess terminal hair growth in the linea alba (Reproduced with permission from Hoffman BL, Schorge JO, Schaffer JL, Halvorson LM, Bradshaw KD, Cunningham FG, Calver LE, eds. *Williams Gynecology*. 2nd ed. New York: McGraw-Hill; 2012. Figure 17-2B).

population are considered to have hirsutism depending on the chosen cutoff for the Ferriman–Gallwey score, a scoring system in which 9 androgen-sensitive sites (upper lip, chin, chest, upper and lower abdomen, arms, thighs, upper back, and lower back) are assessed, with a maximum grade of 4 points for each area. The degree of hair growth in each area is graded from 1 (minimal terminal hair growth) to 4 (frank virilization). The scores are then summed with a total score of 8 or more indicating hirsutism.

Hirsutism may be inherited. It is well known that East Asian, North Asian, and Southeast Asian populations have less body hair and a lower incidence of hirsutism than do Caucasians, or those of West Asian or Middle Eastern descent. Hirsutism may also be drug induced or associated with aging.

Pathophysiology

Hirsutism can also be caused by any of the following:

- An increase in the actual amount of androgens produced by any of the three major sources of androgens: the ovaries, adrenal glands, or skin.
- An increase in androgen receptor sensitivity at the level of the hair follicle.
- Enhanced activity of 5- α reductase.

Two ovarian causes of hirsutism include polycystic ovarian syndrome and ovarian tumors. Two adrenal gland causes include congenital adrenal hyperplasia with 21-hydroxylase deficiency being most common and adrenal gland tumors. Other less common causes of congenital adrenal hyperplasia include 11 β -hydroxylase deficiency and 3 β -ol-dehydrogenase deficiency.

Clinical Presentation

History

Women with hirsutism will present with concerns about increased dark hair growth on any or all of the following areas: upper lip, chin, chest, upper and lower abdomen, arms, thighs, upper back, and lower back.

Physical Examination

The examination should be directed toward describing (1) the location and amount of excess terminal hair growth using the Ferriman–Gallwey scale and (2) identifying other signs of androgen excess including the following:

- Alopecia
- Acne
- Deepening of the voice
- Clitoral enlargement
- Signs of Cushing's syndrome
 - Central obesity
 - Acanthosis nigricans
 - Striae
 - Buffalo hump

Laboratory Findings

In addition to checking a testosterone level and when indicated, dihydrotestosterone and dehydroepiandrosterone sulfate levels, the following may be useful in ruling out a secondary cause of hirsutism:

- Androstenedione
- Dexamethasone suppression test
- Follicle stimulating hormone
- Luteinizing hormone
- Serum prolactin
- Thyroid studies
- 17-hydroxyprogesterone level

Diagnosis and Differential Diagnosis

Hirsutism can be end organ specific (hair follicle androgen excess only), inherited or associated with ovarian or adrenal gland disease. Hirsutism may also be associated with hyperprolactinemia, acromegaly, postmenopausal androgen therapy, thyroid dysfunction, and use of anabolic steroids.

Management

13.9% Eflornithine (Vaniqa) cream is FDA approved for the management of hirsutism and is applied topically twice a day. Several other medications can also be used off-label to treat hirsutism. The risk/benefit ratio of each of these

drugs needs to be carefully considered when prescribing any of the following for the medical management of hirsutism.

Medications prescribed for hirsutism include spironolactone, finasteride, flutamide, cyproterone acetate as well as leuprolide acetate, bromocriptine, and metformin. Any combination or oral contraceptives can be used but those with non-androgenic progestins are considered to be the best. Adrenal gland suppression of androgen production can be obtained with dexamethasone or prednisone.

Mechanical treatments are also available for managing hirsutism. These include epilation with tweezing, waxing, sugaring or threading, chemical depilation, bleaching, electrolysis, light treatment with intense pulse light (IPL), the diode, or Nd:YAG laser. The latter can be safely and effectively used to treat individuals with light and darker-skin pigmentation.

Indications for Consultation

A consultation to dermatology should be requested when the hair disease is difficult to diagnosis or if the hair loss or excessive hair growth are progressing despite appropriate therapy. If anxiety about hair loss and change in body image are the main problems, consider referral to psychology or psychiatry. If androgen excess with associated scalp hair thinning and hirsutism persists despite appropriate therapy, a referral to endocrinology is recommended.

Patient Information

- The Cicatricial Alopecia Research Foundation (CARF) www.carfintl.org supports research and provides excellent information for patients with any cicatricial or scarring alopecia.
- The National Alopecia Areata Foundation (NAAF) www.naaf.org supports research and patients and families dealing with alopecia areata.
- The North American Hair Research Society (NAHRS) www.nahrs.org/Cached-Similar is another source of information.

REFERENCES

1. Paus R, Cotsarelis G. The biology of hair follicles. *N Engl J Med*. 1999;341(7):491–497. PMID: 10441606.
2. Hamilton JB. Patterned loss of hair in man: types and incidence. *Ann NY Acad Sci*. 1951;53(3):708–728. PMID: 14819896.
3. Ludwig E. Classification of the types of androgenetic alopecia (common baldness) occurring in the female sex. *Br J Dermatol*. 1977;97(3):247–254. PMID: 921894.
4. Olson EA, Hordinsky M, Price VH, et al. Alopecia areata investigational guidelines—Part II. *J Am Acad Dermatol*. 2004;51(3):440–447. PMID: 15337988.
5. Olsen E, Messenger AG, Shapiro J, et al. Evaluation and treatment of male and female pattern hair loss. *J Am Acad Dermatol*. 2005;52(2):301–311. PMID: 15692478.

6. Price VH, Roberts JL, Hordinsky M, et al. Lack of efficacy of finasteride in postmenopausal women with androgenetic alopecia. *J Am Acad Dermatol*. 2000;43(5 Pt 1):768–776. PMID: 11050579.
7. Shapiro J. Hair loss in women. *N Engl J Med*. 2007;357(16):1620–1630. PMID: 17942874.
8. Gilhar A, Etzioni A, Paus R. Alopecia areata. *N Engl J Med*. 2012;366(16):1515–1525. PMID: 22621196.
9. Hordinsky MK. Treatment of alopecia areata: what is new on the horizon? *Derm Ther*. 2011;24(3):364–368. PMID: 21689246.
10. Headington JT. Telogen effluvium. New concepts and review. *Arch Dermatol*. 1993;129(3):356–363. PMID: 8447677.
11. Whiting DA. Chronic telogen effluvium. *Dermatol Clin*. 1996;14(4):723–731. PMID: 9238330.
12. St. Pierre SA, Vercellotti GM, Donovan JC, Hordinsky MK. Iron deficiency and diffuse alopecia in women: more pieces to the puzzle. *J Am Acad Dermatol*. 2010;63(6):1070–1076. PMID: 20888064.
13. Ross EK, Tan E, Shapiro J. Update on primary cicatricial alopecias. *J Am Acad Dermatol*. 2005;53(3):1–37. PMID: 15965418.
14. Karnik P, Tekeste Z, McCormick TS, et al. Hair follicle stem cell-specific PPAR gamma deletion causes scarring alopecia. *J Invest Dermatol*. 2009;129(5): 1243–1257. PMID: 19052558.
15. Rosenfield RL. Hirsutism. *N Engl J Med*. 2005;353(24):2578–2588. PMID: 16354894.
16. Ferriman D, Gallwey JD. Clinical assessment of body hair growth in women. *J Clin Endocrinol Metab*. 1961;21:1440–1447. PMID: 13892577.

20

Nail Disorders

Andrea Bershow

Introduction to Chapter / 188
Nail Anatomy / 188
Clinical Presentation / 189

Indications for Consultation / 193
References / 193

INTRODUCTION TO CHAPTER

Nails have several important functions. The nail plate acts as a protective shield for the fingertips; it assists in grasping and manipulating small objects. Our nails are also used for scratching, grooming, and cosmetic adornment.¹

NAIL ANATOMY

The nail unit is composed of the nail plate, nail matrix, nail folds, nail bed, and hyponychium (Figure 20-1A and B).^{1,2}

- **Nail matrix:** Forms the nail plate.
- **Nail plate:** Hard, translucent, keratin-containing structure covering the dorsal surface of the distal digits on the hands and feet. Formed by the nail matrix, the nail plate grows out from under the proximal nail fold. The nail usually appears pink, which is due to the underlying vasculature of the nail bed. The small, white, semi-circular structure at the proximal portion of the nail is the lunula, which is the visible portion of the nail matrix.
- **Nail bed:** Structure underlying the nail plate, which contributes to the nail plate's ability to attach to the finger.
- **Hyponychium/onychodermal band:** Under the distal free edge of the nail. The hyponychium is the transition point between the nail and the normal skin of the digit. The onychodermal band is the point of strongest attachment between the nail and the underlying digit.

- **Nail folds:** Proximal and lateral. These are epithelial structures. The cuticle protects the matrix by sealing off the potential space between the nail plate and the proximal nail fold.

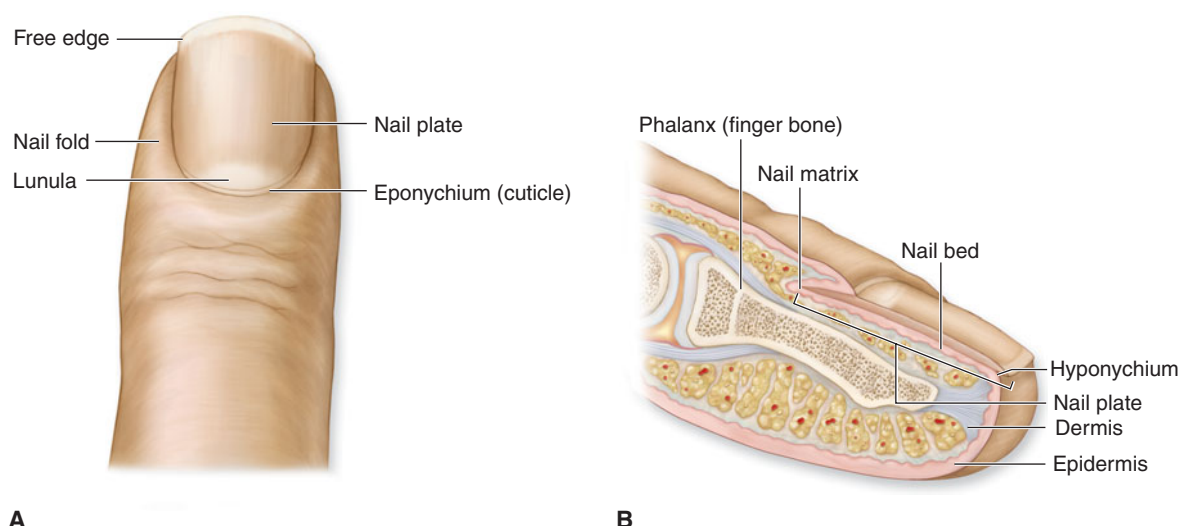
Differential Diagnosis

Nail disorders can be difficult to differentiate from one another. To determine the correct diagnosis takes practice and often laboratory studies such as fungal cultures. To add to the confusion, many nail disorders can have secondary fungal or bacterial infections.

Examples of specific diseases in each category include:

- ✓ **Infectious:** Dermatophyte, candida, mold, and bacteria.
- ✓ **Papulosquamous:** Psoriasis and lichen planus.
- ✓ **Traumatic:** Habit tic, some cases of onychodystrophy or onycholysis.
- ✓ **Systemic:** Yellow nail syndrome, clubbing, and Beau's lines.
- ✓ **Tumors:** Squamous cell carcinoma, melanoma, and benign tumors.

Tumors involving the nail unit are an important category of nail disorders. These are covered in other sections of this textbook are covered in Chapters 16, 17 and 18.



▲ **Figure 20-1.** (A, B) Anatomy of the nail (Reproduced with permission from Mescher AL, ed. *Junqueira's Basic Histology: Text & Atlas*. 12th ed. New York: McGraw-Hill; 2010. Figure 18-14A & B).

A differential diagnosis of nail disorders and clinical findings that distinguish them from one another are presented in Table 20-1.

CLINICAL PRESENTATION

Infectious

► Fungal

Dermatophyte, mold, and candida infections of the nails are common causes of nail disorders. They closely resemble other nail disorders such as psoriasis. Fungal infections of the nails are covered in Chapter 10.

► Bacterial

Bacteria can also infect the nail unit. *Pseudomonas* is a common colonizer of onycholytic nails.² The affected nail is usually discolored green or black (Figure 20-2). Patients often have a history of wet-work. Bacterial cultures of pus or nail clippings can confirm the diagnosis. Treatment involves trimming the onycholytic portion of the nail and the use of one of the following topical therapies: soaking affected nails 2 to 3 times a day in a dilute bleach solution (2% sodium hypochlorite) or half-strength vinegar solution; and application of polymyxin B, chlorhexidine solution, 15% sulfacetamide, gentamicin or chloramphenicol ophthalmological solution or octenidine dihydrochloride 0.1% solution for 4 weeks or until resolved.^{2,3} Systemic antibiotics should not be administered unless there are signs of cellulitis.

Papulosquamous

► Psoriasis

Psoriasis is a common cause of nail disease. Patients often report a personal or family history of psoriasis. Patients with nail involvement are more likely to have psoriatic arthritis, so it is important to ask about a history of joint pain. Nail psoriasis significantly impacts patients' quality of life with pain and negative impact on activities of daily living, professional activities, and housework.⁴ Severe nail psoriasis is associated with a higher risk of depression and anxiety.⁴ Psoriasis of the nails commonly presents with pitting, onycholysis, subungual debris, and discoloration (Figure 20-3). The nails will usually be negative for fungal elements with examination of a potassium hydroxide (KOH) preparation; however, psoriatic nails can be secondarily infected with a dermatophyte. Punch biopsy of an involved area of the nail unit (nail bed or matrix) can confirm the diagnosis.⁵ Treatment of nail psoriasis is challenging. High-potency topical corticosteroids (betamethasone or clobetasol) with or without vitamin D analogues (calcitriol or calcipotriol) can be used. For nail matrix lesions, these medications should be applied to the proximal nail fold. For nail bed lesions, the onycholytic nail should be trimmed back and the medications should be applied to the nail bed. Tazarotene gel 0.1% applied at bedtime to involved nail plates may improve onycholysis and pitting.¹

► Lichen Planus

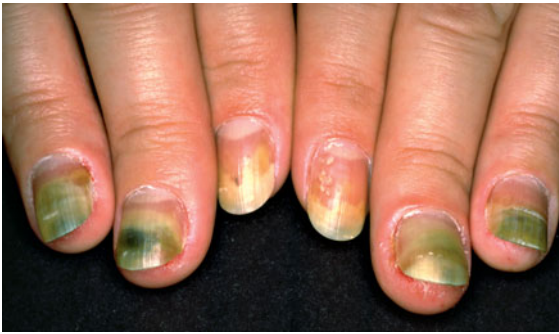Nail lichen planus commonly occurs in isolation without any evidence of skin or mucosal lichen planus, but about

Table 20-1. Differential diagnosis of nail disorders.

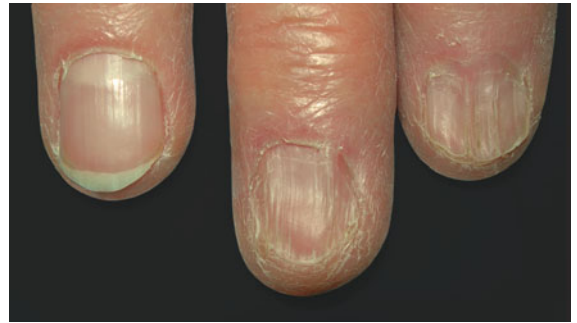
Nail Disease	Clinical Findings
Infectious	
Onychomycosis	Brown, yellow, orange or white discoloration, thickened nail plate, subungual hyperkeratosis, onycholysis
Pseudomonas infection	Green or black discoloration of nail plate. Onycholysis is usually present. Paronychia is common
Papulosquamous	
Psoriasis	Nail matrix involvement: Pitting is broader and more irregular than pitting due to alopecia areata, leukonychia, erythema of lunula, crumbling of nail plate Nail bed involvement: Discoloration (oil drop—yellow or salmon patch—red), splinter hemorrhage, subungual hyperkeratosis, or onycholysis
Lichen planus	Thinning of nail plate with longitudinal ridging and fissuring. Dorsal pterygium is almost pathognomonic for nail lichen planus. The matrix is scarred and the nail plate is divided into two distinct sections
Associated with systemic diseases	
Beau's lines	Horizontal, depressed, white, nonblanching bands of the nail plate. Can be caused by systemic insults, drugs, or trauma
Clubbing	Overcurvature of the nail. Can be idiopathic or related to cardiovascular, pulmonary, or gastrointestinal disorders
Koilonychia	Also called spoon nails. The center of the nail is depressed relative to the edges. Can be caused by iron deficiency, hypothyroidism, trauma, or be congenital
Half and half nails	Also called Lindsay's nails. The proximal half of the nail is normal or white and the distal half is darker. Can be caused by renal disease
Mee's lines	Single or multiple transverse white lines, usually present on all nail plates. Classically caused by arsenic poisoning, but can be the result of many other systemic insults
Splinter hemorrhage	Small, longitudinal lines of dark discoloration. Should grow out with the nail plate. Usually caused by trauma, but can be related to systemic illnesses, or drugs. If the lesions occur distally on a single nail, it is less likely to be related to a systemic cause
Terry's nails	The nails are white proximally, with a narrow pink or brown distal band. Can be related to liver disease or aging
Yellow nail syndrome	Diffuse yellow, thickened nail plates. Most commonly seen with lung disease and chronic lymphedema
Other	
Alopecia areata	Superficial, regular, geometric pitting most common. The pitting is much more regular than pitting due to psoriasis
20-Nail dystrophy (trachyonychia)	Nails have a roughened surface, longitudinal ridging, and thinning. Nail plates have a sandpaper appearance Look for skin or hair abnormalities suggestive of lichen planus, psoriasis, or alopecia areata to help identify the underlying cause
Habit tic deformity	Roughly parallel, horizontal depressions most often over the median nail plate
Onycholysis	Nail plate appears white due to air between the nail plate and nail bed

10% of patients with mucosal membrane or skin lichen planus also have nail involvement.^{2,5} Nail lichen planus usually has an abrupt onset with longitudinal ridging, thinning, and fissuring of the nail plate (Figure 20-4). Pain may be present.² Biopsy may be necessary for diagnosis in the absence of skin or mucous membrane findings. Early treatment may avert the possibility of pterygium

formation. Once present, a pterygium is permanent and will not respond to any treatment. First-line treatment for nail lichen planus is systemic or intralesional corticosteroids.² Systemic retinoids can also be used.⁵ There are reports of success with topical tacrolimus⁶ and a combination of topical tazarotene and clobetasol under occlusion.⁷



▲ **Figure 20-2.** Onycholysis with pseudomonas colonization. Green discoloration of the undersurface of nail plates.



▲ **Figure 20-4.** Lichen planus. Longitudinal ridging and thinning of nail plate with early pterygium formation.

Systemic

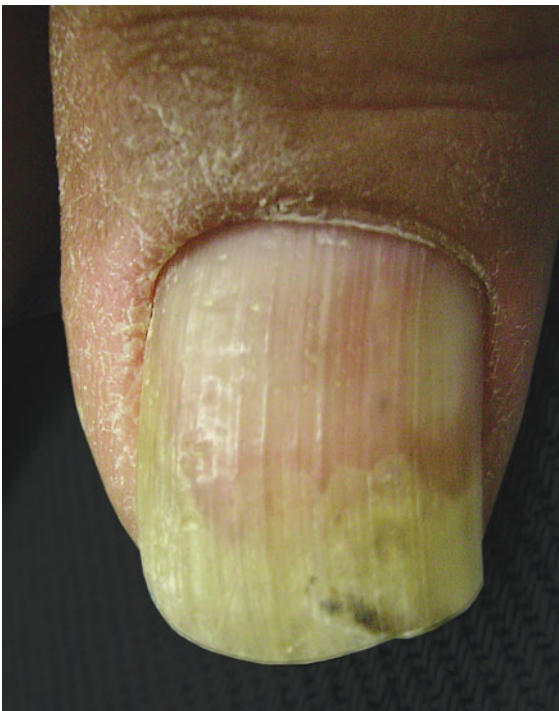▶ Beau's Lines

Beau's Lines appear after a disruption of nail formation in the matrix. They present as horizontal, depressed, white, nonblanching, bands of the nail plate (Figure 20-5). The depth of the line corresponds to the severity of damage,

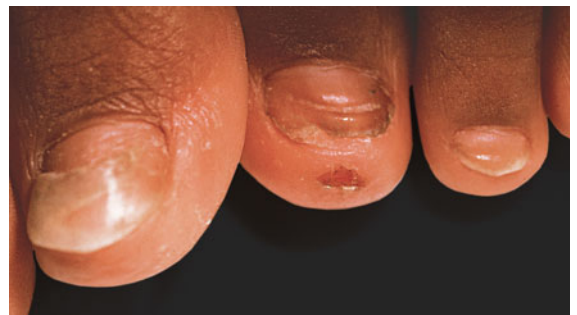and the width corresponds to the length of exposure.⁸ One can usually elicit a history of major systemic stress due to illness, surgery, accident, or history of exposure to a causative medication. Associated medications include chemotherapeutic medications and systemic retinoids.⁸ No treatment is necessary since the lines will resolve when the affected nail plate grows out. However, the lesions will continue to occur with repeated administration of causative medications or repeated illness.

▶ Yellow Nail Syndrome

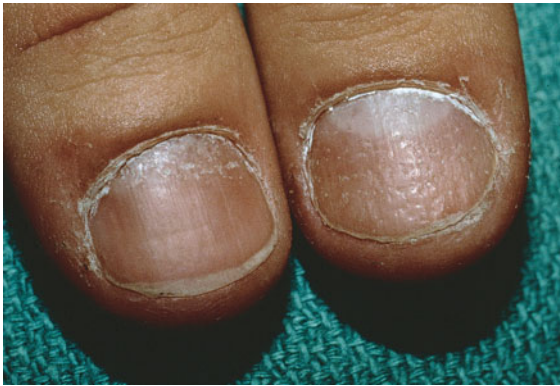Yellow nail syndrome is commonly seen as part of a triad with lung disease and chronic lymphedema. Most patients are between the fourth and sixth decades of life, but cases have been reported in children and infants.⁹ It can also be associated with rheumatoid arthritis, chronic obstructive pulmonary disease, bronchiectasis, chronic bronchitis, sinusitis, carcinoma of the larynx and other malignancies, and thyroid disease. Yellow nail syndrome may be inherited or congenital.² Patients may have a history of associated conditions, or a family history of the



▲ **Figure 20-3.** Psoriasis. Nail pits, onycholysis, and "oil drop" with psoriatic plaque on nail folds.



▲ **Figure 20-5.** Beau's lines. Horizontal, depressed bands on toenails with separation of nail plate on great toenail in a patient following pneumonia.



▲ **Figure 20-6.** Nail pits in a patient with alopecia areata. Superficial pitting in a geometric pattern.

syndrome. Examination shows diffuse yellow-colored, thickened nail plates with excessive curvature of the nails, or a slow rate of nail growth. All nails are affected.² Nail disease will sometimes resolve with treatment of the underlying condition.²

► Alopecia Areata

Nail involvement in alopecia areata is present in up to 50% of children and 20% of adults.² Extensive nail involvement correlates with more severe hair loss, and a poorer prognosis.^{10–12} The nail changes can precede, occur concomitantly, or occur after hair loss.^{2,10} Rarely, nail changes can be the only finding in alopecia areata.⁵ Superficial, regular, geometric pitting is most common (Figure 20-6). This pitting is much more regular than pitting due to psoriasis.^{2,10} Geometric punctate leukonychia can be seen as regularly spaced, small, white spots on the nail plate.² Trachyonychia (sandpaper-like nails) can occur. Nonspecific findings may include Beau's lines, onychomadesis (shedding of the nail plate), onychorrhexis (brittle nails), thinning or thickening of the nail plate, spoon nails, and red lunulae.^{2,10} Biopsy of the matrix is usually not necessary, but if done will show spongiosis and a lymphocytic infiltrate of the proximal nail fold, nail matrix, nail bed, and/or hyponychium.⁵ Oral or intralesional corticosteroids may improve the nail disease.^{2,5} There is a report of successful treatment with topical tazarotene.¹³

► Trachyonychia

20-Nail dystrophy (trachyonychia) is most commonly caused by alopecia areata, and can affect 1 to 20 nails. It can also be caused by atopic dermatitis, ichthyosis vulgaris, lichen planus, or psoriasis, and can be an isolated finding in childhood.^{2,5,11} Nails have a roughened surface, with longitudinal ridging and thinning and are classically described as having a sandpaper appearance. There are no

nail findings that distinguish trachyonychia due to alopecia areata, lichen planus, or psoriasis.² However, abnormalities suggestive of lichen planus, psoriasis, or alopecia areata may be present on the skin and help with diagnosis. Longitudinal nail biopsy can help determine the underlying disorder; however, it is not usually recommended for this relatively benign condition.¹⁴ The condition usually resolves on its own in a few years when not associated with other skin diseases.⁵ Topical tazarotene has been reported to be useful.¹³

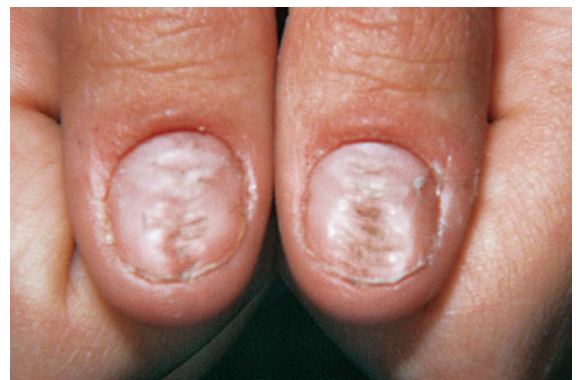Traumatic

► Habit Tic

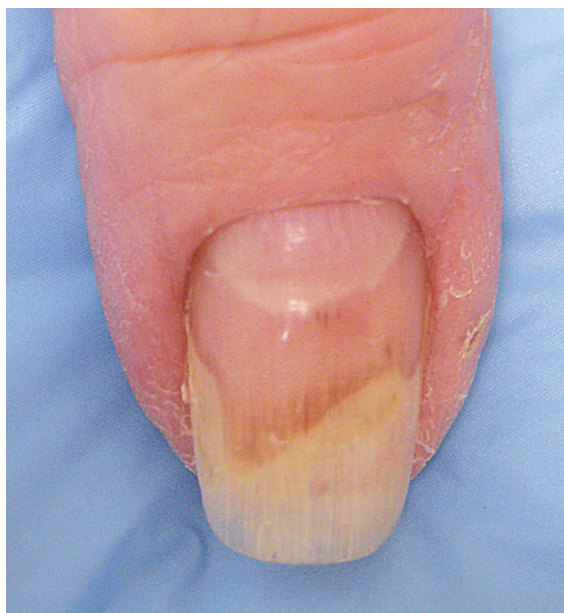Habit tic deformity occurs with manipulation of the proximal nail fold. Patients may or may not admit to picking, rubbing, or scratching the proximal nail fold or cuticle, but often will absent-mindedly pick at their cuticles during the office visit. The lesions are roughly parallel, horizontal depressions most often over the median nail plate (Figure 20-7). There may also be an absent cuticle, and a widening of the cuticular sulcus. Behavior modification is the most effective treatment. Manipulation of the nail fold should be minimized, by occluding with bandages if necessary.¹⁵ The condition may be successfully treated with selective serotonin reuptake inhibitors or other therapies used to treat obsessive-compulsive disorders.¹⁶ Cyanoacrylate adhesive (superglue) applied to the proximal nail fold 1 to 2 times weekly, to mimic the cuticle and seal the sulcus, has also been reported to be effective. This acts as a barrier to manipulation. Patients should be warned of the potential to develop allergic contact dermatitis to the adhesive.¹⁵

► Onycholysis

Simple onycholysis is not due to any underlying medical disorder. The separation usually starts distally, but can start



▲ **Figure 20-7.** Habit tic deformity. Parallel horizontal depressions over the medial nail plate caused by chronic rubbing of the cuticle.



▲ **Figure 20-8.** Onycholysis. Chronic irritant dermatitis on nail folds from dish detergent with onycholysis of nail plate.

proximally. The detached nail plate appears white due to air between the nail plate and nail bed (Figure 20-8). It is more common in women and adults. The longer the condition persists, the less likely it is to resolve. Patients may have a history of exposure to irritants (eg, nail cosmetics, soaps), or physical trauma.¹⁷ The most common causes of toenail trauma are ill-fitting shoes, sports-related trauma, long nails, and stubbing the toe.¹⁷ Common causes of fingernail trauma include hitting the nail plate with a tool or squeezing the nail plate in a door, and vigorous cleaning under the nail. Onycholysis can also be associated with taxane chemotherapy and other oral medications.⁸ Photo-onycholysis may be associated with the tetracyclines, particularly doxycycline and exposure to UV light.⁸

If a secondary infection with pseudomonas, mold, or yeast is present the nail can appear green or brown.¹⁷ *Candida* is cultured more than 80% of the time, but is likely just a colonizer, as treatment with systemic antifungals does not cure onycholysis.¹⁷ If reattachment does not occur, the nail bed will eventually cornify and produce dermatoglyphics like the rest of the digit. If this occurs, the nail plate will no longer attach to the nail bed.

Secondary onycholysis is caused by an underlying nail disorders such as psoriasis, lichen planus, and onychomycosis or systemic diseases such as hyperthyroidism and porphyria. Tumors of the nail bed can also cause onycholysis.

Management involves minimizing nail trauma. The patient should be instructed to keep the detached portion

of their nails trimmed back until the nail is reattached. They should not vigorously clean the area under the detached nail as this can cause further detachment. Patients should wear gloves for dry and wet work. They should not use any cosmetic nail products.¹⁷ Wearing shoes with low heels and a wide toe box is also recommended.

A topical antiseptic, such as thymol 4% solution, can be applied to the exposed nail bed to prevent infection.

INDICATIONS FOR CONSULTATION

Patients should be referred to dermatology if they are not responding to therapy, or if the diagnosis is uncertain, or a biopsy of the nail unit is needed.

Patient Information

- MedlinePlus: www.nlm.nih.gov/medlineplus/naildiseases.html
- American Academy of Dermatology: www.aad.org/media-resources/stats-and-facts/prevention-and-care/nails/nails

REFERENCES

1. Jiarvuthisan MM, Sasseville D, Vender RB, Murphy F, Muhi CY. Psoriasis of the nail: anatomy, pathology, clinical presentation and review of the literature on therapy. *J Am Acad Dermatol.* 2007;57:1–27. PMID: 17572277.
2. Scher RK, Daniel III CR. *Nails: Diagnosis therapy Surgery*, 3rd ed. China: Elsevier Saunders; 2005: 13–25, 85, 112–113, 115–117, 123–125, 130–131, 164, 171, 256.
3. Rallis E, Paparizos V, Flemetakis A, Katsambas A. Pseudomonas fingernail infection successfully treated with topical nadifloxacin in HIV-positive patients. *AIDS.* 2010;24(7):1087–1088. PMID: 20386383.
4. Reich K. Approach to managing patients with nail psoriasis. *J Eur Acad Dermatol Venereol.* 2009;23(suppl. 1):15–21. PMID: 19686381.
5. Holzberg M. Common nail disorders. *Dermatol Clin.* 2006;24:349–354. PMID: 16798432.
6. Ujiie H, Shibaki A, Akiyama M, Shimizu H. Successful treatment of nail lichen planus with topical tacrolimus. *Acta Derm Venereol.* 2010;90(2):218–219. PMID: 20169322.
7. Prevost NM, English III JC. Case reports: palliative treatment of fingernail lichen planus. *J Drugs Dermatol.* 2007;6(2):202–204. PMID: 17373179.
8. Piraccini BM, Iorizzo M, Starace M, Tosti A. Drug-induced nail diseases. *Dermatol Clin.* 2006;24(3):387–391. PMID: 16798438.
9. Al Hawsawi K, Pope E. Yellow nail syndrome. *Pediatric Dermatol.* 2010;27(6):675–676. PMID: 21510012.
10. Alkhalifah A, Alsantali A, Wang E, McElwee K, Shapiro J. Alopecia areata update: Part I. Clinical picture, histopathology, and pathogenesis. *J Am Acad Dermatol.* 2010;62(2):177–188. PMID: 20115945.
11. Vano-Galvan S, Aboin S, Bea-Ardebol S, Sanchez-Mateos J. Sudden hair loss associated with trachyonychia. *Cleve Clin J Med.* 2008;75(8):567–568. PMID: 18756837.

12. Kar B, Handa S, Dogra S, Kumar B. Placebo-controlled oral pulse prednisolone therapy in alopecia areata. *J Am Acad Dermatol.* 2005;2(52):287–290. PMID: 15692475.
13. Soda R, Diluvio L, Bianchi L, Chimenti S. Treatment of trachyonychia with tazarotene. *Clin Exper Dermatol.* 2005;30(3):301–302. PMID: 15807700.
14. Grover C, Khandpur S. Longitudinal nail biopsy: Utility in 20-nail dystrophy. *Dermatol Surg.* 2003;29(11):1125–1129. PMID: 14641339.
15. Ring DS. Inexpensive solution for habit-tic deformity. *Arch Dermatol.* 2010;146(11):1222–1223. PMID: 21079056.
16. Vittorio CC, Phillips KA. Treatment of habit tic disorders with fluoxetine. *Arch Dermatol.* 1997;133(10):1203–1204. PMID: 9382557.
17. Daniel III CR, Iorizzo M, Piraccini BM, Tosti A. Simple onycholysis. *Cutis.* 2011;87:226–228. PMID: 21699122.

Pigment Disorders

April T. Sanchez
Amit G. Pandya

21

Introduction to Chapter / 195
Vitiligo / 195
Melasma / 198

Postinflammatory Hyperpigmentation / 200
Postinflammatory Hypopigmentation / 201
References / 202

INTRODUCTION TO CHAPTER

Although disorders of pigmentation are not life-threatening, their impact can be profound. Lack of pigment or excessive pigment is quickly noticed by others and can create psychological stress for affected individuals. This is even more important during the sensitive years of adolescence, when many of these disorders begin. Depression, anxiety, embarrassment, seclusion, low self-esteem, fear of rejection, and perception of discrimination may occur in these patients. Additionally, the stigma associated with pigmentary disorders in certain cultures can cause an even greater psychological impact. Clinicians should be aware of these issues as well as the diagnosis and treatment of pigmentary disorders when treating affected patients.

VITILIGO

Introduction

Vitiligo, one of the most common pigmentary disorders, affects 0.5% to 1% of the world's population without discrimination based on gender, age, location, or race. Women and those with darker skin may be more likely to present to medical attention. Most affected individuals develop lesions before 20 years of age and experience a progressive increase in depigmentation over time. The disease is multifactorial but ultimately results in loss of melanocytes, causing disfigurement, sun sensitivity, and severe psychosocial

distress.¹ For these reasons, it should be thought of as more than a purely cosmetic disorder and recognized for its real effects on patient health.

Pathophysiology

Research into the pathogenesis of vitiligo is an active field, but has not yet resulted in a clear answer. Several mechanisms have been proposed, such as genetic abnormalities, autoimmunity, and dysregulation of redox (reduction–oxidation), biochemical, and neural pathways, all of which culminate in the common endpoint of melanocyte destruction.² Vitiligo is considered an autoimmune disease for several reasons.³ First, it is associated with other autoimmune disorders (particularly autoimmune hypothyroidism, pernicious anemia, Addison's disease, and systemic lupus erythematosus). Second, elevated levels of autoantibodies not only directed at melanocytes, but also at other end organs (thyroid, gastric mucosa, adrenal gland, etc.) are often found in affected individuals. Additionally, cytotoxic T cells infiltrate active lesions, clearly implicating the immune response in disease activity. Interestingly, vitiligo sometimes develops in patients who successfully mount an immune response to malignant melanoma, and has even been observed following bone marrow transplantation from an affected donor.⁴

Controversy exists as to whether autoantibodies and immune system activation are the precipitating event or a response to melanocyte death from other causes in patients

with vitiligo.⁵ For example, impaired handling of oxidative stress is observed in affected patients, leading to cell death. Affected skin may be more susceptible to cell loss through apoptosis and via melanocytorrhagy, which is the upward migration and loss of melanocytes through the stratum corneum due to inadequate cell adhesion.

The distribution of segmental vitiligo is in a quasi-dermatomal pattern, leading to the hypothesis that neural factors are important in the development of this form of vitiligo, a theory that is further supported by an association between vitiligo and certain neurological disorders. Genetically mediated disease susceptibility underlies each of the above mechanisms of melanocyte cell loss. Perhaps not coincidentally, the genes known to play a role in disease expression (PTPN22, NALP1, and certain HLA genes) are also functional components of the immune system, linking the genetic and autoimmune theories of pathogenesis. As with many disorders, it is likely that no single pathway is solely responsible but that multiple pathogenic mechanisms overlap to manifest disease in patients with vitiligo.⁶

Clinical Presentation

History

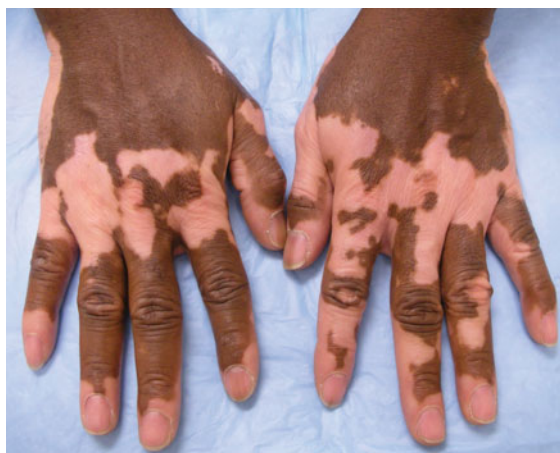Initial onset may be sudden, but the patient will usually report slow, progressive expansion of white spots on the skin without associated symptoms. A personal history of autoimmune disease or family history of vitiligo may be present. Sun exposure or trauma may draw attention to the lesions, causing the patient to seek medical attention. Subjectively, the patient may express emotional distress over the conspicuous and disfiguring lesions.

Physical Examination

Stark white, well-demarcated macules of varying sizes are noted in five possible patterns.

- Generalized-bilaterally symmetrical macules on face, trunk, and extremities (Figures 21-1 and 21-2).
- Segmental pattern: Affecting one site or one side of the body.
- Acrofacial: Affecting the lips, perioral areas, hands, and feet.
- Universal: Involving over 50% of the body surface area over a wide distribution.
- Mixed pattern: A combination of generalized, segmental, or acrofacial patterns.

The macules are nonscaling and accentuate with Wood's lamp examination. Lesions are often symmetric but may occur anywhere with a peculiar predilection for circumferential involvement of orifices, face and upper chest, and sites of pressure. Hair and mucous membranes

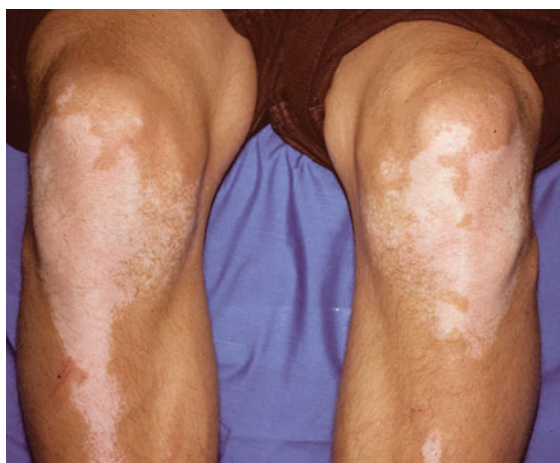

▲ **Figure 21-1.** Vitiligo on dorsum of hands.

may also be affected. Only rarely are borders erythematous or hyperpigmented.

Laboratory Findings

No abnormalities are seen in routine laboratory studies; however, patients may have evidence of thyroid abnormalities or other autoimmune diseases. Histologically, vitiligo is characterized by the absence of melanocytes in affected skin, although degenerating melanocytes may be seen in lesional borders. Conversely, normal melanocytes are seen in clinically nonaffected skin, but keratinocytes may appear abnormal, with extracellular granular material and vacuolated cytoplasm in the basal layer.



▲ **Figure 21-2.** Vitiligo on knees in a patient after ultraviolet light therapy, note small areas of repigmentation of skin with treatment.

Diagnosis

Diagnosis is clinical, based on the appearance and distribution of the lesions, chronic and progressive involvement, lack of associated symptoms, and exclusion of vitiligo mimics.

► Differential Diagnosis

- ✓ **Tinea versicolor:** May be differentiated by the presence of fine scale, positive potassium hydroxide (KOH) preparation, and distribution primarily on the trunk and neck.
- ✓ **Pityriasis alba:** A relatively common condition in children with atopy; also may have fine scale, but lesions retain some pigment and are less sharply demarcated.
- ✓ **Postinflammatory hypopigmentation:** A history of trauma or inflammation of the affected area will precede the loss of pigment.
- ✓ **Guttate hypomelanosis:** Presents with hypopigmented macules in a photodistribution on a background of actinic damage primarily on the arms and legs; unlike vitiligo, the macules are usually 5 mm in diameter or less.
- ✓ **Chemical leukoderma:** Certain chemicals, particularly aromatic derivatives of phenols and catechols, can destroy melanocytes, resulting in chemical leukoderma that may be differentiated from vitiligo by the history of toxin exposure, lesions with bizarre borders and scale, a “confetti-like” distribution, and symptomatic pruritus.
- ✓ **Ash leaf spots of tuberous sclerosis:** Accompanied by angiofibromas, periungual fibromas, connective tissue nevi, and possibly neurological sequelae.
- ✓ **Other:** Sarcoidosis, Hansen’s disease, and mycosis fungoides (cutaneous T-cell lymphoma) may present with white macules and should be considered in the appropriate clinical setting, requiring a skin biopsy to make the correct diagnosis.

Management

The rate of spontaneous repigmentation is as high as 20%,¹ but is usually incomplete. Treatment is almost always undertaken due to the often progressive course and significant psychosocial burden of disease.⁷ The most important aspect of treatment is establishing realistic expectations with the patient in terms of the aesthetic outcome anticipated and the need for prolonged treatment.

A multifaceted approach is used based on the varied mechanisms contributing to vitiligo. Immunosuppression

quiets the autoimmune contribution and stimulation of melanin production counteracts the progressive loss of melanocytes. Both of these ends are accomplished with psoralen plus ultraviolet (UV) A photochemotherapy and UV B phototherapy. Topical corticosteroids, calcineurin inhibitors (pimecrolimus cream, tacrolimus ointment), and vitamin D3 supplementation may improve vitiligo by affecting the immune system locally. Light therapy commonly causes itching, dry skin, and sometimes perilesional hyperpigmentation. There is also a low, albeit concerning, risk of iatrogenic skin cancer in patients with excessive UV doses. Topical or systemic steroids are sometimes used in combination with phototherapy. Caution must be exercised to avoid the many side effects of chronic steroid use. Oral antioxidants such as vitamins C and E may be useful adjuncts to minimize oxidative damage from free radicals present in lesional skin. The excimer laser is a new form of narrow band UVB treatment with the ability to treat localized areas without affecting normal skin. Finally, several surgical techniques for autologous transplantation (such as punch-grafting, split-thickness grafting, and epidermal blister grafts) have been employed with good to excellent success in patients resistant to other medical therapies. Donor site cells may even be cultured to allow treatment of more extensively affected regions. Again, a combination of medical and surgical therapy is often used to maximize repigmentation.

Aside from influencing disease activity, specialized makeup may be surprisingly effective in evening skin tone. Cosmetic tattooing is usually limited to specific areas, such as the lips. The opposite approach is sometimes taken for extensive disease involving more than 50% of the body surface area by depigmenting normal skin to attain the goal of homogenous skin coloration. In addition to vigilant sunscreen use, meticulous search for skin cancers is required, as the depigmented skin is prone to the deleterious effects of sun damage. Concomitant autoimmune disorders should be sought with thyroid studies, screening for antinuclear and other organ-specific antibodies, and hematologic evaluation.

Information on support groups should be offered to patients with vitiligo due to the potential for significant psychosocial effects and negative impact on quality of life associated with this condition.⁷ A patient’s perceived quality of life impacts treatment response, regardless of modality used, and must be addressed in order to achieve treatment success. In addition, vitiligo patients suffer an increased rate of psychiatric comorbidity, and when necessary, appropriate psychiatric referral should be given.

Indications for Consultation

When patients are not responding to topical therapy, they should be referred to a center experienced in phototherapy or even to a specialty center skilled at surgical therapy for vitiligo.

Patient Information

- The National Vitiligo Foundation offers educational materials, reports clinical trials and research updates, and support groups on the website: www.nvfi.org
- Vitiligo Support International provides disease information, discussion forums, and public advocacy accessible at: www.vitiligosupport.org
- The American Vitiligo Research Foundation strives to increase public awareness by focusing on affected children and supporting humane research initiatives: www.avrf.org

MELASMA

Introduction

Melasma is an acquired disorder which presents with symmetrical and hyperpigmented macules on the face and upper body. It affects over 5 million Americans, the vast majority of which are women (up to 90%) in their reproductive years with darker skin tones (most often Fitzpatrick skin types III–VI).⁸ Important risk factors include a positive family history, exposure to UV light or residence in regions of intense solar radiation, a history of pregnancy (thus the nickname “the mask of pregnancy”), and exposure to hormonal oral contraceptive pills (OCPs). Although a family history is less likely to be present in patients with melasma induced by OCPs, the cumulative effect of multiple risk factors appears to be important in disease pathogenesis.⁹ Estimates of disease prevalence vary widely from 8.8% to 40% depending on the patient population studied, but by all estimates, this is a common disease with significant impact on patients’ quality of life.¹⁰

Pathophysiology

The etiology of melasma is still unclear, but certain factors (eg, genetics, sunlight, and hormones) are known to be important in pathogenesis.¹¹ Familial grouping of affected individuals suggests that relevant genes have yet to be identified. UV radiation is known to stimulate melanocytes and increase cytokines such as alpha-Melanocyte Stimulating Hormone, which is over-expressed in skin affected by melasma. The onset of melasma following pregnancy or use of oral contraceptives implicates hormones as a precipitating factor, possibly through upregulation of the estrogen receptor and its varied downstream effects. Most likely, multiple mechanisms act synergistically to induce disease in genetically susceptible individuals.

Clinical Presentation

History

Lesions of melasma are usually asymptomatic. Historical information pertaining to relevant risk factors (family

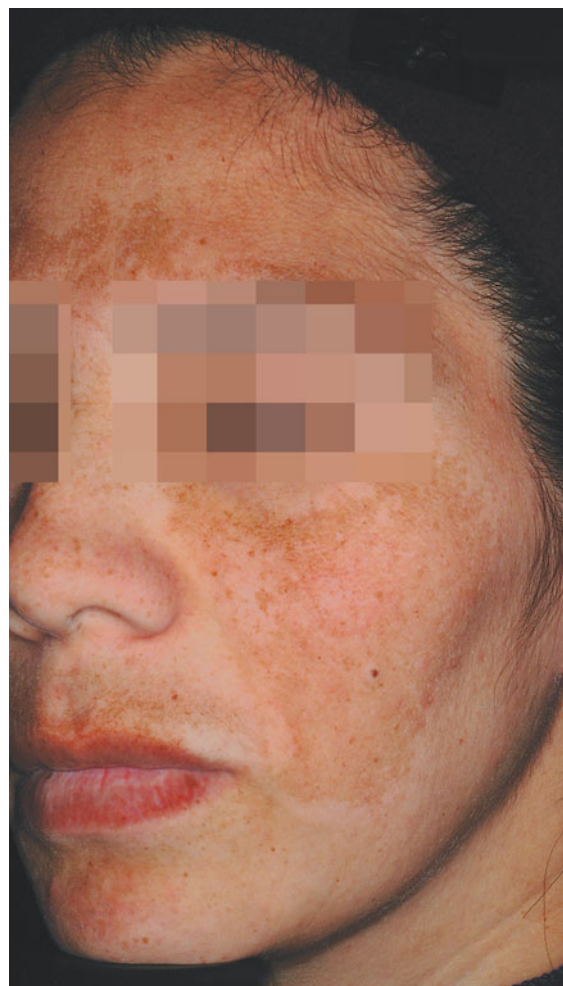history, UV exposure, pregnancy, and hormonal contraceptive use) should be elicited.

Physical Examination

The tan to muddy brown macules with geographic borders found in melasma are appreciated in three distinct patterns.

- Centrifacial: Across the forehead and down the midline of the face including the cheeks (Figure 21-3).
- Malar: Across the cheeks and bridge of the nose.
- Mandibular: Along the ramus of the mandible.

Centrifacial is most common, although a mixture of patterns is frequently seen. Lesions rarely present on the forearms. Wood’s examination enhances lesions suggesting increased epidermal melanin deposition, whereas lack of enhancement indicates melanin predominantly in



▲ **Figure 21-3.** Melasma in centrifacial pattern.

the dermis;¹² however, recent studies have found dermal pigment in most patients with Wood's lamp enhancing melasma, which may be one of the reasons why this disorder is so recalcitrant to treatment.¹¹

► Laboratory Findings

Circulating hormone levels are not routinely checked but may reveal higher levels of luteinizing hormone and lower levels of estradiol in nulliparous patients relative to unaffected counterparts. A biopsy is not required for diagnosis, but if performed, shows enlarged melanocytes with well-developed dendrites and increased melanin in the dermis and/or epidermis, reflecting increased melanocytic activity.¹³

Diagnosis

The key diagnostic features of melasma are tan to brown macules in the centrofacial areas of women.

► Differential Diagnosis

- ✓ **Postinflammatory hyperpigmentation:** Presents with an antecedent history of trauma or inflammation.
- ✓ **Freckles:** Present with smaller and more discrete lesions present before puberty.
- ✓ **Solar lentigines:** Usually more diffuse, not necessarily symmetrical, and associated with other evidence of actinic damage, as is actinic lichen planus.

- ✓ **Facial acanthosis nigricans:** Usually presents with other stigmata of diabetes mellitus and involvement of body folds.
- ✓ **Medications:** Such as minocycline, can cause facial pigmentation, but is usually present in sun-protected areas as well and one often elicits a history of drug ingestion with the onset of the pigmentation.
- ✓ **Rare conditions:** Acquired nevus of Ota.

Management

The goals of melasma treatment are to prevent new pigment production through both pharmacologic and physical means and to lighten affected skin by reducing melanosomes.¹⁴ Hydroquinone (Table 21-1), perhaps the oldest and most widely used treatment, accomplishes both of these goals by inhibiting tyrosinase, which catalyzes the first step in melanin production by converting tyrosine to dihydroxyphenylalanine (DOPA), and by decreasing melanocyte viability through inhibition of DNA and RNA synthesis. Skin irritation is the most common side effect observed, but nowadays this is usually due to the many additional components in currently available preparations. The most serious side effect of chronic use is ochronosis, which is a pepper-like deposition of hydroquinone in the skin, although this condition is rare in the United States. Theoretically, there is an increased risk of malignancy with hydroquinone due to toxic benzene metabolites, but no cases have been reported as yet. Topical retinoids have also been shown to reduce pigmentation in skin affected

Table 21-1. Topical medications for the treatment of melasma.

Medication	Examples of Brand Name(s)	Dosing	Notes
Hydroquinone: 2% formulations are over-the counter 4% formulations are prescription only	Aclaro, Alphaquin, Alustra, Claripel, Eldopaque, Eldoquin, EpiQuin Micro, Esoterica, Glyquin, Lustra, Melpaque, Melquin, Nuquin, Solaquin, Melanex, Melanol, Viquin	Twice daily to affected areas	Side effects: skin irritation (particularly when mixed with tretinoin and alpha hydroxy acids) and ochronosis (rare) Pregnancy category C Moderate efficacy
Triple combination cream (Fluocinolone acetonide 0.01%, hydroquinone 4%, tretinoin 0.05%): prescription only	Tri-Luma	Once daily at bedtime	Side effects: Skin irritation, mainly due to tretinoin Pregnancy category C Most efficacious
Kojic acid 1-4%: All products are over-the counter	Found in products made by REVIVA, Peter Thomas Roth, PCAC, Cosmetic Skin Solutions, La Roche-Posay, Cuccio Naturale, and Devita	Twice daily to affected areas	Side effects: Skin irritation and risk of allergy Moderate efficacy
Azelaic acid 15-20%: prescription only	Azelex, Finacea	Twice daily to affected areas	Side effects: skin irritation Pregnancy category B Moderate efficacy

by melasma, but the most efficacious treatments combine hydroquinone with a retinoid and a corticosteroid in a topical formulation. Improvement is often seen in 1 month but may take up to 6 months for maximum effect. There is no limit as to how long hydroquinone can be used. Published reports of large series of patients on daily hydroquinone have shown that it can safely be used for at least 1 year.¹⁵ Other topical tyrosinase inhibitors that may be utilized include azelaic acid (a useful second-line agent), kojic acid (an adjunct that increases efficacy but also irritation), and ascorbic acid (a less irritating although also less efficacious adjunctive treatment). Chemical peels may be of modest benefit as an adjunct in recalcitrant disease, but with the risk of exchanging melasma for postinflammatory hyperpigmentation. Preliminary studies with laser and light treatments are promising, but further studies are required to better define their risks, benefits, and role in the treatment of melasma.

Regardless of the agent(s) chosen, all patients should be instructed to avoid exacerbating factors, especially UV exposure by using sunblock with SPF ≥ 30 and titanium dioxide or zinc oxide as well as sun-avoidance and protective clothing. If possible, exogenous hormones should be discontinued, as should common allergens in makeup and facial creams (to prevent postinflammatory hyperpigmentation from contact dermatitis). The stubborn lesions of melasma often require an artful combination of treatments suited to each individual, and since patients often report a significant impact of melasma on their quality of life,¹⁰ counseling on realistic expectations of therapy should be given.

Indications for Consultation

There are no defined indications for consultation, but practitioners may consider referral to a specialist for patients nonresponsive to standard treatments and those seeking more specialized therapy with chemical peels or lasers.

Patient Information

American Academy of Dermatology: www.aad.org/skin-conditions/dermatology-a-to-z/melasma

POSTINFLAMMATORY HYPERPIGMENTATION

Introduction

Postinflammatory hyperpigmentation, a darkening of the skin following inflammation or trauma, is extremely common, affecting all ages and races as well as both genders. Those with Fitzpatrick skin types IV–VI are the most susceptible, making it the third most frequent chief complaint among African Americans presenting to a dermatologist.¹⁶ Clinically, it is considered to be

the prolonged sequela of a variety of other skin conditions ranging from acne to herpes zoster, trauma, and the direct toxic effect of certain drugs.¹⁷

Pathophysiology

The skin darkening observed macroscopically is due to an increase in melanin pigmentation following melanocyte stimulation. In response to trauma, inflammatory dermatoses, or certain medications, inflammatory mediators (such as histamine, prostaglandins, and leukotrienes) are released, causing exuberant pigment production. When the basement membrane is compromised, the excess pigment “leaks” into the papillary dermis (pigment incontinence). There, it is swallowed by macrophages and remains in so-called “melanophages” and isolated from the effects of treatment, which explains the long time course of persistent lesions and stubborn resistance to treatment.¹⁸

Clinical Presentation

History

Lesions can develop unpredictably after virtually any insult to the skin and persist for quite a long time. Darker skin type and exposure to the sun worsen the problem. There are no associated symptoms, aside from possible residual irritation caused by the inciting trauma. Exposure to hyperpigmenting medications such as tetracycline, bleomycin, 5-fluorouracil, and antimalarials may be discovered during the history.

Physical Examination

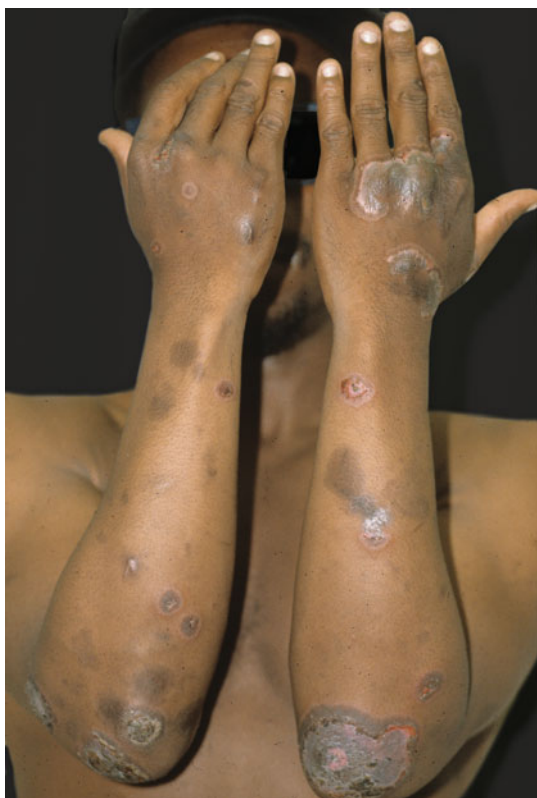Hyperpigmented macules with indistinct borders will be found at the site of prior inflammation (Figure 21-4). Brown to black lesions that are more sharply demarcated under Wood’s lamp indicate epidermal melanin deposition, whereas more gray-colored lesions highlighted by infrared photography localize pigment to the dermis.

Laboratory Findings

No laboratory findings are associated with postinflammatory hypermelanosis. Any abnormalities found are attributable to other, simultaneous diseases. Histology, if performed to determine the primary inflammatory lesions, will show melanocytic hyperplasia and increased melanin in the epidermis and/or dermis.

Diagnosis

The key diagnostic features of postinflammatory hyperpigmentation are hyperpigmented macules following trauma or inflammation.



▲ **Figure 21-4.** Postinflammatory hyperpigmentation in areas of resolving erythema multiforme.

► Differential Diagnosis

- ✓ **Toxic effect of drugs causing postinflammatory hyperpigmentation:** May be difficult to differentiate from contact sensitivity to medications. Knowing the common culprits and taking a detailed drug history along with patch testing may help determine whether toxicity or allergy is responsible.
- ✓ **Melasma:** May be indistinguishable from postinflammatory pigmentation, but the history usually does not include any preceding inflammation or symptoms.
- ✓ **Café au lait spots:** Present with sharply demarcated borders and are not preceded by trauma.
- ✓ **Acanthosis nigricans:** The primary lesion is a plaque (not a macule) with velvety texture usually in intertriginous areas.
- ✓ **Tinea versicolor:** May present with hyperpigmentation, but will become hypopigmented after sun exposure in the summer months and bear a fine scale that reveals hyphae and spores when examined with a KOH preparation.

- ✓ **Addison's disease:** Presents with hyperpigmentation that is more generalized, and the patient will report symptoms of hypocortisolism.
- ✓ **Hyperpigmented lesions of lichen planus:** Favor the flexural surfaces, sometimes with reticulated white plaques on the oral mucosa, and are extremely pruritic.

Management

The most important component of management is eliminating all inflammation from affected areas by using a treatment tailored to the underlying condition. Then, depigmenting agents may be used, similar to the management for melasma. Hydroquinone, tretinoin, azelaic acid, kojic acid, glycolic acid peels, and combination therapy (hydroquinone, tretinoin, and fluocinolone) have been successfully used (Table 21-1), but the patient should be made aware that the treatment course will likely be prolonged (>6 months) and may result in no benefit. Importantly, protecting the skin from sunlight with broad-spectrum sunscreens must be emphasized to prevent further increase in pigmentation.

Indications for Consultation

Patients are usually managed without further consultation; however, referral to a specialist may be considered if the cause of the underlying inflammation cannot be found.

Patient Information

SkinofColorSociety:www.skinofcolorsociety.org/documents/Post%20InflammatoryHyperpigmentation.pdf

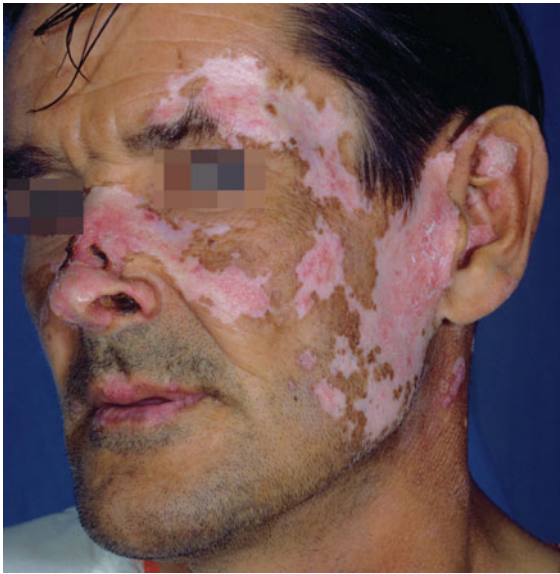POSTINFLAMMATORY HYPOPIGMENTATION

Introduction

As the name implies, postinflammatory hypopigmentation is the decrease in pigmentation due to loss of melanocytes following any cause of inflammation. It is also quite common among males and females of all ages, especially in lighter skin types (Fitzpatrick's types I–II).

Pathophysiology

Interestingly, both hypopigmentation and hyperpigmentation can be caused by the identical precipitating event: inflammation or injury. Further, areas of hyperpigmentation and hypopigmentation may coexist in the same area as it goes through the various stages of healing. The observation that patients with skin of color more readily hyperpigment after inflammation, whereas a hypopigmenting response tends to occur in light-skinned individuals lends



▲ **Figure 21-5.** Postinflammatory hypopigmentation in man with discoid lupus erythematosus.

support to a genetic basis for the disease.¹⁸ In certain patients, inflammatory mediators cause a loss of melanocytes, resulting in the clinical phenotype.

Clinical Presentation

History

The patient will usually remember the culpable insult and give a history of previous skin lesions, exposure to chemicals, application of irritating treatments, or trauma to the area. Pruritus and skin irritation are rarely present.

Physical Examination

Hypopigmented to depigmented macules are found at the site of inflammation or injury (Figure 21-5). Atrophy and scarring may indicate prior trauma, but epidermal changes may be absent. As in postinflammatory hyperpigmentation, lesions will become more discrete under Wood's lamp.

Laboratory Findings

If routine laboratory studies are performed, values should be within normal limits. Microscopic studies are nonspecific, revealing a decrease in melanin deposition with or without a decrease in melanocytes in affected skin. The greater value of biopsy is in determining the primary process responsible for the inflammation if the etiology is unclear.

Diagnosis

The key diagnostic features of postinflammatory hypopigmentation are hypopigmented to depigmented macules at the site of prior injury or inflammation.

Differential Diagnosis

- ✓ **Vitiligo:** Presents with complete loss of pigment within well-circumscribed borders and a progressive disease course.
- ✓ **Tinea versicolor, pityriasis alba, and guttate hypomelanosis:** See page 197.
- ✓ **Congenital conditions:** Such as nevus depigmentosus, nevus anemicus, and hypomelanosis of Ito may also be considered, but these are usually long-standing and fixed.

Management

Similar to postinflammatory hyperpigmentation, any ongoing source of inflammation should be eradicated before the pigmentary problem is addressed. Repigmentation is accomplished with melanocyte stimulation by simple sun exposure or UV radiation with or without psoralen. Again, therapy is prolonged and may result in a less than perfect outcome.

Indications for Consultation

Consultation is usually not required.

Patient Information

Patient.co.uk: www.patient.co.uk/doctor/Post-inflammatory-Hypopigmentation-of-Skin.htm

REFERENCES

1. Yaghoobi R, Omidian M, Bagherani N. Vitiligo; a review of the published work. *J Dermatol.* 2011;38(5):419–431. PMID: 21667529.
2. Njoo MD, Westerhof W. Vitiligo: pathogenesis and treatment. *Am J Clin Dermatol.* 2001;2(3):167–181. PMID: 1705094.
3. Ongenaes K, Van Geel N, Naeyaert JM. Evidence for an autoimmune pathogenesis of vitiligo. *Pigment Cell Res.* 2003;16(2):90–100. PMID: 12622785.
4. Alajlan A, Alfadley A, Pedersen KT. Transfer of vitiligo after allogeneic bone marrow transplantation. *J Am Acad Dermatol.* 2002;46(4):606–610. PMID: 11907519.
5. Gauthier Y, Cario Andre M, Taieb A. A critical appraisal of vitiligo etiologic theories. Is melanocyte loss a melanocytorrhagy? *Pigment Cell Res.* 2003;16(4):322–332. PMID: 12859615.
6. Schallreuter KU, Bahadoran P, Giachino C, et al. Vitiligo pathogenesis: autoimmune disease, genetic defect, excessive reactive oxygen species, calcium imbalance, or what else? *Exp Dermatol.* 2008;17(2):139–160. PMID: 18205713.

7. Ongenae K, Beelaert L, Van Geel N, Naeyaert JM. Psychosocial effects of vitiligo. *J Eur Acad Dermatol Venereol*. 2006;20(1): 1–8. PMID: 16405601.
8. Grimes PE. Melasma: etiologic and therapeutic considerations. *Arch Dermatol*. 1995;131(12):1453–1457. PMID: 7492140.
9. Ortonne JP, Arellano I, Berneburg M, et al. A global survey of the role of ultraviolet radiation and hormonal influences in the development of melasma. *J Eur Acad Dermatol Venereol*. 2009;23(11):1254–1262. PMID: 19486232.
10. Balkrishnan R, McMichael AJ, Camacho FT, et al. Development and validation of a health-related quality of life instrument for women with melasma. *Br J Dermatol*. 2003;149(3): 572–577. PMID: 14510991.
11. Sheth VM, Pandya AG. Melasma: a comprehensive update: part I. *J Am Acad Dermatol*. 2011;65(4):689–697. PMID: 21920241.
12. Gilchrist BA, Fitzpatrick TB, Anderson RR, Parrish JA. Localization of melanin pigmentation in the skin with Wood's lamp. *Br J Dermatol*. 1977;96:245–248. PMID: 857837.
13. Grimes PE, Yamada N, Bhawan J. Light microscopic, immunohistochemical, and ultrastructural alterations in patients with melasma. *Am J Dermatopathol*. 2005;27(2):96–101. PMID: 15798432.
14. Sheth VM, Pandya AG. Melasma: a comprehensive update: part II. *J Am Acad Dermatol*. 2011;65(4):699–714. PMID: 21920242.
15. Torok HM. A comprehensive review of the long-term and short term treatment of melisma with a triple combination cream. *Am J Clin Dermatol*. 2006;7(4):223–230. PMID: 16901182.
16. Taylor SC. Epidemiology of skin diseases in ethnic populations. *Dermatol Clin*. 2003;21(4):601–607. PMID: 14717401.
17. Halder RM, Nootheti PK. Ethnic skin disorders overview. *J Am Acad Dermatol*. 2003;48(6 suppl):S143–S148. PMID: 12789168.
18. Ruiz-Maldonado R, de la Luz Orozco-Covarrubias M. Postinflammatory hypopigmentation and hyperpigmentation. *Semin Cutan Med Surg*. 1997;16(1):36–43. PMID: 9125764.

22

Immunobullous Diseases

Kimberly Bohjanen

Introduction to Chapter / 204
Bullous Pemphigoid / 204
Pemphigus Vulgaris / 206

Dermatitis Herpetiformis / 208
References / 209

INTRODUCTION TO CHAPTER

The immunobullous diseases are uncommon chronic skin disorders caused by autoantibodies directed against various cutaneous proteins. These disorders primarily occur in older adults and can cause significant discomfort in affected patients and can even be fatal in the case of pemphigus. Patients with immunobullous diseases often have significant quality of life issues in questions pertaining to physical, emotional, and mental health.¹ Skin biopsies for routine histology and immunofluorescence are needed to confirm the diagnosis.

BULLOUS PEMPHIGOID

Introduction

Bullous pemphigoid is an uncommon blistering eruption that primarily affects elderly patients. The mean age of onset ranges from 68 to 82 years of age.

The incidence is estimated to be between 4.5 and 14 new cases per million per year. It is more common in women.²

Pathophysiology

Bullous pemphigoid is an autoimmune disease associated with the production of autoantibodies targeting the basement membrane. The basement membrane is important for the adhesion of the epidermis to the dermis, and so when targeted, leads to a separation (blister) in this space. The antigens themselves are parts of the hemidesmosomes of

the basal cells. The targets are BP 180 and BP 230.³ BP 180 is a transmembrane protein in basal cells, which is the extracellular noncollagenous domain of type 17 collagen. BP 230 is a cytoplasmic plakin family protein of the hemidesmosome. There is evidence for the pathogenic roles of these autoantibodies in this disease, especially against BP 180.

Clinical Presentation

History

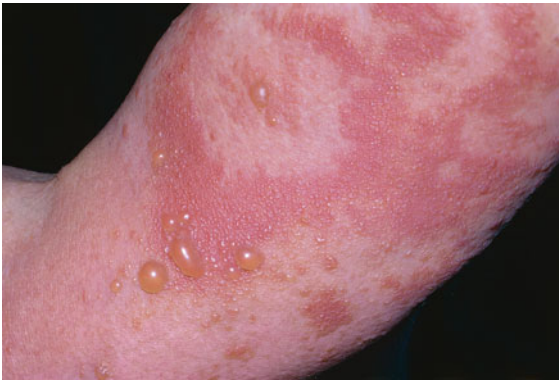Despite being labeled a blistering disorder, many patients will present initially with prebullous pemphigoid which presents as a pruritic urticarial rash without blisters.^{4,5} The pruritus can be severe. When blisters develop, they are tense blisters because they are forming between the dermis and epidermis and do not easily rupture.

Physical Examination

In the prebullous phase, the patient has pruritic urticarial plaques. In the bullous phase, the patient develops blisters. Most commonly the tense blisters are bilateral, symmetric, and on the trunk and proximal flexural extremities (Figure 22-1). The blisters may or may not have surrounding erythema. Mucosa can be involved, but usually in less than 20% of patients.

Laboratory Findings

- Histopathology of a skin biopsy from the edge of an intact bulla shows a subepidermal bulla with



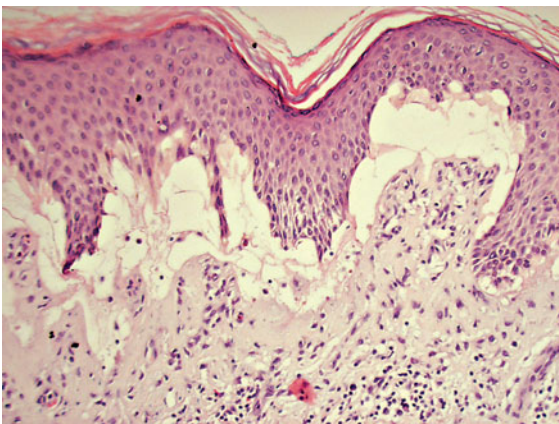
▲ **Figure 22-1.** Bullous pemphigoid. Vesicles and bullae with surrounding erythema on arm.

a dermal eosinophil inflammatory component (Figure 22-2).

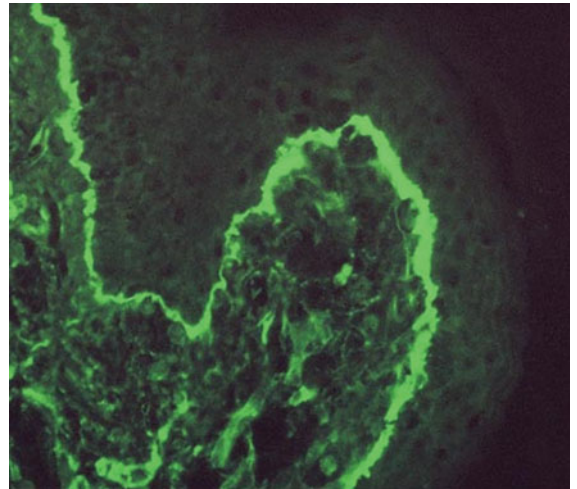
- Direct immunofluorescence of a skin biopsy taken of normal skin near a bulla shows a linear deposition of C3 and IgG along the basement membrane zone (Figure 22-3).
- Indirect immunofluorescence of the blood shows linear IgG along the blister roof on salt-split skin (Many patients do not have detectable circulating antibodies).
- An enzyme-linked immunosorbant assay (ELISA) for BP 180 and BP 230 is available.

Diagnosis

The key diagnostic features of pemphigoid are tense, pruritic vesicles and bullae.



▲ **Figure 22-2.** Histopathology of bullous pemphigoid. Subepidermal bulla with an inflammatory infiltrate.



▲ **Figure 22-3.** Direct immunofluorescence microscopy of perilesional skin in bullous pemphigoid, linear deposition of IgG along the basement membrane.

Differential Diagnosis

In the prebullous phase

- ✓ **Urticaria:** The individual lesions of urticaria should last less than 24 hours.
- ✓ **Drug rash:** Usually truncal with macular papular erythema.
- ✓ **Dermatitis:** This eruption is usually eczematous.
- ✓ **Other:** primary pruritus.

In the bullous phase

- ✓ Other bullous disorders (Table 22-1).
- ✓ **Other:** epidermolysis bullosa acquisita, dermatitis herpetiformis, bullous drug reaction, bullous tinea, bullous diabeticorum, coma/pressure bullae, edema.

Management

Skin biopsies for routine histopathology should be done from the edge of the blister and skin biopsies from perilesional skin should be sent for direct immunofluorescence. Blood could be sent for indirect immunofluorescence. Tense bullae can be drained with a sterile needle leaving the roof intact to act as a biologic dressing. White petrolatum can be used with nonstick dressings for any eroded areas. Bullous pemphigoid can be a chronic relapsing disease.

Table 22-1. Clinical and laboratory findings in bullous diseases.

Disease	History and Physical Examination	Routine Histology and Direct Immunofluorescence
Pemphigoid	Tense pruritic bullae that are bilateral and symmetric	Subepidermal blister with IgG and C3 at the basement membrane
Pemphigus	Flaccid bullae with positive Nikolsky sign	Blister within epidermis with intercellular IgG and C3
Dermatitis herpetiformis	Pruritic crusts on extensor surfaces	Subepidermal blister with IgA in dermal papillae
Stevens-Johnson/TEN	Very ill patients with significant crusting of lips, nose, and eyes. Nikolsky sign is positive	Subepidermal blister with epidermal necrosis. Immunofluorescence is negative
Epidermolysis bullosa	Tense blisters in areas prone to trauma	Subepidermal blister with IgA at the basement membrane

TEN, toxic epidermal necrolysis.

Indications for Consultation

Patients with bullous pemphigoid should be referred to dermatology. One-year mortality rates range from 6% in the United States to 41% in France.² Therapies include oral and topical corticosteroids, azathioprine, methotrexate, mycophenolate mofetil, and tetracycline with nicotinamide.

Patient Information

International Pemphigus and Pemphigoid Foundation: www.pemphigus.org.

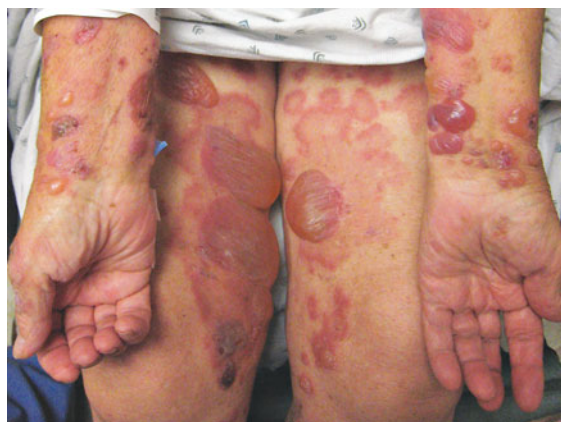PEMPHIGUS VULGARIS

Introduction

Pemphigus vulgaris is a rare blistering disease of the skin and mucous membranes, which primarily affects older patients with an median age of onset of 71 years of age.²

Pathophysiology

Pemphigus vulgaris is an autoimmune blistering disease with IgG autoantibodies directed against desmogleins 3 and 1.⁴⁻⁶ Desmogleins are the desmosomal protein



▲ **Figure 22-4.** Pemphigus. Flaccid bullae and vesicles and erosions on forearms and thighs.

members belonging to the cadherin family. These proteins help the keratinocytes in the epidermis attach to each other. When these proteins are targeted, intraepidermal blisters form usually just above the basal layer.

Clinical Presentation

History

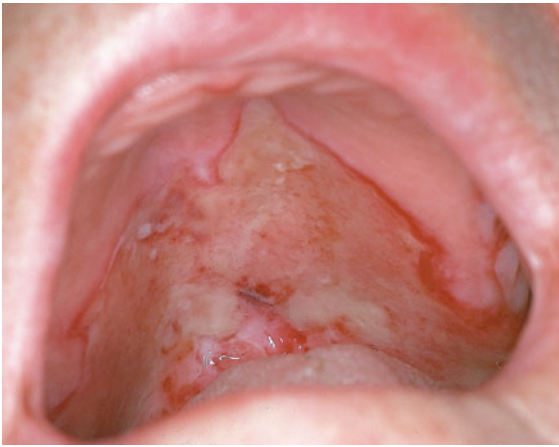Patients will have ongoing, painful, superficial blisters or erosions of the skin and/or mucosa. Some patients will only have mucosal involvement, usually the oral cavity.

Physical Examination

Because the blister is forming in the epidermis, it is flaccid and easily ruptured (Figure 22-4). Many patients will only have crusted erosions where the blisters used to be. The blisters and erosions are usually painful. The mucosal involvement is usually the oral cavity (Figure 22-5), but may involve the pharynx, larynx, esophagus, conjunctiva, and genitals. The skin rash typically involves the head, upper trunk, and intertriginous zones. When the patient has ongoing activity of the disease, a positive Nikolsky sign may be present at the edge of a blister (Figure 23-5). A Nikolsky sign is positive when the top layers of the skin slip away from the lower layers when rubbed, leaving a moist base.

Laboratory Findings

- A skin biopsy of the edge of a blister or erosion will show suprabasilar bulla with acantholysis and minimal inflammation (Figure 22-6).⁴⁻⁶
- A skin biopsy for direct immunofluorescence of normal skin next to a blister or erosion will show intercellular IgG and C3 (Figure 22-7).

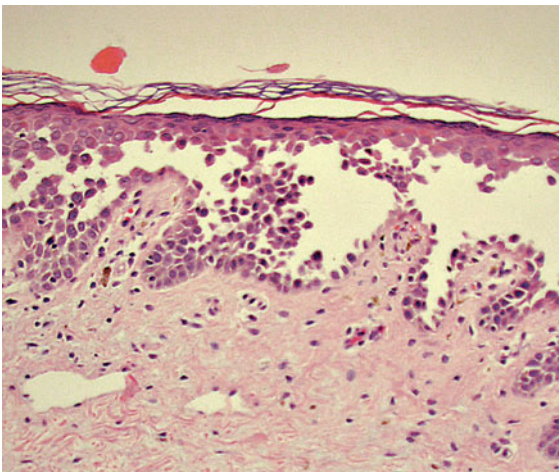


▲ **Figure 22-5.** Pemphigus. Collapsed flaccid bullae and erosions on palate.

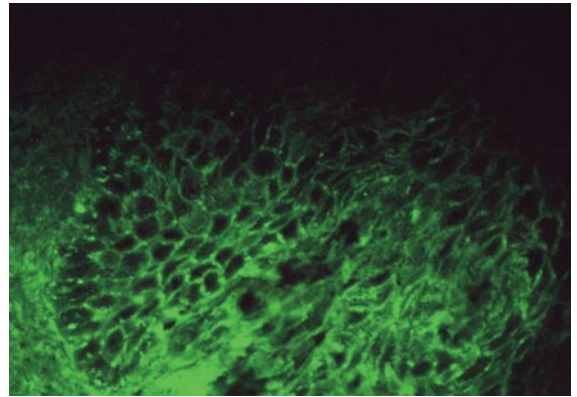
- Indirect immunofluorescence of the blood will show intercellular IgG deposition on stratified squamous epithelium. The titer level will usually parallel disease activity.
- ELISA for desmogleins 3 and 1 are available and may also parallel disease activity.

Diagnosis

The key diagnostic findings of pemphigus are flaccid bullae with a positive Nikolsky sign.



▲ **Figure 22-6.** Histopathology of pemphigus. Suprabasilar bulla with acantholysis (dissociation of keratinocytes) and minimal inflammation.



▲ **Figure 22-7.** Direct immunofluorescence microscopy of perilesional skin in bullous pemphigus. Intercellular IgG.

Differential Diagnosis

Because the blister is superficial, other eroding diseases must be considered.

- ✓ **Staph-scalded skin:** Patients have sheets of exfoliating skin related to a staph producing toxin.
- ✓ **TEN:** Clinically ill patients with significant crusting of the lips, nose, and eyes.
- ✓ **Other:** herpetic eruptions, impetigo, IgA pemphigus, and vasculitis.

Management

A skin biopsy for routine histopathology should be done from the edge of a blister and a skin biopsy for immunofluorescence should be done from skin near a lesion. Blood for indirect immunofluorescence or ELISA should be sent. Eroded areas should be covered with white petrolatum and nonstick dressings. Culture as appropriate for superinfection.

Indications for Consultation

If left untreated this disease is fatal and must be referred to dermatology immediately or hospitalized preferably in a burn unit if the patient has widespread disease. Systemic corticosteroids are the initial drug of choice. Other treatments include azathioprine, mycophenolate mofetil, methotrexate, cyclophosphamide, IVIG, plasmapheresis, and rituximab.

Patient Information

International Pemphigus and Pemphigoid Foundation: www.pemphigus.org

DERMATITIS HERPETIFORMIS**Introduction**

Dermatitis herpetiformis is an autoimmune blistering disease, which can involve a younger subset of patients when compared to pemphigus vulgaris and bullous pemphigoid. The typical age of onset is between 30 and 40 years of age, with men more affected than women. A genetic predilection is found in families and associated HLA-DQ2 and HLA-DQ8.

Pathophysiology

Dermatitis herpetiformis is linked to celiac disease and dietary gluten. Both celiac disease and dermatitis herpetiformis have gluten-sensitive enteropathy. IgA autoantibodies are found in both conditions. In dermatitis herpetiformis, epidermal transglutaminase is the main antigen.⁷ In celiac disease, the main antigen is tissue transglutaminase. In the skin, transglutaminase is found in the dermal capillaries and the basal cells of the epidermis. Transglutaminase is a cytoplasmic calcium-dependent enzyme that catalyzes crosslinks between glutamine and lysine. Transglutaminase modifies the gliadin portion of gluten and make it an autoantigen. Protein to protein crosslinking between transglutaminase and gliadin complexes causes an intense autoantibody response. Due to the inflammation in the skin, a blister is formed in the basement membrane zone between the epidermis and dermis.

Clinical Presentation**History**

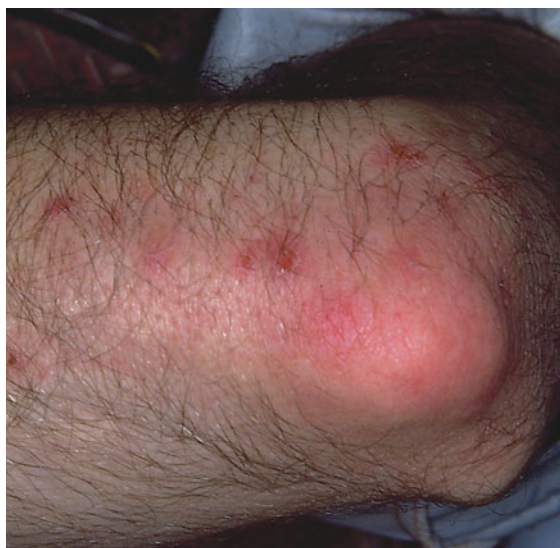The patient will usually present with excoriations and complaints of intense pruritus and may have gastrointestinal symptoms such as diarrhea and abdominal cramping.

Physical examination

Because the blister is forming between the dermis and the epidermis, it should be a tense blister. However, since this condition is so pruritic, most patients will have scratched the blister off leaving only erosions and excoriations (Figure 22-8). The eruption is classically symmetric with a distribution on the extensor surfaces of the extremities, elbows, knees, buttocks, scalp, and neck. Face and groin may also be involved, but rarely the mucosa.

Laboratory Findings

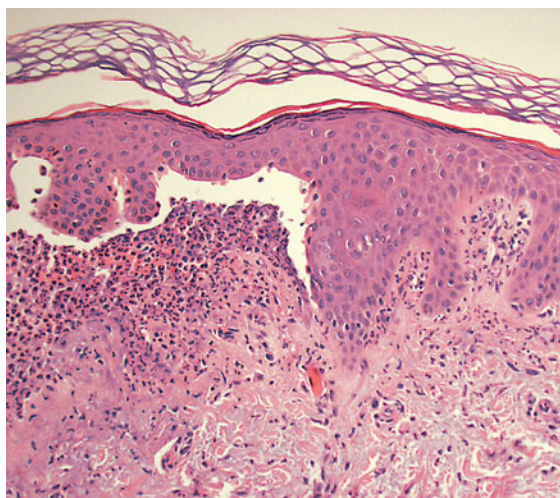
- Histopathology of a skin biopsy of an intact blister/vesicle (if it can be found) will show a subepidermal blister with neutrophils and some eosinophils in the tips of the dermal papillae (Figure 22-9).⁸



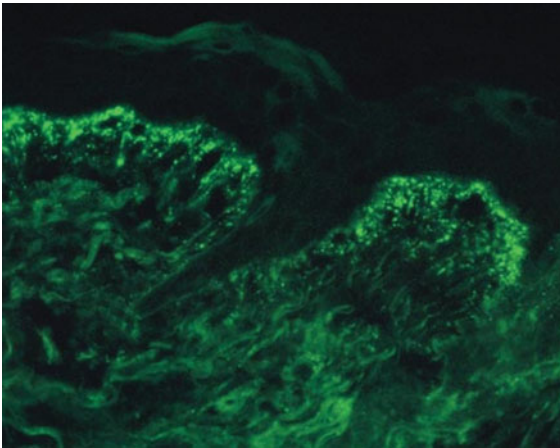
▲ **Figure 22-8.** Dermatitis herpetiformis. Excoriated erosions on elbow and forearm.

- A biopsy of perilesional skin for immunofluorescence will show granular deposits of IgA at the tips of the dermal papillae (Figure 22-10).
- Indirect immunofluorescence of the blood for antien-domysial antibodies is specific for dermatitis herpetiformis.

A total IgA level should be done before any other serological tests as selective IgA deficiency is more common in celiac



▲ **Figure 22-9.** Histopathology of dermatitis herpetiformis. Subepidermal blister with neutrophils and eosinophils in the tips of the dermal papillae.



▲ **Figure 22-10.** Direct immunofluorescence microscopy of perilesional skin in dermatitis herpetiformis. Granular deposits of IgA at the tips of the dermal papillae.

patients with celiac disease and needs to be considered in the evaluation of patients with dermatitis herpetiformis. ELISA for IgA antitissue transglutaminase is available. Studies are reviewing the ELISA for IgA antiepidermal transglutaminase and this may become a very useful tool.

Diagnosis

The key diagnostic features of dermatitis herpetiformis are erosions and excoriated papules on the extensor surfaces of the extremities, elbows, knees, buttocks, scalp, and neck.

► Differential Diagnosis

- ✓ **Scabies:** Pruritic papules on elbows, knees, body folds, volar wrists, and finger web spaces. Scabies mite are often seen in skin scrapings.
- ✓ **Bullous pemphigoid:** Tense bullae in a bilateral symmetric distribution.
- ✓ **Other:** Linear IgA bullous dermatosis, atopic dermatitis, and urticaria.

Management

A strict gluten free diet is a mainstay of therapy and consultation with a dietician is important as this diet is difficult to maintain. Even with a strict gluten free diet, the skin

lesions are slow to respond.⁹ Dapsone and sulfapyridine rapidly control the skin lesions.⁸ Systemic corticosteroids are not helpful in this disease. Antihistamines may help with pruritus.

Dermatitis herpetiformis is associated with other immune-mediated conditions and screening studies for thyroid disease, diabetes, and connective tissue disease should be considered.^{7,10} If clinical signs of gastrointestinal disease or non-Hodgkin lymphoma are present, a work-up must be done as these diseases are associated with dermatitis herpetiformis. Patients with gastrointestinal disease are at risk for splenic atrophy and a blood smear should be done to detect Howell-Jolly bodies and other abnormalities.

Indications for Consultation

Dermatitis herpetiformis is a complex blistering disorder that can be difficult to diagnosis. Patients should be referred to dermatology for diagnosis and management.

Patient Information

Celiac Disease Foundation: www.celiac.org

REFERENCES

1. Chee S, Murrell DF. Pemphigus and quality of life. *Dermatol Clin.* 2011;29(3):521–525, xi. PMID: 21605821.
2. Langan SM, Smeeth L, Hubbard R, Fleming KM, Smith CJ, West J. Bullous pemphigoid and pemphigus vulgaris—incidence and mortality in the UK: population based cohort study. *BMJ.* 2008;337:a180–a180. PMID: 18614511.
3. Schmidt E, della Torre R, Borradori L. Clinical features and practical diagnosis of bullous pemphigoid. *Dermatol Clin.* 2011;29(3):427–438. PMID: 21605808.
4. Schmidt E, Zillikens D. Modern diagnosis of autoimmune blistering skin diseases. *Autoimmun Rev.* 2010;10(2):84–89. PMID: 20713186.
5. Pohla Gubo G, Hintner H. Direct and indirect immunofluorescence for the diagnosis of bullous autoimmune diseases. *Dermatol Clin.* 2011;29(3):365–372, vii. PMID: 21605801.
6. Venugopal SS, Murrell DF. Diagnosis and clinical features of pemphigus vulgaris. *Dermatol Clin.* 2011;29(3):373–380. PMID: 21605802.
7. Bolotin D, Petronic-Rosic V. Dermatitis herpetiformis: part I. Epidemiology, pathogenesis, and clinical presentation. *J Am Acad Dermatol.* 2011;64(6):1017–1024. PMID: 21571167.
8. Bolotin D, Petronic-Rosic V. Dermatitis herpetiformis: Part II. Diagnosis, management, and prognosis. *J Am Acad Dermatol.* 2011;64(6):1027–1033. PMID: 21571168.
9. Nino M, Ciacchi C, Delfino M. A long-term gluten-free diet as an alternative treatment in severe forms of dermatitis herpetiformis. *J Dermatol. Treat.* 2007;18(1):10–12. PMID: 17365260.
10. Krpti S. Dermatitis herpetiformis. *Clinic Dermatol.* 2012; 30(1):56–59. PMID: 22137227.

23

Erythema Multiforme, Stevens–Johnson Syndrome, Toxic Epidermal Necrolysis, Staphylococcal Scalded Skin Syndrome

Cindy Firkins Smith

Introduction to Chapter / 210
Erythema Multiforme / 210
Stevens–Johnson Syndrome and Toxic Epidermal Necrolysis / 213

Staphylococcal Scalded Skin Syndrome / 216
References / 218

INTRODUCTION TO CHAPTER

Diagnosing and differentiating this group of mucocutaneous blistering diseases can be difficult. Despite the challenges, doing so is very important. The earlier the astute clinician can differentiate the patient with dramatic, but non-life-threatening cutaneous findings from the one who is at risk for progression to complete skin desquamation, the better the outcome for the patient. The goal of this chapter is to sort through the confusion and assist the clinician who is presented with such a patient.

ERYTHEMA MULTIFORME

Introduction

Experts once believed that erythema multiforme (EM), Stevens–Johnson syndrome (SJS), and toxic epidermal necrolysis (TEN) were all one disease on a spectrum of severity, with EM the mildest form and TEN the most severe. More recently, however efforts to link disease morphology with cause have led to reconsideration of that dogma. Experts now believe that EM and SJS/TEN are two separate diseases with different etiologies. EM is an acute, self-limited, but sometimes recurrent immune-mediated mucocutaneous disease.^{1,2} It presents most commonly as “targetoid” skin lesions in a young adult

who may or may not have oral mucosal or skin blisters and has a history of infection, usually herpes simplex, but is otherwise healthy.

Pathophysiology

There remains considerable debate about what causes EM; infections, medications, malignancies, autoimmune disease, immunizations, radiation, sarcoidosis, menstruation, and other causes have been implicated.¹ Most experts believe that up to 90% of cases of EM are caused by infections, with herpes simplex virus (HSV) the most commonly implicated agent.^{1–4} In addition to HSV, a wide range of bacterial, viral, fungal and parasitic infections have also been implicated (Table 23-1). Some believe that drugs are an uncommon cause of EM, while others believe that they are a common cause and are involved in up to half of cases.¹ While hundreds of drugs have been implicated, the most common culprit drugs identified are also those most commonly implicated in SJS/TEN: antibiotics (especially sulfa and penicillins), anticonvulsants, and nonsteroidal anti-inflammatory drugs. Experts who believe that EM is an infection-related disease would classify these drug-related cases as SJS/TEN, albeit a milder form. Regardless, it is important to recognize that when a patient presents with EM and a medication is the most likely cause, the patient should be approached with caution; this patient may actually have SJS/TEN.

Table 23-1. Infections implicated in erythema multiforme.

Viral	Adenovirus, cytomegalovirus (CMV), enterovirus, Epstein-Barr virus, hepatitis, Human immunodeficiency virus (HIV), HSV 1 & 2, influenza, molluscum, parvovirus, poliovirus
Bacterial	<i>Borrelia burgdorferi</i> , <i>Chlamydia</i> , <i>Corynebacterium</i> , <i>Diphtheria</i> , <i>Legionella</i> , <i>Lymphogranuloma venereum</i> , <i>Mycobacterium avium</i> , lepra and tuberculosis, <i>Mycoplasma pneumonia</i> , <i>Neisseria meningitidis</i> , <i>Pneumococcus</i> , <i>Proteus</i> , <i>Pseudomonas</i> , <i>Psittacosis</i> , <i>Rickettsia</i> , <i>Salmonella</i> , <i>Staphylococcus</i> , <i>Streptococcus</i> , <i>Treponema pallidum</i> , <i>Tularemia</i> , <i>Vibrio parahaemolyticus</i> , <i>Yersinia</i>
Fungal	Coccidiomycosis, histoplasmosis, sporotrichosis, dermatophytes
Parasitic	Malaria, trichomonas, toxoplasmosis

Since the majority of cases of EM occur in association with HSV, most information on pathogenesis comes from studies of people with HSV-associated disease. These data suggest that EM is a cell-mediated immune response to viral antigens in involved skin. Some individuals may be genetically susceptible, but specific predisposing genotypes have yet to be clearly defined.

Clinical Presentation

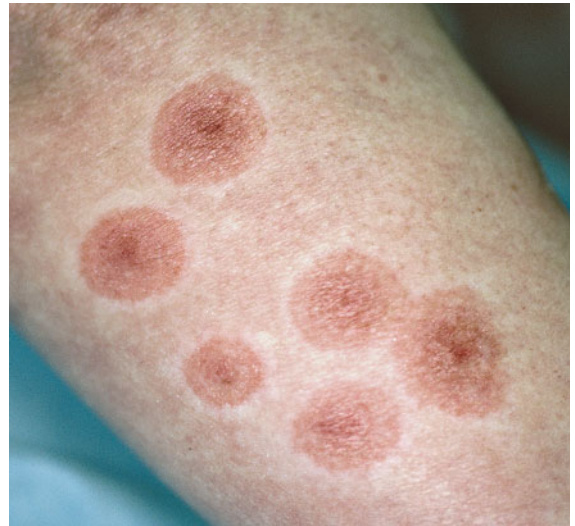History

Most patients report the abrupt onset of skin lesions. Patients were usually previously healthy and may or may not recall symptoms of an infection in the days to weeks prior to their outbreak.

Physical Examination

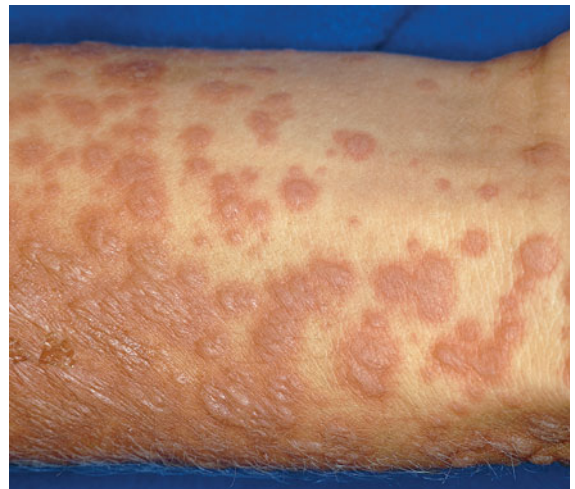
While target lesions are the classic cutaneous finding, the very name “erythema multiforme” implies a variable presentation. A “classic” target lesion is a round, well-defined pink to red patch/plaque with three concentric rings: an erythematous or purpuric center with or without bullae, a surrounding halo of lighter erythema and edema, and a third darker ring (Figure 23-1). In actual practice, target lesions are often atypical with two, rather than three zones, poorly defined borders, more extensive purpura, bullae, and appear more urticarial than targetoid (Figure 23-2). Classifying the target lesions may help establish the diagnosis, with “classic” targets more common in EM and “atypical” targets more common in SJS/TEN.

Oral mucous membrane involvement is common in EM, but is usually mild and limited to a few vesicles or erosions that may or may not be symptomatic (Figure 23-3).

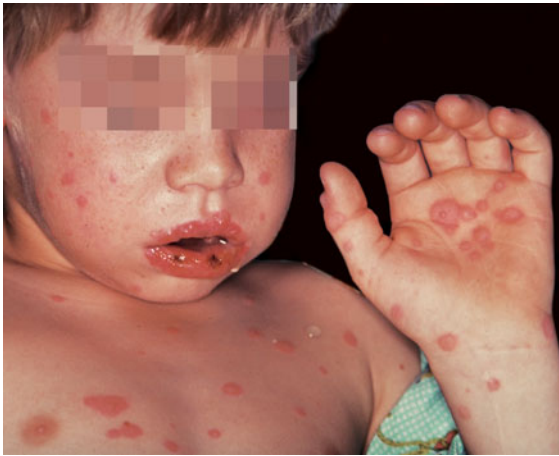

▲ **Figure 23-1.** Erythema multiforme. “Classic” target lesions.

When more extensive mucous membrane involvement is seen, such as widespread vesicles, ulcers, and erosions in multiple sites (eg, oral, ocular, genital, and perirectal), this is considered a more severe form of the disease. The term “erythema multiforme major” has been used to describe these severe cases of EM, but it is a confusing term, often used synonymously with Stevens–Johnson syndrome. The important thing to note is that patients with classic



▲ **Figure 23-2.** Stevens-Johnson/toxic epidermal necrolysis. Atypical target lesions coalescing to form flaccid bullae.



▲ **Figure 23-3.** Erythema multiforme. Classic target lesions on hands and mucosal ulcerations.

herpes simplex related EM **rarely** have widespread, severe mucous membrane involvement, and in these patients it is particularly rare to have ocular lesions.³

Systemic symptoms, if present, are usually mild (fever, cough, rhinorrhea, malaise, arthralgias, and myalgias). Although skin lesions may number from few to hundreds, generally less than 10% of the total body surface area (TBSA) is involved.⁴ Despite its dramatic appearance, the skin is often asymptomatic. While mild pruritus and tenderness have been reported, severe pruritus might incline the clinician toward a diagnosis of urticaria and severe skin tenderness toward a diagnosis of SJS/TEN.

► Laboratory Findings

Blood studies are nondiagnostic and generally will not help differentiate EM from urticaria, or SJS/TEN. A skin biopsy is helpful and even if not strictly diagnostic of EM will help differentiate from other diagnoses, particularly SJS/TEN, which exhibits much more widespread epidermal necrosis and less dermal inflammation.⁴ A skin biopsy specimen demonstrating severe epidermal necrosis or graft-versus-host-like findings should increase suspicion for more severe disease.⁵ Patients with recurrent disease without a clear etiology might benefit from HSV serologic testing.

Diagnosis

A typical EM patient will present with arcuate or targetoid pink patches on the extremities that may evolve into a more classic target shape and spread centrally. The patient may complain of recent upper respiratory symptoms or a HSV outbreak, but is usually otherwise healthy. Typically skin symptoms are mild (itching or tenderness) or absent and if mucous membrane involvement is present, it is limited.

Table 23-2. Erythema multiforme versus Stevens-Johnson syndrome (SJS)/toxic epidermal necrolysis (TEN).

Features	Erythema Multiforme	SJS/TEN
Target lesion morphology	“Classic” targets (identifiable 3 zone target lesions)	“Atypical” targets (macules, patches, 2 zones)
Distribution	Acral	Truncal, widespread
Erythema	Localized	Diffuse
% Skin detachment	<10%	>10%
Skin symptoms	None to mild pruritus and tenderness	Tenderness/pain
Mucous membrane involvement	Oral erosions may or may not be present Limited mucous membrane involvement in other locations (not ocular)	Mild to severe oral erosions always present Other mucous membranes may be involved
Recent HSV infection	May or may not be reported	Usually not reported
Nikolsky sign (lateral pressure causes skin shearing)	Negative	Often positive
Systemic symptoms	None to mild	Patient often febrile, systemically ill

► Differential Diagnosis

- ✓ EM and SJS/TEN can be difficult to differentiate, particularly early on (Table 23-2). Any patient that presents with atypical target lesions, more extensive membrane and skin involvement and systemic symptoms should be considered at risk for SJS/TEN, particularly if a drug etiology is suspected. Less common causes of targetoid lesions, such as fixed drug eruption, syphilis, subacute cutaneous lupus erythematosus, and occasionally urticaria, can usually be differentiated by skin biopsy.

Management

Self-limited disease may not require treatment. Patients with severe disease may require supportive therapy, particularly for pain and dehydration caused by oral mucous membrane involvement. Oral, intravenous, and intramuscular corticosteroids can be used to suppress symptoms. When

EM is recurrent it is important to identify and if possible, treat and prevent the cause. The most common cause of recurrent EM is HSV and these patients might benefit from HSV prophylaxis with acyclovir, valacyclovir, or famciclovir. Mycoplasma pneumonia infection, hepatitis C, vulvovaginal candidiasis, and other conditions have also been reported to precipitate recurrent EM and should be treated when possible.² Uncomplicated EM is self-limited and resolves without sequelae, usually within 2 weeks. Occasionally severe, recurrent EM requires long-term immunosuppression.²

Indications for Consultation

Dermatologic consultation should be considered in any patient with EM when the severity of symptoms or cutaneous findings suggests a potential diagnosis of SJS/TEN, or when EM is recurrent and the cause cannot be elucidated and recurrences prevented, or when chronic corticosteroid and/or immunosuppression is being considered. Ocular involvement warrants ophthalmologic evaluation.

STEVENS-JOHNSON SYNDROME AND TOXIC EPIDERMAL NECROLYSIS

Introduction

Stevens-Johnson syndrome (SJS) and toxic epidermal necrolysis (TEN) are rare, life-threatening mucocutaneous blistering diseases with an incidence of approximately 1 to 2 cases per 1 million.⁶ The frequency is higher in older patients and in those with HIV/AIDS.⁷

Pathophysiology

While SJS/TEN has been associated with multiple different etiologies (Table 23-3), the majority are thought to be due to an idiosyncratic drug reaction. While considered a form of delayed-type hypersensitivity, the precise pathophysiology of SJS/TEN is unclear.⁷ Although debate exists over the exact mechanism, the end result is epithelial cell death. Research suggests that certain individuals have a “genetic susceptibility” to certain adverse drug reactions, including SJS/TEN, perhaps caused by an inborn inability to detoxify drug metabolites. Multiple reports suggest that anti-infective sulfonamides, phenobarbital, carbamazepine, lamotrigine, and nonsteroidal anti-inflammatory drugs, particularly oxicam derivatives are strongly associated with SJS/TEN.⁶ Allopurinol is the most common cause in Europe and Israel.⁶ Acetaminophen use may be a risk factor in children.⁸ There is no test available to identify a causative agent and patients with SJS/TEN often have a history of taking multiple medications, which further complicates identifying the cause. Experts have attempted to address this issue by developing an algorithm of drug causality for epidermal necrolysis (ALDEN) that assigns a numerical value to multiple criteria including drug and reaction timing, a patient’s previous drug exposure, drug notoriety for causing SJS/TEN, and the presence of other potential causes.⁹

Table 23-3. Causes of Stevens-Johnson syndrome and toxic epidermal necrolysis.

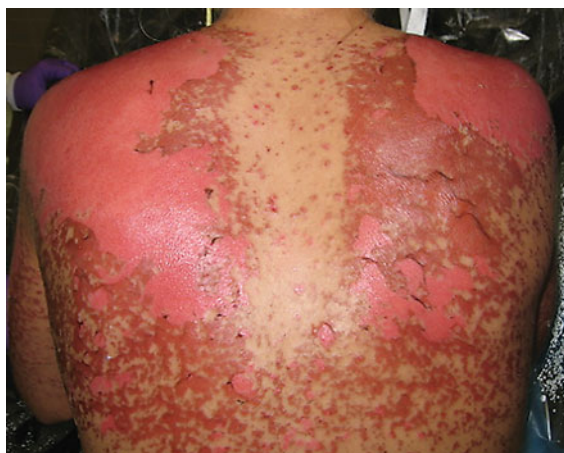Etiology	Frequency	Examples
Drugs	Cause majority of cases Symptoms <i>usually</i> begin less than 1 month and not more than 2 months after culprit drug initiation	Antibiotics (sulfonamides, penicillins, quinolones, cephalosporins), anticonvulsants (especially phenobarbital, carbamazepine, lamotrigine), allopurinol (most common cause in Europe and Israel). Nonsteroidal anti-inflammatory drugs (NSAIDs, especially oxicam derivatives), nevirapine, abacavir, chlorzoxazone, others. ¹ Acetaminophen in children ⁸
Infections	Less common and controversial as causative agents	Bacterial (most common: Mycoplasma pneumonia; less common: Yersinia, tuberculosis, syphilis, chlamydia, Streptococci, Salmonella, Enterobacter, Pneumococcus), Fungal (coccidiomycosis, histoplasmosis), Viral (enterovirus, adenovirus, measles, mumps, influenza, etc)
Immunizations	Rare	Smallpox, measles, diphtheria-pertussis-tetanus (DPT), Bacillus Calmette-Guérin (BCG), measles-mumps-rubella (MMR)
Other	Rare	Graft versus host disease, chemical or fumigant exposure, radiation therapy, inflammatory bowel disease

Clinical Presentation

The earlier a patient with SJS/TEN is diagnosed and managed appropriately, the better the outcome, but unfortunately early diagnosis can be challenging. In general, any patient taking a high-risk drug (Table 23-3) who presents with dusky red or purpuric papules or plaques, blisters or erosions, and mucosal involvement should be considered at risk for SJS/TEN.

History

Typically SJS/TEN begins with a 1 to 14 day influenza-like prodrome that may include fever, sore throat, chills, headache, and malaise. Signs of mucosal irritation (dysphagia,



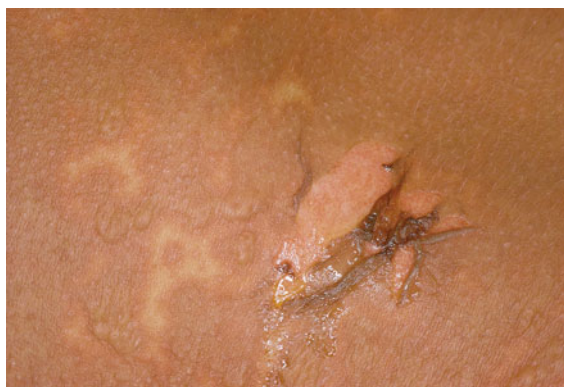▲ **Figure 23-4.** Toxic epidermal necrolysis. Dusky erythematous macules and patches with areas of denuded skin.

dysuria, and conjunctivitis) are often present for several days before the onset of cutaneous lesions.¹⁰

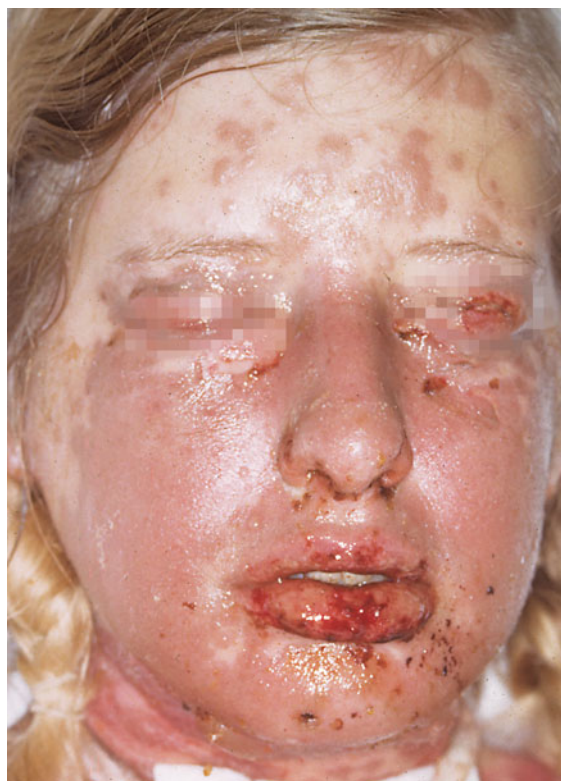Most episodes of SJS/TEN occur within the first month of initiation of the culprit drug and for most high-risk drugs SJS/TEN risk exists only during the initial 2 months of use.^{6,7,11}

► Physical Examination

The rash typically begins as macules or patches that develop blisters and then erode. Lesions can be irregular, targetoid, purpuric, and have necrotic centers. As individual lesions expand they coalesce into large, often painful, dusky, erythematous patches (Figure 23-4) that exhibit a positive Nikolsky sign (the skin peels away with laterally applied pressure, Figure 23-5). Mucous membrane involvement



▲ **Figure 23-5.** Positive Nikolsky sign. Epidermis peels away leaving with lateral pressure leaving a denuded base.

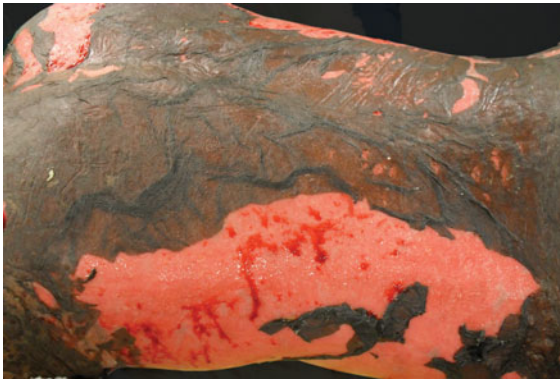

▲ **Figure 23-6.** Stevens-Johnson syndrome. Diffuse painful erythema on face with erosions on lips, nose, and eyes.

is considered a hallmark of disease with many patients exhibiting involvement in more than one area (oral, ocular, genitourinary, nasopharyngeal, rectal, and respiratory, Figure 23-6).¹² Mucous membrane involvement can be mild or severe and the severity of mucous membrane involvement does not correlate with the severity of skin disease. From a technical standpoint, making a diagnosis of SJS versus TEN is done by measuring TBSA involvement (Table 23-4). From a practical standpoint, the greater the TBSA involvement, the more severe the disease and the worse the prognosis (Figure 23-7).

Table 23-4. Diagnosis and total body surface area involvement (TBSA).

Total Body Surface Area Involvement (TBSA, %)	Diagnosis
<10	Stevens-Johnson syndrome
10-15	SJS-TEN overlap
>15	Toxic epidermal necrolysis



▲ **Figure 23-7.** Toxic epidermal necrolysis. Widespread areas of detached necrotic skin with denuded areas.

► Laboratory Findings

A skin biopsy is a very helpful tool to confirm the diagnosis and rule out most other mucocutaneous blistering diseases. Early on, histopathology demonstrates apoptotic keratinocytes in the epidermis. Later in the disease histopathology shows subepidermal blistering, sparse lymphocytic infiltrate, and full-thickness epidermal necrosis. Speed is important in establishing a diagnosis of SJS/TEN. When submitting a skin specimen for histopathological examination, it is important to do a punch or shave biopsy that includes dermis, submit it in formalin, state the suspected diagnosis, and request for rapid 2- to 4-hour processing. Other laboratory studies are nonspecific and do not help to establish the diagnosis, although they have been used to predict patient outcome through a severity of illness ranking score called SCORTEN.¹³ In general, the older the patient and the poorer the patient's underlying health at baseline, the higher the mortality.

Diagnosis

The key diagnostic features of SJS and TEN are sudden onset of erythematous, dusky, often painful patches usually initially on the central parts of the body. Within in few hours to days flaccid blisters appear and the skin begins to slough, leaving raw denuded areas. Mucous membrane ulcerations may be present in multiple sites. The Nicolsky sign is positive. A skin biopsy shows epidermal necrosis.

► Differential Diagnosis

- ✓ When a patient presents with mucocutaneous blisters and a history suspicious for SJS/TEN, the clinician should do a skin biopsy, preferably at the leading edge of an intact blister. Early SJS/TEN is most difficult to differentiate from EM, both clinically and histologically. Usually an EM patient will present less dramatically

Table 23-5. Staphylococcal scalded skin syndrome (SSSS) versus toxic epidermal necrolysis (TEN).

Features	Staphylococcal Scalded Skin Syndrome	Toxic Epidermal Necrolysis
Symptoms	Kids irritable but not too ill; adults often very ill	Patients often ill with fever, malaise, and myalgia
Skin tenderness	Skin exquisitely tender	Skin tenderness varies
Mucous membrane involvement	Periorificial involvement; mucous membranes spared	Severe mucous membrane involvement
Histopathology Clinical correlation	Blisters in the granular layer with acantholysis; superficial scaling/desquamation	Blisters with keratinocyte necrosis: often large areas of epidermal erosion
Etiology	<i>S. aureus</i> exfoliative exotoxin	Usually drug, occasionally infection
Management	Identify nidus of infection and treat, supportive care/referral depends on the severity of symptoms and underlying medical conditions	Identify culprit drug and eliminate, refer to Burn unit or Intensive Care Unit (ICU)

from a cutaneous and systemic standpoint, fail to progress to more extensive cutaneous disease, and lack the extensive mucous membrane involvement typical of SJS/TEN. Clinically SJS/TEN can be difficult to differentiate from staphylococcal scalded skin syndrome (Table 23-5), drug rash with eosinophilia and systemic symptoms (DRESS), and exfoliative erythroderma, particularly early in the course of disease, but a skin biopsy should allow for differentiation. Immunobullous diseases such as bullous pemphigoid, pemphigus vulgaris, paraneoplastic pemphigus, pemphigus foliaceus, or linear IgA dermatosis also fall within the differential diagnosis. Skin biopsies (one sent for routine hematoxylin and eosin stain and a second for direct immunofluorescence) will assist in differentiating them from SJS/TEN.

Management

The first and most important step in the management of the SJS/TEN patient is the immediate discontinuation of any unnecessary medications. The earlier the offending agent is withdrawn, the better the patient's prognosis.¹⁴ Some studies suggest that patients who are managed early and aggressively in a burn unit have a better outcome, and

transfer should be considered, especially in cases of extensive desquamation. Patients require a multidisciplinary approach to achieve hemodynamic stabilization, caloric replacement, infection prophylaxis, aggressive skin, eye, and mucous membrane care. The optimal approach to wound care has not been established. Sepsis is the major cause of death and infection surveillance and control are paramount. The use of adjuvant treatments such as intravenous immunoglobulin (IVIG) for SJS/TEN remains controversial with no agent demonstrating conclusive benefits.

Any ocular involvement warrants ophthalmologic evaluation and follow-up. The most common and severe long-term sequelae are ophthalmologic and include dry eyes, inverted eyelashes, chronic inflammation, fibrosis, and visual loss, including blindness.⁶ Other long-term sequelae common to survivors include irregular skin pigmentation, nail abnormalities and alopecia, sicca syndrome, and pulmonary complications.⁶ The mortality rate is almost 10% in patients with SJS, approximately 30% for patients with SJS/TEN and almost 50% for patients with TEN.⁶ Patients who survive SJS/TEN must be educated to avoid the culprit drug as well as those that are closely related or structurally similar.

Indications for Consultation

Any patient who presents with a severe mucocutaneous blistering disorder should be seen in consultation as quickly as possible. If a dermatologist is not available, the patient should be referred to a facility with a critical care or burn unit for further evaluation. Prompt recognition, elimination of the underlying cause, and aggressive supportive therapy allow the best hope for survival.

STAPHYLOCOCCAL SCALDED SKIN SYNDROME

Introduction

Staphylococcal scalded skin syndrome (SSSS) is a staphylococcal toxin-mediated disorder usually seen in children and infants and only rarely seen in adults; in both adults and children it occurs more commonly in males.¹⁵ A typical child with SSSS is less than 5 years of age and otherwise healthy. When adults develop SSSS there is usually an underlying serious medical illness or comorbidity, most commonly renal failure, but septicemia, immunodeficiency, diabetes mellitus, alcohol and drug addiction, and malignancy have also been reported.^{16,17}

Pathophysiology

Staphylococcal scalded skin syndrome is caused by exotoxins (ET) produced by certain strains of *Staphylococcus aureus* which cleave desmoglein 1, an important desmosomal protein. Damage to the desmosomes causes disruption of cell to cell adhesion in the epidermis and subsequent blistering.¹⁸ Disease extent seems to be related to the amount and type of toxin produced, the extent of

release, and the patient's ability to respond to it. Patients with SSSS experience blistering and shearing of large sheets of skin often over a large surface area.¹⁷ The higher incidence of SSSS in children may be a result of immunologic immaturity and the lack of anti-ET antibodies or immature kidneys and therefore less efficient exotoxin removal from the bloodstream.¹⁹

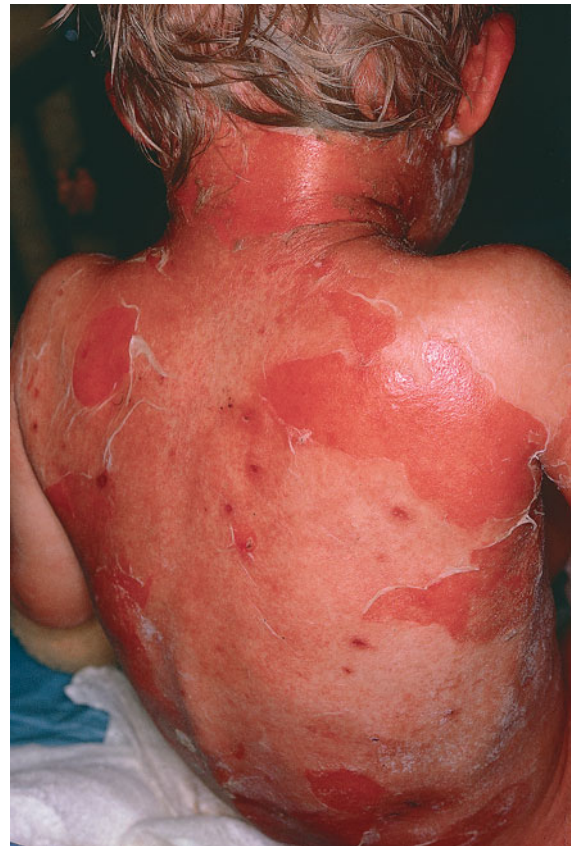Clinical Presentation

History

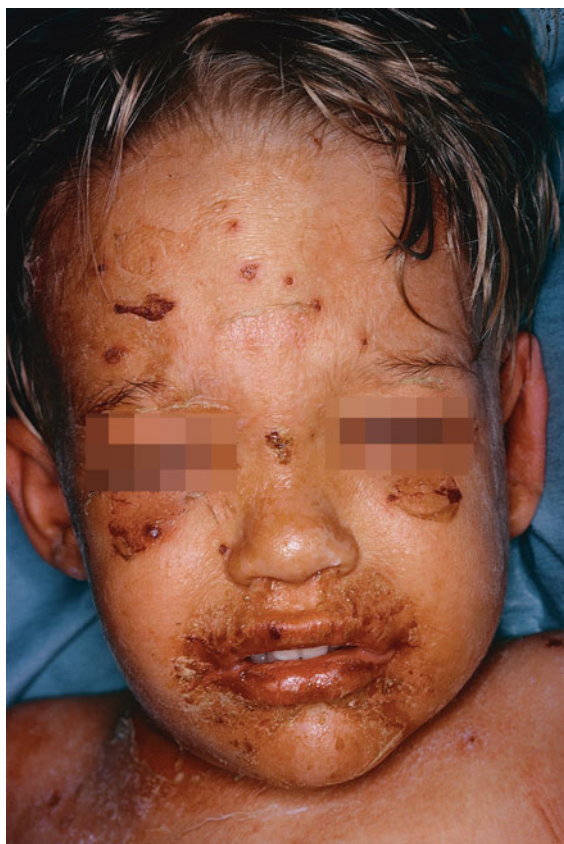SSSS presents with a vague "URI-like" prodrome of multiple symptoms including fever, sore throat, conjunctivitis, rhinitis, myalgias, arthralgias, irritability, and malaise, followed by skin blistering, desquamation, and erosion.

Physical Examination

Pink patches begin abruptly on the face, trunk, and extremities. As they spread they develop flaccid blisters, especially



▲ **Figure 23-8.** Staphylococcal scalded skin syndrome. Flaccid blisters that have sloughed leaving denuded areas of "scalded skin."



▲ **Figure 23-9.** Staphylococcal scalded skin syndrome. Erythema with superficial desquamation of skin with crusts and erosions around mouth and eyes.

in flexures. As the blisters enlarge they slough and give rise to large denuded areas, thus the “scalded skin” appearance (Figure 23-8). Often both involved skin and uninvolved skin exhibit a positive Nikolsky sign (the top layers of skin separate from those underneath when slightly pushed or rubbed). While there is usually significant facial involvement, especially around the eyes, nose, and mouth, mucous membranes are spared (Figure 23-9).

► Laboratory Findings

Blood tests may be nonspecific or may be consistent with underlying bacterial infection. Although SSSS is caused by a toxin-producing staphylococcus, the source of the bacteria is not always obvious. The blisters and erosions themselves are sterile unless secondarily infected and they are not the sources of the primary bacterial infection. Sites to examine and culture for pathogenic staphylococcus include conjunctiva, nasopharynx, flexures, periumbilical skin (especially in the neonate), perineal and perirectal skin. In adults evaluation **must** be continued until the infectious source is

identified. Blood cultures are usually negative in children and often positive in adults.

Skin biopsy of SSSS is usually diagnostic, revealing a superficial split along the granular layer of the epidermis, resulting from intraepidermal acantholysis. There is very little inflammation and no cell necrosis. The optimal specimen for histopathological examination is a punch or shave biopsy that includes dermis, submitted in formalin for rapid fixation and examination. However, obtaining a skin biopsy in an already uncomfortable child is not always an easy task. Since SSSS pathology occurs in the superficial epidermis, submitting a blister roof or freshly peeled skin in formalin for rapid fixation or in saline for frozen section (if available) can yield a diagnosis with little trauma to the patient.

Diagnosis

The key diagnostic findings of SSSS are sudden onset of blisters that rapidly slough leaving denuded (scalded) patches in a young child. A skin biopsy shows epidermal necrosis.

► Differential Diagnosis

- ✓ The most important disease to differentiate from SSSS is TEN, a severe blistering disease usually caused by a reaction to medication. It has higher morbidity and mortality than SSSS, particularly in children, and management is different (Table 23-5). Other diagnoses to consider are scarlet fever, Kawasaki disease, and toxic shock syndrome.

Management

Children with uncomplicated SSSS usually do well, are easily managed, and recover quickly, with resolution within 1 to 2 weeks. Ideally, antibiotic treatment should specifically target the culprit *staphylococcus*, but in the absence of an identified source or pending culture results, the patient should be treated empirically with antistaphylococcal β -lactamase-resistant antibiotics. Purulent areas or lesions should be drained. Whenever possible, blisters should be left intact to provide a biologic dressing. Supportive therapy including fluid replacement, pain control, and skin care to reduce secondary infection risk and bland emollients, petroleum jelly, or Aquaphor to decrease tenderness and pruritus should all be employed as indicated.¹⁷ Despite appropriate therapy, adults with SSSS often fare poorly and face a high risk of mortality.

Indications for Consultation

All adults with suspected SSSS and children with severe disease need referral to intensive care or burn units for multidisciplinary care in a critical care environment.

REFERENCES

1. Sanchis JM, Bagan JV, Gavalda C, Murillo J, Diaz JM. Erythema multiforme: diagnosis, clinical manifestations and treatment in a retrospective study of 22 patients. *J Oral Pathol Med.* 2010;39(10):747–752. PMID: 20738747.
2. Wetter D, Davis M. Recurrent erythema multiforme: clinical characteristics, etiologic associations, and treatment in a series of 48 patients at Mayo Clinic, 2000 to 2007. *J Am Acad Dermatol.* 2009;62(1):45–53. PMID: 19665257.
3. Howland WW, Golitz LE, Weston WL, Huff JC. Erythema multiforme: clinical, histopathologic, and immunologic study. *J Am Acad Dermatol.* 1984;10(3):438–446. PMID: 6725656.
4. Williams PM, Conklin RJ. Erythema multiforme: a review and contrast from Stevens–Johnson syndrome/toxic epidermal necrolysis. *Dent Clin Am.* 2005;49(1):67–76. PMID: 15567361.
5. Hosaka H, Ohtoshi S, Nakada T, Iijima M. Erythema multiforme, Stevens–Johnson syndrome and toxic epidermal necrolysis: frozen-section diagnosis. *J Dermatol.* 2010;37(5):407–412. PMID: 20536645.
6. Mockenhaupt M. The current understanding of Stevens–Johnson syndrome and toxic epidermal necrolysis. *Expert Rev Clin Immunol.* 2011;7(6):803–813. PMID: 22014021.
7. Borchers AT, Lee JL, Naguwa SM, Cheema GS, Gershwin ME. Stevens–Johnson syndrome and toxic epidermal necrolysis. *Autoimmun Rev.* 2008;7(8):598–605. PMID: 18603022.
8. Levi N, Bastuji-Garin S, Mockenhaupt M, et al. Medications as risk factors of Stevens–Johnson syndrome and toxic epidermal necrolysis in children: a pooled analysis. *Pediatrics.* 2009;123(2):e297–e304. PMID: 19153164.
9. Sassolas B, Haddad C, Mockenhaupt M, et al. ALDEN, an algorithm for assessment of drug causality in Stevens–Johnson syndrome and toxic epidermal necrolysis: comparison with case-control analysis. *Clin Pharm Ther.* 2010;88(1):60–68. PMID: 20375998.
10. Carr DR, Houshmand EH, Heffernan MP. Approach to the acute, generalized, blistering patient. *Semin Cutan Med Surg.* 2007;26(3):139–146. PMID: 18070680.
11. Mockenhaupt M, Viboud C, Dunant A, et al. Stevens–Johnson Syndrome and toxic epidermal necrolysis: assessment of medications risks with emphasis on recently marketed drugs. The EuroSCAR-study. *Soc Invest Dermatol.* 2008;128(1):35–44. PMID: 17805350.
12. Wetter DA, Camilleri MJ. Clinical, etiologic, and histopathologic features of Stevens–Johnson syndrome during an 8-year period at the Mayo Clinic. *Mayo Clin Proc.* 2010;85(2):131–138. PMID: 20118388.
13. Bastuji-Garin S, Fouchar N, Bertocchi M, Roujeau JC, Revuz J, Wolkenstein P. SCORTEN: a severity of illness score for toxic epidermal necrolysis. *J Invest Dermatol.* 2000;115(2):149–153. PMID: 10951229.
14. Garcia-Doval I, LeCleach L, Bocquet H, Otero XL, Roujeau JC. Toxic epidermal necrolysis and Stevens–Johnson syndrome: does early withdrawal of causative drugs decrease the risk of death? *Arch Dermatol.* 2000;136(3):323–327. PMID: 10724193.
15. Cribier B, Piedmont Y, Grosshans E. Staphylococcal scalded skin syndrome in adults: a clinical review illustrated with a new case. *J Am Acad Dermatol.* 1994;30(2 part 2):319–324. PMID: 10724193.
16. Dobson CM, King CM. Adult staphylococcal scalded skin syndrome: histological pitfalls and new diagnostic perspectives. *Br J Dermatol.* 2003;148(5):1068–1069. PMID: 12786851.
17. Patel G. Treatment of staphylococcal scalded skin syndrome. *Expert Rev Anti-infect Ther.* 2004;2(4):575–587. PMID: 15482221.
18. Aalfs AS, Otkarina DA, Diercks GF, Jonkman MF, Pas HH. Staphylococcal scalded skin syndrome: loss of desmoglein 1 in patient skin. *Eur J Dermatol.* 2010;20(4):451–456. PMID: 20558334.
19. Ladhani S. Understanding the mechanism of action of the exfoliative toxins of *Staphylococcus aureus*. *TEMS Immunol Med Microbiol.* 2003;39(2):181–189. PMID: 14625102.

Skin Signs of Systemic Disease

John Fenyk

24

Introduction to Chapter / 219
Connective Tissues Diseases / 219
Endocrine Disorders / 222

Pulmonary Diseases / 225
Neurological Diseases / 226
References / 228

INTRODUCTION TO CHAPTER

The skin, hair, and nails offer a window into the body. Many systemic conditions and diseases have major or distinct cutaneous manifestations. With practice, a complete skin examination can be rapidly conducted and provide information about underlying systemic disease.

CONNECTIVE TISSUES DISEASES

Discoid Lupus Erythematosus

► Introduction

Discoid lupus erythematosus (DLE) is twice as common in women and is more common in African Americans. Conversion to systemic lupus erythematosus (SLE) is uncommon (5%), but in some cases discoid lupus-like lesions are the initial cutaneous sign of SLE.¹ Approximately 25% of patients with SLE will have discoid lupus lesions at some point in their disease.

► Clinical Presentation

A. History and Physical Examination

The primary lesion is an angular, plaque with “follicular plugging,” central atrophy and peripheral hyperpigmentation, and erythema (Figures 24-1 and 24-2).¹ Pruritus or burning are common symptoms. The lesions are primarily located on sun-exposed areas, generally the face, arms, scalp,

upper chest, and back. Conchal fossa (bowl) scarring of the ear is almost pathognomonic (Figure 24-3). The scarring lesions of DLE may be disfiguring in patients with darker skin pigmentation, leaving permanent hypo- or hyperpigmentation. Scalp lesions may result in permanent hair loss due to scarring alopecia. Variants of DLE include hypertrophic, diffuse, and tumid, the latter two being less common.

B. Laboratory Findings

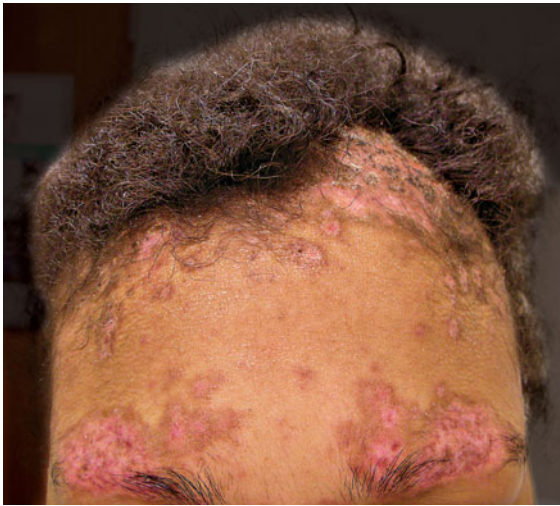Antinuclear antibody (ANA), if present, is most often low titer. A skin biopsy of a lesion for direct immunofluorescence shows a positive lupus band (IgG, IgM, and C3 in a band-like pattern along the dermal-epidermal junction) in most patients.¹

► Differential Diagnosis

✓ Seborrheic dermatitis, psoriasis, other photosensitive dermatoses, and tinea faciei.

► Management

Mild to moderate limited disease can be treated with topical steroids or calcineurin inhibitors. Oral antimalarials such as hydroxychloroquine can be added for more widespread disease or disease that is disfiguring.² Methotrexate, prednisone, and other systemic immunomodulators are other options for systemic therapy. Sunscreens, hats, and sun protective clothing should be regularly used.



▲ **Figure 24-1.** Discoid lupus erythematosus. Pink plaques with scarring alopecia in eyebrows and scalp with peripheral hyperpigmentation.

Subacute Cutaneous Lupus Erythematosus

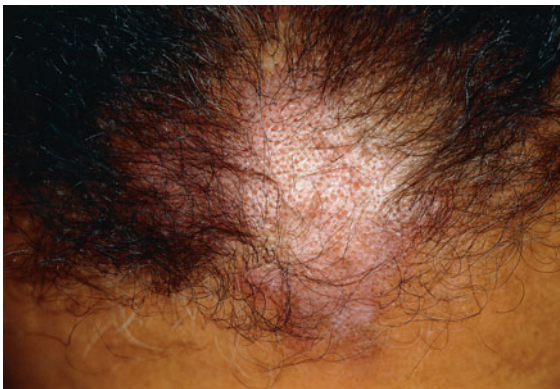► Introduction

Subacute cutaneous lupus erythematosus (SCLE) like all connective tissue diseases is somewhat more common in women than in men.

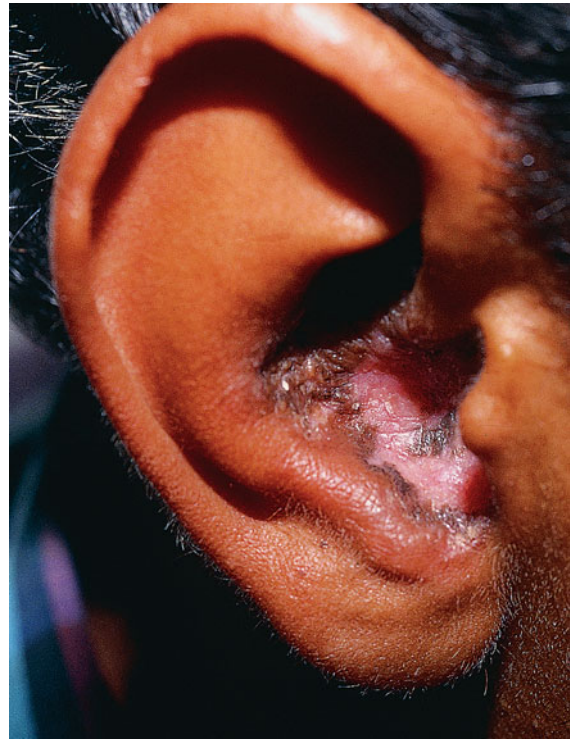► Clinical Presentation

A. History and Physical Examination

SCLE presents with a sudden onset of figurate, annular, arcuate, or psoriasiform lesions that are typically



▲ **Figure 24-2.** Discoid lupus erythematosus. Scarring alopecia with follicular plugging (keratotic plugs in dilated hair follicle ostia).



▲ **Figure 24-3.** Discoid lupus erythematosus. Pink plaque in conchal bowl of ear, a pathognomonic finding.

nonscarring and nonatrophic in a photodistribution (face, neck, extensor arms); however, the upper trunk is also commonly affected (Figure 24-4). Systemic symptoms are frequently absent or of minimal intensity. SCLE is often drug induced and can persist long after the causative drug has been withdrawn.¹

B. Laboratory Findings

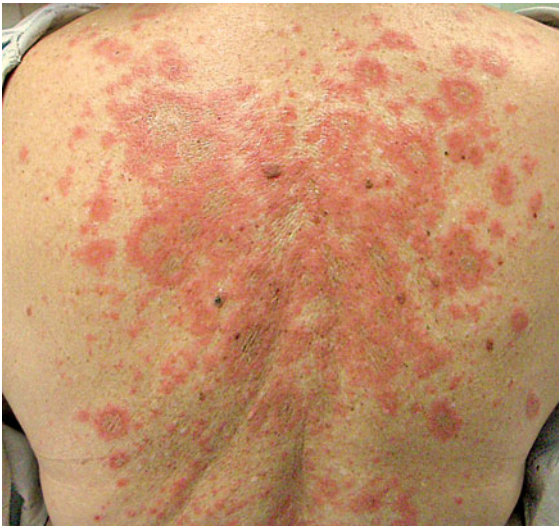ANA usually is positive (>60%).¹ Antibodies to Ro/SS-A are positive in more than 80% of patients. A skin biopsy for direct immunofluorescence will demonstrate a positive lupus band test in more than 60% of patients.

► Differential Diagnosis

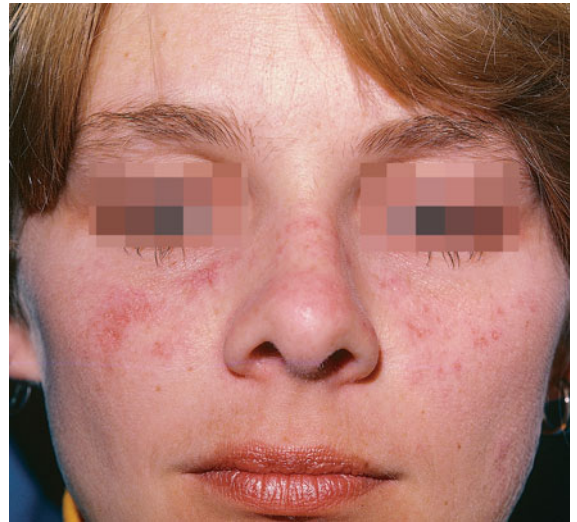✓ Tinea corporis, psoriasis, and dermatomyositis.

► Management

Any potentially inciting drug should be discontinued if possible. Many patients will require medications similar to those used in DLE.² Sun protection is also very important.



▲ **Figure 24-4.** Subacute cutaneous lupus. Annular, pink plaques with no scarring on back.



▲ **Figure 24-5.** Systemic lupus erythematosus. Pink, nonscarring macules over the malar area "butterfly rash."

Systemic Lupus Erythematosus

► Introduction

Systemic lupus erythematosus is the multisystem (systemic) extension of DLE and SCLE, not a part of a seamless continuum of those diseases. Women constitute 85% of those affected.

► Clinical Presentation

A. History and Physical Examination

Skin symptoms are minimal and usually consist of pruritus or increased sun sensitivity. Systemic symptoms are common and include arthralgias, myalgias, fatigue, malaise, fevers, chills, night sweats, weight loss, headaches, visual changes, and diffuse hair loss. Raynaud's symptoms are common. Cutaneous lesions though sometimes "discoid lupus" like, are generally diffuse, nonscarring and often nondescript. The "butterfly rash" (erythema with fine scale over the malar area) is one of the criteria for the diagnoses of SLE (Figure 24-5).¹

B. Laboratory Findings

A positive, high titer ANA is present in more than 95% of patients. The presence of anti-Sm and rRNP antibodies is characteristic of SLE. The white blood cell count is often low ($4000/\text{mm}^3$) with anemia frequent. Drug-induced disease may be detected by antihistone antibody testing. A positive lupus band is present in 90% of skin biopsies from involved skin.

► Differential Diagnosis

- ✓ Dermatomyositis, contact dermatitis, and other photosensitizing diseases.

► Management

Treatment is generally systemic. Hydroxychloroquine,² prednisone, methotrexate, biologic agents, plasmapheresis, and immunomodulators are frequently indicated. Sun protection is important.

► Indications for Consultation

Patients with skin lesions of discoid, subacute cutaneous, or systemic lupus are often co-managed by rheumatology and dermatology recognizing the distinct skills of each specialist.

Patient Information

- Lupus foundation of America, Inc.: www.Lupus.org
- National Institute of Arthritis and Musculoskeletal and Skin Diseases: www.niams.nih.gov/Health_Info/Lupus/

Dermatomyositis

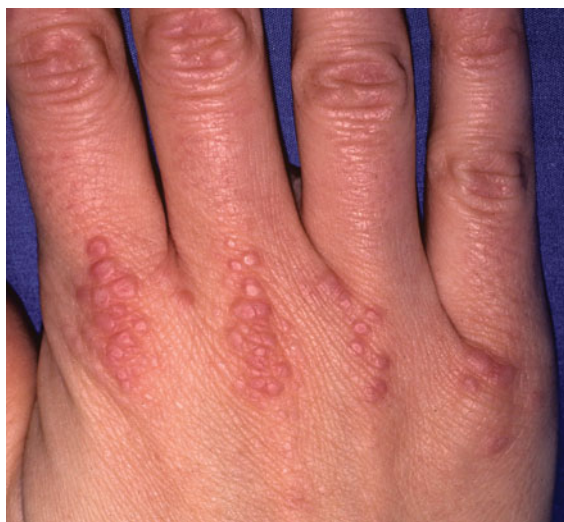► Introduction

Dermatomyositis is a rare chronic immune-mediated disorder that affects the skin and/or proximal skeletal muscles. The diagnosis of cutaneous dermatomyositis is often missed or delayed, because the pruritus and rash associated with it are very similar to other forms of dermatitis. Patients with dermatomyositis have an increased risk of malignancy.³

► Clinical Presentation

A. History and Physical Examination

Intensely pruritic, diffuse, scaly erythematous patches in the scalp with postauricular erythema are characteristic



▲ **Figure 24-6.** Dermatomyositis. Pink papules “Gottron’s papules” over the metacarpophalangeal joints.

findings.³ Similar patches are often found on the upper back shoulders, upper chest (shawl sign), and deltoid regions. Pathognomonic findings include periorbital erythema (heliotrope) and violaceous papules over the joints of the dorsal hands (Gottron’s papules) (Figure 24-6). Periungual erythema may be present. Patients may complain of photosensitivity and proximal muscle weakness (eg, difficulty in climbing stairs or raising arms above the head).

B. Laboratory Findings

Most patients have an elevated ANA and myositis-specific antibodies, including Jo-1 and Ro/SSA.³ Patients with muscle disease usually have an elevated creatine phosphokinase (CK) and aldolase.

► Diagnosis

Pruritic erythematous scaly patches on scalp and upper chest and shoulders with or without proximal muscle weakness. Pathognomonic findings of Gottron’s papules and heliotrope may be present.

► Differential Diagnosis

- ✓ Lupus erythematosus (especially subacute cutaneous), seborrheic dermatitis, and contact dermatitis.

► Management

Antihistaminics (H1 and H2) and doxepin can be used for symptomatic relief of pruritus. Topical steroids and topical

pimecrolimus and tacrolimus may partially control the skin disease. Most patients with moderate to severe disease require systemic steroids or other systemic immunomodulating agents.³ Management also includes an age and gender appropriate workup for malignancy (eg, ovarian, cervical, prostate, lung, colon, and breast) and evaluation for muscle involvement including electromyography (EMG) and muscle biopsy.

► Indications for Consultation

Most patients with dermatomyositis are best managed by a team including rheumatology and/or dermatology and their primary care provider.

Patient Information

PubMed Health: www.ncbi.nlm.nih.gov/pubmedhealth/PMH0001842/

ENDOCRINE DISORDERS

Diabetes Mellitus

► Introduction

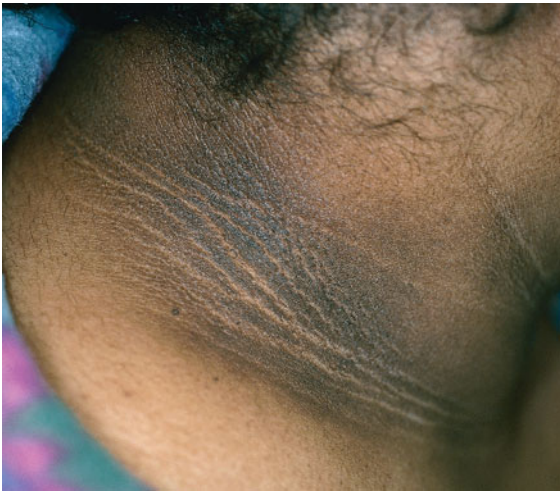Many of the cutaneous changes associated with diabetes directly reflect vascular and neuropathic changes that occur as diabetes progresses. Some changes reflect alterations in production of epidermal growth factors and other factors that affect tissue proliferation. Some of the clinical findings are the direct consequence of associated metabolic disturbances such as abnormal lipid metabolism. Unfortunately, with the possible exception of tight glycemic control with insulin, there is no evidence of other forms of therapy having an impact on skin changes.

► Clinical Presentation

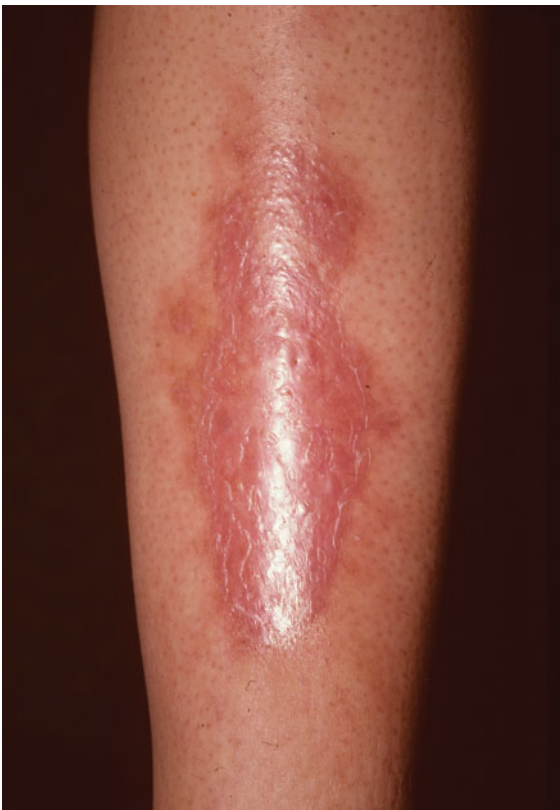A. History and Physical Examination

Patients with diabetes may have one or more of the following skin findings that are specific to diabetes.^{4,5}

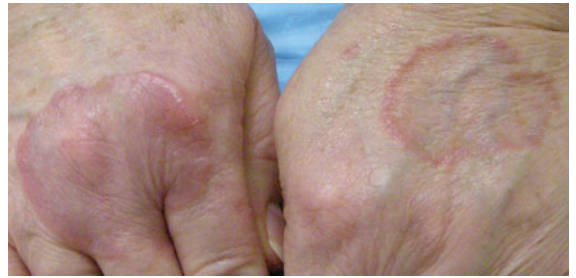
- Acanthosis nigricans: Velvety hyperpigmented, hyperkeratotic thickened skin in flexural areas typically the neck, axillae, and groin (Figure 24-7). Skin tags are often present.
- Diabetic dermopathy: Atrophic, slightly depressed macules on lower legs.
- Necrobiosis lipidica: Rust colored, well-demarcated, shiny plaque on shin which may ulcerate (Figure 24-8).
- Granuloma annulare: Smooth papules or more commonly annular plaques on dorsal hand and feet, elbows, and knees (Figure 24-9). The association with diabetes is still questionable.
- Neuropathic ulcer: Ulcer with callus formation on pressure point on plantar surface of the foot, mostly commonly on the metatarsal heads (Figure 29-5).



▲ **Figure 24-7.** Acanthosis nigricans. Hyperpigmented, velvet-like plaques on lateral neck of a patient with diabetes mellitus.



▲ **Figure 24-8.** Necrobiosis lipoidica. Rust colored, shiny plaque on the pretibial area of a patient with diabetes mellitus.



▲ **Figure 24-9.** Granuloma annulare. Annular, pink plaques with elevated borders on dorsal hands.

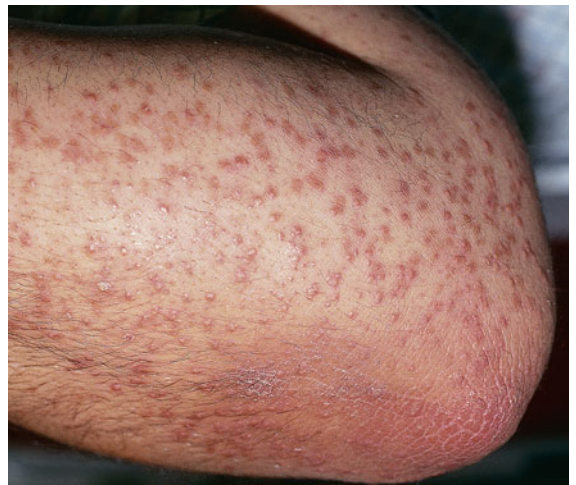- Xanthomas: Eruptive xanthomas (red to yellow dome-shaped papules over elbows and knees) (Figure 24-10) and xanthelasma (yellow orange papules or plaques on eyelids).

B. Laboratory Findings

Most of the skin diseases associated with diabetes are diagnosed on the basis of the history and clinic findings. Skin biopsies may be needed to confirm the diagnosis of granuloma annulare and necrobiosis lipoidica.

► Management

Unfortunately, treatment other than insulin has limited impact on the cutaneous aspects of diabetes. Granuloma annulare and necrobiosis lipoidica can be treated with topical or intralesional steroids. Management of neuropathic ulcers is covered in Chapter 29.



▲ **Figure 24-10.** Eruptive xanthomas. Multiple pink papules on arm of a patient with diabetes mellitus and hyperlipidemia.

Patient Information

American Diabetes Association: www.diabetes.org

Thyroid Disease

► Introduction

Thyroid dysfunction may arise as the result of a variety of distinct disorders. The most common of all is autoimmune thyroid disease, which is more common in women than in men (10:1).

► Clinical Presentation

A. History and Physical Examination

Diffuse enlargement of the thyroid with palpable nodules (goiter) may be noted in both hyper- and hypothyroidism. Hypothyroidism may present with loss of the lateral third of the eyebrow and with a diffuse or patchy alopecia.⁶ The hair may be dry, brittle, and coarse. The skin may be coarse, dry, and cool. Patients may complain of cold intolerance and inability to lose weight. Hyporeflexia and lid lag are often present.

Hyperthyroidism may present with fragile, soft, warm skin and soft, fine hair.⁶ Patients may complain of tremors, pruritus, heat intolerance, and increased sweating. Thick indurated plaques (pretibial myxedema) over the legs (Figure 24-11) and other areas are associated with Graves' disease and hyperthyroidism. Vitiligo and alopecia areata can be associated with autoimmune thyroid disease.

B. Laboratory Findings

Thyroid stimulating hormone (TSH) with reflex T3 and T4 should be the initial tests for screening purposes. If autoimmune thyroiditis is suspected, antimicrosomal and antithyroglobulin antibodies tests should also be done.

► Management

Appropriate management of the thyroid condition should be instituted.

► Differential Diagnosis

- ✓ Pituitary and hypothalamic dysfunction, carcinoid, pheochromocytoma, and infection.

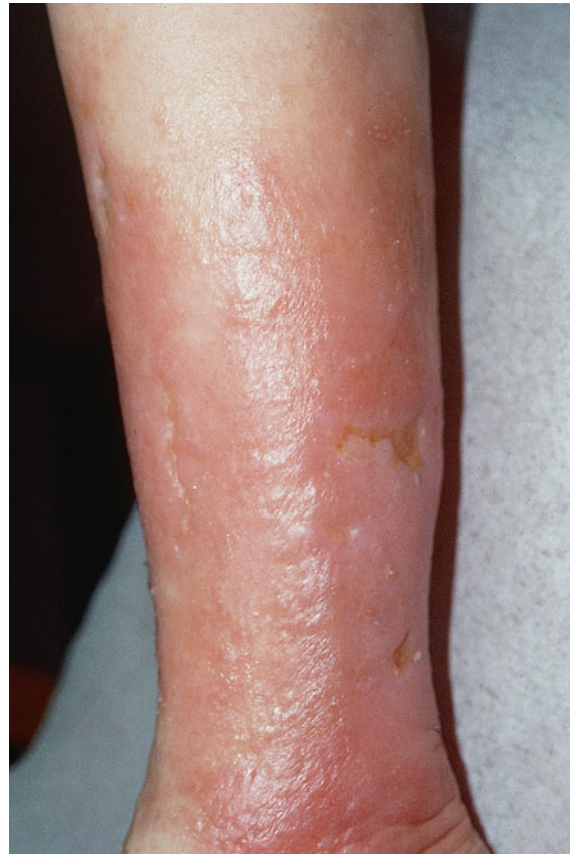Patient Information

American Thyroid Association: www.thyroid.org

Hepatic Disorders

► Introduction

The myriad of cutaneous findings associated with hepatic disease only occasionally point to a specific liver disease.



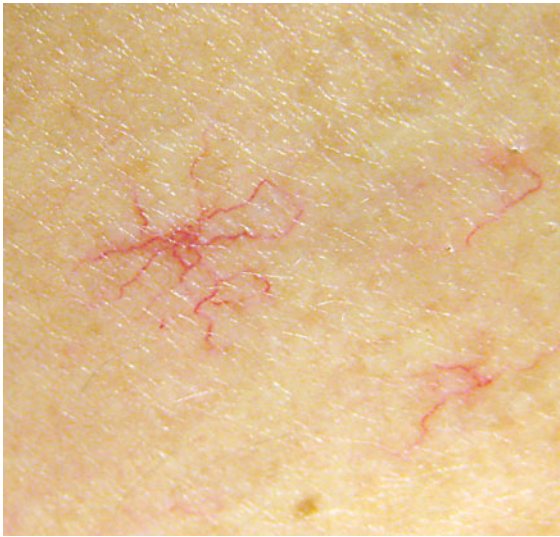▲ **Figure 24-11.** Pretibial myxedema. Pink, waxy, indurated plaque on lower leg of a patient with Graves' disease and hyperthyroidism.

Most findings give a picture of hepatic damage, but do not indicate whether the process is infectious, allergic, metabolic, inherited (ie, Wilson's), pregnancy-related, or from toxins.

► Clinical Presentation

A. History and Physical Examination

Patients with hepatic disease may complain of central truncal or palmar pruritus. Clinical findings associated with hepatic disease include rapid appearance of numerous angiomas and spider telangiectasias (Figure 24-12), easy bruising, ecchymoses, palmar erythema, male gynecomastia (or other signs of hyperestrogenemia and conjugation problems), jaundice, scleral icterus, sweet and/or ammonia odor to breath and skin, hypertrichosis, white nails, excoriations, prurigo, prurigo nodularis, porphyria cutanea tarda (Figure 24-13), lichen planus, cushingoid appearance, enlarged cutaneous abdominal vasculature, and abdominal distension.⁷



▲ **Figure 24-12.** Spider angioma. Telangiectasia in a patient with liver disease. These can also occur in the absence of liver diseases (eg, in children and pregnant women).

B. Laboratory Findings

Hepatic profile, metabolic profile, and, if indicated, hepatitis panel should be ordered. A complete blood cell count (CBC), differential, indices may be helpful, especially in some metabolic conditions and toxic exposures. Coagulation studies should be checked, especially in advanced disease. Drug and alcohol screens may be

indicated. A skin biopsy may be helpful in the case of clinically indistinct findings or to confirm the diagnosis of lichen planus or porphyria cutanea tarda.

► Management

Identification and treatment of the cause of the liver disorder is imperative. Diet modification, appropriate fluid management, and careful management of therapeutic drugs are critical, particularly in end-stage disease.

► Differential Diagnosis

- ✓ Nonhepatic metabolic conditions that may induce pruritus, alter protein metabolism, or mimic hyperestrogenic states.

Patient Information

American Liver Foundation: www.liverfoundation.org

PULMONARY DISEASES

Sarcoidosis

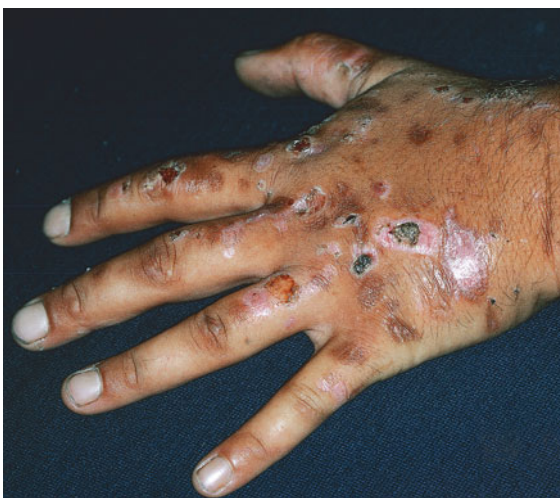► Introduction

Sarcoidosis is easiest to understand as two separate diseases, the first being a multisystem disease with about 30% of patients having cutaneous findings and the second being skin only cutaneous sarcoidosis or “sarcoidal infiltrates of the skin” (without evidence of systemic disease). This granulomatous process occurs primarily in adults and it is more common in African American individuals. The etiology of sarcoidosis is unknown.

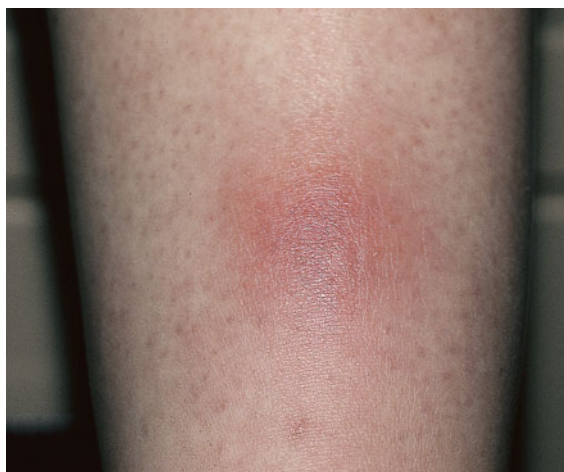► Clinical Presentation

A. History and Physical Examination

The classic nongranulomatous lesion associated with sarcoidosis is erythema nodosum (Figure 24-14), a tender erythematous and subcutaneous nodule generally located on the distal lower extremity, often the anterior or tibial surface.^{8,9} Other cutaneous lesions associated with sarcoidosis include granuloma annulare (Figure 24-9), erythema multiforme, nonspecific nail changes, and scarring and nonscarring alopecia. Cutaneous sarcoid granulomas present as yellow-red to rust-colored papules, plaques, or nodules (Figure 24-15). Other findings often associated with pulmonary involvement include clubbing of the nails and cyanosis of the fingertips and occasionally the lips. Palpable and sometimes quite visible lymphadenopathy, either localized or diffuse, occurs with systemic disease. Lesions of sarcoidosis frequently appear in scars. The conjunctiva is often involved in 50% or more of patients.



▲ **Figure 24-13.** Porphyria cutanea tarda. Collapsed bullae with crusts, erosions, and atrophic scars on dorsal hand.



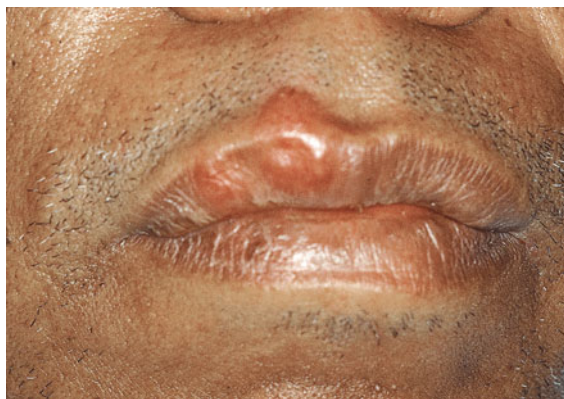▲ **Figure 24-14.** Erythema nodosum. Erythematous, tender, nodule on the pretibial surface.

B. Laboratory Findings

A skin biopsy is needed to confirm the diagnosis of cutaneous sarcoidosis. A chest X-ray, magnetic resonance imaging (MRI), positron emission tomography (PET), contrast enhanced cardiac scans, sinus films, angiotensin-converting enzyme (ACE), EKG, and pulmonary functions tests should be considered when clinically appropriate.

► Management

Sarcoidosis spontaneously resolves in the vast majority of patients (as high as 90+%). Topical and intralesional steroids can be used for the cutaneous granulomatous lesions. Systemic steroids and immunosuppressive agents may be needed for systemic disease.



▲ **Figure 24-15.** Cutaneous sarcoidosis. Erythematous nodular granuloma on upper lip.

► Differential Diagnosis

- ✓ Granuloma annulare, rheumatoid nodule, necrobiosis lipoidica, interstitial granulomatous dermatitis, foreign body reactions, granulomatous infection, and many other granulomatous processes must all be considered in the differential diagnosis.

Patient Information

PubMed Health: www.ncbi.nlm.nih.gov/pubmedhealth/PMH0001140/

NEUROLOGICAL DISEASES

Neurofibromatosis

► Introduction

Neurofibromatosis (NF) is a multisystem, autosomal dominant disorder affecting males slightly more often than women. Skin, eyes, nerves, bones, and endocrine organs constitute the primary targets of this process. The most common forms are NF1 (classic neurofibromatosis) and NF2.

► Pathophysiology

Both NF1 and NF2 are the result of single gene effects on tissues of neural crest origin. NF-1 is associated with gene mutations on chromosome 17 and NF-2 on chromosome 22.

► Clinical Presentation

A. History and Physical examination

Classic café au lait spots are seen within the first 3 years of life in both forms. The café au lait spot is a tan to light brown patch, appearing freckle-like typically ranging in size from 2 to 20 cm. Neurofibromas appear later and are seen in both forms. Neurofibromas are skin-colored papules, nodules, or polyps, which on firm palpation invaginate into the dermis (Figure 24-16). Plexiform neuromas are larger nodules and plaque with a “bags of worms” texture. Deposits of pigment in the iris (hamartomas called Lisch nodules) occur only in NF1 and are one of the diagnostic features when 2 or more are present. Unilateral acoustic neuromas may occur in NF1, but are more common and usually bilateral in NF2.

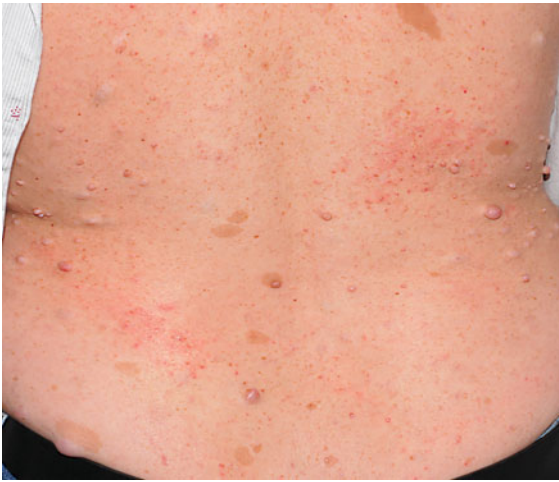B. Laboratory Findings

Histopathology of neurofibromas shows dermal nerve fibers and spindle cells. Café au lait lesions may have giant melanosomes.

► Diagnosis

To make the diagnosis of neurofibromatosis, two of the following findings must be present.¹⁰

1. Six or more café au lait spots 1.5 cm or larger
2. Axillary freckling (Crowe's sign)



▲ **Figure 24-16.** Neurofibromatosis (NF1). Multiple neurofibromas and café au lait spots on back.

3. First degree relative with neurofibromatosis
4. One plexiform neuroma or two or more neurofibromas
5. Bowing or thinning of long bone cortex or sphenoid wing dysplasia
6. Two or more Lisch nodules
7. Bilateral optic nerve gliomas

► Management

Management includes observation for development of associated tumors such as adrenal pheochromocytoma, sarcomas, optic glioma, acoustic neuroma, and astrocytoma. Symptomatic cutaneous lesions may need to be excised. Patients and their families should be referred for genetic counseling.

► Indications for Consultation

If there is a question about the diagnosis, patients should be referred for a specialist examination which should include a complete skin examination to confirm the diagnosis. They also should be referred for an ophthalmologic examination and genetic counseling. Once patients are diagnosed, management often requires a team approach with primary care, dermatology, neurology, and other appropriate specialists.

Patient Information

Neurofibromatosis network: www.nfnetwork.org

Tuberous Sclerosis

► Introduction

Tuberous sclerosis is an autosomal dominant disease, which is associated with tumors of the skin, central

nervous system, kidneys, and other organs. It has no gender predilection.

► Pathophysiology

Tuberous sclerosis is associated with dysregulation of tumor suppressor function that results in hyperplasia of both ectodermal and mesodermal cell-derived tissues. Mutations in tumor suppressor genes *TSC1* or *TSC2* on chromosome 9 or 16 are the cause of this disease.

► Clinical Presentation

A. History and Physical Examination

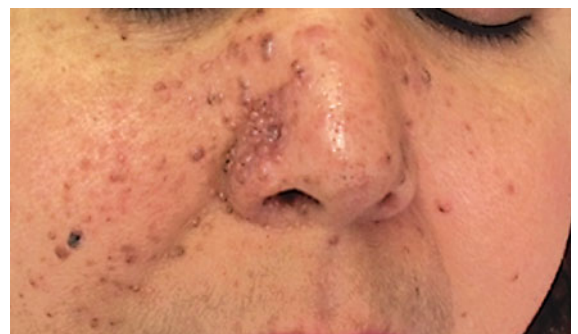Almost all affected (96%) individuals will have white or off-white macules, often referred to as “thumb print” or “ashleaf” macules present at birth or observed in the first year of life. A low IQ is present in about 45% of affected individuals. The clinical presentation includes the following:¹¹

- Three or more white macules
- Angiofibromas (adenoma sebaceum, Figure 24-17) 1 to 2 mm papules primarily over the central face.
- Connective tissue nevi skin-colored plaques (shagreen patch)
- Periungual and subungual fibromas
- Retinal plaques
- Cardiac rhabdomyomas
- Central nervous system tumors
- Seizures

B. Laboratory Findings

The following abnormalities may be present.

- Imaging studies may show “tubers” or gliomas of the brain and renal hamartomas.
- Skin biopsies show decreased melanocytes (in white macules) and angiofibromas in ungual or periungual lesions.



▲ **Figure 24-17.** Tuberous sclerosis. Multiple 1 to 2 mm angiofibromas (adenoma sebaceum) on nose and cheeks.

- An EKG may show dysrhythmias.
- Genetic tests may reveal mutations in *TSCS1* or *TSCS2* genes.

► Diagnosis and Differential Diagnosis

For diagnosis see above in clinical presentation.

The differential diagnosis for facial angiofibromas includes acne, rosacea, dermal nevi, fibrous papules, and syringomas.

► Management

Confirmation of the diagnosis requires an appropriate workup including EKG, renal studies, appropriate imaging studies, and genetic evaluation. Symptomatic cutaneous angiofibromas can be treated with surgical removal and laser. Observation for malignant transformation of gliomas is important.

► Indications for Consultation

Diagnosis and management are often difficult and frequently require a team approach with primary care clinicians, dermatology, neurology, geneticists, nephrology, and radiology.

Patient Information

Tuberous Sclerosis Alliance: www.tsalliance.org

REFERENCES

1. Obermoser G, Sontheimer RD, Zelger B. Overview of common, rare and atypical manifestations of cutaneous lupus erythematosus and histopathological correlates. *Lupus*. 2010;19(9):1050–1070. PMID: 20693199.
2. Kuhn A, Ruland V, Bonsmann G. Cutaneous lupus erythematosus: update of therapeutic options part I. *J Am Acad Dermatol*. 2011;65(6):e179–e193. PMID: 20739095.
3. Callen JP, Wortmann RL. Dermatomyositis. *Clin Dermatol*. 2006;24(5):363–373. PMID: 16966018.
4. Ahmed I, Goldstein B. Diabetes mellitus. *Clin Dermatol*. 2006;24(4):237–246. PMID: 16828404.
5. Perez MI, Kohn SR. Cutaneous manifestations of diabetes mellitus. *J Am Acad Dermatol*. 1994;30(4):519–531. PMID: 8157778.
6. Doshi DN, Blyumin ML, Kimball AB. “Cutaneous manifestations of thyroid disease.” *Clin Dermatol*. 2008;26(3):283–287. PMID: 18640525.
7. Ghosn SH, Kibbi A. Cutaneous manifestations of liver diseases. *Clin Dermatol*. 2008;26(3):274–282. PMID: 18640524.
8. Tchernev G. Cutaneous sarcoidosis: the “great imitator”: etiopathogenesis, morphology, differential diagnosis, and clinical management. *Am J Clin Dermatol*. 2006;7(6):375–382. PMID: 17173472.
9. English JC, Patel PJ, Greer KE. Sarcoidosis. *J Am Acad Dermatol*. 2001;44(5):725–743.
10. Jett K, Friedman JM. Clinical and genetic aspects of neurofibromatosis 1. *Genet Med*. 2010;12(1):1–11. PMID: 20027112.
11. Curatolo P, Bombardieri R, Jozwiak S. Tuberous sclerosis. *Lancet* 2008;372(9639):657–668. PMID: 18722871.

The Differential Diagnosis of Purpura

Sarah Nakib
Monica Rani

25

Introduction to Chapter / 229
Approach to Diagnosis / 229

Evaluation / 229
References / 236

INTRODUCTION TO CHAPTER

Purpura is extravasation of red blood cells into the skin or mucous membrane. For this reason, purpuric lesions do not blanch on diascopy (pressing on the lesion with a glass slide or finger). The differential diagnosis for purpura is broad, but it can be quickly narrowed by classifying the lesions based on their morphology, as well as other clinical and laboratory findings.^{1,2} The clinical descriptive terms for purpura are listed below, and their respective tables describing the differential diagnosis are referenced.

- **Petechiae:** Flat lesions, macules ≤ 4 mm (Figure 25-1), typically initially bright red and then fade to a rust color (Tables 25-1 and 25-2).
- **Ecchymosis:** Flat lesions, macules and/or patches, >5 mm (Figures 25-2 and 25-3), typically initially red or purple, but may fade to yellow, brown, or green (Table 25-3).
- **Palpable purpura:** Elevated, round or oval, red or purple papules and/or plaques (Figure 25-4), sometimes barely palpable (Table 25-4).
- **Retiform purpura:** Stellate or branching lesions, with angular or geometric borders (Figure 25-5). These are often palpable plaques, but can present as nonpalpable patches as well (Tables 25-5 and 25-6).

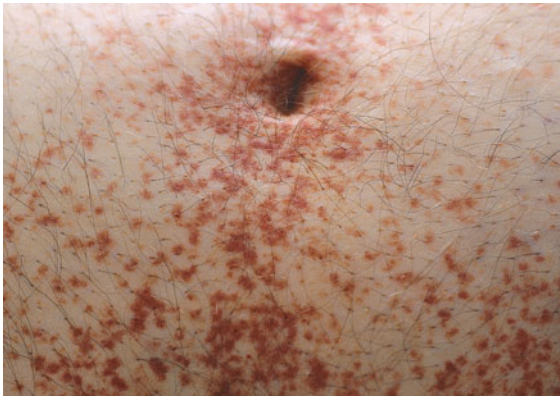APPROACH TO DIAGNOSIS

A flow chart for the differential diagnosis of purpura is in Figure 25-6. When considering the differential diagnosis of purpura, it is important to note that some of these

conditions are life threatening and require prompt consultation of the appropriate specialty.

EVALUATION

- A careful history and review of underlying medical conditions, medications, and a complete physical examination can be crucial to the diagnosis.
- Laboratory studies listed in the tables may assist with narrowing the differential diagnosis.
- A skin biopsy is often necessary for further evaluation, at which time referral to a dermatologist is recommended. An optimal biopsy involves appropriate selection of the biopsy type, site, timing, and interpretation of results. At times, an additional biopsy needs to be done for direct immunofluorescence (DIF).
 - Indications for skin biopsy: Palpable and retiform purpura should prompt a skin biopsy. Other indications include purpura whose cause cannot be determined by history, physical examination, and laboratory testing.
 - Timing of biopsy: A new lesion less than 2 days old is ideal for biopsy. It is important to make note of the age of the lesion, as a disease process can appear different on histopathologic examination at various stages. For example, late leukocytoclastic vasculitis (LCV) and early microocclusive purpura can have similar histopathologic findings. It is important to let the pathologist reading the biopsy know how long the process has been present. Distinguishing



▲ **Figure 25-1.** Petechiae. Bright red macules <4 mm on abdomen.

between vasculitis and microocclusive disease is important because the two disorders require different treatments.

- Biopsy for direct immunofluorescence (DIF): In addition to the standard 4 mm punch biopsy, an additional biopsy should be sent for DIF (in special media) if leukocytoclastic vasculitis (LCV), small and small-medium vessel vasculitis is in the differential. This is particularly useful early in the process of LCV and can assist in the diagnosis of IgA-mediated diseases.
- Findings on biopsy: Vasculitis is characterized by inflammation within vessel walls, often leading to extravasation of red blood cells and fibrin deposition in vessel walls. Vasculitis that manifests on the skin is limited to involvement of vessels found in the dermis and/

Table 25-1. Causes of petechiae (primary lesion is a macule ≤ 4 mm) with low platelets ($<150,000/\mu\text{L}$).

Disease/Disorder	Clinical Features and Associations	Initial Diagnostic Evaluation
Low platelets ($<150,000/\mu\text{L}$)	Mucocutaneous bleeding (eg, epistaxis, increased bleeding with menses or minor cuts) Splenomegaly and lymphadenopathy may be present	CBC with differential and peripheral smear; If anemic, check reticulocyte count, LDH, haptoglobin, and bilirubin If hemolysis is present, check PTT, PT/INR, fibrinogen, D-dimer, Coombs, ANA. If inconclusive, consider bone marrow biopsy
Immune thrombocytopenia (ITP) ³	F > M Primary: Insidious onset Secondary: Associated with underlying disease, for example, viral infections	Platelets $<100,000$ Diagnosis of exclusion Primary: Isolated decreased platelets Secondary: May relate to viral process (can obtain serology for HIV, HCV, HBV, EBV, or PCR for parvovirus and CMV), <i>H. pylori</i> , ANA, pregnancy, APLA, or TSH
Thrombotic thrombocytopenic purpura (TTP) ¹	Pentad: thrombocytopenia, hemolytic anemia, changes in mental status, fever, and renal dysfunction. Do not need all 5 for diagnosis It may be idiopathic, familial, drug-induced, from pregnancy, HIV, autoimmune disease, or hematopoietic stem cell transplant HUS: Thrombocytopenia, MAHA, and renal dysfunction; usually in children with prodrome of bloody diarrhea	Labs that can be observed: \downarrow Platelets and MAHA, schistocytes on p.smear, \uparrow reticulocyte count, positive hemolysis labs (\uparrow LDH, \uparrow indirect bilirubin, \downarrow haptoglobin), nLPTT & INR, \uparrow creatinine, \downarrow ADAMTS13 (in idiopathic TTP)
Disseminated intravascular coagulation (DIC) ⁴	Spectrum in hematologic abnormalities can have bleeding and/or thrombosis. May also have soft-tissue bleeding in muscle and joints May be related to trauma, shock, infection, malignancy, and obstetric complication	\uparrow PT/INR, \uparrow PTT, \downarrow fibrinogen, positive fibrin degradation product/D-dimer, and hemolysis labs
Drug-induced ¹	Petechiae, purpura due to drugs such as quinine, bactrim	Generally, isolated thrombocytopenia
Bone marrow suppression ¹	Associated with aplastic anemia, MDS, drugs (eg, thiazides and antibiotics), alcohol, cirrhosis, myelofibrosis, granulomas from infections, hematologic, or solid malignancies	Peripheral smear may show pancytopenia, blasts, hypersegmented PMNs, leukoerythroblastic changes (teardrop cells, nucleated RBCs, immature WBCs)

ADAMTS13, a disintegrin and metalloproteinase with a thrombospondin type 1 motif, member 13; ANA, antinuclear antibody; APLA, antiphospholipid antibody; bx, biopsy; CBC, Complete blood count; CMV, cytomegalovirus; dx, diagnosis; EBV, Epstein-Barr virus; F, female; *H. pylori*, *Helicobacter pylori*; HBV, hepatitis B virus; HCV, hepatitis C virus; HIV, human immunodeficiency virus; HUS, hemolytic uremic syndrome; LDH, lactate dehydrogenase; M, male; MAHA, microangiopathic hemolytic anemia; MDS, myelodysplastic syndrome; nRBC, red blood cells; p.smear, peripheral smear; PCR, polymerase chain reaction; PMNs, polymorphonuclear leukocytes; PT/INR, prothrombin time/international normalized ratio; PTT, partial thromboplastin time; TSH, thyroid stimulating hormone; WBC, white blood cells.

Table 25-2. Causes of petechiae (primary lesion is a macule ≤ 4 mm), with normal to high platelets ($>150,000/\mu\text{L}$).

Disease/Disorder	Clinical Features and Associations	Initial Diagnostic Evaluation
Platelet function disorder^{5,6}	Mucocutaneous bleeding	Look for splenomegaly and LAD Labs: CBC with differential, peripheral smear, BUN, creatinine, LFTs, and platelet aggregation tests. If suspect vWD or dysproteinemia, obtain vWF studies or SPEP/UPEP, respectively
Congenital or inherited ⁵	vWD: usually AD	vWD: \downarrow vW factor, \downarrow vWF activity (measured by ristocetin co-factor assay) \downarrow factor VIII, confirm with vWF multimer analysis
Acquired (eg, drug-induced, liver disease, uremia, dysproteinemia, acquired vWD) ⁵	Associated medications include: ASA, NSAIDs, clopidogrel, ticlopidine Acquired vWD may be associated with malignancy, autoimmune disease, hypothyroidism, or drugs	Liver disease may show abnormal LFTs or \uparrow PT/INR, \uparrow PTT Uremia will show \uparrow BUN Dysproteinemias will show abnormalities on SPEP/UPEP
Thrombocytosis secondary to myelofibrosis ⁶	Myelofibrosis maybe primary or secondary to other malignancy Massive splenomegaly, \pm fatigue, weight loss, and fever	Peripheral smear shows leukoerythroblastic changes and bone marrow biopsy shows a “dry tap” with severe fibrosis
No platelet abnormality		
Pigmented purpuric eruptions, capillaritis	Clustered petechial hemorrhage, often with a background of yellow brown discoloration often on lower extremities. Most common in middle aged to older men For example, Schamberg’s disease, “cayenne pepper” appearance	No systemic findings A biopsy maybe needed to differentiate lesions from vasculitis
Hypergammaglobulinemic purpura of Waldenstrom	Often in women, with recurrent crops of petechiae/purpura on lower extremities that burn/sting Primary or secondary to autoimmune disease (eg, Sjogren’s or SLE), RA, less likely hematologic malignancy	Hypergammaglobulinemia on SPEP \uparrow titer of IgG or IgA RF (standard RF tests only detect IgM RF) \uparrow ESR \pm positive ANA, anti-Ro, anti-La
Intravascular, local pressure, or trauma	Can be caused by valsava (eg, from vomiting or constipation) or blood pressure cuff	Can occur without an underlying lab abnormality

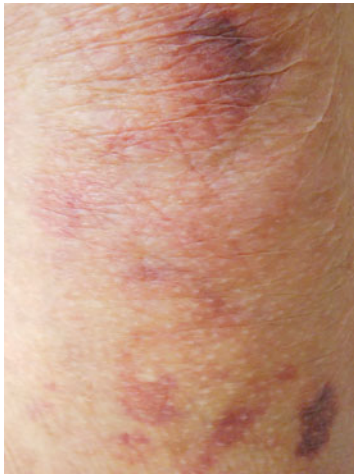AD, autosomal dominant; ANA, anti-nuclear antibody; ASA, aspirin; BUN, blood urea nitrogen; CBC, complete blood count; ESR, erythrocyte sedimentation rate; LAD, lymphadenopathy; LFTs, liver function tests; NSAIDs, nonsteroidal anti-inflammatory drugs; p.smear, peripheral smear; PT/INR, prothrombin time/international normalized ratio; RA, rheumatoid arthritis; RF, rheumatoid factor; SLE, systemic lupus erythematosus; SPEP/UPEP, serum protein electrophoresis/urine protein electrophoresis; vWD, Von Willebrand disease; vWF, Von Willebrand factor.

or subcutis. The size of the affected vessels may give clues to the diagnosis.

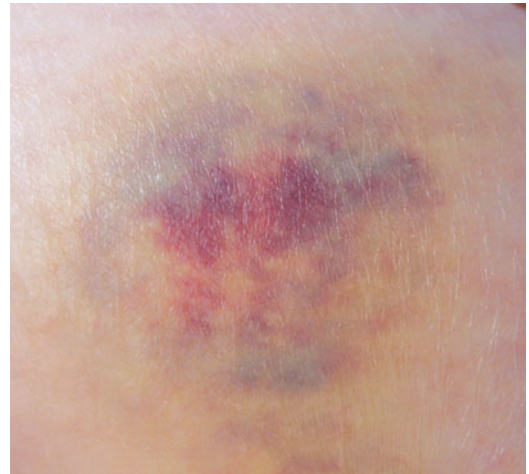- Small (eg, Henoch–Schönlein purpura, acute hemorrhagic edema of infancy, and urticarial vasculitis)
- Small-medium (eg, mixed cryoglobulinemia and rheumatic vasculitides)
- Medium (eg, polyarteritis nodosa)

DIF findings can give additional information, relating to the type of antibody visualized, for example, Henoch–Schönlein purpura and acute hemorrhagic edema of infancy show IgA deposition. The presence of granulomas

also narrows the differential. Microgranulomas with an eosinophilic infiltrate are found in Churg–Strauss, necrotizing granulomatous inflammation of the vessel in Wegener’s disease, and necrotizing pauci immune inflammation in microscopic polyangiitis. In chilblains, lymphocytic vasculitis with edema and thickening of dermal vessel wall is seen. Retiform purpura without inflammation generally reveals bland thrombi with no inflammation of vessel wall. Other retiform purpuras can have specific features, for example, cryoglobulinemia shows Periodic acid–Schiff stain positive hyaline intramural deposits, cholesterol emboli show needle-shaped clefts, and oxalate



▲ **Figure 25-2.** Ecchymosis. Red, purpuric patches on arm in a 80-year-old male.

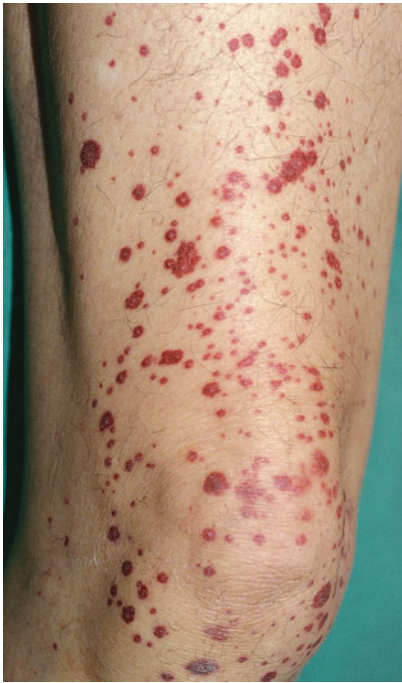

▲ **Figure 25-3.** Ecchymosis. Resolving purpura leaving red, purple, blue, and yellow patches.

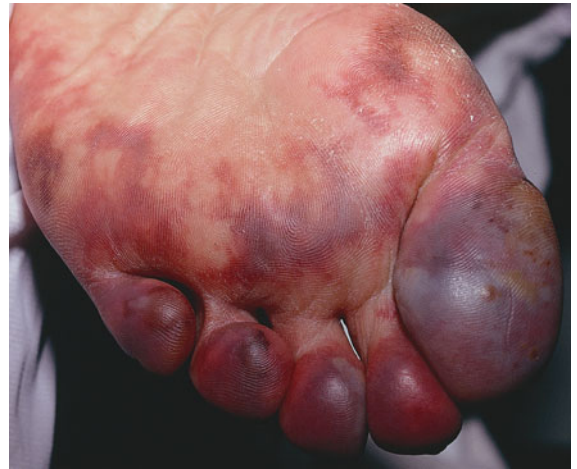Table 25-3. Causes of ecchymosis (primary lesion is a macule or patch ≥ 5 mm).

Disease/Disorder	Clinical Features and Associations	Initial Diagnostic Evaluation
Procoagulant defects¹	Susceptible to having deeper bleeding, into soft tissue	\uparrowPT/INR, $\pm$$\uparrow$PTT
Anticoagulant	For example, warfarin	\uparrow PT/INR
Liver disease	History of alcohol abuse, hepatitis, and primary liver disease	\uparrow PT/INR, \uparrow PTT, abnormal LFTs
Vitamin K deficiency	State of malnutrition (eg, alcoholic), malabsorption (eg, from antibiotics), and liver disease	\uparrow PT/INR
DIC	See Table 25-1	
Platelet disorders	See Table 25-1	
Decreased dermal support of vessels and minor trauma¹		
Solar or senile purpura	Older age and sun damaged skin usually on forearms	None
Corticosteroid therapy (systemic and topical)	Cushing's syndrome stigmata (eg, central obesity, dorsocervical fat pad, moon facies) Skin may reveal atrophy and telangiectasia	None
Scurvy (vitamin C deficiency)	Diet lacking in vitamin C Perifollicular hemorrhage, corkscrew hairs, gingival bleeding, and tooth loss	\downarrow Serum ascorbic acid deficiency and possibly other vitamins (eg, B12 and folate)
Systemic amyloidosis	All have hepatosplenomegaly, GI involvement (diarrhea, protein loss), and macroglossia May also have cardiac, renal, and liver involvement. Periorbital waxy ecchymotic papules, purpura with minor trauma, and "pinch-purpura"	SPEP/UPEP and free light chain, \pm bone marrow bx CBC with differential, LFTs, BUN, creatinine, urinalysis, and EKG Biopsy of abdominal subcutis fat pad reveals apple-green birefringence on Congo red stain Consider genetic testing for hereditary form
Genetic disease with collagen or elastin defects	Ehler-Danlos Syndrome: stretchable skin and flexible joints, usually AD inheritance Pseudoxanthoma elasticum: appearance of "plucked chicken skin" on neck	Genetic testing for specific mutations depending on the suspected condition

AD, autosomal dominant; BUN, blood urea nitrogen; bx, biopsy; CBC, complete blood count; EKG, electrocardiogram; GI, gastrointestinal; LFTs, liver function tests; PT/INR, prothrombin time/international normalized ratio; PTT, partial thromboplastin time; SPEP/UPEP, serum protein electrophoresis/urine protein electrophoresis.



▲ **Figure 25-4.** Palpable purpura. Multiple red papules on leg of a patient with Henoch-Schönlein purpura.



▲ **Figure 25-5.** Retiform purpura. Purpura on toes with retiform pattern on foot in a patient with cholesterol emboli.

Table 25-4. Causes of palpable purpura, inflammatory.

Disease/Disorder	Clinical Features and Associations	Initial Diagnostic Evaluation
Leukocytoclastic vasculitis, small and small-medium vessel vasculitis⁷⁻⁹	Purpuric papules or plaques typically on distal legs or dependent areas	Skin biopsy for routine histology and another for DIF
Idiopathic (IgG, IgM, or IgA), secondary to drugs or infection	IgA lesions can appear targetoid	In addition to skin biopsies, careful review of medications, and recent/current infections
Henoch-Schönlein purpura	M > F. Usually age <20 years Tetrad: purpura (universal), arthritis (82%), nephritis (40%), abdominal pain (63%), or gastrointestinal hemorrhage (33%) May appear targetoid, on extensor areas and buttock Extension to trunk/upper extremities can indicate renal involvement	Two skin biopsies should be done, one for routine histology and one for DIF Obtain BUN/Cr, urinalysis
Urticarial vasculitis	Persistence of hive-like lesions >24 hours, often burn > itch. Can have concomitant systemic symptoms (eg, LAD, arthralgia, angioedema, and fever). Can be caused by drug (eg, ACE inhibitors, penicillin, and sulfonamides), autoimmune disease, hematologic or other malignancies, and infections	In addition to skin biopsies, the following lab findings may be helpful: ↓ Complement (eg, CH50, C4, C3, Clq) may relate to a variety of systemic processes, for example, SLE, malignancy, and infection Creatinine and UA. For suspected infection screen for HBV, HCV, and heterophile serology For suspected autoimmune condition screen with autoantibody test

(continued)

Table 25-4. Causes of palpable purpura, inflammatory (Continued).

Disease/Disorder	Clinical Features and Associations	Initial Diagnostic Evaluation
Mixed cryoglobulinemia (Type II and III)	Usually acral distribution Weakness, livedo reticularis, leg ulcers, HSM, and Raynaud's phenomenon Can also have glomerulonephritis and peripheral neuropathy	In addition to skin biopsies, the following labs may be helpful: Cryoglobulins (proteins that precipitate from serum or plasma when cooled) Type II: Sjogren's, SLE evaluation. Type III: Hepatitis C RNA, ESR, and C4, RF
Rheumatic vasculitis (eg, RA, SLE, Sjogren's syndrome)	Digital ischemia, livedo reticularis, pericarditis, bowel ischemia, peripheral neuropathy	In addition to skin biopsies, the following lab findings may be helpful: + ANA and ↓complement (SLE) + RF, anti-CCP (RA) + ANA, RF, anti-Ro or La (Sjogren's)
Anti-neutrophilic cytoplasmic antibody (ANCA) associated		
Wegener's granulomatosis	Usually young and middle-aged adults Can have a nasal or oral (eg, sinusitis, saddle-nose deformity), pulmonary (eg, infiltrate, nodule, and cavity), or renal involvement (hematuria, RBC casts)	In addition to skin biopsies, +ANCA (90%), c-ANCA (anti-PR3)
Churg-Strauss	Usually age 30-40 years, with HLA-DRB4 Can also involve lungs (eg, asthma), peripheral nerves, heart, and kidneys	In addition to skin biopsies, CBC with differential, showing eosinophilia +ANCA (50%), p-ANCA (anti-MPO), or c-ANCA (anti-PR3)
Microscopic polyangiitis	Can involve the kidney and lungs	In addition to skin biopsies, +ANCA (70%), p-ANCA (anti-MPO)

ANA, antinuclear antibody; anti-CCP, anticitrullinated protein; C, complement; c/p ANCA, cytoplasmic/perinuclear antineutrophil cytoplasmic antibodies; CBC, complete blood count; CH50, Complement H50; Cr, creatinine; DIF, Direct immunofluorescence; ESR, erythrocyte sedimentation rate; HBV, hepatitis B virus; HCV, hepatitis C virus; HSM, hepatosplenomegaly; LAD, lymphadenopathy; MPO, myeloperoxidase; PAS, Periodic acid-Schiff stain; PR 3, proteinase 3; RA, rheumatoid arthritis; RBC, red blood cells; RF, rheumatoid factor; RNA, ribonucleic acid; SLE, systemic lupus erythematosus; UA, urinalysis.

Table 25-5. Causes of retiform purpura with inflammation.

Disease/Disorder	Clinical Features and Associations	Initial Diagnostic Evaluation
Rheumatic vasculitis (eg, RA and SLE) ^{1,13}	See Table 25-4	
PolyarteritisNodosa ^{1,13}	M > F. Age ~ 50 years Can have palpable subcutis nodules. Often multisystemic (eg, constitutional, renal, abdominal pain, livedo reticularis, peripheral neuropathies). Associated with HBV	In addition to skin biopsy, ↑ESR, CRP, WBC HBsAg (positive in 30%)
ANCA vasculitides	See Table 25-4	
Chilblains ^{1,13}	Acral distribution Occurs in cold, wet environment	History can be very suggestive. Skin biopsy may be helpful

ANCA, antineutrophil cytoplasmic antibodies; CRP, C-reactive protein; ESR, erythrocyte sedimentation rate; F, female; HBsAg, hepatitis B antigen; HBV, hepatitis B virus; M, male; RA, rheumatoid arthritis; SLE, systemic lupus erythematosus; WBC, white blood cell.

Table 25-6. Causes of retiform purpura, noninflammatory, and related to microocclusive disease.

Disease/Disorder	Clinical Features and Associations	Initial Diagnostic Evaluation
Platelet occlusion^{1,4,6,10}		In addition to a skin biopsy, the following lab findings may be helpful
Heparin necrosis (from heparin or low molecular weight heparin), heparin-induced thrombocytopenia (HIT), type II ¹⁰	Often on the abdomen > extremities. Lesions may be distant sites or sites of heparin infusion or injection. Onset 4-10 days after treatment or <24 hours if drug used within 100 days. Postop highest risk. New venous or arterial thrombus (venous > arterial) (Type I is with platelets >100,000 μ L and benign course)	Platelets <100,000 μ L or >50% drop from original with a + HIT antibody
Thrombocytosis, from myeloproliferative disorder ⁶	See Table 25-2	
Paroxysmal nocturnal hemoglobinuria (PNH)	Complement-mediated hemolytic anemia, hypercoagulability state, smooth muscle dystonia, cytopenia, aplastic anemia, MDS, evolution to AML, Budd-Chiari syndrome	CBC with differential and flow cytometry, showing \downarrow CD55 and CD59 Urine hemosiderosis
TTP	See Table 25-1	
Cold-related gelling or agglutination (eg, cryoglobulinemia, cold agglutinins) ¹	See Table 25-4. In addition, cryoglobulinemia type I (monoclonal) is associated with multiple myeloma and Waldenstrom's. Cold agglutinins in adults are associated with lymphoproliferative disease and in children infections (eg, <i>Mycoplasma pneumonia</i> , mononucleosis, and HIV)	
Occlusion secondary to organism invading vessel ¹	Invasive fungus, pseudomonas, strongyloidiasis, or leprosy in immunosuppressed patients or with history of travel to endemic areas	In addition to skin biopsy sent for routine histology, an additional biopsy may be sent for culture Culture blood and other affected body fluids
Occlusion from systemic coagulopathies^{1,11-13}		
Inherited hypercoagulable states	Venous or arterial thrombi, miscarriages in women	\uparrow PT/INR, PTT Protein C and S, antithrombin III, prothrombin 20210A, factor V Leiden mutation
Warfarin necrosis ¹	Onset 1-10 days after exposure Large irregular bullae with eventual necrosis on breasts, buttocks, thighs, and penile skin. More common in obese women or those with underlying hypercoagulopathy (eg, protein C or S or ATIII deficiency), may be postinfectious. Can have purpura fulminans	Nonspecific
Purpura fulminans ¹	Branching palpable purpura leading to peripheral symmetrical gangrene. Can have sepsis with DIC (refer to Table 25-1) or be postinfectious	\uparrow PT/INR, PTT, D-dimer, fibrin degradation products \downarrow Fibrinogen, platelets Bacteria cultures may be positive. Psmear shows schistocytes
Antiphospholipid antibody or lupus anticoagulant ^{1,13}	Acute and painful purpura, livedo reticularis and racemosa, and anetoderma. Usually age <40 years. Arterial thrombus, recurrent venous thrombi, or spontaneous abortions Associated with SLE (40%-50% of SLE pts r-w), malignancy, infection, or drugs	+ Anticardiolipin or B2-glycoprotein antibodies + Lupus anticoagulant (\uparrow PTT)

(continued)

Table 25-6. Causes of retiform purpura, noninflammatory, and related to microocclusive disease (Continued).

Disease/Disorder	Clinical Features and Associations	Initial Diagnostic Evaluation
Occlusion from emboli¹		
Cholesterol	M > F. Acral distribution Arterial or cardiac catheter, prolonged anticoagulation, acute thrombolytic therapy, arteriosclerosis, hypertension, and tobacco use are risk factors Can be multisystemic	In addition to characteristic skin biopsy findings, CBC with differential, showing eosinophilia Other lab abnormalities will depend on affected organ
Oxalate crystal	Acral distribution	Other than characteristic skin biopsy findings, may have hyperoxaluria
Endocarditis	Associated with IV drug use and prosthetic valves Stigmata include Osler's nodes, Janeway lesions, and splinter hemorrhages	Blood cultures, EKG Transthoracic and/or transesophageal echocardiogram
Occlusion from reticulocytes		
Sickle cell disease	Can have symptoms of anemia from chronic hemolysis, infections with encapsulated organism from infarcting spleen, osteomyelitis from infarcting bone, and pain crisis	CBC shows anemia Sickle-shaped RBCs or Howell-Jolly bodies on peripheral smear Hb electrophoresis
Calciophylaxis ¹⁴	F > M. Painful lesions leading to well-demarcated nonhealing ulcers. Can localize to extremities. Proximal distribution (eg, on trunk, buttock, and thighs) has poorer prognosis. Associated with chronic renal failure, diabetes, obesity, and poor nutrition	In addition to skin biopsy, the following lab findings are suggestive: hyperphosphatemia, elevated calcium-phosphate product (>70 mg/dL). Can also have ↑PTH, Ca, BUN, alkaline phosphatase

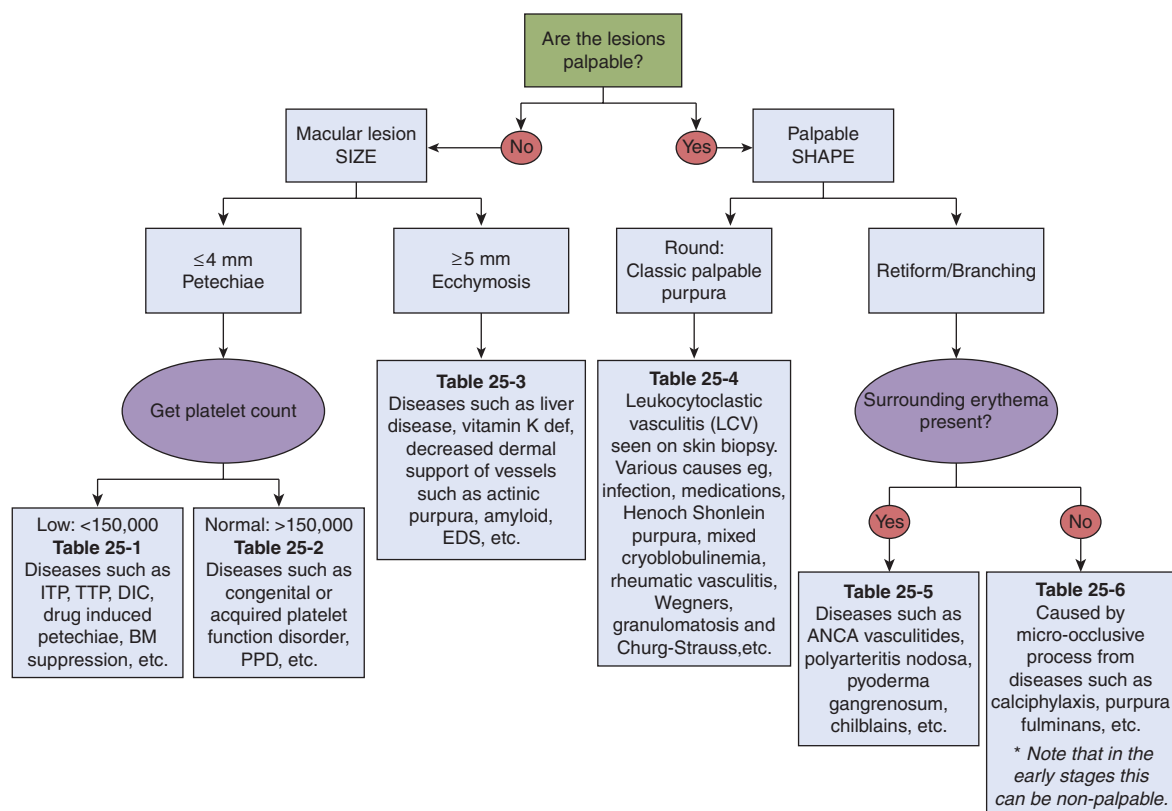
AML, acute myelogenous leukemia; APS, antiphospholipid syndrome; BUN, blood urea nitrogen; Ca, calcium; CBC, complete blood count; DIC, disseminated intravascular coagulation; F, female; Hb, hemoglobin; HIT, Heparin-induced thrombocytopenia; HIV, human immunodeficiency virus; HTN, hypertension; M, male; MDS, myelodysplastic syndrome; PT/INR, prothrombin time/international normalized ratio; PTH, parathyroid hormone; PTT, partial thromboplastin time; SLE, systemic lupus erythematosus.

crystal emboli show yellow-gray birefringent crystals in the subcutis and vessel walls.¹ A skin biopsy for calciophylaxis shows calcification of small and medium vessels.

The online learning center at www.LangeClinicalDermatology.com has clinical self-assessment questions for this chapter.

REFERENCES

- Piette WW. The differential diagnosis of purpura from a morphologic perspective. *Adv Dermatol.* 1994;9:3–24. PMID: 8060741.
- Piette WW. Hematologic diseases. In: Goldsmith LA, Katz SI, Gilchrist BA, Paller AS, Leffell DJ, Wolf K, eds. *Fitzpatrick's Dermatology in General Medicine*. 8th ed. New York, NY: McGraw-Hill; 2012:1731–1740.
- McCrae K. Immune thrombocytopenia: no longer 'idiopathic'. *Cleve Clin J Med.* 2011;78(6):358–373. PMID: 21632906.
- Kitchens CS. Thrombocytopenia and thrombosis in disseminated intravascular coagulation (DIC). *Hematology Am Soc Hematol Educ Program.* 2009;240–246. PMID: 200008204.
- Nichols WL, Hultin MB, James AH, et al. von Willebrand disease (VWD): evidence-based diagnosis and management guidelines, the National Heart, Lung, and Blood Institute (NHLBI) Expert Panel report (USA). *Haemophilia.* 2008;14(2):171–232. PMID: 18315614.
- Tefferi A. Polycythemia vera and essential thrombocythemia: 2012 update on diagnosis, risk stratification, and management. *Am J Hematol.* 2012;87(3):285–293. PMID: 22331582.
- Sunderkotter C, Sindrilara A. Clinical classification of vasculitis. *Eur J Dermatol.* 2006;16(2):114–124. PMID: 16581560.
- Carlson AJ, Chen KR. Cutaneous vasculitis update: small vessel neutrophilic vasculitis syndromes. *Am Dermatopathol.* 2006;28(6):486–506. PMID: 17122493.
- Gonzalez-Gay MA, Garcia-Porrúa C, Salvarani C, Lo Scocco G, Pujol RM. Cutaneous vasculitis: a diagnostic approach. *Clin Exp Rheumatol.* 2003;21(6 suppl 32):S85–S88. PMID: 14740432.
- Ortel TL. Heparin-induced thrombocytopenia: when a low platelet count is a mandate for anticoagulation. *Hematology Am Soc Hematol Educ Program.* 2009;225–232. PMID: 200008202.
- Wyson A, Venkatesan P. An approach to the patient with retiform purpura. *Dermatol Ther.* 2011;24(2):151–172. PMID: 21410606.
- Weinstein S, Piette WW. Cutaneous manifestations of antiphospholipid antibody syndrome. *Hematol Oncol Clin North Am.* 2008;22(1):67–77, vi. PMID: 18207066.
- Khenifer S, Thomas L, Balme B, Dalle S. Livedoid vasculopathy: thrombotic or inflammatory disease? *Clin Exp Dermatol.* 2010;35(7):693–698. PMID: 19874344.
- Mathu RV, Shortland JR, Nahas AM. Calciophylaxis. *Postgrad Med J.* 2001;77(911):557–561. PMID: 11524512.



▲ **Figure 25-6.** Flow chart for the differential diagnosis of purpura.

26

Pruritus in Patients with No Underlying Skin Disease

Rehana L. Ahmed

Introduction to Chapter / 238
Approach to Diagnosis / 238

Management / 238
References / 242

INTRODUCTION TO CHAPTER

Pruritus (itch) is the unpleasant sensation of the skin that results in a desire to scratch. It is a major symptom of many cutaneous and systemic diseases. Pruritus can range from mild to severe, and may be intermittent or chronic (lasting longer than 6 weeks). Pruritus can have a significant impact on health-related quality of life (HRQOL), and has been associated with depression, decreased sleep quality, and global distress.¹ The authors of a recent case-control study of patients with chronic pruritus observed that the impact of chronic pruritus on HRQOL may be similar to that of chronic pain.² Pruritus has multiple etiologies in patients with and without underlying skin disease. The International Forum for the Study of Itch published a clinical classification of pruritus³ in which they proposed 6 categories for pruritus based on the underlying origin:

1. Dermatological: Pruritus associated with diseases of the skin, including diseases that feature prominent pruritus such as atopic dermatitis, allergic contact dermatitis, xerotic dermatitis, lichen simplex chronicus, lichen planus, scabies, and urticaria. These diseases typically have characteristic skin findings.
2. Systemic: Pruritus associated with diseases in organs other than the skin, such as the liver, kidneys, hematopoietic system, etc.
3. Neurological: Pruritus associated with diseases or disorders of the central or peripheral nervous system.
4. Psychogenic/psychosomatic: Pruritus associated with psychiatric disorders.

5. Mixed: Pruritus from combinations of categories 1 to 4.
6. Other: Pruritus of undetermined origin.

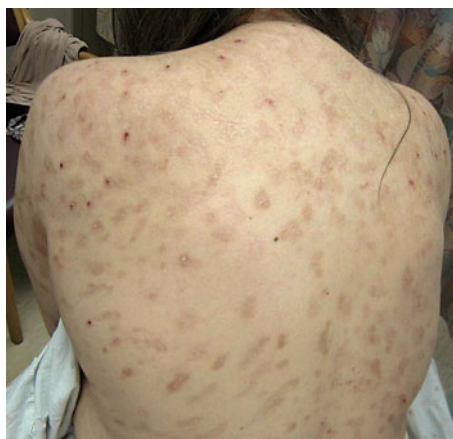Typically, the pruritus in categories 2 to 6 is associated with no primary skin lesions. However, secondary lesions from scratching or rubbing, such as excoriations (Figure 26-1), prurigo nodularis (Figure 26-2), or lichenification can be seen. It is important to determine the etiology of chronic pruritus, because it can be an early symptom of the diseases in categories 2 to 4. Table 26-1 contains information about selected diseases that are associated with chronic pruritus.

APPROACH TO DIAGNOSIS

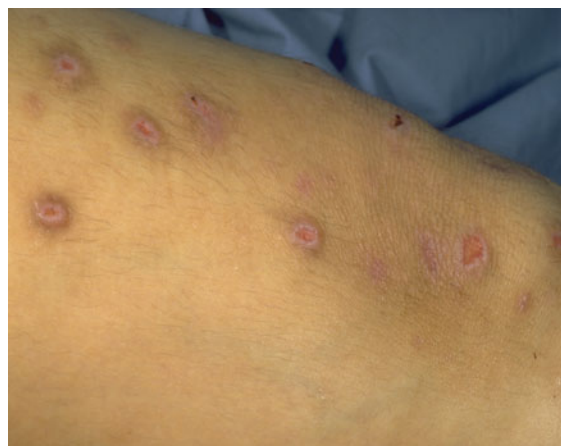The approach to the diagnosis of pruritus with no underlying skin disease relies on a careful history and physical examination. A thorough review of the patient's medical history and medications is essential. Additional evaluation with a skin biopsy, laboratory testing, or imaging may be required to further determine whether or not there is an underlying medical condition contributing to the patient's pruritus (Table 26-2). It is also important to rule out skin disorders that may be very pruritic, but may have subtle skin lesions, such as dry skin, scabies (Figure 26-4), pediculosis, or dermatitis herpetiformis.

MANAGEMENT

The neurophysiology of pruritus is quite complex and comprises an active area of research;¹¹ a better understanding will influence targeted treatment strategies. Correction



▲ **Figure 26-1.** Excoriations in a patient with no underlying skin disease. Excoriations with postinflammatory hyperpigmentation on back.



▲ **Figure 26-2.** Prurigo nodularis.

Table 26-1. Differential diagnosis of pruritus in patients with no underlying skin disease.

Disease	Epidemiology/Etiology	History and Clinical Presentation of Pruritus
Systemic		
Endocrine and metabolic disorders		
Renal failure	Occurs in 15%-48% of patients with end-stage renal failure, up to 90% on hemodialysis ⁴ Etiology poorly understood	Generalized more common than localized Peaks at night Resolves with transplantation ⁵
Hepatic disorders	Common—in up to 80% of patients with primary biliary cirrhosis Seen more in intrahepatic than extrahepatic obstruction: primary biliary cirrhosis, primary sclerosing cholangitis, obstructive choledocholithiasis, carcinoma of the bile duct, cholestasis, and hepatitis Pruritus of pregnancy (pruritus gravidarum) occurs in 1%-8% of pregnancies	Generalized, migratory Worse on the hands, feet, and areas constricted by clothing Worse at night May precede other manifestations of liver disease such as chronic cholestasis ⁶ Pruritus of pregnancy presents with pruritus of the hands and feet, may generalize. Usually presents in the 3rd trimester and resolves with delivery ⁷
Thyroid disease	More common with hyperthyroidism Pruritus with hypothyroidism, hypoparathyroidism, and pseudohypoparathyroidism may be due to xerosis ⁸	Usually more severe and generalized with hyperthyroidism Generalized or localized with hypothyroidism ⁸
Diabetes mellitus	Approximately 7% of diabetics are affected Reported with poor glycemic control, mechanism unknown ⁸	May be localized, especially in genital and perianal areas (may be due to neuropathy or infection)
Infections		
Human immunodeficiency virus (HIV)/Acquired immunodeficiency syndrome (AIDS)	May be presenting symptom of HIV infection HIV-infected patients develop several pruritic dermatoses, but may develop pruritus without other cutaneous findings ⁹	Local or generalized Intractable pruritus may correlate with HIV viral loads Elevated serum IgE, peripheral hypereosinophilia, and altered TH1/TH2 profile are associated with poor prognosis ⁹

(continued)

Table 26-1. Differential diagnosis of pruritus in patients with no underlying skin disease (Continued).

Disease	Epidemiology/Etiology	History and Clinical Presentation of Pruritus
Systemic		
Hepatitis C	Present in approximately 15% of patients with chronic hepatitis C ¹⁰	Generalized or localized (See cholestasis, above)
Parasites	Several, including ancylostoma, tungiasis, schistosomiasis, myiasis, helminthosis, toxicosis, trypanosomiasis ¹⁰	Local or generalized Often with other skin findings
Hematologic disorders		
Myelodysplasia	Prevalence unknown	Generalized or localized May present as aquagenic pruritus
Iron deficiency	May be a sign of malignancy ¹⁰	Generalized or localized Perianal or vulvar regions may be involved
Polycythemia vera (PCV)	30%-50% experience pruritus	Generalized Aquagenic pruritus may precede development of PCV by years ¹¹
Hodgkin's disease	30% have pruritus Severe persistent pruritus associated with poor prognosis May predict recurrence Less prevalent in non-Hodgkin's lymphoma and leukemia ¹²	Persistent, generalized Mild to intractable
Tumors		
Solid-organ tumors	May precede a cancer diagnosis Occurs in 5%-27% of patients in palliative care Unknown whether or not rates of malignancy are increased in patients with unexplained pruritus	Often generalized Mild to intractable Intensity or extent of pruritus not correlated with extent of tumor involvement ¹²
Carcinoid	Flushing and gyrate (wave-like) erythema common May experience pruritus during flushing episode	Upper half of body more commonly affected Other symptoms are often present
Drug induced: virtually any drug may be associated with pruritus		
	Common: antihypertensives, antiarrhythmics, anticoagulants, antidiabetic drugs, hypolipidemics, antimicrobials and chemotherapy agents, psychotropics, antiepileptics, cytostatic agents, cytokines, growth factors, monoclonal antibodies, plasma volume expanders, nonsteroidal anti-inflammatory drugs (NSAIDs) ¹⁰	Generalized pruritus is more common Mechanisms include cholestasis, hepatotoxicity, seborrhea/xerosis, phototoxicity, neurologic, histamine release, deposition, idiopathic
Neurologic (Neurogenic/Neuropathic)		
	Diverse etiology: brachioradial pruritus, multiple sclerosis, spinal or cerebral neoplasms, abscess, or infarcts; phantom itch, postherpetic neuralgia, notalgia (Figure 26-3) or meralgia paresthetica, conditions associated with nerve damage, compression, or irritation (including diabetes mellitus or vitamin B12 deficiency) ¹⁰	Usually localized Occurs due to dysfunction of signaling, synthesis, or sensation at any level of afferent pathway from skin to brain
Psychogenic/Psychosomatic		
	Delusions of parasitosis, psychogenic excoriations, and somatoform pruritus Associated with psychiatric disorders ¹⁰	Generalized or localized Important to rule out other causes
Mixed		
	Combination, such as uremic itch with xerosis, or neurologic and dermatologic itch in HIV/AIDS	

(continued)

Table 26-1. Differential diagnosis of pruritus in patients with no underlying skin disease (Continued).

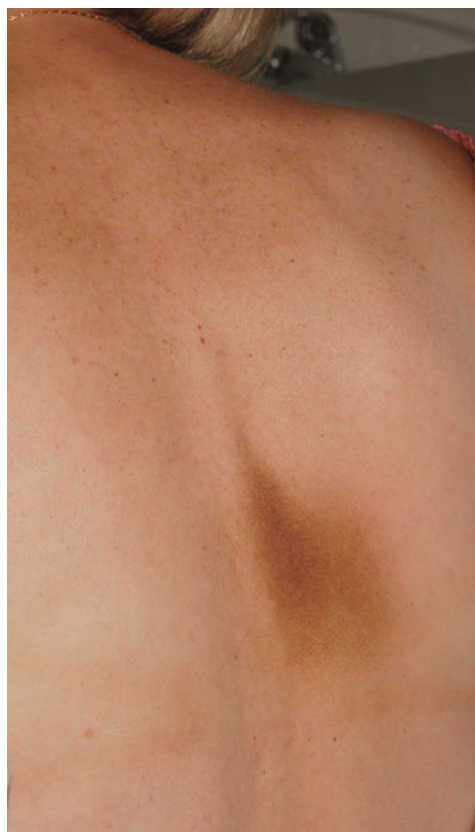Disease	Epidemiology/Etiology	History and Clinical Presentation of Pruritus
Other (of Unknown Origin)		
Pruritus of the elderly	Many causes: chronic disease, polypharmacy, xerosis, institutionalized care, age-related alterations of skin including atrophy, decreased cutaneous vascular supply, altered lipid composition, altered peripheral nerve innervations, and compromised moisture retention ¹³	Generalized or localized
Aquagenic pruritus	Generally secondary to systemic disease or other skin disorders There are strict criteria for true idiopathic aquagenic pruritus	Prickling, stinging, burning, and tingling sensation occur within 30 min of water exposure and lasts up to 2 h Begins on lower extremities and generalizes Spare head, palms, soles, and mucosa ¹⁴
Pruritus in anorexia nervosa	Etiology unknown Not related to other behaviors or internal abnormalities Resolves with weight restoration ¹⁵	Intermittent or constant May also experience burning or tingling Often localized: neck, thighs, forearms, buttocks, ankles, and upper arm

Table 26-2. Evaluation of pruritus.**Initial laboratory and imaging studies to evaluate for selected diseases:**

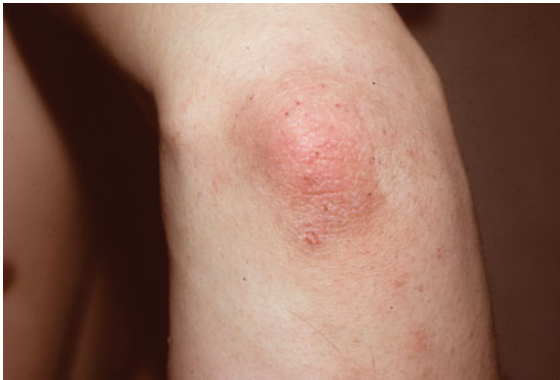- Complete blood count with differential (leukemia, myeloma, iron-deficiency anemia, B12 deficiency, polycythemia, infection, and HIV).
- Chemistry profile with liver function tests including aspartate aminotransferase (AST), alanine aminotransferase (ALT), alkaline phosphatase (ALP), and total bilirubin (cholestasis, hepatitis).
- Creatinine and blood urea nitrogen (uremia).
- Thyroid function with thyroid-stimulating hormone and reflex free T4 (thyroid disease).
- Chest X-ray (lymphoma, lung cancer).

Additional testing may be guided by the patient's history and physical findings including:

- Sedimentation rate (inflammation)
- Glucose (diabetes).
- Iron studies: transferrin, percent saturation, ferritin, and total iron (anemia).
- Serum protein electrophoresis (myeloma).
- Other: HIV antibody test, hepatitis serology, antinuclear antibody, antimitochondrial antibody, antigliadin antibody, antitransglutaminase antibody, parathyroid hormone, calcium, phosphate, specific immunoglobulin (Ig)E, serum tryptase, serotonin and its metabolites, stool for ova and parasites, stool for occult blood, and age and gender appropriate malignancy work-up.



▲ **Figure 26-3.** Notalgia paresthetica. Hyperpigmented, slightly lichenified plaque on back caused by chronic rubbing and scratching.



▲ **Figure 26-4.** Bites from scabies mite on elbow. Subtle excoriated papules.

of underlying conditions may improve pruritus (such as for pruritus related to iron-deficiency).¹⁰ While a complete review of all treatment options for pruritus is beyond the scope of this chapter, Chapter 6 contains topical antipruritic medications and oral medications that may be helpful in the management of patients with pruritus. Treatments may include emollients, topical capsaicin, lidocaine, calcineurin inhibitors or corticosteroids, antihistamines (sedating and nonsedating), and light therapy (narrow or broadband UVB). Other systemic treatments are guided by the underlying cause of pruritus (including anticholestatics, antidepressants, anticonvulsants, thalidomide, and opioid inhibitors).¹⁰ Innovative management of pruritus due to underlying systemic disease is reviewed in reference.¹⁶

The online learning center at www.LangeClinicalDermatology.com has clinical self-assessment questions for this chapter.

REFERENCES

1. Tessari G, Dalle Vedove C, Loschiavo C, et al. The impact of pruritus on the quality of life of patients undergoing dialysis: a single centre cohort study. *J Nephrol.* 2009;22(2):241–248. PMID: 19384842.
2. Kini SP, Delong LK, Veledar E, McKenzie-Brown AM, Schaufele M, Chen SC. The impact of pruritus on quality of life: the skin equivalent of pain. *Arch Dermatol.* 2011;147(10):1153–1156. PMID: 21680760 [Epub ahead of print].
3. Ständer S, Weisshaar E, Mettang T, et al. Clinical classification of itch: a position paper for the International Forum for the Study of Itch. *Acta Derm Venerol.* 2007;87(4):291–294. PMID: 17598029.
4. Narita I, Iguchi S, Omori K, Gejyo F. Uremic pruritus in chronic hemodialysis patients. *J Nephrol.* 2008;21(2):161–165. PMID: 18446709.
5. Patel TS, Freedman BI, Yosipovitch G. An update on pruritus associated with CKD. *Am J Kidney Dis.* 2007;50(1):11–20. PMID: 17591521.
6. Kremer AE, Beuers U, Oude-Elferink RP, Pusch T. Pathogenesis and treatment of pruritus in cholestasis. *Drugs.* 2008;68(15):2163–2182. PMID: 18840005.
7. Weisshaar E, Diepgen TL, Luger TA, Seeliger S, Witteler R, Ständer S. Pruritus in pregnancy and childhood—do we really consider all relevant differential diagnoses? *Eur J Dermatol.* 2005;15(5):320–331. PMID: 16172038.
8. Jabbar SA. Cutaneous manifestations of endocrine disorders, a guide for dermatologists. *Am J Clin Dermatol.* 2003;4(5):315–331. PMID: 12688837.
9. Singh F, Rudikoff D. HIV-associated pruritus. Etiology and management. *Am J Clin Dermatol.* 2003;4(3):177–188. PMID: 12627993.
10. Cassano N, Tessari G, Vena GA, Girolomoni G. Chronic pruritus in the absence of specific skin disease. An update on pathophysiology, diagnosis and therapy. *Am J Clin Dermatol.* 2010;11(6):399–411. PMID: 20866115.
11. Saini KS, Patnaik MM, Tefferi A. Polycythemia vera-associated pruritus and its management. *Eur J Clin Invest.* 2010;40(9):828–834. PMID: 20597963.
12. Yosipovitch G. Chronic pruritus: a paraneoplastic sign. *Dermatol Ther.* 2010;23(6):590–596. PMID: 21054705.
13. Ward JR, Bernhard JD. Willan's itch and other causes of pruritus in the elderly. *Int J Dermatol.* 2005;44(4):267–273, review. PMID: 15811075.
14. du Peloux Menagé H, Greaves MW. Aquagenic pruritus. *Semin Dermatol.* 1995;14(4):313–316. PMID: 8679437.
15. Morgan JF, Lacey JH. Scratching and fasting: a study of pruritus and anorexia nervosa. *Br J Dermatol.* 1999;140(3):453–456. PMID: 10233265.
16. Feramisco JD, Berger TG, Steinhoff M. Innovative management of pruritus. *Dermatol Clin.* 2010;28(3):467–478. PMID: 20510757.

Fever and Rash

Kristen Hook

27

Introduction to Chapter / 243
Approach to Diagnosis / 243

Evaluation / 243
References / 252

INTRODUCTION TO CHAPTER

Bacterial and viral infections are frequently associated with a rash and fever in children. Many of these rashes have known etiologies and characteristic features. Recognizing the pattern of the rash, and identifying key points in the history can help to establish the diagnosis. In Table 27-1, a number of pediatric exanthems are summarized, as well as some other rashes associated with fever. Most exanthems are self-limited and resolve in 7 to 10 days and only symptomatic treatment is needed.

Vaccinations have significantly decreased the incidence of measles, rubella, varicella, and their congenital complications. However, isolated outbreaks of imported measles still occur, especially in unvaccinated populations.^{1,2}

APPROACH TO DIAGNOSIS

Identifying key points in the history and patterns of rash development will aid in diagnosis (see Table 27-1). Many exanthems are preceded by a prodromal period, and may have an associated characteristic enanthem. Morphology is commonly described as erythematous and papular or maculopapular. The distribution and chronology of the symptoms, as well as morphology of the lesions are important defining characteristics. For instance, a rash appearing and resolving in a cephalocaudal pattern is characteristic of many exanthems such as measles and rubella. Additionally, some rashes may be unilateral, or present only in dependent areas, such

as unilateral laterothoracic exanthem and Henoch–Schonlein purpura, respectively. The color of the rash, characteristic primary lesion, presence of desquamation or swelling can all aid in diagnosis. Rarely, biopsy is needed to confirm the diagnosis. Serologic evaluation can help in some cases to identify a specific viral etiology, but is not necessary for treatment in most cases. Frequently included in the clinical differential diagnosis is drug rash, heat rash (miliaria rubra) among a host of possible viral etiologies.

EVALUATION

- Most rashes can be diagnosed clinically based on the patient's history and physical findings.
- If the diagnosis is not clear, serologic blood studies as listed in Table 27-1 may be helpful.
- However, a skin biopsy is rarely helpful in establishing the diagnosis of most viral exanthems. A skin biopsy can be diagnostic for erythema multiforme and Henoch–Schonlein purpura. Varicella and cytomegalovirus infections may show specific changes on biopsy. A biopsy can be helpful in staphylococcal scalded skin syndrome, especially if toxic epidermal necrolysis is considered, but is not necessary for diagnosis.
- If varicella (chickenpox) is suspected, polymerase chain reaction (PCR), direct fluorescent antibody test (DFA),

and viral cultures can be done. A Tzanck smear or a skin biopsy can be done but does not distinguish between herpes simplex and varicella zoster infections.

- Kawasaki disease should be considered in any child with prolonged fever of unknown origin.
- Vaccine preventable diseases should be considered in unvaccinated populations and the immunocompromised.

- Appropriate services should be consulted, and inpatient hospitalization considered for patients with meningococemia, toxic-shock syndrome, staphylococcal scalded skin syndrome, and Kawasaki's disease.

The online learning center at www.LangeClinicalDermatology.com has clinical self-assessment questions for this chapter.

Table 27-1. Differential diagnosis of fever and rash.

Disease/Etiology	History	Clinical Findings	Laboratory Studies
Viral			
Measles ³⁻⁸ (rubeola) Paramyxovirus ssDNA	Incubation: 8-14 days Prodrome: fever, cough, coryza, and conjunctivitis Rash lasts 4-7 days	Erythematous macules and papules appear on scalp along hairline and behind ears. Spreads in cephalocaudal distribution (Figure 27-1) and by 5th day, clears in same distribution. Koplik spots (red macules with a white blue center) may be seen on the buccal mucosa. Complications: otitis, pneumonitis, encephalitis, and myocarditis	A fourfold increase in acute and convalescent titers (IgG) confirm diagnosis. IgM assay can be used for rapid diagnosis. PCR and ELISA are also available
Varicella ^{7,8} (Chicken pox) Varicella zoster virus dsDNA	Incubation: 10-21 days Prodrome: Malaise and low grade fever Late fall, winter, and spring	Tear drop vesicles, "dew on a rose petal" (Figure 27-2A and B). Multiple lesional stages present at once. Immunocompromised patients at increased risk of disseminated disease, pneumonia, and secondary infection. Reye syndrome associated with aspirin use. Congenital varicella is associated with hypoplastic limbs	Clinical diagnosis usually sufficient. PCR and DFA are available for rapid diagnosis, viral cultures take several days. Acute and convalescent IgM and IgG antibody titers confirmatory
Cytomegalovirus (CMV) dsDNA	Postnatal infection in immune competent usually asymptomatic, but mononucleosis-like syndrome may occur	Erythematous macules and papules in diffuse distribution. Skin or mucosal ulcerations are possible. Complications include congenital CMV: "Blueberry muffin" baby resulting in hearing loss, seizures, and intracranial calcifications	Urine virus isolation, serologic evaluation, antigen (blood), and PCR analysis (blood). Skin biopsy may show intracytoplasmic, intranuclear viral inclusions in endothelial cells
Mononucleosis Human herpesvirus 4 (HHV-4) Epstein-Barr virus dsDNA	Incubation: 30-50 days Prodrome: Fever, pharyngitis, lymphadenopathy, malaise, and anorexia. Rash following use of amoxicillin/ampicillin	Morbiliiform rash spreads over entire body (Figure 27-3). Periorbital edema. Petechiae on palate (Figure 27-4). Painful mucosal ulcerations (especially vaginal/perineal)	Leukocytosis with 50% lymphocytosis. Elevated LFTs. Monospot test for IgM heterophile antibodies, usually positive by second week of infection. Not reliable in children <4 years due to low sensitivity

(continued)

Table 27-1. Differential diagnosis of fever and rash (Continued).

Disease/Etiology	History	Clinical Findings	Laboratory Studies
Viral			
Rubella ⁷⁻⁹ (German measles) Togavirus ssRNA	Incubation: 16-18 days Prodrome: fever, headache, and upper respiratory symptoms	Rose-pink macules in cephalocaudal spread, and clears in 2-3 days in the same manner. May have soft palate petechiae (Forschheimer's spots), posterior auricular/occipital lymphadenopathy. Self-limited. Complications: teratogenic (congenital rubella syndrome characterized by deafness, cataracts, congenital heart disease, and CNS signs), hepatitis, myocarditis, pericarditis, hemolytic anemia, and thrombocytopenic purpura. Arthritis in adults	IgM antirubella antibody presence, and/or a fourfold increase in IgG antirubella antibody are most diagnostic
Roseola ^{7,8} (exanthem subitum) HHV6 dsDNA	Incubation: 5-15 days Prodrome: high fever for 2-3 days, followed by rash on trunk, which then spreads to extremities and face, for 1-2 days. Usually in children <3 years old	Erythematous, blanchable, macules, and papules. Periorbital edema is a common association. Rash appearing after fever defervescence is key finding. Complications: seizures secondary to fever	Serologic confirmation available with ELISA or PCR
Parvovirus B19 ^{7,8,10,11} (fifth disease, erythema infectiosum) Parvovirus B19 ssDNA	Incubation: 4-14 days Patients with fifth disease are no longer viremic at presentation. Patients with papular-purpuric gloves and socks syndrome are viremic at presentation Prodrome: headache and fever	Slapped cheeks (red plaques) at 1-4 days (Figure 27-5), then lacy reticular rash in 4-9 days, which can wax and wane for several weeks. Arthritis alone can be seen in adults as presenting sign. Associated "papular-purpuric gloves and socks" syndrome in adolescents. Complications: hydrops fetalis and aplastic crises in sickle cell patients	Clinical diagnosis is usually sufficient. Serologic studies available for detection of anti-B19 IgM and IgG antibodies. PCR studies also available. In a pregnant female who has been exposed to B19, serologic testing for IgM and IgG antibodies should be performed
Hand, foot, and mouth disease ⁷ Coxsackie A16 (most common serotype) Picornavirus ssRNA	Incubation: 3-6 days Prodrome: fever and malaise	Macules progress to vesicles on red base on the hands and feet (especially on palms and soles) and oral mucosa (Figure 27-6 A and B). Oral lesions are painful and quickly erode	Testing usually not indicated, but PCR is available
Herpangina ⁷ Coxsackie groups A and B most common, other echoviruses ssRNA	Incubation: 4-14 days Prodrome: fever Most common in children 3-10 years old	Oral erosions and ulceration in posterior pharynx and buccal mucosa. Exanthem usually absent	Testing usually not indicated, but PCR is available

(continued)

Table 27-1. Differential diagnosis of fever and rash (Continued).

Disease/Etiology	History	Clinical Findings	Laboratory Studies
Viral			
Gianotti-Crosti syndrome ^{8,12} (acrodermatitis of childhood) Most commonly hepatitis B in developing countries, EBV in USA. Other causes include numerous viruses, bacteria, and vaccinations	Most common in spring/early summer. Most common in 2 year olds with range 6 months to 14 years old. May have associated low grade fever and lymphadenopathy. Hepatosplenomegaly less often	Symmetric papular eruption of face, buttocks, and extremities (Figure 27-7). Papules are pink, to erythematous, “juicy,” and have acral predilection	Evaluate for specific viral etiology, only if indicated
Unilateral laterothoracic exanthem (periflexural exanthema of childhood) No confirmed etiology, but considered a viral exanthem	Most common in 2 year olds with range 6 months to 10 years. Preceded by URI or GI symptoms. Associated with low grade fever, lymphadenopathy, diarrhea or rhinitis, and pruritus	Rash usually starts in unilateral axilla and spreads in centrifugal fashion to contralateral side as the disease progresses (Figure 27-8). Erythematous papules, plaques with associated scale, with unilateral predominance. May appear urticarial	Laboratory tests not indicated
Nonspecific viral exanthem ⁷ Nonpolio enteroviruses (most common cause in summer) and respiratory viruses (most common cause in winter)	Prodrome: fever, myalgia, malaise, or gastrointestinal symptoms. Most are self-limited, resolve in 1 week	Blanchable erythematous papules and macules in diffuse distribution involving trunk (Figure 27-9), and extremities, and less often the face	Laboratory tests not required. Enterovirus culture can be obtained from throat or stool
Bacterial			
Scarlet fever ⁷ Group A beta-hemolytic streptococcus (GABHS): pyrogenic exotoxin—A, B, or C	Incubation: 1-4 days Prodrome: fever, chills, sore throat, and headache. Signs of strep pharyngitis likely. Rash lasts 4-5 days Primarily a disease of children 1-10 years old	Clinical signs of streptococcal pharyngitis likely. Enanthem appears as white coating on the tongue, which sloughs in 4-5 days leaving the classic “strawberry tongue” (Figure 27-10). Fine, erythematous papules and macules (sandpaper-like rash), accentuated in flexures with petechial component (Pastia’s lines). Circumoral pallor characteristic. Rash resolves over 4-5 days and commonly heals with significant desquamation	Gold standard is throat culture with growth of GABHS. The rapid strep test has a high sensitivity and specificity. Antistreptococcal serologic studies are also available and may be useful
Staphylococcal scalded skin syndrome ⁸ (Ritter’s disease) <i>Staphylococcus aureus</i> , phage group II, exfoliative toxin (ETA, ETB) See Chapter 23 for more detailed information	Fever, malaise, lethargy, irritability, and poor feeding with rapid onset of generalized tender erythema. Cutaneous or systemic staphylococcal infection may be present	Tender erythematous lesions with flexural, perioral accentuation which progresses to large, superficial fragile blisters that rupture easily, leaving behind denuded, desquamating, erythematous, and tender (Figure 27-11). The Nikolsky sign (desquamation induced by slight rubbing of the skin) is positive	Culture of causative lesion (eg pustule, purulent conjunctivitis, surgical wound) if present. Blood cultures positive rarely. Skin culture of rash will not yield organisms. The organism is most easily recovered from pyogenic (not exfoliative) foci on the skin, conjunctivae, nares, or nasopharynx. See Table 23-5 for differential diagnosis

(continued)

Table 27-1. Differential diagnosis of fever and rash (Continued).

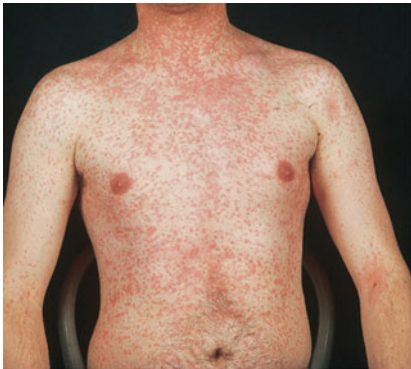Disease/Etiology	History	Clinical Findings	Laboratory Studies
Bacterial			
Toxic shock syndrome (TSS) ^{13,14} <i>Staphylococcus aureus</i> , TSS toxin-1 or streptococcal (GABHS)	Menstrual and nonmenstrual forms; the latter more common. Caused by toxin-producing strains of <i>S. aureus</i> . Prodrome of malaise, myalgias, chills precedes rash. Fever, lethargy, diarrhea, and altered mental status ultimately develop	Diffuse, scarlatiniform rash that later desquamates, palms, and soles involved. Accentuation in skin folds may be seen, and in rare cases, inguinal folds or perineal area may be only area of involvement. Hypotensive symptoms, shock, hyperemia of the mucous membranes and pharyngitis, "strawberry tongue." Skin or muscle tenderness may be associated. Edema of hands/feet Streptococcal disease: Usually characterized by a focal tissue or blood infection with GABHS. Necrotizing fasciitis, myonecrosis may be associated. Extremely painful. Shock develops rapidly with renal impairment, DIC, and respiratory distress syndrome	Evidence of multiorgan involvement required. To meet criteria, 3 of 7 organ systems must be involved. Clinical diagnosis usually acceptable, but if positive culture or toxin production can be demonstrated, this is supportive. Biopsy not helpful usually. Leukocytosis, anemia, thrombocytopenia, elevated creatinine and CK, hypocalcemia, abnormal liver function studies, and evidence of disseminated coagulopathy may be present Cultures may be obtained from blood, throat, CSF, and peritoneal fluid. Tissue biopsy for culture if streptococcus is suspected
Meningococcemia ^{8,15} <i>Neisseria meningitidis</i> Serogroups A, B, and C	Incubation: 2-10 days, average is 4 days Presentation varies from fever to fulminant disease. Upper respiratory prodrome, followed by high fever and headache. Meningitis associated with stiff neck, nausea, vomiting, and coma. Leading cause of bacterial meningitis in children	Petechial rash of skin and mucous membranes. Other morphologies may be seen including macular (Figure 27-12), morbilliform, urticaria, and gray-colored acrocyanosis. Trunk and lower extremities are commonly involved. Palms, soles, and head tend to be spared. Extensive hemorrhagic lesions seen in fulminant disease. Progression to purpura fulminans (purpuric patches with sharply marginated borders, progressing to necrosis and eschar formation) when associated with consumptive coagulopathy. Autoamputation is a potential complication	Culture blood and CSF. Meningococci isolation from nasopharynx is not diagnostic. Petechial lesions may be cultured for organisms. Serology detecting <i>N. meningitidis</i> capsular polysaccharide antigen in CSF, urine, serum, and other bodily fluids is available. PCR available and useful if antibiotics already used
Multiple etiologies			
Urticaria multiforme ¹⁶ Multiple etiologies	Upper respiratory infections, viral infections, and fever can occur as prodrome. Abrupt presentation of rash. Fever commonly associated	Abrupt presentation of annular erythematous wheals that may have associated central clearing (Figure 27-13). Generally widespread. Hand/foot edema common. May have associated lip swelling	Skin biopsy may be helpful if other entities are considered including erythema multiforme

(continued)

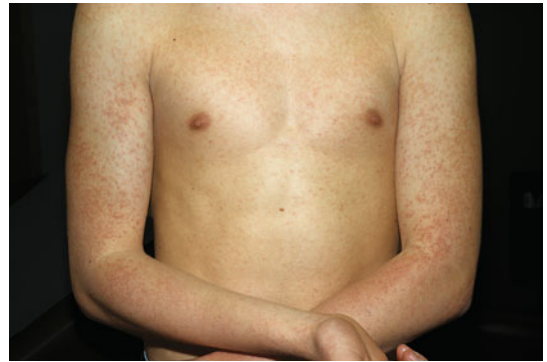Table 27-1. Differential diagnosis of fever and rash (Continued).

Disease/Etiology	History	Clinical Findings	Laboratory Studies
Multiple etiologies			
Serum-sickness like reaction (SSLR)¹⁶ Cefaclor most common cause. Amoxicillin, griseofulvin also described, among others	Develops 1-3 weeks after initiation of inciting drug with mild fever, rash, and joint pain	Targetoid or annular to polycyclic erythematous plaques. Violaceous center of plaques very characteristic	True vasculitis as seen in serum sickness reaction, type 3 immune mediated reaction is absent in SSLR
Erythema multiforme^{8,16} HSV, mycoplasma, medications most common cause	Herpes simplex infection may precede rash	Targetoid erythematous plaques that are persistent and nonmigratory for days. Palm/sole involvement common	HSV titers, cold agglutinins for mycoplasma. Skin biopsy diagnostic
Henoch-Schonlein purpura⁸ Etiology unclear, but linked to GABHS, viral infections, drugs, and immunizations	Small vessel vasculitis that occurs in children. Most common 2-11 years old. Antecedent upper respiratory infection suggests hypersensitivity phenomenon	Initial lesions appear urticarial, but quickly progress to purpuric (nonblanchable) papules with primary distribution on lower extremities (Figure 27-14) and buttocks. Scrotal involvement common. Edema of hands, face, feet commonly seen, especially in younger patients. Individual lesions resolve in 4-5 days. Associated with abdominal pain, arthritis, and glomerulonephritis	IgA immune complexes in affected organs. Direct immunofluorescence of skin specimens may document IgA, but absence should not exclude diagnosis. One-third of patients will have elevated serum IgA
No confirmed etiology			
Kawasaki's disease^{8,17} (acute febrile mucocutaneous lymph node syndrome) Unknown etiology, but probably due to infection	Winter or spring most common. Most common in children <5 years old, peak incidence <2 years old	Need 4 of 5 criteria: (1) fever >5 days, (2) palmoplantar urticarial erythema/desquamation, (3) conjunctivitis, (4) strawberry tongue/red fissured, crusted lips, (5) cervical lymphadenopathy. A polymorphous rash on the trunk and extremities usually occurs presenting as a maculopapular, targetoid or scarlet fever-like rash with accentuation in body fold areas. "Atypical" cases more commonly diagnosed Complications: coronary artery aneurysms, myocarditis, and other cardiovascular disease	No reliable diagnostic test. The histopathologic features of a skin biopsy are nonspecific. Clinical diagnosis required

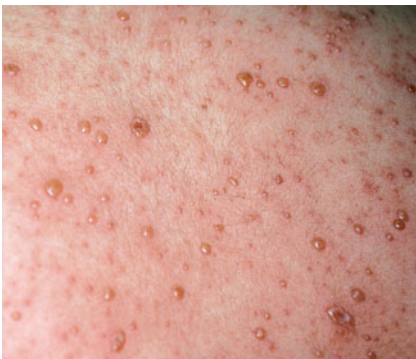CK, Creatine kinase; CNS, central nervous system; CSF, cerebrospinal fluid; DFA, direct fluorescent antibody; DIC, disseminated intravascular coagulation; ds, double stranded; EBV, Epstein-Barr virus; ELISA, enzyme-linked immunosorbent assay; GI, gastrointestinal; LFTs, liver function tests; PCR, polymerase chain reaction; ss, single stranded; URI, upper respiratory infection USA, United States of America.



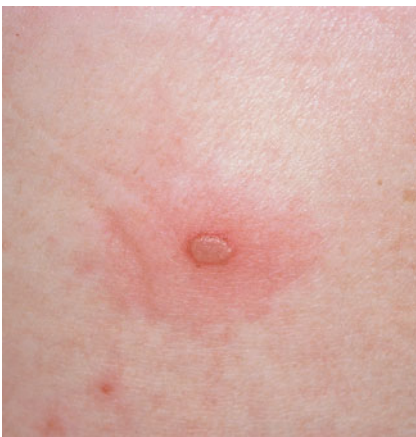▲ **Figure 27-1.** Measles. Erythematous macules and papules with symmetrical, diffuse distribution (Reproduced with permission from Wolff K, Johnson RA. *Color Atlas & Synopsis of Clinical Dermatology*. 5th ed. New York: McGraw-Hill; 2005:788).



▲ **Figure 27-3.** Mononucleosis. Diffuse erythematous morbilliform rash on trunk and arms.

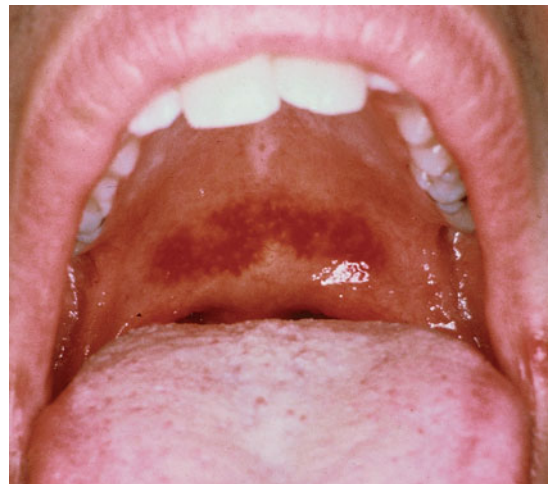

A

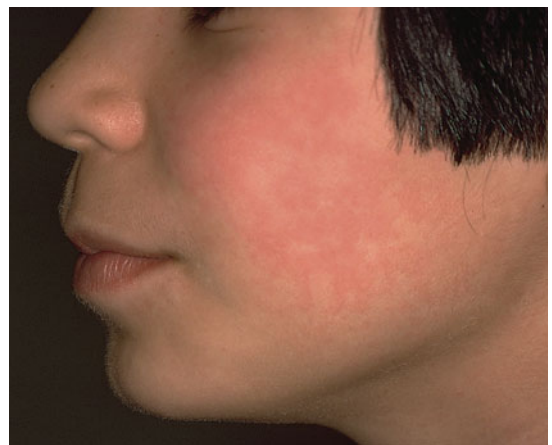

B

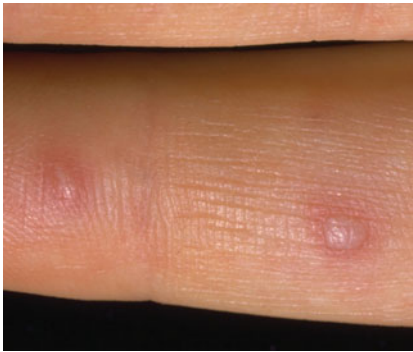
▲ **Figure 27-2.** (A, B) Varicella (chicken pox). **A:** Scattered diffusely distributed vesicles on an erythematous base. **B:** Vesicle on pink base “dew on a rose petal.”



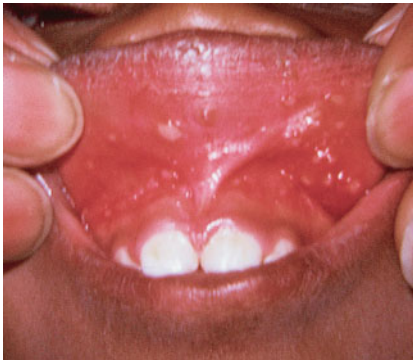▲ **Figure 27-4.** Mononucleosis. Petechiae on palate.



▲ **Figure 27-5.** Parvovirus B19 infection (fifth's disease). Red plaque on cheek.

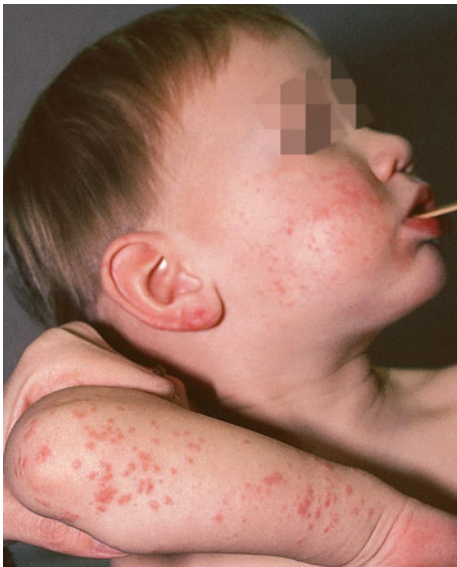

A

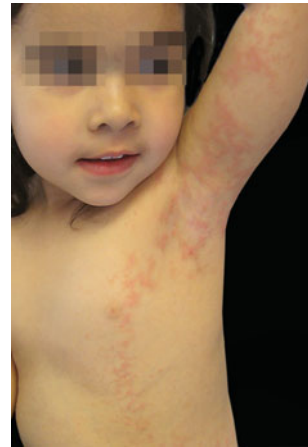

B

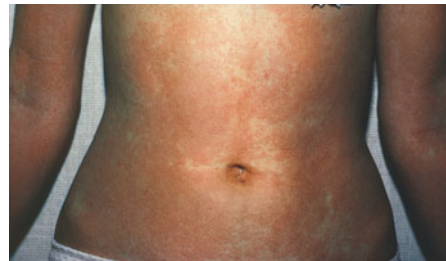▲ **Figure 27-6.** (A, B) Hand, foot, and mouth disease. Vesicles on an erythematous base on fingers and oral mucosa.



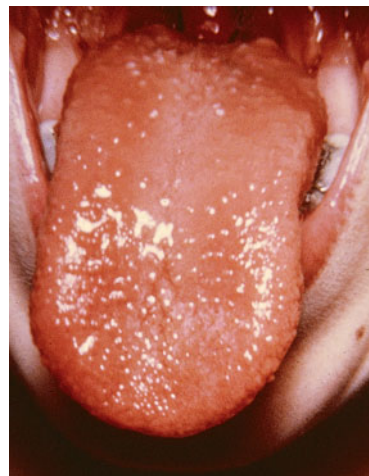▲ **Figure 27-7.** Gianotti-Crosti syndrome. Pink “juicy” papules on cheek and acral arm.



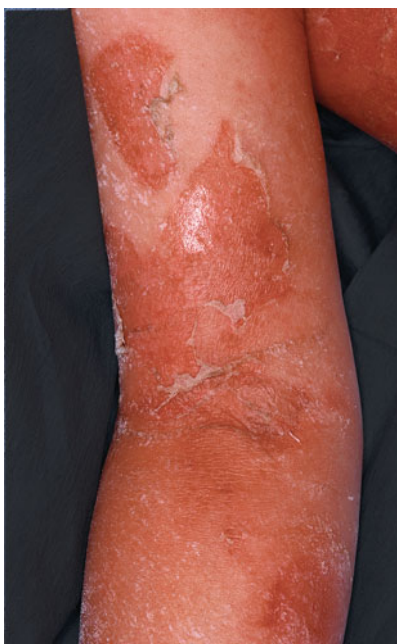▲ **Figure 27-8.** Unilateral laterothoracic exanthema. Erythematous, urticarial-like plaques along the lateral chest and flexural arm.



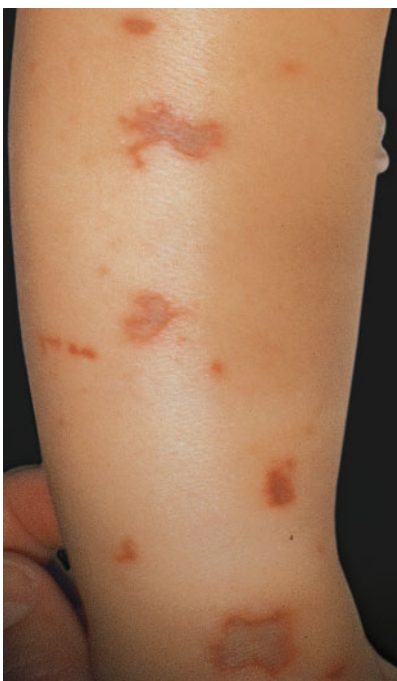▲ **Figure 27-9.** Nonspecific viral exanthem. Erythematous macules in diffuse distribution on trunk and arms in a patient with upper respiratory symptoms.



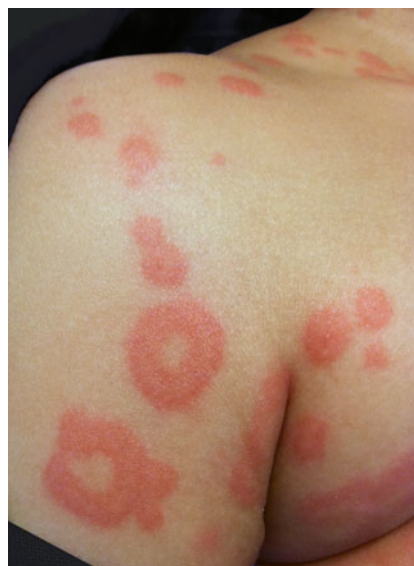▲ **Figure 27-10.** Scarlet fever. “Strawberry tongue” enanthem: bright red tongue with enlarged papillae and white patches.



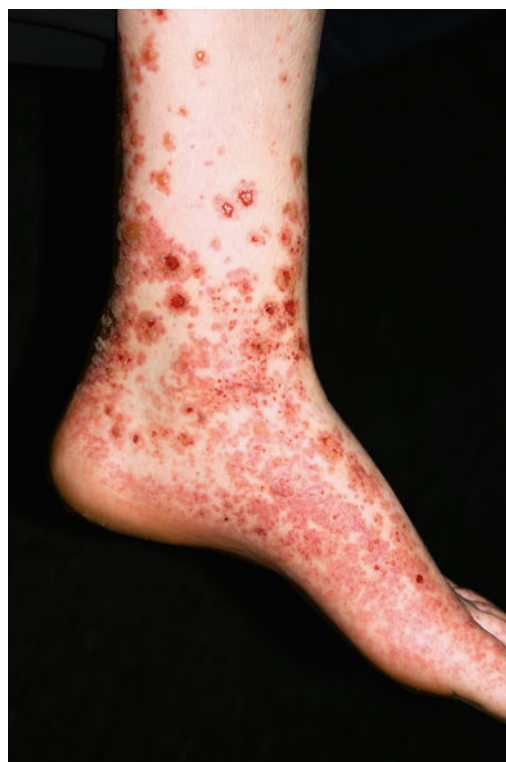▲ **Figure 27-11.** Staphylococcal scalded skin syndrome. Diffuse erythema and sloughing of the epidermis leaving areas of denuded skin on the arm.



▲ **Figure 27-12.** Meningococemia. Erythematous irregularly shaped plaques with a gray center on a child's leg.



▲ **Figure 27-13.** Urticaria multiforme. Annular erythematous wheals on a child's shoulder, arm and trunk.



▲ **Figure 27-14.** Henoch-Schonlein purpura. Confluent, nonblanchable purpuric papules.

REFERENCES

- Pickering LK, Baker CJ, Freed GL, et al. Immunization programs for infants, children, adolescents, and adults: clinical practice guidelines by the Infectious Diseases Society of America. *Clin Infect Dis*. 2009;49(6):817–840. PMID: 19659433.
- Centers for Disease Control and Prevention. Measles—United States, 2011. *MMWR Morb Mortal Wkly Rep*. 2012;61: 253–257. PMID: 22513526.
- American Academy of Pediatrics. Measles. In: Pickering LK, ed. *Red Book: 2003 Report of the Committee on Infectious Diseases*. 26th ed. Elk Grove Village: American Academy of Pediatrics; 2003:419–429.
- Gold E. Almost extinct diseases: measles, mumps, rubella and pertussis. *Pediatr Rev*. 1996;17:120–127. PMID: 8637818.
- Mason WH. Measles. *Adolesc Med*. 1995;6:1–14. PMID: 1035829.
- Mancini AJ. Childhood exanthems: a primer and update for the dermatologist. *Adv Dermatol*. 2000;16:3–38. PMID: 11094623.
- Cherry JD. Contemporary infectious exanthems. *Clin Infect Dis*. 1993;16:199–207. PMID: 8443297.
- Gable EK, Liu G, Morrell DS. Pediatric exanthems. *Prim Care*. 2000;27(2):353–368. PMID: 10815048.
- Rosa C. Rubella and rubeola. *Semin Perinatol*. 1998;22(4): 318–322. PMID: 9738996.
- Naides SJ. Infection with parvovirus B19. *Curr Infect Dis Rep*. 1999;1:273–278. PMID: 11095799.
- Dieck D, Schild L, Hansmann M, Eis-Hubinger AM. Prenatal diagnosis of congenital parvovirus B19 infection: value of serological and PCR techniques in maternal and fetal serum. *Prenat Diagn*. 1999;19:1119–1123. PMID: 10590428.
- Hofmann B, Schuppe HC, Adams O, et al. Gianotti–Crosti syndrome associated with Epstein–Barr virus infection. *Pediatr Dermatol*. 1997;14(4):273–277. PMID: 9263306.
- American Academy of Pediatrics. Toxic shock syndrome. In: Pickering LK, Baker CJ, Long SS, McMillan JA, eds. *Red Book: 2006 Report of the Committee on Infectious Diseases*. 27th ed. Elk Grove Village, IL: American Academy of Pediatrics; 2006:660–665.
- Wolf JE, Rabinowitz LG. Streptococcal toxic shock-like syndrome. *Arch Dermatol*. 1995;131(1):73–77. PMID: 7826100.
- Thompson MJ, Ninis N, Perera R, et al. Clinical recognition of meningococcal disease in children and adolescents. *Lancet*. 2006;367(9508):397–403. PMID: 16458763.
- Shah KN, Honig PJ, Yan AC. “Urticaria multiforme”: a case series and review of acute annular urticarial hypersensitivity syndromes in children. *Pediatrics*. 2007;119(5):e1177–e1183. Review. PMID: 17470565.
- Pinna GS, Kafetzis DA, Tselkas OI, Skevaki CL. Kawasaki disease: an overview. *Curr Opin Infect Dis*. 2008;21(3): 263–270. PMID: 18448971.
- Longo DL, Fauci AS, Kasper DL, Hauser SL, Jameson JL, Loscalzo J. *Harrison's Principles of Internal Medicine*. 18th ed. New York: McGraw-Hill.

Hospital-Acquired Rashes

Barbara D. Wilson

28

Introduction to Chapter / 253
Approach to Diagnosis / 254

References / 258

INTRODUCTION TO CHAPTER

Hospitalized patients frequently have cutaneous problems that the attending physician will need to assess. These problems can range from those unrelated to the hospitalization and inconsequential at that time, to those that could be indicative of serious underlying systemic disease or even imminent life-threatening disorders of the skin. The challenge to correctly diagnose and treat a skin problem in a hospitalized patient is influenced by the lack of both access to timely dermatological consultation in some settings¹ and dermatologic training received by many physicians. It is well known that referring physicians' dermatologic diagnoses and those of dermatologic consultants concur in less than half of the inpatient episodes.²⁻⁵ Implicit in this observation is the risk that many patients could then receive improper, costly, or even harmful treatments or no treatment at all. In a study of inpatient consults by Mancusi and Festa Neto in 2010, the primary doctor endorsed by questionnaire the idea that the consultation was very relevant to the hospitalization or addressed a serious dermatological problem in 31% of cases, and in another 58%, the consultation facilitated diagnosis of skin diseases that were important even if unrelated to the admitting diagnosis.³

For this reason, it is important to be familiar with both common and serious dermatoses seen in the hospital setting and to consider what unique and special risks for dermatological disease that the hospital setting might create.

The kinds of problems seen in a hospital setting and proportions of these problems are often dependent on the nature of the hospital itself (pediatric, academic, tertiary,

and community) and the population that it serves as well as the specialty origin of the consultation (ie, internal medicine vs neurology).³⁻⁶ However, across many studies, there is a tendency to see certain problems frequently, including dermatitis (atopic, seborrheic, and contact), psoriasis, infectious problems (bacterial, fungal, and viral, especially candidiasis and cellulitis), and many drug reactions.¹⁻⁶

The hospital setting can predispose a patient to many dermatological problems. It has been estimated in one study that approximately 36% of dermatological problems in hospitalized patients occurred after the admission.³ The hospitalized patient is especially vulnerable to infections for many reasons including exposure to prevalent and sometimes resistant hospital organisms, lowered or altered immunity due to underlying disease or treatment (eg, chemotherapy), and the loss of skin integrity caused by trauma, surgeries, and intravenous lines creating portals of entry. Searching for and discerning a portal of entry in the skin is especially important in diagnosing skin infections. In addition, some infections are caused by overgrowth, not contagion, resulting from ecologic changes (eg, candida after antibiotics), moist environments (eg, tinea in groin in bedridden patients), or by autoactivation (eg, herpes simplex virus (HSV) in immunosuppressed).

In addition to the exposure to potentially infectious agents, the hospital setting also provides a challenge to regular and careful cleansing/bathing of the skin, which exacerbates many skin problems. Many potential products that can cause allergic or irritant contact dermatitis are also found in the hospital setting including soaps, cleansers, disinfectants, topical therapies, bedclothes, adhesives, and bandages. Other factors that might contribute to

hospital-acquired skin problems include the immobility of patients resulting in pressure on the skin, and nutritional impairment due to prolonged illnesses.

Finally, it is very important to remember that drug reactions are common in the hospital setting, with the number of medications that hospitalized patients receive contributing directly to this trend. Adverse drug reactions in the skin of hospitalized patients can be the result of many mechanisms. Some dermatologic reactions might be expected after exposure to a certain drug (eg, mucositis after chemotherapy) while other reactions might represent toxicity, overdose, or hypersensitivity. Hypersensitivity can be seen with many patterns. The most common by far are exanthems.⁷ Viral exanthems are not expected to be more frequently acquired in the hospital setting, but are always a challenge to differentiate from drug exanthems. In the outpatient setting, an exanthem might be more likely to be due to viral infection in the pediatric population and due to a drug reaction in the adult population, but in the hospital setting, drug reactions are more common in all settings.

APPROACH TO DIAGNOSIS

Important factors to consider in evaluating the patient's skin problem in the hospital setting include the previous known dermatologic history, underlying systemic diagnoses, systemic medications taken over the past 3 weeks including over the counter medications, as well as the topical products that the patient has used recently. It is also important to know immediately if the patient is experiencing rapid change in their skin condition or evidence of acute skin failure. Skin pain, intense pruritus, fever, skin blisters, mucosal lesions, purpura, target lesions, or other specific signs of toxicity may indicate a serious condition.

A dermatologic problem seen in the hospital setting can certainly be that of a preexisting skin problem exacerbated by the current illness or treatment for which the

hospitalization is occurring. Studies have shown that common rashes in hospitals include preexisting atopic dermatitis, seborrheic dermatitis, psoriasis, and stasis dermatitis. It is therefore important to inquire about preexisting diagnoses of skin disease and to be familiar with reasons that these diseases might flare. Examples might include a flare of atopic dermatitis due to secondary bacterial infection, a flare of seborrheic dermatitis due to inability to bathe, a flare of bullous pemphigoid due to the withdrawal of systemic steroids, or a flare of stasis dermatitis due to immobility and increased edema of the lower extremities. In the most extreme settings, the preexisting underlying dermatitis might evolve into erythroderma, defined as involvement of >90% of the body surface area.

Contact dermatitis is common in hospital settings but is rarely the cause of the hospitalization. Most contact dermatitis in the hospital is probably irritant and not allergic contact caused by exposure to strong cleansers for skin, disinfectants, and adhesives. One important opportunity for misdiagnosis due to "hidden" contact dermatitis is the "red leg." The "red leg," assumed to be cellulitis, can really be allergic contact dermatitis due to application of topical products. When diagnosing a "red leg," the physician must look for evidence of stasis dermatitis or even acute venous thrombosis as well as evidence for allergic contact dermatitis. The clinician needs to be aware of what products the patient has been using in this setting to avoid the possibility of inappropriate antibiotic use for presumed cellulitis.

Tables of Differential Diagnosis

Other common dermatologic disorders seen in the hospital as well as several high-risk problems seen less commonly are listed in Tables 28-1 to 28-3. Table 28-1 lists common inflammatory cutaneous diseases, Table 28-2 lists common infections, and Table 28-3 lists uncommon cutaneous diseases with moderate to high morbidity.

Table 28-1. Common inflammatory dermatoses in the hospital.

Disease (in Textbook)	Epidemiology	History	Examination	Laboratory
Drug rash (Chapters 14 and 23)	All ages and races. Relative risk factors: female, older age, multiple medications, immunosuppression (HIV), and some concurrent viral infections. Especially common with sulfonamides, penicillins, cephalosporins, aromatic anticonvulsants, and allopurinol. Drug eruptions are overall about 10% of all hospital consults; morbilliform are most common form	Onset 4-14 days after drug initiation most common. Variable pruritus. More serious reactions such as DRESS and SJS/TEN present with high fever, skin tenderness, severe edema, extensive purpura, targets, and mucosal lesions	Morbiliiform (like measles): pink, red or dull red macules, and papules with confluence especially on trunk/ extremities (Figure 14-6). Dependant areas often more affected. May have polymorphous features (some areas urticarial)	Skin biopsy generally not helpful. CBC can help differentiate viral syndrome. More serious reactions may have abnormal chemistry profile and liver function tests

(continued)

Table 28-1. Common inflammatory dermatoses in the hospital (Continued).

Disease (in Textbook)	Epidemiology	History	Examination	Laboratory
Urticaria (Chapter 14)	All ages, races, and both sexes. Underlying causes include URI, drug ingestions, foods, and systemic diseases including infectious, hematologic, vasculitic, and immunologic diseases. In hospital setting, drugs are the most common cause, but systemic diseases need to be considered	Abrupt appearance of transient pruritic edematous wheals. May have associated oral mucosal swelling (angioedema)	Edematous pink or red wheals of all sizes and shapes anywhere on body and transient over 24 h (Figure 14-2). May have associated angioedema (soft tissue swelling of the face) (Figure 14-3). Fever, target lesions, persistence of wheals, bruising, purpura, and toxicity indicate need to look for causes of complex urticaria ⁸	Mild eosinophilia. Urticaria due to systemic disease have cytopenias, profound eosinophilia, hypocomplementemia, evidence of renal, or liver problems
Contact dermatitis (CD) (Chapter 8)	All ages, races, and both sexes. Allergic CD (eg, metals, adhesives, fragrances, preservatives, formaldehyde, and topical antibiotics) probably less common in hospital setting than irritant CD (eg, strong soaps, disinfectants, surgical preps, bedclothes, and paper products)	Irritant CD is immediate if contact irritant is strong and can have burning or pain. Cumulative irritancy with weaker irritants more commonly subacute. Allergic CD is classically delayed 1-2 days after exposure to allergen and pruritic	Well-demarcated erythematous dermatitis in areas of exposure. Irritant CD can be eczematous and scaling when subacute (Figures 8-2 and 8-3) and sometimes erosive when acute. Allergic CD can have vesicles or bullae if severe (Figure 8-5)	Skin biopsy generally not indicated. Patch tests of specific allergens can later elucidate cause if allergy is suspected
Seborrheic dermatitis (Chapter 9)	All ages, races, and both sexes; common in infants and postpubertal adults; especially common in some neurological diseases, in those on chronic steroids and HIV	Acute exacerbations of chronic dermatitis with variable pruritus. Often worse when bathing is diminished	Greasy, loose scale overlying pink dermatitis in seborrheic distribution on scalp, face, ears, intertriginous areas, chest, and upper back (Figure 9-8)	None helpful
Atopic dermatitis (Chapter 9)	All ages, races, and both sexes; atopic diathesis, family history of atopy	Chronic pruritic eczematous dermatitis with exacerbations	Infantile-extensor and face (Figure 8-7). Child and adult-flexural and possibly widespread (Figure 8-8). Poorly margined, pink eczematous plaques often with lichenification and excoriations ⁹	Possible elevated serum IgE and eosinophilia

CBC, complete blood count; DRESS, drug rash with eosinophilia and systemic symptoms; HIV, human immunodeficiency virus; IgE, immunoglobulin E; SJS/TEN, Stevens Johnson syndrome/toxic epidermal necrolysis; URI, upper respiratory infection.

Table 28-2. Common infections in the hospital.

Disease (in Textbook)	Epidemiology	History	Examination	Laboratory
Viral exanthem (Chapter 27)	All ages and both sexes. More common in children. Less common than drug exanthems in hospital setting. Exposure in community and autoactivation are important factors	Abrupt onset with gradual worsening. Variable pruritus. Dependent on underlying virus but typically associated fever, cough, sore throat, myalgias, headache, lymphadenopathy, conjunctivitis, nausea, vomiting, and diarrhea	Maculopapular, morbilliform, urticarial, and vesicular lesions. Often mucosal lesions. Consider: HIV, EBV, CMV, HHV-6, HHV-7, rubella, rubeola, enteroviruses, adenoviruses, parvovirus B-19, and varicella. (All figures in Chapter 27.) Varies depending on specific causative virus	CBC with atypical lymphs, lymphopenia or lymphocytosis; LFTs, viral specific antibody tests; nasopharyngeal, throat, stool washings, and swabs
Herpes simplex (HSV) Herpes zoster (VZV) (Chapter 11)	All ages, races, and both sexes. Worldwide. VZV more common in >age 50. Severe, recurrent HSV and VZV in immunosuppressed patients	Tingling, pain, and burning sensation may precede rash. VZV is dermatomal with possible dissemination. Rare cutaneous dissemination of HSV in atopics	Grouped vesicles and crusting on red base (Figure 11-1). HSV usually recurrent in the same place. VZV is dermatomal (Figure 11-3). Severe, widespread, ulcerating disease in immunosuppressed	Tzanck smear of lesion. DFA, PCR, and viral culture
Cellulitis (Chapter 12)	All ages, races, and both sexes. More common with trauma, portals, and broken skin	Abrupt onset of tenderness and pain with variable chills, malaise, and fever	Sudden appearance of tender, red, warm, edematous ill-defined or sharply demarcated advancing erythema, generally unilateral (Figure 12-3) ¹⁰	CBC with leukocytosis and left shift. Cultures from definite portal may be helpful. Biopsy for tissue cultures if unresponsive to treatment or immunosuppressed
Pyoderma (abscess) (Chapter 12)	All ages, races, and both sexes. More common with trauma, portals, and broken skin	Acute or subacute onset of variably tender or pruritic areas of skin	Pyoderma with weeping, eroded, crusted, purulent lesions with surrounding erythema (Figure 12-1). Abscesses with tender fluctuant red nodules with or without surrounding erythema (Figure 12-2)	Skin culture after incision for abscess
Candidiasis (Chapter 10)	All ages, races, and both sexes. Risk factors: broad-spectrum antibiotics, diabetes, hyperhidrosis, occlusion, and corticosteroid use	Acute or subacute. Pruritus, tenderness, and burning	Bright red moist or erosive dermatitis, poorly margined with satellite and lesional pustules in intertriginous areas (Figure 10-16), genitals, scrotum, and areas of occlusion (Figure 10-17). Mucous membranes with white removable exudates on red patches (Figure 38-22)	KOH with budding yeast and pseudohyphae. Cultures recommended if unresponsive to treatment

(continued)

Table 28-2. Common infections in the hospital (Continued).

Disease (in Textbook)	Epidemiology	History	Examination	Laboratory
Fungal infection (Chapter 10)	All races and both sexes. <i>T. capitis</i> prepubertal, all other forms commonly postpubertal. M > F for <i>T. cruris</i> and <i>T. pedis</i> . Severity and extent can be worse in immunosuppressed. Relative risk factors: obesity, hyperhidrosis, age, and occlusion. Tinea is an important cause of broken skin and portals for bacterial infection (cellulitis)	Generally subacute or chronic with exacerbations	Generally dry and scaling. On body (Figure 10-4) and groin (Figure 10-7) with annular configuration and central clearing/active border. Spares scrotum. On feet, possibly moccasin (Figure 10-10) or interdigital distribution (Figure 10-9). Rarer inflammatory with vesicopustules (Figure 10-11). Nails with powdery scale and subungual debris (Figure 10-12)	KOH with branching hyphal structures. PAS stain of nail or skin will demonstrate the same. Fungal culture to identify species

CBC, complete blood count; CMV, cytomegalovirus; DFA, direct fluorescent antibody; F, female; HHV, human herpes virus; HIV, Human immunodeficiency virus; KOH, potassium hydroxide; LFTs, liver function tests; M, male; PAS, periodic acid-Schiff; PCR, polymerase chain reaction; T, tinea.

Table 28-3. Uncommon dermatoses in the hospital.

Disease (in Textbook)	Epidemiology	History	Examination	Laboratory
Vasculitis (Chapter 25)	All ages, races, and both sexes. More common in adults with associated underlying diseases (rheumatologic, hematologic, and infectious) and also after use of certain drugs	Generally painful or burning lesions on the skin with accompanying symptoms of underlying disease	Range from nonblanching palpable purpura on the lower extremities (Figure 25-4) and dependent areas as to purpuric nodules and ulcers corresponding in size to that of the involved underlying vessel	Directed at diagnosing underlying disease and defining which organ systems may be involved. Biopsy of appropriate site can show pathologic evidence of the type of vessel involved and type of inflammation seen
Erythroderma (Chapter 9)	All ages, races, and both sexes. Most common in adults. Idiopathic type most common in adult males. Other causes: underlying severe dermatitis, Sezary syndrome, drug reaction, and pityriasis rubra pilaris	Usually acute or subacute over days or weeks. Often with preexisting milder underlying dermatologic disease (atopic, psoriatic, and seborrheic). Medications added in past weeks	Extensive pink inflamed plaques or dull erythema with and without scale covering 90% of body surface area. May have appearance of underlying skin disease	Biopsy may be diagnostic but often not in evolving disease. If chronic erythroderma, concern for hypoalbuminemia, anemia, and electrolyte disturbances. CBC and flow cytometry for cutaneous T-cell lymphoma/leukemia

(continued)

Table 28-3. Uncommon dermatoses in the hospital (Continued).

Disease (in Textbook)	Epidemiology	History	Examination	Laboratory
DRESS syndrome (drug reaction with eosinophilia and systemic symptoms) (Chapter 14)	All ages and races. Women > men. More common in adults. More common in immunosuppressed (HIV) and also after the use of certain drugs including sulfonamides, penicillins, aromatic anticonvulsants, and allopurinol	Onset of variable exanthem along with fever and other organ dysfunction. Significant mortality especially if not recognized	Exanthem is variable. Can be morbilliform and minimal, but purpura, targets, and blisters are also described. Often extensive edema of face (Figure 14-7) and extremities and lymphadenopathy	Eosinophilia and dysfunction of other organs including kidney, liver, lung, GI tract, or other. Imperative screening for organ dysfunction if suspected
Pyoderma gangrenosum (Chapter 29)	All ages, races, and both sexes. More common in adults and those with underlying predisposing disease (inflammatory bowel disease, hematologic and rheumatologic diseases). Recent surgery or trauma to site	Rapid evolution of painful necrotic or purulent ulcer that grows quickly. Initial lesion often very painful pustule. Variable fever	Purulent, necrotic deep ulcer with undermined dusky border. Most common on lower legs (Figure 29-2), but also abdomen, peristomal, and site of surgery	Biopsy is confirmatory, but not diagnostic. Need to consider infection, vasculitis, and trauma

Erythema multiforme, Stevens-Johnson syndrome, and toxic epidermal necrolysis (see Tables 23-1 to 23-3 and Figures 23-1 to 23-9).¹¹ CBC, Complete blood count; GI, gastrointestinal; HIV, human immunodeficiency virus.

The online learning center at www.LangeClinicalDermatology.com has clinical self-assessment questions for this chapter.

REFERENCES

- Hughey LC. Why perform inpatient consultations? [editorial] *Dermatol Ther.* 2011;24(2):149–150. PMID: 21410605.
- Falanga V, Schachner LA, Rae V, et al. Dermatologic consultations in the hospital setting. *Arch Dermatol.* 1994;130(8):1022–1025. PMID: 8053699.
- Mancusi S, Festa Neto C. Inpatient dermatological consultations at a university hospital. *Clinics.* 2010;65(9):851–855. PMID: 21049212.
- Ahmad K, Ramsay B. Analysis of inpatient dermatologic referrals: insight into the educational needs of trainee doctors. *Ir J Med Sci.* 2009;178(1):69–71. PMID: 19002549.
- Davila M, Christenson LJ, Sontheimer RD. Epidemiology and outcomes of dermatology inpatient consultations in a Midwestern U.S. university hospital. *Dermatol Online J.* 2010;16(2):12. PMID: 20178708.
- Penate Y, Guillermo N, Melwani P, Martel R, Borrego L. Dermatologists in hospital wards: an 8-year study of dermatology consultations. *Dermatology.* 2009;219(3):225–231. PMID: 19648729.
- Bigby M, Jick S, Jick H, Arndt K. Drug-induced cutaneous reactions: a report from the Boston Collaborative Drug Surveillance Program on 15,438 consecutive inpatients. *JAMA.* 1986;256(24):3358–3363. PMID: 2946876.
- Micheletti R, Rosenbach M. An approach to the hospitalized patient with urticaria and fever. *Dermatol Ther.* 2011;24:187–195. PMID: 21410614.
- Cathcart SD, Theos A. Inpatient management of atopic dermatitis. *Dermatol Ther.* 2011;24(2):249–255. PMID: 21410608.
- Swartz M. Cellulitis. *N Engl J Med.* 2004;350(9):904–912. PMID: 14985488.
- Hughey LC. Approach to the hospitalized patient with targetoid lesions. *Dermatol Ther.* 2011;24(2):196–206. PMID: 21410609.

Leg Ulcers

Neal Foman

29

Introduction to Chapter / 259
Venous Ulcers / 259
Arterial Ulcers / 262

Neuropathic Ulcers / 263
References / 264

INTRODUCTION TO CHAPTER

An understanding of the pathophysiology, diagnosis, and management of leg ulcers is very important to health care providers as these occur in a significant number of patients. Approximately 1% to 3% of the population, or up to 9 million people in the United States are affected.¹ The annual cost of leg ulcers is proposed to be \$8 to \$10 billion per year, with an estimated loss of 2 million workdays per year.² The majority of leg ulcers are seen in middle-aged to elderly patients, and there is a female:male predilection of 2:1. The three most common types of leg ulcers are venous, arterial, and neuropathic.

VENOUS ULCERS

Introduction

Ulcers caused by venous insufficiency are the most common type of leg ulcerations, accounting for 70% to 80%. They are sometimes called stasis ulcers. About 10% to 20% of leg ulcerations have a mixed venous and arterial etiology. Leg ulcers caused by chronic venous insufficiency lead to significant morbidity and can have a long-term negative impact on an individual's quality of life. Diagnosis can be difficult, and management is often expensive and labor-intensive.

Pathophysiology

Venous ulcers most commonly arise secondary to varicose veins or postphlebotic syndrome. They may also be seen in

patients with a history of a deep vein thrombosis (DVT), obesity, or previous leg injury or surgery. When a patient with normal venous return stands or walks, the calf muscle acts in concert with veins and associated valves to empty the venous system and reduce its pressure.³ Venous hypertension develops when the valves become incompetent. This leads to tissue hypoxia and ultimately to skin destruction and breakdown. In addition, wound healing processes are compromised and autolytic processes take action. The result is loss of the epidermis and dermis and the formation of an ulcer.

Clinical Presentation

History

Most commonly, patients complain of a heavy or swollen feeling in the affected leg. Pain ranges from mild with a superficial ulceration to severe with a deep ulceration. Patients may describe limitation of movement of the affected extremity, depending on the location of the ulcer. In addition, patients with venous stasis and dermatitis may have significant pruritus of the skin surrounding an ulcer.

Physical Examination

Most patients with venous ulceration have some degree of nonpitting or pitting edema. Varicosities may be visible, and there is often hyperpigmentation from hemosiderin deposition over the shin. Typically, venous ulcers occur over or proximal to the medial malleolus, but they may occur anywhere below the knee. They can be single or multiple,

small or large, shallow or deep. They are usually well margined with sloped borders, but can present with irregular shapes (Figure 29-1). Often, there is fibrinoid material and/or granulation tissue at the base. The surrounding skin may have an inflamed, eczematous appearance. These ulcers can sometimes have copious drainage.

► Laboratory Findings

There are no specific laboratory findings that point toward a diagnosis of venous ulceration. However, a complete blood count (CBC), erythrocyte sedimentation count (ESR), and blood glucose can help to diagnose an underlying hematologic, inflammatory, or diabetic condition. A culture will likely yield mixed flora, and may not be relevant unless the wound appears clinically infected. A venous Doppler ultrasound can help to locate venous occlusion or incompetent perforating veins.

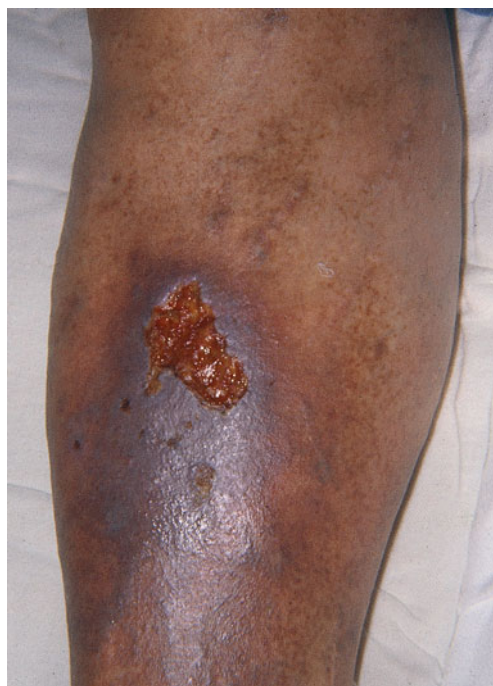Diagnosis and Differential Diagnosis

The key diagnostic findings of venous ulcers are well-circumscribed ulcerations usually over the shin or medial malleolus, on a backdrop of hyperpigmentation, varicosities, and lower extremity edema. Pedal pulses are usually present. Fibrinoid material or granulation tissue is often observed at the base of the ulcer.

See Table 29-1 for the differential diagnosis of leg ulcers.

Management

One must always know the cause of an ulcer before designing a treatment plan. In treating venous ulcers, the primary goal is to reverse venous hypertension so that there is an environment amenable to wound healing.⁴ The most effective way to accomplish this is with compression, the gold standard for the treatment of venous leg ulcers. Compression reverses venous hypertension, has positive effects on microcirculation, reduces deep venous reflux, reduces lower leg edema, and allows for improved oxygenation of the skin. There are two categories of compression products available: *inelastic compression products*, which are used for reduction of edema and healing of ulcers, and *elastic compression products*, which are used for maintenance to prevent ulcer recurrence. The most widely used inelastic products are Unna boots or Profore boots. These are occlusive wraps that are applied as an ace wrap would be applied in the office and removed 1 week later. They may also be applied at the patient's residence by a trained home health professional. An important companion to the use of these leg wraps is frequent elevation of the legs. Elastic compression is achieved with products such as TEDS or Jobst stockings, which can be worn on a regular basis for maintenance, once a venous ulcer has healed. Compression should always be a component of treating a venous ulcer, but **one must rule out the possibility of arterial insufficiency** prior to applying a compressive dressing to a patient.



▲ **Figure 29-1.** Venous ulcer. Sharply margined ulcer with irregular border in area of stasis dermatitis.

In addition to compression, the treatment of the wound itself is very important. The ulcer bed must be prepared so as to allow for optimum healing.⁵ Tissue removal or debridement may be necessary, as the fibrinoid material present in some wounds interferes with healing. This may be accomplished surgically or mechanically with scissors, a curette, or a scalpel, and may require local anesthesia. Enzymatic or proteolytic agents (eg, Santyl, Panafil, or Accuzyme) can also be used to more slowly debride a wound when necessary.

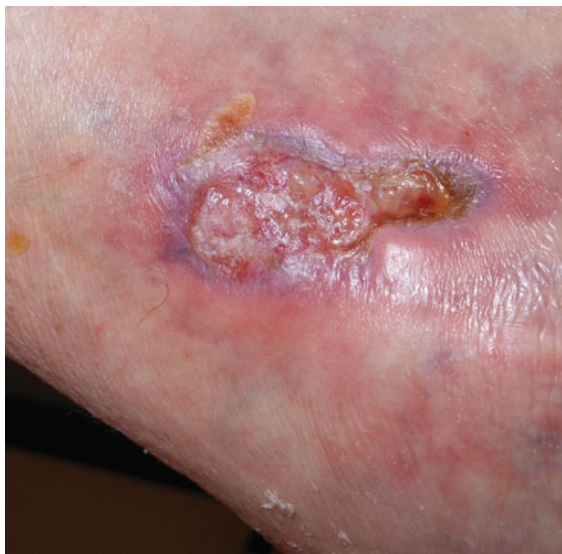The moisture balance in an ulcer can have a significant effect on healing. In particular, wounds heal more quickly in a moist environment. This is accomplished by using dressings that absorb excess fluid in a very exudative wound, or that retain fluid in an otherwise dry wound.⁶ When there is significant exudate, some appropriate absorptive dressing choices are Kerlix, gauze sponges, surgical pads, hydrophilic foam dressings (eg, COPA), or hydrocellular polyurethane dressings (eg, Allevyn). When a wound is dry, some appropriate dressing choices are Telfa, Vaseline petroleum gauze, or a nonadhering oil emulsion dressing (eg, Curity).

An ulcer often needs help with reepithelialization. There are several products that aid in providing contact between the wound edges so that they are stimulated to grow back together. Hydrocolloid dressings (eg, Duoderm or Restore) provide this function. Extracellular matrix

Table 29-1. Differential diagnosis of leg ulcers.

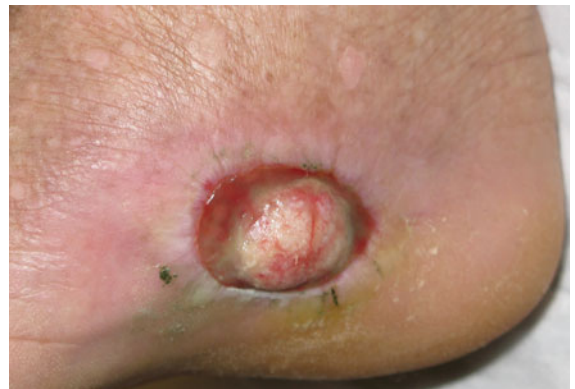Type of Ulcer	Risk Factors	History and Physical	Notes
Venous	Deep venous thrombosis (DVT), varicose veins, previous lower extremity surgery or injury, and obesity	Lower extremity edema, varicosities, hyperpigmentation, and dermatitis, ulcer over shin or medial malleolus. Pulses usually palpable	Compression is the key to treatment
Arterial	Peripheral arterial disease, smoking, hyperlipidemia, hypertension, and diabetes	Intermittent claudication, painful ulcer, shiny skin, eschar may be present at base of ulcer, ulcer over distal lower extremities. Pulses usually not palpable	Low threshold for referral to vascular surgery. Do not use compression
Neuropathic	Diabetes, spinal cord injury or disease, alcohol abuse, and leprosy	Ulcer over pressure points of plantar foot, surrounded by callus, foot deformities, insensate lower extremities, deep	Prevention is critical as a significant number of these ulcers can lead to amputation
Inflammatory	Vasculitis and systemic lupus erythematosus	May have signs and symptoms of systemic inflammatory disease	Systemic workup is appropriate
Infectious	Diabetes and obesity	Significant exudate, foul odor, pain, and warmth of surrounding skin	Culture prior to starting treatment with antibiotics
Pyoderma gangrenosum	Inflammatory bowel disease, arthritis, and myeloproliferative disorder	Irregularly shaped ulcer with undermined edges (Figure 29-2)	Diagnosis of exclusion
Malignancy	History of ionizing radiation	Nonhealing ulcer (Figure 29-3)	Must be considered if standard therapy fails

dressings (eg, Oasis, or Matristem) create a scaffold over which growth factors and keratinocytes can migrate, thus bringing a wound together. Biologic agents (eg, Apligraf or Dermagraft) provide the building blocks for new skin to regenerate.



▲ **Figure 29-2.** Pyoderma gangrenosum. Ulcer with violaceous border and undermined edges.

One last item to be addressed in the treatment of a venous ulcer is the possibility of infection. Most ulcers are colonized with bacteria, but this is not often to the level of actual infection. These ulcers do not require antibiotic treatment. Certainly, if there are clinical signs of infection such as thick odorous exudate, surrounding erythema, or increasing pain, one should consider the use of an oral antibiotic after a culture has been taken. If a patient has stasis dermatitis adjacent to an ulcer, this



▲ **Figure 29-3.** Squamous cell carcinoma. Presenting as a foot ulcer.

should be treated with a midpotency topical steroid, such as triamcinolone ointment, 0.1%. The latter will help to maintain the integrity of the skin, thus decreasing the risk of cellulitis.

Ongoing treatment may be necessary for many months before a venous ulcer will heal. Recurrence is common, seen in 54% to 78% of all venous ulcers.⁷

Indications for Consultation

If the underlying etiology of a leg ulcer cannot be determined, a specialist such as a vascular surgeon or a dermatologist should be consulted. If an ulcer is not healing despite appropriate treatment, referral to a wound care clinic should be considered. Also consider referral if the necessary management products are not available at the patient's primary clinic.

ARTERIAL ULCERS

Introduction

About 6% to 10% of leg ulcers are found in the setting of peripheral arterial disease, and are usually referred to as arterial or ischemic ulcers. Some ulcers have a mixed venous–arterial component. It is very important to determine the underlying etiology so that the appropriate management plan can be followed.

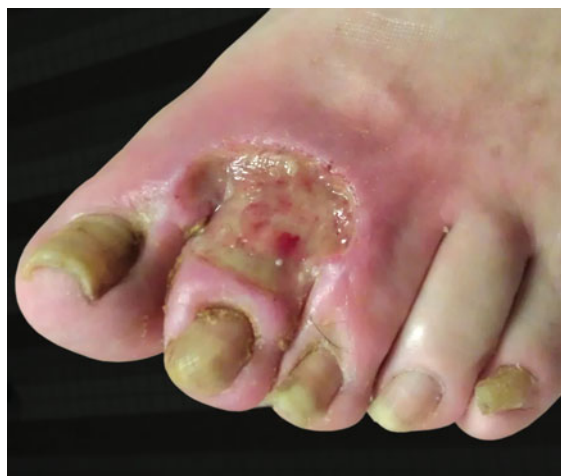Pathophysiology

The major risk factors for arterial ulcers are peripheral arterial disease, cigarette smoking, and diabetes. Other factors that contribute to the risk are hyperlipidemia and hypertension. In contrast to venous ulcers, arterial ulcers are seen more commonly in men. The underlying etiology in most cases is a decrease in or complete obstruction to arterial blood flow in the lower extremities. This is often the result of narrowing of the vessel lumen by an atherosclerotic plaque. The compromised blood flow leads to tissue ischemia and necrosis, and ultimately a skin ulceration forms.

Clinical Presentation

History

The most common complaint of a patient with an arterial ulcer is intermittent claudication. The patient experiences pain around the calf muscles during exercise early in the disease and at rest in late disease. The pain tends to be relieved when the patient places the leg in a dependent position.⁸ In general, arterial leg ulcers are significantly more painful than venous ulcers. The patient may report that their feet are usually cold, and they may notice that their feet and legs become pale with elevation.



▲ **Figure 29-4.** Arterial ulcer. Round sharply defined edges.

Physical Examination

Arterial ulcers present in distal locations, often over bony prominences such as the toes. They tend to have a round, punched-out appearance with sharp edges (Figure 29-4). The base of the ulcer is often dry and may be covered with necrotic debris, presenting as an eschar. These ulcers are sometimes so deep that bone or tendon might be visible. Perhaps the most important clinical feature in making a diagnosis of an arterial ulcer is the absence of pedal pulses. The skin on the lower legs of these patients is often shiny and atrophic appearing with little or no hair.

Laboratory Findings

It is very important to measure the ankle-brachial index (ABI) in a patient who is suspected of having arterial insufficiency. This is the ratio of the ankle systolic pressure of the affected limb to the higher of the brachial systolic pressures measured in each arm. An ABI <0.8 indicates occlusive arterial disease.⁹ A Duplex ultrasound can also be helpful to identify arterial occlusion or atherosclerotic disease. As with venous ulcers, a CBC, ESR, and blood glucose can help to diagnose an underlying hematologic, inflammatory, or diabetic condition. A culture will likely yield mixed flora, and may not be relevant unless the wound appears clinically infected.

Diagnosis and Differential Diagnosis

The key diagnostic findings of arterial ulcers are punched-out appearing, well-circumscribed, and sometimes quite deep ulcerations, usually present in distal locations over bony prominences such as the toes. Pedal pulses tend to be absent. The base of the ulcer tends to be dry and might

appear necrotic. The surrounding skin is often shiny and hairless.

See Table 29-1 for the differential diagnosis of leg ulcers.

Management

If an arterial etiology is suspected, compression should **not** be part of the treatment plan as this can lead to ischemia and necrosis of tissue.

Therapy of arterial ulcers should be targeted at reestablishing adequate arterial blood supply. One should have a low threshold for referring the patient to vascular surgery for evaluation. In addition, the patient should be encouraged to stop smoking, eat a low fat diet, and gain better control of their blood pressure and blood sugar. Antiplatelet medications such as aspirin and clopidogrel (Plavix) can be helpful in preventing ischemic events.

Pain control is another important element of the care of arterial ulcers. This may include systemic medication in addition to good local wound care. If an arterial ulcer is exudative or there is surrounding erythema, one should consider a systemic antibiotic after culture.

Indications for Consultation

Most patients with arterial ulcers should be evaluated by and co-managed with vascular surgery as surgical intervention might be a necessary part of their treatment.

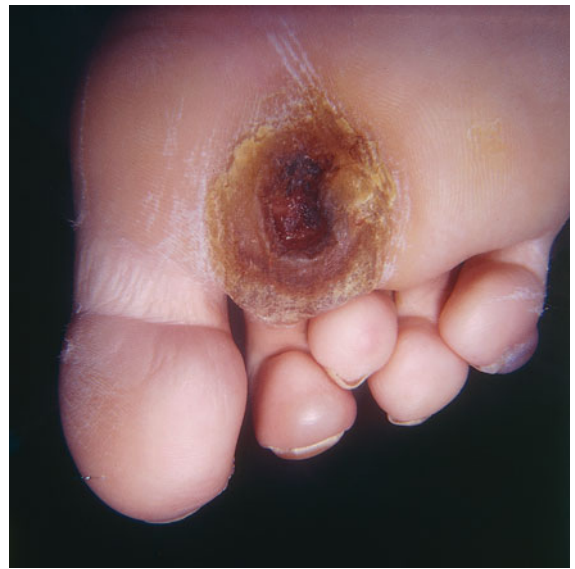NEUROPATHIC ULCERS

Introduction

Ulcerations secondary to peripheral neuropathy account for up to 10% of all leg ulcers. Some patients have both an ischemic and a neuropathic component to their ulcers. The most common cause of neuropathic foot ulcers in the United States is diabetes. Approximately 20% of those with diabetes (3 million people) will develop a foot ulcer in their lifetime.¹⁰ Unfortunately, up to 25% of these patients will eventually require an amputation.

Pathophysiology

The vast majority of diabetic patients have peripheral neuropathy that predisposes them to the development of an ulcer. The neuropathy interferes with the patient's ability to perceive pain thus leading to repeated trauma to pressure points on the feet. In addition, neuropathy can lead to the development of foot deformities resulting in further trauma to susceptible areas.¹¹ Lastly, autonomic dysfunction contributes to hypohidrosis which causes the skin to become fissured and calloused. The result is the formation of a neuropathic ulcer. Less common causes of neuropathic ulcers are spinal cord disease or injury, alcohol abuse, and leprosy.



▲ **Figure 29-5.** Neuropathic ulcer. Ulcer with callus over metatarsal head in a diabetic patient.

Clinical Presentation

History

The neuropathic ulcer is usually painless. The patient will often complain of burning, numbness, or other paresthesias of the feet and lower legs.

Physical Examination

The typical location of a neuropathic ulcer is over a pressure point of the plantar foot, such as the great toe, metatarsal head, or heel. A callus often surrounds and hides the full extent of the wound (Figure 29-5). The patient may have claw toes, flat feet, or Charcot joints. These ulcers tend to be deep and bone or tendon might be visible.

Laboratory Findings

As with venous and arterial ulcers, a CBC, ESR, and blood glucose can help to diagnose an underlying hematologic, inflammatory, or diabetic condition. If infection is suspected, one should consider an X-ray or MRI to rule out osteomyelitis. Tissue and/or bone cultures should be taken prior to the initiation of antibiotic therapy.

Diagnosis and Differential Diagnosis

The key diagnostic findings of neuropathic ulcers are deep, punched-out appearing ulcerations mainly over pressure points of the plantar foot. These ulcers are often surrounded by callus and the foot might exhibit some deformity.

See Table 29-1 for the differential diagnosis of leg ulcers.

Management

Of paramount importance in the care of a diabetic patient is the prevention and early detection of lower extremity ulcers. The largest cause of amputation other than traumatic injury is a nonhealing diabetic foot ulcer.¹²

Proper care of the ulcer itself is very important, with a goal of keeping the ulcer environment moist. Once a wound is prepared properly, an engineered product such as Oasis or Dermagraft can be quite useful in helping an ulcer to reepithelialize.

Identification and early management of infection in a neuropathic ulcer will significantly decrease morbidity and even mortality. If osteomyelitis is suspected or confirmed, appropriate parenteral antibiotic therapy should be instituted promptly.

Aggressive debridement of the surrounding callus and nonviable tissue should be performed either surgically (with a scalpel), mechanically (with wet-to-dry dressings), or enzymatically (with collagenase).¹³

Another important component of treatment of a neuropathic ulcer is off-loading of pressure.¹⁴ Repeated trauma to high pressure areas of an insensate foot is the underlying cause of many neuropathic ulcers. There are a number of different devices used to reduce foot pressure and one should consider consultation with a podiatrist to aid in the selection of the appropriate device for a patient. Most commonly, orthotic devices with cushioning are chosen for this purpose.

Indications for Consultation

It is often useful to co-manage a patient with a neuropathic ulcer with a podiatrist who has expertise in orthotics and procedures involving the foot. If there is also an arterial component, consultation with a vascular surgeon might be appropriate as well.

Patient Information

- PubMed Health—Stasis ulcers: www.ncbi.nlm.nih.gov/pubmedhealth/PMH0001837/
- American Diabetes Association: www.diabetes.org/living-with-diabetes/complications/foot-complications/

The on-line learning center at www.LangeClinicalDermatology.com has a self assessment quiz for this chapter.

REFERENCES

1. Valencia IC, Falabella A, Kirsner RS, Eaglstein WH. Chronic venous insufficiency and venous leg ulceration. *J Am Acad Dermatol.* 2001;44:401–421. PMID: 11209109.
2. Philips T, Stanton B, Provan A, Lew R. A study of the impact of leg ulcers on quality of life: financial, social, and psychological implications. *J Am Acad Dermatol.* 1994;31:49–53. PMID: 8021371.
3. Sackheim K, DeAraujo TS, Kirsner RS. Compression modalities and dressings: their use in venous ulcers. *Dermatol Ther.* 2006;19:338–347. PMID: 17199676.
4. Lund J, Mieh D. Leg ulcers. In: Schwarzenberger K, Werchniak AE, Ko CJ, eds. *General Dermatology.* 1st ed. Philadelphia, PA: Elsevier; 2009:346.
5. Schultz GS, Sibbald RG, Falanga V, et al. Wound bed preparation: systematic approach to wound management. *Wound Repair Regen.* 2003;11:1–28. PMID: 126561015.
6. Palfreyman SJ, Nelson EA, Lochiel R, Michaels JA. Dressing for healing venous leg ulcers. *Cochrane Database Syst Rev.* 2006;3:CD001103. PMID: 16855958.
7. Abbade LP, Lastoria S. Venous ulcer: epidemiology, diagnosis and treatment. *Int J Dermatol.* 2005;44(6):449–456. PMID: 15941430.
8. Hiatt WR. Medical treatment of peripheral arterial disease and claudication. *N Engl J Med.* 2001;344:1608–1621. PMID: 11372014.
9. Vowden K, Vowden P. Doppler and the ABPI; how good is our understanding? *J Wound Care.* 2001;10:197–202. PMID: 12964353.
10. Pham HT, Rich J, Veves A. Wound healing in diabetic foot ulceration: a review and commentary. *Wounds.* 2000;12:79–81.
11. Caputo GM, Cavanagh PR, Ulbrecht JS, et al. Assessment and management of foot disease in patients with diabetes. *N Engl J Med.* 1994;331:854–860. PMID: 7848417.
12. Browne AC, Sibbald RG. The diabetic neuropathic ulcer: an overview. *Ostomy Wound Manage.* 1999;45(1A suppl):65–205. PMID: 10085972.
13. Dinh TL, Veves A. Treatment of diabetic ulcers. *Dermatol Ther.* 2006;19:348–355. PMID: 17199677.
14. Armstrong DG, Nguyen HC, Lavery LA, et al. Offloading the diabetic foot wound: a randomized clinical trial. *Diabetes Care.* 2001;24:1019–1022. PMID: 11375363.

Skin Diseases of the Scalp

Maria K. Hordinsky

30

Introduction to Chapter / 265
Approach to Diagnosis / 265

Evaluation of Dermatoses Involving
the Scalp / 265

INTRODUCTION TO CHAPTER

The scalp is characterized by a high density of sweat glands and pilosebaceous units consisting of hair follicles, sebaceous glands, and arrector pili muscles. It is estimated that there are some 100,000 follicles on the scalp so this also means that there are about 100,000 sebaceous glands and associated arrector pili muscles.

Skin diseases involving the scalp can be broadly classified into inflammatory dermatoses, infections, and neoplastic (see Table 30-1). Hair on the scalp protects the skin from ultraviolet light and if absent or decreased, predisposes balding individuals to sunburns, photodamage, and photosensitivity. Likewise, the presence of hair may make cleaning the scalp surface with shampoos challenging permitting the development of scalp conditions such as dandruff and seborrheic dermatitis related to colonization of commensal *Malassezia* yeasts.

APPROACH TO DIAGNOSIS

Dermatoses of the scalp are common and can be broadly categorized into three major categories: inflammatory, infectious, and neoplastic. Lesions on the scalp can also

be related to photodamage or systemic diseases such as dermatomyositis or to bullous conditions such as pemphigus vulgaris or pemphigus erythematosus.

EVALUATION OF DERMATOSES INVOLVING THE SCALP

Most skin diseases of the scalp are diagnosed clinically based on the patient's history and physical findings. A scalp biopsy or additional tests may be needed to confirm the diagnosis. Some of these additional tests include:

- A potassium hydroxide (KOH) examination and/or fungal cultures when tinea capitis is suspected.
- Bacterial and viral cultures if there is a primary or secondary skin infection.
- Patch testing if allergic contact dermatitis is a consideration.
- Biopsy for direct immunofluorescence examination if a bullous disorder is suspected.

The online learning center at www.LangeClinicalDermatology.com has clinical self-assessment questions for this chapter.

Table 30-1. Differential diagnosis for skin diseases of the scalp.

Disease	Epidemiology	History	Physical Examination
Inflammatory			
Allergic contact dermatitis	Common F > M Any age	Pruritic. Onset is within hours or days after contact with the allergen	Usually presents with erythema, edema, and pruritus of the forehead, eyelids, ears, and rarely the scalp
Atopic dermatitis	Common M ≥ F	Pruritic	Scalp involvement more commonly seen in infants
Cicatricial alopecias	Relatively uncommon Prevalence is reported to range from 3.2% to 7.3% of all the alopecia conditions Most common include discoid lupus erythematosus, lichen planopilaris, and central centrifugal alopecia	Hair loss may be acute or chronic and associated with itching, burning, pain, redness, and/or drainage	Visible loss of follicular ostia, evidence for scalp inflammation with erythema, scaling, pustules, and scalp bogginess (Figures 19-8, 10, 11)
Psoriasis	Common M > F Any age	Asymptomatic to pruritic	Red papules and plaques with silvery, thick, adherent scale can be present (Figure 9-3)
Seborrheic dermatitis	Common M > F Age: bimodal; peaks in infancy and adulthood	The patient typically complains of a dry, scaly, and itchy scalp	Infants usually present with “cradle cap,” pink to yellow macules and patches with white greasy scales on the scalp Commonly presents in adults with “dandruff,” white flakes with no erythema (Figure 9-7). Moderate to severe seborrheic dermatitis is characterized by erythematous plaques with white greasy scales
Infectious/infestations			
Dissecting cellulitis	Uncommon M > F Age: 18-40	Drainage, pruritus, and pain may all be present Considered by some to be part of the follicular triad that includes acne conglobata and hidradenitis suppurativa	Recurrent pustules, scarring alopecia, and boggy plaques with sinus tract formation are present (Figure 19-13). <i>Staphylococcus aureus</i> is commonly isolated
Folliculitis	Common M:F dependent upon etiology that may include occlusion, heat, humidity, immunosuppression, medications, disease such as diabetes, and medications	May be pruritic	Characterized by follicular 1-3 mm pustules and/or inflammatory papules
Head lice	Common F > M Age: 3-11, especially girls with long hair; black children are less commonly affected	Transmission is via direct contact or by fomites such as combs, brushes, hats, helmets, and headphones	The occipital scalp, posterior ears, and neck are the most commonly affected sites; pyoderma and regional lymphadenopathy may be present
Herpes zoster	Common F = M Primarily older individuals	Painful prodromal period	Vesicles on a red base in a dermatomal pattern

(continued)

Table 30-1. Differential diagnosis for skin diseases of the scalp (Continued).

Disease	Epidemiology	History	Physical Examination
Infectious/infestations			
Tinea capitis	Most common in children 3-7 years old and relatively uncommon after puberty	May be asymptomatic or symptomatic	Characterized by adherent scale with no alopecia or with areas of alopecia that have broken hair fibers, which appear like black dots Dandruff-like adherent scale, with no alopecia Areas of alopecia may be dotted with broken hair fibers, which appear like black dots
Kerion	Uncommon Children are more affected than adults; animals can be the source of infection	Very tender	Characterized by inflammation and suppurative lesions on the scalp (Figure 10-3). There may be sinus formation and rarely mycetoma-like grains
Systemic			
Dermatomyositis	Rare F > M	Intensely pruritic	Characterized by diffuse, scaly erythematous patches in the scalp with postauricular erythema
Bullous diseases			
Pemphigus vulgaris	Uncommon M = F Onset is most common between the ages of 50 and 60	Lesions may be painful	Flaccid blisters, crusting, erosions, and tufted hair fibers may be present
Pemphigus foliaceus	Uncommon M = F Onset typically after age 50-60 years, endemic to central and southwestern Brazil and Columbia	Burning sensation or pain may be present	Crusting, scale, erosions, and erythema may be present
Bullous pemphigoid	Uncommon M = F Onset typically after age 50	Pruritic	Erythema, blisters
Neoplastic			
Actinic keratosis	Common. M > F Age: >50 years. Fair skin	May be tender and persist for months to years. History of excessive sun exposure and balding. When numerous, patients may mistake these as "rash"	Skin-colored, yellow-brown, or pink gritty papules and plaques with adherent hyperkeratotic scale (Figure 17-1)
Cutaneous T-cell lymphoma	Uncommon M > F	May be pruritic	Eczematous or psoriasiform patches or plaques or nodules may be present

F, Female; M, male

31

Skin Diseases of the Face

Noah Goldfarb
Steven W. Lin

Introduction to Chapter / 268
Approach to Diagnosis / 268

Evaluation / 268

INTRODUCTION TO CHAPTER

The face is the area of the body most exposed to sunlight and therefore at highest risk for ultraviolet (UV) light-induced dermatoses (photodermatoses), photoaging, and skin cancers. The face also has the highest density of sebaceous glands, predisposing this area to conditions such as acne, rosacea, and seborrheic dermatitis. Inflammation around the hair follicles may lead to skin diseases such as folliculitis and pseudofolliculitis barbae. In addition, skin diseases involving mucous membranes will typically affect the eyes, nose, and mouth. Since the face is so critical to nonverbal communication and social interactions, skin diseases involving this area can cause a significant degree of emotional distress.

APPROACH TO DIAGNOSIS

Skin diseases involving the face can be broadly categorized into pilosebaceous conditions, inflammatory dermatoses, infectious diseases, connective tissue diseases, UV-induced photodermatoses, and pigment disorders (see Table 31-1). Widespread actinic keratoses on the face are also included because they are sometimes misdiagnosed as a “rash.”

Papules and pustules can be seen in several conditions such as acne, rosacea, perioral dermatitis, folliculitis, pseudofolliculitis barbae, impetigo, and acute contact dermatitis. Acne can be distinguished by the presence of its hallmark lesions, the comedones. Rosacea can sometimes be difficult to distinguish from acne. Patients with rosacea

classically have central facial erythema, flushing and telangiectasias, and no comedones. Facial dermatitis also has a broad differential, but the most common causes of eczematous eruptions on the face are atopic dermatitis in children and contact and seborrheic dermatitis in adults. Connective tissue diseases, such as dermatomyositis and lupus erythematosus, should be considered for eczematous facial eruptions not responding to standard therapy.

EVALUATION

- Most inflammatory dermatoses, skin diseases of the pilosebaceous unit and pigment disorders on the face are diagnosed clinically based on the patient’s history and physical findings and usually do not require diagnostic testing for confirmation of the diagnosis.
- A potassium hydroxide (KOH) examination and/or fungal cultures should be done for any rash with consisting of annular scaly plaques.
- Viral culture, polymerase chain reaction (PCR), or Tzanck smear can be utilized to confirm the diagnosis of herpes zoster or herpes simplex.
- A skin biopsy should be done if discoid or acute cutaneous lupus is suspected.
- Patch testing can be done for recalcitrant rashes in which allergic contact dermatitis is suspected.

The online learning center at www.LangeClinicalDermatology.com has clinical self-assessment questions for this chapter.

Table 31-1. Differential diagnosis for diseases of the face.

Disease	Epidemiology	History	Physical Examination
Pilosebaceous			
Acne vulgaris	Common Teens: M > F Adults: F > M Age: adolescents and young adulthood	Asymptomatic, pruritic or tender Individual lesions last weeks to months Fluctuating course Menstrual flares	Open (black heads) and closed (white heads) comedones, erythematous papules, pustules, cysts, and nodules (Figures 15-1 to 15-4)
Rosacea	Common F > M Age: 30-50 years	Facial flushing, stinging, or burning Eye dryness, itching, stinging, or burning Chronic course	Flushing (transient erythema), nontransient erythema, papules, pustules, and telangiectasias on central face. Blepharitis and conjunctivitis may be present (Figure 15-4 to 15-6)
Perioral dermatitis	Common F >> M Age: 20-45 years of age	Asymptomatic or symptomatic with pruritus or burning Duration: weeks to months	Grouped monomorphic follicular erythematous papules, vesicles, and pustules in the perioral region (Figure 15-7)
Pseudofolliculitis barbae	Common M >> F Age: teenagers and young adults, predominately African Americans	Asymptomatic or tender. Chronic course. Flares with shaving	Papules and pustules in the beard distribution, posterior neck, cheeks, mandibular area, and chin (Figure 15-10)
Inflammatory			
Atopic dermatitis	Common M ≥ F Age: usually presents in childhood, but may persist	Pruritic Chronic course with exacerbations Usually worse in winter. Personal and family history of atopy	<i>Infants:</i> red papules, scaly plaques, and excoriations (Figure 7-7) <i>Children and adults:</i> red lichenified plaques on cheeks, and eyelids (Figure 8-8)
Allergic contact dermatitis	Common F > M Age: any age	Pruritic Onset: hours to days after contact with allergen	<i>Acute:</i> papules and vesicles on an erythematous base (Figures 8-4 and 8-5) <i>Chronic:</i> xerosis, fissuring, hyperpigmentation and lichenification on earlobes, lips, eyelids, and hairline (Figures 8-1 to 8-3)
Irritant contact dermatitis	Common F > M	Pruritic, painful, or burning. May have history of atopy	Well-demarcated plaques with a “glazed” appearance (Figures 8-1 to 8-3)
Seborrheic dermatitis	Common M > F Age: bimodal; peaks in infancy and adulthood	Asymptomatic or mildly pruritic Waxing and waning course with seasonal variations	Lesions are symmetric, with greasy scale and underlying erythema on the eyebrows, nasolabial folds, lateral aspects of the nose, retroauricular areas, and ears (Figure 9-7)
Infectious			
Herpes simplex labialis (HSV)	Common M:F unknown Primary infection is in childhood, recurrence at any age HSV1 > HSV2	Fever and pharyngitis may be present with primary infection. Pain or tingling may precede recurrent infections. Lasts 2 weeks	Symptomatic primary infection usually presents with gingivostomatitis with vesicles on lips, tongue, gingiva, buccal mucosa, and oropharynx. Recurrent infections present with grouped vesicles on central face, usually on lips or perioral area (Figure 11-1)

(continued)

Table 31-1. Differential diagnosis for diseases of the face (Continued).

Disease	Epidemiology	History	Physical Examination
Infectious			
Herpes zoster (Shingles)	Common M:F unknown Age: any age, but usually >50 years	Severe pain, pruritus, or paresthesias may precede eruption. Lasts 3 weeks	Grouped vesicles on an erythematous base that crust over in a unilateral dermatome (Figure 11-3)
Impetigo	Common M = F Age: young children	May be pruritic Lasts days to weeks Frequently spreads through schools and day care centers	<i>Nonbullous impetigo</i> : honey-colored crusts with erosions on central face (Figure 12-1) <i>Bullous impetigo</i> : starts as superficial vesicles rapidly enlarging into flaccid bullae
Tinea faciei	Uncommon F ≥ M Age: any age, with peaks in childhood and between 20 and 40 years of age	Asymptomatic or pruritic More common in children in contact with domestic pets and livestock	Starts as a scaly annular plaque that develops a raised border that advances peripherally and may develop papules and pustules (Figure 10-5)
Connective tissue diseases			
Discoid lupus erythematosus	Common F > M Age: 20-45 years of age More common in African Americans	Asymptomatic or mildly pruritic Sunlight may precipitate flares 5%-10% develop SLE May resolve spontaneously	Red or purple patch with superficial scale that enlarges into a plaque with central scarring and depigmentation on scalp, face, ears, upper chest, neck, and extensor surfaces of the arms and hands (Figures 24-1 and 24-2)
Localized acute cutaneous lupus (also known as malar or butterfly rash)	Uncommon F > M Age: any age, but most commonly age 30-40 years	Pruritic or burning Maybe related to sun exposure. Associated with fevers, fatigue, oral ulcers, and other findings consistent with SLE	Red clustered papules, urticarial plaques, and patchy erythema with variable scale on malar eminence and nasal bridge with sparing of the nasolabial folds (Figure 24-4)
Neoplastic			
Actinic keratoses	Common M > F Age: >50 years Fair skin	May be tender. Persists for months to years History of excessive sun exposure	Skin-colored, yellow-brown, pink gritty papules and plaques with adherent hyperkeratotic scale on face and ears (Figure 17-1)
Pigmentation			
Melasma	Common F >> M Age: young adulthood	Asymptomatic Last months to years May have history of UV exposure, pregnancy, or exogenous hormone exposure	Symmetric patches of hyperpigmentation on the forehead, cheeks, nose, upper lip, chin, and jawline (Figure 21-3)
Vitiligo	Common M = F Age: any age	Asymptomatic Chronic and progressive Family history of autoimmune disease	Well-demarcated white depigmented macules and patches typically favoring the perioral and periorcular areas (Figure 21-1)
Pityriasis alba	Common F ≥ M Age: usually in children. More common in skin of color	Asymptomatic or mildly pruritic. Last several months. More common in atopic individuals	Lightly hypopigmented or white patches with fine scale, typically on the cheeks

(continued)

Table 31-1. Differential diagnosis for diseases of the face (Continued).

Disease	Epidemiology	History	Physical Examination
Photodermatoses			
Photoaging	Common M:F unknown Age >40 years Risk is inversely related to skin pigmentation	Asymptomatic Cigarette smoking hastens skin aging	Dyspigmentation, wrinkling, telangiectasias, atrophy, and leathery thickening, on the face, lateral neck, central upper chest, extensor forearms, and dorsal hands
Phototoxicity	Common M:F unknown Age: any age Risk is inversely related to skin pigmentation	Pain, burning, and pruritus. Worse in summer. Several medications, chronic porphyrias, and photosensitive dermatoses can cause exaggerated response to UV exposure	Bright red patches with edema and blistering that heal with desquamation and hyperpigmentation on sun-exposed areas including the forehead, nose, malar cheeks, neck, upper chest, upper back, extensor forearms, and dorsal hands (Figure 2-30)

F, Female; M, male; SLE, systemic lupus erythematosus; UV, ultraviolet.

32

Skin Diseases of the Arms

Steven W. Lin
Noah Goldfarb

Introduction to Chapter / 272
Approach to Diagnosis / 272

Evaluation / 272

INTRODUCTION TO CHAPTER

Many skin conditions that affect the arms result from exposure to sunlight, contact allergens or irritants, trauma, bug bites, and other environmental insults. The arms are within close reach of the contralateral hand so patients can easily scratch pruritic dermatoses. Scratching or trauma may produce a linear streak of papules (Koebner reaction) in certain diseases such as lichen planus and psoriasis. Some skin diseases have a predilection for specific locations on the arms. While it is unknown why many dermatoses have a tendency to localize to certain anatomical locations, lesion distribution is frequently a very important clue to establish diagnosis.

APPROACH TO DIAGNOSIS

Skin diseases primarily involving the arms can be broadly categorized according to their etiology. These include inflammatory, infectious, neoplastic, and photodermatoses (see Table 32-1). The distribution of skin lesions is often helpful in diagnosing skin diseases located on the arms. For example, psoriasis usually favors the extensor surface (especially the elbows), photodermatoses affect areas exposed to light, keratosis pilaris is typically seen on

the proximal dorsal arms, and atopic dermatitis generally affects the extensor surface in infants and flexural surface in children and adults. Lichen planus is commonly located on the volar wrist and flexural surfaces and nummular dermatitis on extensor surfaces.

EVALUATION

- Most inflammatory skin diseases on the arm are diagnosed clinically based on the patient's history and physical findings and usually do not require diagnostic testing for confirmation of the diagnosis.
- A potassium hydroxide (KOH) examination and/or fungal cultures should be done for any rash with annular scaly plaques.
- Viral and bacterial cultures can be performed if primary or secondary infection is suspected.
- Skin biopsies can be done if the clinical presentation is atypical or otherwise equivocal.
- Patch testing should be done if allergic contact dermatitis is suspected.

The online learning center at www.LangeClinicalDermatology.com has clinical self assessment questions for this chapter.

Table 32-1. Differential diagnosis for diseases of the arms.

Disease	Epidemiology	History	Physical Examination
Inflammatory			
Atopic dermatitis	Common M ≥ F Age: usually presents in childhood, but may persist	Pruritic. Chronic course with exacerbations Usually worse in winter Family or personal history of atopy	<i>Infants:</i> red papules, scaly plaques, and excoriations on extensor arms <i>Children and adults:</i> red lichenified plaques, prurigo nodules, and excoriations on flexor arms, especially antecubital fossae (Figure 8-8)
Keratosis pilaris	Very common. Often seen with atopic dermatitis	Usually asymptomatic. Rarely, mildly pruritic	Follicular-based keratotic papules with peripheral erythema. Stippled or “goosebumps” appearance on extensor surfaces (Figure 8-9)
Allergic contact dermatitis	Common F > M Age: any age	Pruritic and painful fissures. Onset is hours to days after contact with allergen	<i>Acute:</i> papules and vesicles on an erythematous base (Figures 8-4 and 8-5) <i>Chronic:</i> xerosis, fissuring, hyperpigmentation, and lichenification at sites of direct contact with allergen (Figure 8-6)
Psoriasis vulgaris	Common. M = F Onset at any age but peaks in 20s and 50s	Asymptomatic or mildly pruritic. Chronic Associated with arthritis Family history of psoriasis	Red papules and plaques with silvery, thick, adherent scale on elbows and extensor surface (Figure 9-1)
Lichen planus	Uncommon F > M Age: 30-60 years	Pruritic or symptomatic Lasts months to years May be drug-induced or associated with hepatitis C	Classically flat-topped, well-defined, polygonal, violaceous, shiny papules on volar wrist and flexor arms (Figures 9-10 and 9-11)
Lichen simplex chronicus	Common F > M Age >20 years. More common in atopic patients	Paroxysmal episodes of pruritus disproportionate to external stimuli (eg, changing clothes). Emotional stress may exacerbate	Sharply defined round, oval, or linear plaque(s) comprised of confluent dull pink-red papules with excoriations on extensor arms (Figure 8-13)
Nummular eczema	Common M > F Age: bimodal; peaks in young adults and the elderly	Pruritic Chronic waxing and waning course Associated with dry skin	Round, light pink, scaly, thin, 1-3 cm plaques on extensor arms (Figure 8-11)
Infectious			
Tinea corporis	Common M:F unknown Age: all. More common in hot humid areas, farms, and crowded living conditions	Mild pruritus History of contact with infected people or animals. Outbreaks seen in daycare facilities, schools, and wrestlers	Solitary or grouped well-demarcated red annular plaques with raised border with peripheral scale (Figure 10-4)
Photodermatoses. See Chapter 31 (Skin Diseases of the Face)			

F, Female; M, male.

33

Skin Diseases of the Hands

Steven W. Lin
Noah Goldfarb

Introduction to Chapter / 274
Approach to Diagnosis / 274

Evaluation / 274

INTRODUCTION TO CHAPTER

Hands have structures with many unique structural and functional features. As such, they are prone to developing specific dermatologic diseases. Structurally, the palms have a thick keratin layer, a high concentration of sweat glands, Meissner's corpuscles, and other mechanoreceptors. Functionally, we use our hand to interact with the world. Therefore, hands are subject to physical injury. Hands are often the first body part to come into contact with objects and substances in our environment. As a result, they are frequently the site of exposure to allergens, irritants, and infectious agents. This concept is central to the transmission of pathogens and development of certain dermatologic conditions such as contact dermatitis. Given their distal location, the neurovascular supply of hands (particularly the digits) can also predispose the hands to neuropathies, ischemic insults, and vasculitides. Hands tend to get more sun exposure than centrally located anatomical structures thereby subjecting them to photodermatoses and actinic damage. Hands may also manifest cutaneous signs of internal disease.

APPROACH TO DIAGNOSIS

Skin diseases primarily involving the hands can be broadly categorized into inflammatory dermatoses, infections, connective tissue disorders, and photodermatoses (see Table 33-1). Widespread actinic keratoses on the hands are also included in this chapter because they are sometimes misdiagnosed as a "rash." The inflammatory dermatoses are most common and typically present with pruritic papules or plaques. The morphology of tinea manuum depends on its

distribution, with annular plaques being more common on the dorsal hand and diffuse fine scale on the palm. Sunlight-induced dermatoses and connective tissue disorders present on the dorsal hands with pink papules and plaques.

EVALUATION

- Most inflammatory hand dermatoses including dyshidrotic dermatitis, atopic dermatitis, psoriasis, and irritant contact dermatitis are diagnosed based on the patient's history and clinical findings and usually do not require diagnostic testing for confirmation of the diagnosis.
- A potassium hydroxide (KOH) examination and/or fungal cultures should be done in most scaly hand rashes. Tinea manuum may be clinically indistinguishable from inflammatory dermatoses such as dermatitis and psoriasis.
- Patch testing should be done if allergic contact dermatitis is a likely diagnosis.
- A skin biopsy can be done if the clinical presentation is atypical or equivocal.
- Viral and bacterial cultures can be done if primary or secondary infections are suspected.
- A thorough history with review of systems and physical exam are very important for cutaneous manifestations of internal disease and connective tissue disorders. Suspicion for these diseases may prompt further evaluation with appropriate diagnostic studies.

The online learning center at www.LangeClinicalDermatology.com has clinical self assessment questions for this chapter.

Table 33-1. Differential diagnosis for diseases of the hands.

Disease	Epidemiology	History	Physical Examination
Inflammatory			
Irritant contact dermatitis	Common F > M Any age Atopics are at increased risk	Pruritic, burning, or painful Variable onset depends on frequency of exposure and strength of irritant	Well-demarcated with a “glazed” appearance Erythema, fissures, blistering, and scaling usually in finger web spaces or dorsum of hands (Figures 8-1 to 8-3)
Allergic contact dermatitis	Common F > M Any age	Pruritic with onset hours to days after contact with allergen	<i>Acute:</i> papules and vesicles on an erythematous base (Figures 8-4 and 8-5) <i>Chronic:</i> xerosis, fissuring, hyperpigmentation, and lichenification usually on the dorsum of hand and distal fingers (Figures 8-1 to 8-3)
Atopic dermatitis	Common F > M Age: any May be only manifestation of disease in adults	Pruritic and sometimes painful Chronic course with exacerbations Triggers: frequent hand washing or wet work Usually worse in winter Family history of atopy	Presents with swelling, xerosis, fissuring, erythema, and lichenification on dorsum and palms (Figure 2-10)
Dyshidrotic dermatitis	Common F ≥ M Age: young adults and atopics overrepresented	Very pruritic Chronic and recurrent, episodes last 2-3 weeks. Exacerbated by sweat and stress	Multiple grouped vesicles and erosions on noninflammatory base on lateral surface and palms (Figure 8-12)
Psoriasis vulgaris	Common M = F Age of onset: peaks in 20s and 50s. May be only manifestation of disease	Painful fissures or pruritic Chronic indolent course May have arthritis and family history of psoriasis	Presents with well-demarcated erythematous plaques with loosely adherent, silvery scale (Figure 9-1), or less commonly with pustules on central palms (Figure 9-6)
Palmoplantar pustulosis	Uncommon F > M Onset: 50-60 years of age	Pruritus, burning, pain Lasts years Waxing and waning course	Scattered creamy yellow pustules and dusky red macules on palms
Lichen planus	Uncommon F > M Age: 30-60 years	Asymptomatic or pruritic Lasts months to years May be drug-induced or associated with hepatitis C infection	Classically, flat-topped, well-defined, polygonal, violaceous, shiny papules on volar wrist and dorsum (Figure 9-10)
Infectious			
Warts	Common M > F More common in children and young adults	Asymptomatic or painful. May persist for years	Discrete or confluent hyperkeratotic papules or plaques. May have black or brown dots within the lesions created by thrombosed capillaries (Figure 11-6)
Tinea manuum	Uncommon M > F	Asymptomatic or pruritic. Last months to years Contact with infected person or animal or autoinoculation (eg, from foot or groin) Usually associated with tinea pedis	On palms presents with diffuse fine scaling (Figure 10-6). Unilateral in 50%. On dorsum presents with annular red patch/plaque with peripheral scale at leading edge. Nails may be affected
Herpetic whitlow	Uncommon At risk: Healthcare workers, or contact with HSV	Painful	Grouped and confluent vesicles on red edematous base on a distal digit

(continued)

Table 33-1. Differential diagnosis for diseases of the hands (Continued).

Disease	Epidemiology	History	Physical Examination
Neoplastic			
Actinic keratoses	Common M > F Age: >40 years	Asymptomatic or tender Duration: months to years Risk factors: advancing age, cumulative sun exposure, outdoor occupation, and fair skin type	Skin-colored, yellow-brown, pink ill-defined gritty papules with adherent hyperkeratotic scale (Figure 17-1)
Systemic disease			
Acute cutaneous lupus erythematosus (generalized)	Uncommon F > M Age: any age, but most commonly 30-40 years of age High morbidity	Pruritus or burning Duration: weeks to months Maybe related to sun exposure. Associated with fevers, fatigue, oral ulcers, and other systemic findings consistent with SLE	Red clustered papules, urticarial plaques, and patchy erythema with variable scale on dorsal hands, classically sparing the skin overlying the joints
Dermatomyositis	Uncommon F > M Age: bimodal; peaks at ages 5 to 10 and 50 years	Asymptomatic or mildly pruritic. Chronic course Associated with photosensitivity, scalp pruritus/burning, and symmetric proximal muscle weakness	Flat-topped violaceous papules overlying knuckles and interphalangeal joints (Gottron's papules) Periungual erythema (Figure 24-6)
Porphyria cutanea tarda	Uncommon M = F Age: adults 30-50. Hereditary or acquired (eg, medications)	Pain from erosions Gradual onset easily traumatized fragile skin Implicated drugs: ethanol, estrogen, iron, among others Other predisposing factors: diabetes mellitus and hepatitis C virus	Tense vesicles/bullae and erosions with normal appearing surrounding skin Atrophic white-pink scars and milia on dorsal hands (Figure 24-13)
Photodermatoses: see Chapter 31 (Skin Diseases of the Face)			

F, Female; HSV, herpes simplex virus; M, male; SLE, systemic lupus erythematosus.

Skin Diseases of the Trunk

Steven W. Lin
Noah Goldfarb

34

Introduction to Chapter / 277
Approach to Diagnosis / 277

Evaluation / 277

INTRODUCTION TO CHAPTER

The trunk is a general term for the core body region including the chest, abdomen, flanks, and back. The trunk has many unique characteristics. In many people it is a site of minimal sunlight exposure as it is usually covered by clothing. Dermatoses within this distribution may be caused by an allergic contact dermatitis due to chemicals in clothing, soaps, dryer sheets, and other allergens. Since the trunk is generally covered by clothing, this occlusion often creates a warm, humid environment ideal for the development of diseases such as folliculitis, acne, and tinea versicolor. A high density of sebaceous glands in the presternal area may provide an ideal location for pityrosporum ovale yeast proliferation, making this a common location for seborrheic dermatitis. Skin folds, such as the abdominal skin folds and inframammary creases are prone to intertrigo and/or maceration, increasing the risk of developing cutaneous candida infections among other dermatoses. The trunk is the most common location for herpes zoster. The umbilicus is unique in that it has a high density of apocrine glands. Interestingly some conditions including psoriasis and scabies often favor this site.

APPROACH TO DIAGNOSIS

Skin diseases primarily involving the trunk can be broadly categorized into inflammatory dermatoses, infections, and pilosebaceous diseases (see Table 34-1). The inflammatory diseases are the most common cause of skin disease

on the trunk, however infectious skin diseases are more common in hot humid climates, in obese or immunocompromised patients. The trunk is the area of the body that is most involved in diseases such as morbilliform drug rashes, guttate psoriasis, tinea versicolor, and pityriasis rosea.

EVALUATION

- Most skin diseases on the trunk are diagnosed clinically based on the patient's history and physical findings and usually do not require diagnostic testing for confirmation of the diagnosis.
- A potassium hydroxide (KOH) examination and/or fungal cultures should be done for any rash with annular scaly plaques or scaly macules with variable color.
- Viral and bacterial cultures can be performed if primary or secondary infection is suspected.
- A rapid plasma reagin (RPR) should be done if secondary syphilis is suspected and in pityriasis rosea-like rashes in high-risk groups.
- Skin biopsies can be done if the clinical presentation is equivocal or if Grover's disease or folliculitis due to pityrosporum is suspected.
- Patch testing should be done if allergic contact dermatitis is suspected.

The online learning center at www.LangeClinicalDermatology.com has clinical self assessment questions for this chapter.

Table 34-1. Differential diagnosis for diseases of the trunk.

Disease	Epidemiology	History	Physical Examination
Inflammatory			
Allergic contact dermatitis	Common F > M Age: any age	Pruritus Onset: hours to days after contact with allergen	<i>Acute:</i> papules and/or vesicles on an erythematous base (Figures 8-4 and 8-5) <i>Chronic:</i> xerosis, fissuring, hyperpigmentation, and lichenification (Figures 8-1 to 8-3). Typical locations: axillae, waistline, and umbilicus
Psoriasis	Common M = F Age of onset: any age but peaks in 20s and 50s	Asymptomatic or mildly pruritic. Chronic May have history of arthritis and family history of psoriasis	Red papules and plaques with silvery, thick, adherent scale typically on lower back, umbilicus, buttocks, and gluteal cleft. Guttate psoriasis presents with multiple small scaly papules (Figure 9-5)
Seborrheic dermatitis	Common M > F Age: bimodal; peaks in infancy and adulthood	Asymptomatic or mildly pruritic. Intermittent with seasonal variation	Symmetric pink plaques with greasy scale on central chest
Pityriasis rosea	Common F > M Age: any, most common in children and young adults Seen in fall or spring	Variable pruritus, sometimes preceding nonspecific “flu-like” symptoms Spontaneous remission in 6-12 weeks	Begins with a herald patch, an oval, slightly elevated, salmon pink 2-5 cm plaque with trailing collarette scale. Later dull pink oval papules or plaques with fine scale develop symmetrically on trunk in “Christmas tree” distribution (Figure 9-9)
Infectious			
Candidiasis	Common M = F Age: infants and adults, other ages when risk factors present	Pruritus, soreness Risk factors: pregnancy, immunodeficiency, obesity, diabetes, antibiotic and glucocorticoid use	Initially vesicopustules that rupture and coalesce leading to moist, macerated, red plaque with fissures with satellite pustules at periphery on inframammary, axillae, and abdominal skin folds (Figure 10-17)
Tinea versicolor	Common M = F Age: postpubertal	Asymptomatic rarely mild pruritus Duration: months to years. More common in summer and warm moist environments	3-5 mm round to oval macules with fine scale, may coalesce and develop hypo- or hyperpigmentation or variable coloration on central back and chest and neck (Figure 10-14)
Tinea corporis	Common M = F Age: any, most common in preadolescents	Asymptomatic or mild pruritus. Spread by direct contact with infected humans, animals, soil, or autoinoculation from a dermatophyte infection present on other locations	Red, scaly papule that expands outward and develops into annular plaque with slightly raised well-demarcated border with peripheral scale (Figure 10-4) Central clearing may result in a “target-like” appearance
Folliculitis	Common M:F dependent upon etiology which may include non-infectious causes Age: any	Variable pruritus. Risk factors: occlusion, heat, humidity, diabetes, immunosuppression, trauma, and medications	Follicular-based papules or pustules May have surrounding red zone May have erosions or crust from secondary changes (Figures 15-8 & 15-9)

(continued)

Table 34-1. Differential diagnosis for diseases of the trunk (Continued).

Disease	Epidemiology	History	Physical Examination
Infectious			
Infectious exanthems	Common Age: <20 years Viral pathogen most common, can be bacterial, mycoplasmal, rickettsial, or other	Prodromal symptoms including fever, malaise, coryza, sore throat, nausea, vomiting, diarrhea, abdominal pain, and headache Usually precedes cutaneous eruption by up to 3 weeks	Multiple presentations: scarlatiniform, morbilliform (Figures 27-1 to 27-6), vesicular, and pustular Often accompanied by oral mucous membrane involvement, lymphadenopathy, hepatomegaly, and splenomegaly
Syphilis (secondary)	Uncommon M > F Age: 15-40 Risk factors: men who have sex with men	History of asymptomatic, genital ulcer several weeks to months prior to onset of rash. Systemic symptoms (fever, malaise, myalgia, and headache). May be present or shortly precede onset of eruption	Scattered ill-defined pink macules or red, scaly, well-defined papules symmetrically distributed on trunk (Figure 12-6)
Herpes zoster	Common M:F unknown Age: any age, but usually >50 years	Severe pain, paresthesias, or pruritus precedes eruption. Resolves over 2-3 weeks	Grouped vesicles on an erythematous base (Figure 11-4) that later crusts over a unilateral dermatome (usually thoracic)
Pilosebaceous			
Acne	Common Teens: M > F Adults: F > M Age: adolescents and young adults	Asymptomatic, pruritic, or tender. Individual lesions may last weeks to months. Variable course Menstrual exacerbations	Open (black heads) and closed (white heads) comedones, erythematous papules, pustules, and nodules on upper chest and back (Figure 15-1)
Other			
Drug eruption	Common F > M Age: any, most common in hospitalized patients	Symptoms, onset, and duration variable and depend on offending agent. History of recent changes or adjustments to medications Risk factors: elderly, concomitant viral infection	Morphology and distribution extremely variable, virtually every cutaneous reaction may be seen. Morbilliform most common, presents with small pink macules and papules, often starts on trunk and pressure-bearing areas, may generalize and become confluent (Figure 10-6)
Grover's disease (transient acantholytic dermatosis)	Uncommon M > F Age: ≥50	Variable pruritus Abrupt onset with chronic course. Exacerbated by heat, sweat, sunlight, fever, and bedridden status	Discrete, scattered, and/or confluent red hyperkeratotic scaly papules sometimes with crust, erosion on central trunk, and proximal extremities

F, female; M, male.

35

Skin Diseases of the Legs

Noah Goldfarb
Steven W. Lin

Introduction to Chapter / 280
Approach to Diagnosis / 280

Evaluation / 280

INTRODUCTION TO CHAPTER

The legs are predisposed to dermatoses that are gravity dependent, including stasis dermatitis and vascular conditions such as leukocytoclastic vasculitis, the pigmented purpuric dermatoses, and livedo reticularis. Legs are also the site of frequent trauma and thus are susceptible to conditions that may be induced by trauma including superficial thrombophlebitis, pyoderma gangrenosum, necrobiosis lipoidica, chronic ulcers, and cellulitis. In patients with preexisting vascular conditions affecting the lower extremities, including diabetes mellitus, venous insufficiency, and peripheral vascular disease, traumatic wounds may take longer to heal and may have an increased risk of infection.

APPROACH TO DIAGNOSIS

Skin diseases primarily involving the legs can be broadly categorized into inflammatory conditions, infectious diseases, superficial vascular disorders, neoplastic lesions, and underlying systemic diseases (see Table 35-1). Differentiating between these conditions can usually be done based on an appropriate history and physical examination. Occasionally, dermatitis on the lower extremities may be difficult to distinguish from a cellulitis. Cellulitis of the lower extremities tends to be unilaterally, as compared to dermatitis, which usually is bilateral.

EVALUATION

- Most leg rashes including stasis dermatitis, nummular dermatitis, asteatotic dermatitis, cellulitis, stucco keratoses, diabetic dermopathy, superficial thrombo-

phlebitis, pigmented purpuric dermatoses, and livedo reticularis are diagnosed clinically based on the patient's history and physical findings and usually do not require diagnostic testing to confirm a diagnosis.

- The diagnosis of erythema nodosum and necrobiosis lipoidica can be made from the history and physical exam alone, but many clinicians obtain a skin biopsy to confirm the clinical diagnosis.
- Skin biopsies for routine histology and direct immunofluorescence should be done in all patients with suspected leukocytoclastic vasculitis to confirm the diagnosis and evaluate for IgA deposition. Basic laboratory tests should also be done to evaluate for renal or liver involvement.
- A skin biopsy for routine histology and tissue culture for bacterial, deep fungal, and atypical mycobacterium infections should be performed in patients with suspected pyoderma gangrenosum. While the skin biopsy is non-specific, a biopsy is required to exclude other diagnoses, since pyoderma gangrenosum is a diagnosis of exclusion.
- Skin biopsy on the lower extremity should be done with caution because wounds in this area heal more slowly and become infected more often. This is especially pertinent in patients with preexisting vascular conditions affecting the lower extremities, including diabetes mellitus, venous insufficiency, or peripheral vascular disease. An attempt should be made to biopsy lesions that are located most proximal.
- A potassium hydroxide (KOH) examination and/or fungal cultures should be done for any rash with annular scaly plaques.

- Viral and bacterial cultures can be performed if primary or secondary infection is suspected.
- Patch testing should be done if allergic contact dermatitis is suspected.

The online learning center at www.LangeClinicalDermatology.com has clinical self-assessment questions for this chapter.

Table 35-1. Differential diagnosis for diseases of the legs.

Disease	Epidemiology	History	Physical Examination
Inflammatory			
Asteatotic dermatitis	Common M > F Age: typically >60 years	Pruritus and dry skin Waxing and waning course Worse in winter	Dry, fissured, cracking, mildly scaly and inflamed plaques on bilateral anterior lower legs (Figure 8-3)
Stasis dermatitis	Common F > M Age: middle-aged and elderly adults	Asymptomatic or pruritic Associated with leg swelling	Erythematous, scaly plaques, may be hyperpigmented, lichenified, or sclerotic on bilateral anterior lower legs, especially medial ankles (Figure 29-1)
Nummular eczema	Common M > F Age: Adults	Pruritus Chronic, waxing, and waning course Worse in fall and winter	Round, light pink, scaly, thin, 1-3 cm plaques on legs (Figure 8-11)
Psoriasis vulgaris	Common M = F. Onset at any age but peaks in 20s and 50s	Asymptomatic to mildly pruritic. Chronic course. May be associated with arthritis Family history of psoriasis	Red papules and plaques with silvery, thick, adherent scale, commonly on knees (Figure 9-1)
Erythema nodosum	Uncommon F > M Age: 20-40 years	Tender lesions Variable course May be associated with fevers and arthralgias	Indurated, tender, red, deep, poorly defined nodules, usually on bilateral shins (Figure 24-14)
Pyoderma gangrenosum	Rare F ≥ M Age: all ages, but typically 30-40 years	Painful. May last months to years Spontaneous healing may occur	Initially, a hemorrhagic pustule with surrounding erythema. Later, ulceration with granulation tissue, eschar and purulent material at the base, and a dusky red/purple border (Figure 2-13)
Infectious			
Cellulitis	Common M = F Age: more common in older adults	Pain, swelling, fever, chills, and malaise Increased risk in diabetics	Localized warm, red, tender plaque with ill-defined borders, usually on lower leg (Figure 12-3)
Tinea corporis	Common M > F Age: any age	Mild pruritus History of concomitant tinea pedis	Solitary or grouped, well-demarcated red annular plaques with a raised border and peripheral scale (Figure 10-4). Sometimes peripheral vesicles or pustules
Neoplastic			
Stucco keratoses	Common M > F Age: older adults	Asymptomatic and usually unnoticed	Keratotic, stuck on appearing, whitish-grey papules bilaterally on extensor surface (Figure 16-3)

(continued)

Table 35-1. Differential diagnosis for diseases of the legs (Continued).

Disease	Epidemiology	History	Physical Examination
Systemic			
Diabetic dermopathy	Uncommon M:F unknown Age: usually >50 years	Asymptomatic Appears in crops. Slowly resolves with scarring	Well-circumscribed, round, atrophic, and hyperpigmented plaques that heal with scarring on bilateral shins
Necrobiosis lipoidica	Uncommon F > M Age: young adults	Usually asymptomatic, but may ulcerate and become painful. Gradual onset, may last years. One-third have history of diabetes or minor trauma	Well-demarcated, shiny plaque with a mildly elevated erythematous border and an atrophic, yellowish, waxy center on bilateral shins (Figure 24-8)
Thrombocytopenic purpura (TTP)	Uncommon M = F Age: any age, depending on etiology	Asymptomatic Onset: hours Associated with low platelets due to HIV, TTP, ITP, DIC, drugs, infections, and bone marrow dyscrasias	Petechiae: pinpoint, nonblanching, nonpalpable red macules (Figure 25-1) Ecchymosis: larger red macules and black-and-blue patches
Vascular			
Superficial thrombophlebitis	Uncommon M:F unknown Age: young to middle aged adults	Asymptomatic or tender Idiopathic or due to trauma, infection, IV extravasation, or migratory thrombophlebitis	Red and tender subcutaneous cord with swelling along the course of a vein Can occur on the trunk or extremities, but most commonly occurs on the legs
Leukocytoclastic vasculitis.	Uncommon M = F Age: all ages	Asymptomatic, pruritic, or tender. Duration: days to years depending on etiology. Idiopathic or due to drugs, underlying CVD, infections, or malignancy	Classic presentation is palpable purpura/petechiae with bright red well-defined macules and scattered red papules on lower legs and ankles (Figure 25-4)
Pigmented purpuric dermatosis (Schamberg's disease)	Common M > F Age: typically 30-60 years	Asymptomatic or mildly pruritic. Slowly evolving over months. Chronic course, lasting years	Characteristic purpuric, speckled, "cayenne pepper-like" macules or less commonly annular plaques and lichenoid papules on lower legs
Physiologic livedo (cutis marmorata)	Common M:F unknown Age: more apparent in neonates, infants, and children	Asymptomatic A physiologic phenomenon that occurs in the cold	Purple discoloration of the skin in a netlike distribution on the lower extremities that resolves with warming
Primary and secondary pathologic livedo reticularis (LR)	Uncommon M < F Age: 20-30 years of age	Asymptomatic. Secondary LR is associated with conditions that cause vasospasm, increased blood viscosity, vasculitis, or intravascular obstruction	Purple discoloration of the skin in a netlike distribution on the lower extremities that persists after rewarming (Figure 2-28)

CVD, collagen vascular disorder; DIC, disseminated intravascular coagulation; F, female; HIV, human immunodeficiency virus; ITP, idiopathic thrombocytopenic purpura; IV, intravenous; M, male; TTP, thrombocytopenic purpura.

Skin Diseases of the Feet

Noah Goldfarb
Steven W. Lin

36

Introduction to Chapter / 283
Approach to Diagnosis / 283

Evaluation / 283

INTRODUCTION TO CHAPTER

The plantar surface of the foot has the thickest keratin layer, a high concentration of eccrine sweat glands, as well as sensory nerves, including Pacinian corpuscles, and other mechanoreceptors. The combination of abundant keratin and sweat creates an ideal environment for fungal infections. Friction and contact with footwear also make the feet susceptible to contact dermatitis. In addition, the feet are disproportionately affected by vascular disorders, due to their gravity-dependent anatomical location, and by peripheral small fiber sensory neuropathies. Since the feet are a site of frequent injury, vascular disorders and sensory neuropathies predispose this area to recurrent and difficult-to-manage wounds.

APPROACH TO DIAGNOSIS

The most common causes of skin diseases on the feet are dermatophyte infections and inflammatory dermatoses (see Table 36-1). Clinically these two categories of disease are often indistinguishable from one another. The presence of fissures and/or scale in the toe web space and nail dystrophy is more suggestive of a dermatophyte infection, but nail dystrophy can also occur in psoriasis.

EVALUATION

- Inflammatory skin diseases, such as dyshidrotic dermatitis, atopic dermatitis, psoriasis, and warts, are typically diagnosed clinically based on the patient's history and physical findings, and usually do not require diagnostic testing for confirmation of the diagnosis.
- Potassium hydroxide (KOH) examination and/or a fungal culture should be done for almost all foot rashes as fungal infections may be indistinguishable from inflammatory dermatoses.
- Bacterial culture should be done if a bacterial toe web infection is suspected.
- Skin biopsy could be considered if psoriasis is a likely diagnosis; however, the histopathologic changes of psoriasis on the foot are often nonspecific.
- Patch testing can be considered for any rash in which allergic contact dermatitis is suspected.

The online learning center at www.LangeClinicalDermatology.com has clinical self-assessment questions for this chapter.

Table 36-1. Differential diagnosis for diseases of the feet.

Disease	Epidemiology	History	Physical Examination
Inflammatory			
Allergic contact dermatitis	Common F > M Age: any age	Pruritus and painful fissures Onset: hours to days after contact with allergen	<i>Acute:</i> Papules and vesicles on an erythematous base (Figures 8-4 and 8-5) <i>Chronic:</i> xerosis, fissuring, hyperpigmentation, and lichenification (Figures 8-1 to 8-3)
Atopic dermatitis	Common M ≥ F Age: usually begins in childhood but may persist	Pruritic and painful Chronic waxing and waning course Family history of atopy	Presents with swelling, xerosis, fissuring, erythema, and lichenification on the dorsal feet and soles (Figure 2-10)
Dyshidrotic dermatitis	Common F ≥ M Age: usually young adults	Severely pruritic or painful. Chronic and recurrent with episodes lasting 2-3 weeks	Multiple grouped vesicles and erosions on a noninflammatory base located on the soles (Figure 8-12)
Psoriasis vulgaris	Common M = F Age of onset: any age, but peaks in 20s and 50s	Pruritic and painful Chronic, indolent course. Associated with arthritis and nail pitting/dystrophy Family history of psoriasis	Well-demarcated plaques with adherent, thick scale on an erythematous base. Less commonly present with pustules over pressure-bearing regions of the soles (Figure 9-1)
Palmoplantar pustulosis	Uncommon F > M Age: 50-60 years of age	Pruritus, burning or pain Chronic waxing and waning course	Scattered creamy-yellow pustules and dusky-red macules on soles, with a tendency to affect the heel and instep of the foot; may be bilateral or unilateral
Infectious			
Tinea pedis	Common M > F Age: post-puberty	Asymptomatic or pruritic Lasts months to years Associated with onychomycosis	<i>Interdigital type:</i> dry scaling and/or maceration, peeling, and fissuring in toe webs (Figure 10-9) <i>Moccasin type:</i> well-demarcated erythematous patch with fine, white uniform scale on soles and sides of feet (Figure 10-10) <i>Inflammatory/bullous type:</i> vesicles or bullae containing clear fluid, erosions on the soles (Figure 10-11)
Cellulitis	Common M = F Age: any age, but occurs more commonly on the feet in adults	Pain swelling, fever, malaise, and chills Increased risk in diabetic patients and patients with fissures on their feet	Localized erythema, warmth, swelling, and tenderness with ill-defined borders (Figure 12-3)
Warts	Common M > F Age: more common in children and young adults	Asymptomatic or painful. May persist for years	Discrete or confluent hyperkeratotic papules or plaques on soles. May have black or brown dots within the lesions created by thrombosed capillaries (Figure 11-7)

F, females; M, males.

Skin Diseases Involving Multiple Body Regions

Noah Goldfarb
Steven W. Lin

37

Introduction to Chapter / 285
Approach to Diagnosis / 285

Evaluation / 285

INTRODUCTION TO CHAPTER

Many common diseases such as atopic dermatitis, psoriasis, drug rashes, urticaria, viral exanthems, bug bites, and vitiligo present with lesions in multiple body regions. Less common disorders such as syphilis, erythema multiforme, Stevens–Johnson syndrome/toxic epidermal necrolysis, the immunobullous diseases, cutaneous T-cell lymphomas, and connective tissue disorders also present in multiple body locations.

APPROACH TO DIAGNOSIS

Skin diseases affecting several anatomic sites simultaneously are listed in Table 37-1. Lesion distribution is frequently a very important clue to the diagnosis. For example, atopic dermatitis typically involves the flexor extremities, specifically the popliteal and antecubital fossae, whereas psoriasis vulgaris usually involves the elbows, knees, and extensor surfaces. It is still unclear why certain diseases have a predilection for specific anatomic locations.

Diffuse erythematous patchy (scarlatiniform) or maculopapular (morbilliform) eruptions are typically due to a medication reaction or viral exanthem. Clinically these conditions may appear indistinguishable, but a thorough history is often helpful in differentiating them. Inflammatory disorders, such as atopic dermatitis, contact dermatitis, and psoriasis, may also be diffusely distributed but these conditions have more epidermal changes with scaling and usually have accentuation in specific characteristic locations. Bullae are the primary lesions associated with bullous drug eruptions and autoimmune bullous

dermatoses. Bullous drug eruptions have a wide spectrum of clinical presentations, ranging from single fixed bullae to widespread bullae and skin sloughing, seen with toxic epidermal necrolysis. The immunobullous dermatoses are a group of antibody-mediated conditions that present with either flaccid or tense bullae depending on whether the autoantigens are located in the epidermis (ie, pemphigus vulgaris) or below the epidermis (ie, bullous pemphigoid), respectively. Unlike patients with tense bullae, those with flaccid lesions may lack bullae altogether and present only with crusted erosions with a surrounding edge of scale. If flaccid bullae are present, they will classically have a positive Nikolsky sign.

EVALUATION

- Most inflammatory skin diseases, such as atopic dermatitis, nummular dermatitis, and psoriasis, can be diagnosed clinically, but any inflammatory dermatosis that has an atypical presentation or does not respond to appropriate treatment may require serial biopsies to verify the correct diagnosis and exclude the diagnosis of cutaneous T-cell lymphoma.
- Potassium hydroxide (KOH) examination and/or fungal cultures should be performed for any rash with annular scaly plaques.
- Skin biopsy should be performed on any patient with erythroderma (>80% body surface area of erythema and scaling).
- Skin biopsy should be performed for any bullous dermatosis at the edge of the bullae for routine

histopathologic examination and from adjacent skin for direct immunofluorescence studies.

- Skin biopsy should be performed urgently in any patient with suspected Stevens–Johnson syndrome/toxic epidermal necrolysis to verify diagnosis.
- Viral culture, polymerase chain reaction (PCR), Tzanck smear, or a skin biopsy can be done to verify the diagnosis of herpes zoster.

- Patch testing can be considered for any rash in which allergic contact dermatitis is suspected.

The online learning center at www.LangeClinicalDermatology.com has clinical self-assessment questions for this chapter.

Table 37-1. Differential diagnosis of skin diseases involving multiple body regions.

Disease	Epidemiology	History	Physical Examination
Inflammatory			
Allergic contact dermatitis	Common F > M Age: any age	Pruritic Onset is hours to days after contact with allergen	<i>Acute:</i> papules and vesicles on an erythematous base (Figures 8-4 and 8-5) <i>Chronic:</i> xerosis, fissuring, hyperpigmentation, and lichenification (Figures 8-1 to 8-3) <i>Typical locations:</i> scalp, face, eyelids, earlobes, neck, hands wrists, or feet
Atopic dermatitis	Common M > F Age: usually presents in childhood but may persist	Pruritic Chronic course with exacerbations. Worse in winter. Personal or family history of atopy	<i>Infants:</i> red papules, scaly plaques and excoriations on cheeks, trunk and extensor extremities (Figure 8-7) <i>Children and adults:</i> red lichenified plaques, and excoriations (Figure 8-8) typically on neck, wrists, hands, ankles, feet, and flexor extremities, especially the antecubital and popliteal fossas
Nummular eczema	Common M > F Age: bimodal; peaks in young adults and the elderly	Pruritic Chronic waxing and waning course Associated with dry skin	Round, light pink, scaly, thin, 1-3 cm plaques (Figure 8-11) on trunk and extremities
Prurigo nodularis	Uncommon F > M Can be idiopathic or secondary to other underlying etiology	Pruritic. Persists for months to years. Variable patient insight. May admit to picking and/or scratching lesions	Solitary or multiple discrete well-demarcated dome-shaped hyperpigmented papules or nodules often in variable stages of healing on extensor extremities (Figure 26-2)
Psoriasis	Common M = F Age: any age, but peaks in young adulthood (20s) and middle aged adults (50s)	Asymptomatic to mildly pruritic Chronic. May have arthritis and family history of psoriasis	Red papules and plaques with silvery, thick, adherent scale on scalp, extensor extremities, elbows, knees, genitals, umbilicus, lower back, and retroauricular area (Figures 9-1 to 9-3) Nail pitting/dystrophy
Lichen planus	Uncommon F > M Age: 30-60 years	Pruritic. Lasts months to years May be drug-induced or associated with hepatitis C	Multiple variants; classically flat-topped, well-defined, polygonal, violaceous, shiny papules on volar wrists, shins, glans penis, back, scalp, and buccal mucosa in a symmetric distribution (Figures 9-10 to 9-11)
Erythema multiforme	Uncommon M > F Age: usually in children, adolescents, and young adults	Asymptomatic or pruritic may have associated fevers Recurrence associated HSV infections	Typical target lesions: papules with 3 zones of color on palms, soles, dorsal hands/feet, forearms, face, and genitals (Figures 23-1 and 23-3)

(continued)

Table 37-1. Differential diagnosis of skin diseases involving multiple body regions (Continued).

Disease	Epidemiology	History	Physical Examination
Infectious			
Herpes zoster	Common M:F unknown Age: any age, but usually older than 50 years	Severe pain, pruritus, or paresthesias preceding eruption. Lasts 3-4 weeks	Grouped vesicles on an erythematous base. Usually located on the face or thorax in a unilateral dermatome (Figures 11-3 and 11-4)
Viral exanthem	Common M:F unknown Age: usually in children less than 20 years Enterovirus, more common in the summer months	Asymptomatic or associated with a prodrome of fever, malaise, rhinitis, sore throat, nausea, vomiting, diarrhea, or headache	Scarlatiniform: patchy generalized erythema with desquamation, most prominent in the body folds Morbilliform: macules and papules on the head, neck, trunk, and proximal extremities (Figure 27-9)
Tinea corporis	Uncommon M = F Age: all ages, but more common in children	Asymptomatic or mildly pruritic Associated with hot/humid weather, farming and crowded living conditions	Annular plaque(s) with a scaly, raised well-demarcated border and central clearing on any body location except palms and soles (Figure 10-4)
Syphilis (secondary)	Uncommon M > F Age: 15-40 years	Asymptomatic ulcer usually on glans penis followed weeks to months later by diffuse eruption on trunk Systemic symptoms may be present or shortly precede onset of eruption (fever, malaise, myalgia, and headache) Risk factors: men who have sex with men	<i>Palms/soles:</i> red-brown or ham colored macules or papules ± scale (Figure 12-7) <i>Trunk:</i> multiple diffuse pink macules or scattered, discrete, firm, red, scaly, well-defined papules in symmetrical distribution (Figure 12-6) <i>Scalp:</i> patchy or diffuse alopecia <i>Oral mucosa:</i> mucous patches <i>Anogenital region:</i> moist warty papules (condyloma lata)
Drug rashes and urticaria			
Morbilliform drug eruption	Common F > M Age: any age, but less commonly in children	Asymptomatic or pruritic. Begins 1 day to 3 weeks after taking offending agent. Antibiotics, anticonvulsants, and NSAIDs are the most common causes	Small pink macules and papules starting on the trunk and pressure-bearing areas spreading diffusely with a symmetric distribution on trunk and extremities with prominence in body folds (Figure 14-6)
Stevens-Johnson syndrome (SJS)/toxic epidermal necrolysis (TEN)	Rare M = F Age: any age, but usually adults Increased risk in older patients and those with HIV/AIDS High mortality	Painful 1-14 day prodrome with mucosal irritation The most common offending agents are allopurinol, carbamazepine, lamotrigine, NSAIDs, phenobarbital and sulfonamide, taken within 4 weeks of rash	Erythematous, purpuric, dusky, targetoid macules, and patches that expand and coalesce. Lesions develop necrotic centers and flaccid bullae with a positive Nikolsky sign. Mucous membranes are commonly involved (Figures 24-4 to 24-7) Lesions are widely distributed with prominence on trunk and face
Urticaria	Common M = F Age: any age, but chronic urticaria is more common in adults	Pruritic Individual lesions last less than 24 h. Acute urticaria may last up to 6 weeks	Pink edematous plaques (wheals) with no surface changes such as scales or crust. Can occur on any body area (Figures 14-1 and 14-2)

(continued)

Table 37-1. Differential diagnosis of skin diseases involving multiple body regions (Continued).

Disease	Epidemiology	History	Physical Examination
Bullous disorders			
Bullous pemphigoid	Uncommon M = F Age: 60-80 years	Pruritus with or without blisters	Initially, pruritic urticarial plaques without blisters; later tense bullae arise usually on the trunk and proximal flexural extremities (Figure 22-1). Mucous membrane involvement in <20% of cases
Pemphigus vulgaris	Rare M = F Age: 40-60 years High mortality	Painful blisters and erosions on the skin No pruritus ± Mucous membrane involvement Patients may complain of pharyngitis and/or dysphagia	Painful flaccid bullae with a positive Nikolsky sign and crusted erosions with a wet base usually on head, upper trunk and intertriginous areas (Figure 22-4). Mucosal lesions may involve the oral cavity (Figure 22-5), pharynx, larynx, genitals, esophagus, or conjunctiva
Dermatitis herpetiformis	Uncommon M > F Age: any age, but most commonly 20-60 years	Severe episodic pruritus Associated with a gluten-sensitive enteropathy	Grouped pink crusted papules and erosions on extensor extremities, elbows, knees, buttocks, scalp, and neck in a symmetric distribution (Figure 22-8). Vesicles rarely seen due to excoriation
Connective tissues disease			
Generalized acute cutaneous lupus erythematosus	Uncommon F > M Age: any age, but most commonly 30-40 years of age. Associated with systemic lupus erythematosus (SLE). High morbidity	Pruritus or burning Duration: weeks to months Maybe related to sun exposure Associated with fevers, fatigue, oral ulcers, and other systemic findings consistent with SLE	Red clustered papules, urticarial plaques, and patchy erythema with variable scale Typical locations: photosensitive distribution, involving the forehead, malar eminence, bridge of the nose, neck upper chest and dorsal hands, classically sparing the skin overlying the joints (Figure 24-5)
Dermatomyositis	Rare F > M Age: bimodal; peaks at ages 5-10 and 50 years of age Associated with malignancy in approximately 20% of adult cases	Asymptomatic or pruritic Chronic course Associated with photosensitivity, scalp pruritus/burning and symmetric proximal muscle weakness	Macular violaceous erythema located periorbitally (heliotrope sign), chest, lateral thighs, back, and shoulders. Flat-topped violaceous papules (Gottron's papules) overlying the knuckles and interphalangeal joints as well as elbows and knees Periungual erythema may be present (Figure 24-6)
Neoplastic			
Mycosis fungoides (cutaneous T-cell lymphoma)	Uncommon M > F Age: usually in middle-aged adults	Asymptomatic or mild pruritus Onset: months to years with chronic course Very slow or absent disease progression	Well-defined eczematous or psoriasiform patches and plaques that may progress to thicker plaques, nodules, or erythroderma usually distributed asymmetrically with a predilection for sun-protected sites, especially the buttocks
Pigmentation			
Vitiligo	Common M = F Age: any age	Asymptomatic Chronic course Personal or family history of autoimmune disease	Well-demarcated depigmented macules and patches typically on dorsal hands, ventral wrists, extensor forearms, genitals and face, favoring the perioral and periocular regions (Figures 21-1 and 21-2)

(continued)

Table 37-1. Differential diagnosis of skin diseases involving multiple body regions (Continued).

Disease	Epidemiology	History	Physical Examination
Other			
Bug bites	Common M = F Age: any age, but usually in childhood, adolescents, and young adulthood	Pruritic Most are aware of bug bites, but when the reaction is delayed or occurs during sleep patients may not know they were bitten	Erythematous papules, bullae, or urticarial plaques (Figure 14-5). Typically located on exposed sites such as the head, neck, lower legs, and arms
Scabies	Common M = F Any age, but more common in children	Intense pruritus. Chronic symptoms until treated	Multiple excoriated papules on finger webs, volar wrist, flexural areas, elbows, knees, and genitals (Figures 13-1 to 13-5)
Granuloma annulare	Common F > M Age: children and young adults, but depends on the type. Several variants exist	Asymptomatic Lasts months to years. May cause aesthetic concern. Recurrence is common	Skin colored or erythematous papules generally without surface change, solitary or multiple on extensor extremities and dorsal hands and feet (Figure 24-9)

F, females; HSV, herpes simplex virus; M, males; NSAIDs, nonsteroidal anti-inflammatory drugs.

38

Diseases of the Oral Cavity

Ioannis G. Koutlas

Introduction to Chapter / 290
Ulcerated Lesions / 290
Vesicubullous Lesions / 293
Maculopapular Lesions / 298

Papillary, Exophytic, or Fungating Lesions / 307
Nodular or Polypoid Lesions / 309
Pigmented Lesions / 310
References / 313

INTRODUCTION TO CHAPTER

Many dermatologic conditions, inflammatory, immunologic, infectious, or neoplastic, can also occur in the oral mucosa, with essentially similar clinicopathologic features. Occasionally, the mouth is the sole manifestation of a dermatologic condition as in the case with lichen planus and mucous membrane pemphigoid. There are also common conditions that are unique to the oral mucosa, such as recurrent aphthous stomatitis (canker sores) and geographic tongue. In this chapter, the reader will be introduced to the clinical characteristics, differential diagnosis, and management of common oral conditions.

Anatomy of the Oral Cavity

With the exception of the posterior one-third of the tongue, which is of endodermal origin, the epithelium that lines the oral mucosa derives mostly from ectoderm. In contrast to the skin, the oral epithelium exhibits different patterns of keratinization. For example:

- The masticatory mucosa (hard palate, gingiva, and alveolar mucosa) has keratinized or parakeratinized (retained nuclei in the stratum corneum) squamous epithelium.
- The tongue has parakeratinized, nonkeratinized, and specialized epithelia (papillae).
- The buccal mucosa and vestibule have nonkeratinized stratified or parakeratinized squamous epithelia, respectively.

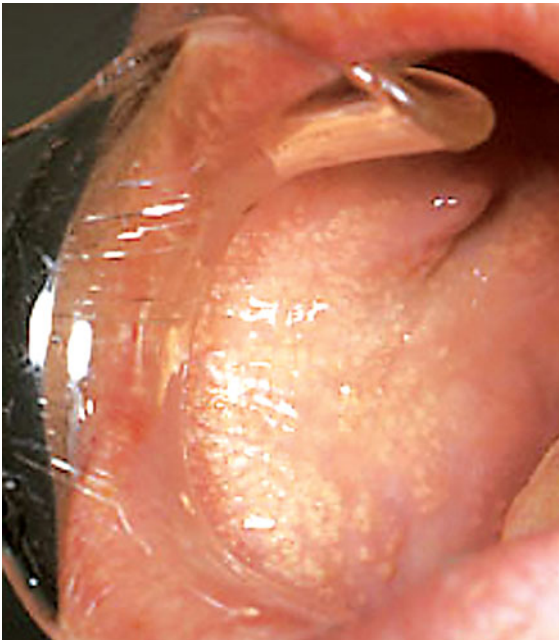The supporting connective tissue is of ectomesenchymal origin. Adnexal elements are not present in the connective tissue of the oral mucosa, with the exception of sebaceous glands, known as Fordyce granules/spots (Figure 38-1), which are present in 70% to 90% of individuals. However, the mouth has 800 to 1000 lobules of minor salivary glands, with the exception of the gingiva and the anterior aspect of the hard palate.

Categories of Oral Diseases

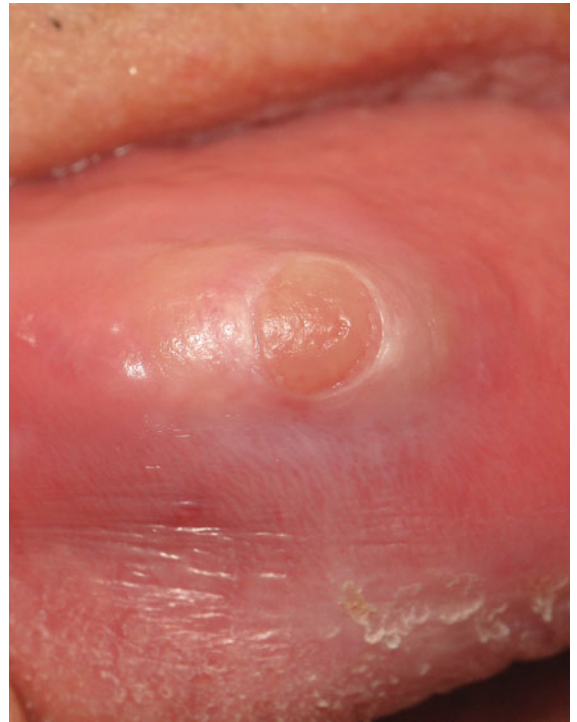
Clinically, oral lesions can be (1) ulcerated, (2) vesicubullous, (3) maculopapular, (4) exophytic, papillary, or fungating, (5) nodular or polypoid, and (6) pigmented. Special attention should be given to lesions that are white (leukoplakic), or red (erythroplakic) patches or a mixture of the two (erythroleukoplakic) and lesions that are gray, black, or brown, as these lesions may be malignant or premalignant.

ULCERATED LESIONS

Oral ulcers have various etiologies, which include trauma, immunologic diseases, infections (bacterial, deep fungal, or viral), and neoplasms (squamous cell carcinoma, lymphoma, malignant salivary gland tumors, etc.). They are generally painful, except for squamous cell carcinoma, which may be asymptomatic, when it presents as an ulcer.



▲ **Figure 38-1.** Intraoral sebaceous glands (Fordyce granules). Small yellow papules on the vestibule and buccal mucosa.



▲ **Figure 38-2.** Traumatic ulcer on the lower lip.

Traumatic Ulcers

► Introduction

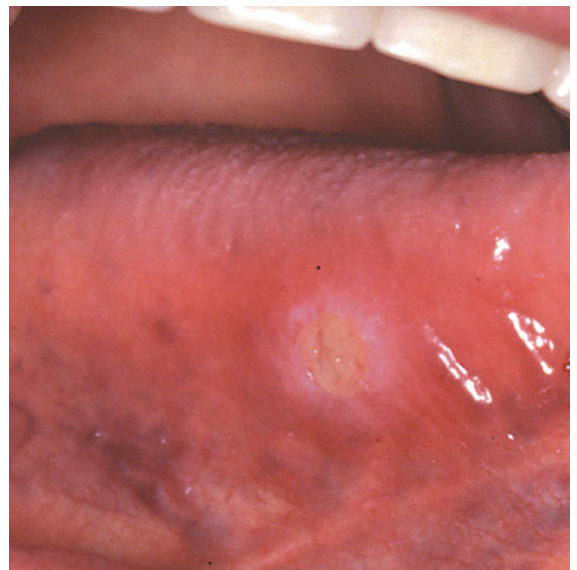Traumatic ulcers are usually the result of physical injury (eg, accidental biting during mastication, contact with sharp or broken cusps of teeth, and sharp food), and less often, thermal or chemical burn (eg, chemicals used during dental or surgical procedures, aspirin, alcohol, peroxide, and other acidic substances). Rarely, electrical injury can occur, especially in very young children who accidentally chew on an electrical wire.

► Clinical Presentation

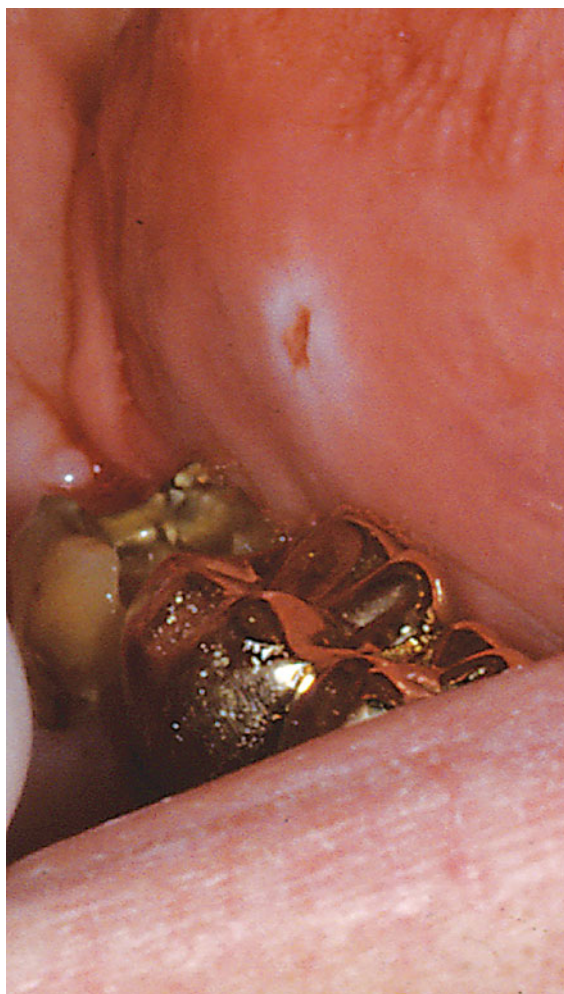
Traumatic ulcers frequently affect the tongue, lips, and buccal mucosa (Figures 38-2 to 38-4) and in cases of vigorous tooth brushing, small and often multiple ulcerations can occur on the gingiva. In general, traumatic ulcers present as round, ovoid or irregular, erythematous lesions usually covered by a pseudomembrane and surrounded by a white border that represents reactive epithelial regeneration.

► Management

Traumatic ulcers heal after removal of the cause and depending on the size and the location; they usually heal within 1 to 2 weeks. Over the counter topical dyclonine



▲ **Figure 38-3.** Traumatic ulcer on the tongue covered by pseudomembrane.



▲ **Figure 38-4.** Traumatic ulcer on the tongue. Round white rim indicating epithelial hyperplasia and regeneration. This ulcer was caused by trauma due to adjacent broken molar cusp.

hydrochloride, hydroxypropyl cellulose, lidocaine, or benzocaine can relieve the pain associated with ulcerations. Treatment with topical corticosteroids (gels are preferred over creams and ointments since they adhere better to the oral soft tissues) can be used in some instances. Chronic large ulcers may require topical steroids. Ulcers of the tongue may take more time to resolve due to the unique nature and composition of the tongue, which is, a movable muscle. Ulcerated lesions that last longer than 3 weeks without an obvious etiology should raise a clinician's suspicion of neoplasia, and these lesions should be biopsied with incisional or excisional techniques.

Recurrent Aphthous Stomatitis (RAS)

► Introduction

Recurrent aphthous stomatitis (canker sores) is one of the most common oral mucosal lesions presenting with one or multiple ulcers NOT preceded by vesicles or bullae.¹ RAS affects between 5% and 60% (mean 20%) of people with a predilection for females, caucasians, and children of higher socioeconomic status.

Many predisposing factors have been implicated with the development of RAS. In some patients there is genetic predisposition with certain HLA types. Hypersensitivity to certain foods such as citrus fruits, chocolate, coffee, gluten, nuts, strawberries, tomatoes, medications (eg, nonsteroidal anti-inflammatory drugs [NSAIDs], and beta blockers), sodium lauryl sulfate in toothpastes, smoking cessation, stress, trauma, infectious agents (eg, *Helicobacter pylori*, herpes simplex, and streptococci), and female hormonal changes have been associated with development of RAS.

Systemic diseases presenting with oral ulcers akin to RAS include nutritional deficiencies (iron, folate, and vitamin B complex), IgA deficiency, Behçet's disease, Sweet's syndrome (acute neutrophilic dermatosis), PFAPA syndrome (periodic fever, aphthae, pharyngitis, and cervical adenitis), inflammatory bowel disease, reactive arthritis (Reiter syndrome, cyclic neutropenia, and AIDS).

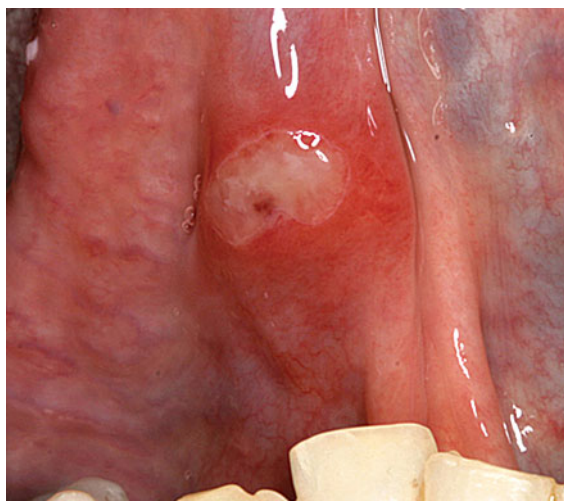► Clinical Presentation

RAS ulcers are mostly round or ovoid and generally painful. They are usually covered by a pseudomembrane and surrounded by an erythematous halo. There are three types of aphthae, minor, major, and herpetiform.

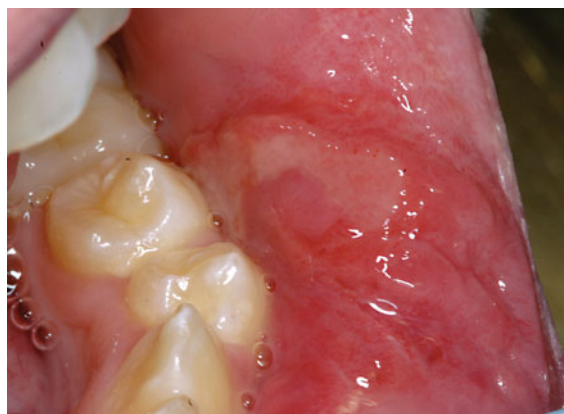- Minor aphthae (Figure 38-5) are the most common form of RAS and typically present with recurring episodes of 1 to 5 small ulcers, less than 1 cm in greatest diameter. They predominantly affect the nonmasticatory mucosa and are usually seen in the anterior part of the mouth. They last 7 to 14 days, if left untreated.
- Major aphthae (Figure 38-6) are larger, deeper, last longer (2 to 6 weeks) and are very painful. Major aphthae are most frequently seen on the lips and the posterior oropharynx.
- Herpetiform RAS (Figure 38-7) is characterized by as many as 50 to 100 small ulcers and may clinically resemble ulcers of primary herpes simplex, thus the confusing term "herpetiform." Recurrences are usually closely spaced and lesions, although favoring the nonmasticatory mucosa, can be seen throughout the mouth.

► Management

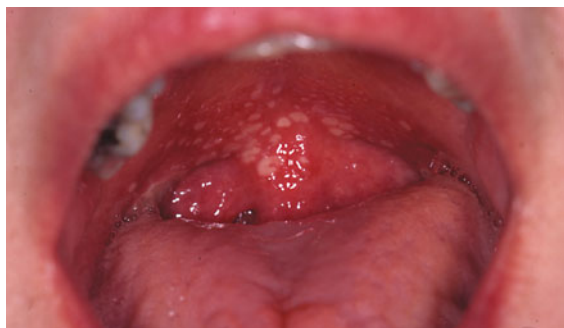The treatment for RAS depends on the extent and degree of pain of the lesions. Some patients can tolerate the lesions and associated pain, but other patients have difficulty eating



▲ **Figure 38-5.** Recurrent aphthous stomatitis, minor aphtha.



▲ **Figure 38-6.** Recurrent aphthous stomatitis, major aphtha.

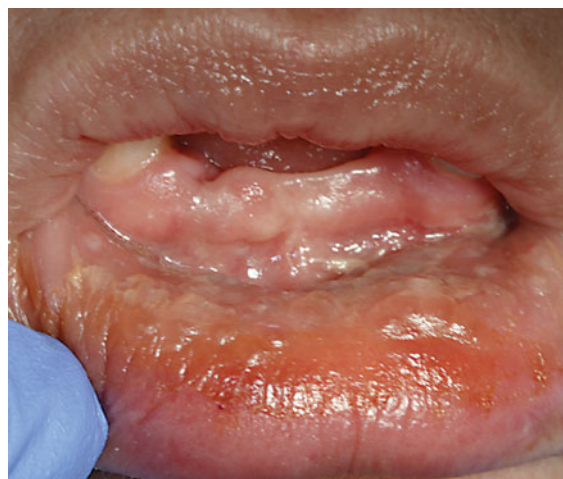

▲ **Figure 38-7.** Recurrent aphthous stomatitis, herpetiform type. Multiple small ulcers on palate.

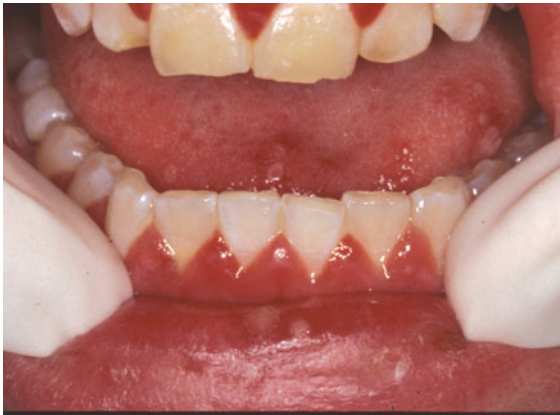or even functioning during episodes. Over the counter topical anesthetics or protective bioadhesive products such as Orajel, Orabase, and Zilactin may be of some benefit. Fluocinonide or betamethasone dipropionate 0.05% gels can be used topically 2 to 3 times a day. They should be applied to early lesions at the onset of prodromal pain and tingling. Steroid solutions, such as dexamethasone 0.5 mg/5 mL, and prednisolone or betamethasone syrups may be used in patients who have widespread lesions. In hard to reach areas, such as tonsillar pillars, beclomethasone dipropionate aerosol spray can be used as an alternative. Systemic steroids can be used in patients with very painful major aphthae and in herpetiform lesions. Occasionally, systemic steroids are used in conjunction with topical steroids. RAS that does not respond to steroids should be referred to specialists who may prescribe dapsone, tacrolimus, thalidomide, tetracycline, levamisole, MAO inhibitors, and other medications as alternatives to steroids. Cauterization with silver nitrate and laser ablation are not recommended. Besides using medications to treat RAS, the clinician should review the eating habits of patients, which may be contributing to RAS. If indicated, an evaluation should be done for systemic diseases, which could be related to RAS.

▼ VESICULOBULLOUS LESIONS

Vesiculobullous lesions of the oral mucosa may be due to trauma, allergic reactions (Figure 38-8), infections (herpes simplex or zoster), or immune-mediated disease (pemphigus vulgaris and mucous membrane pemphigoid). Intact vesicles are rarely identified and generally vesiculobullous processes manifest as erosions and ulcerations as most blisters rupture spontaneously. Therefore, a clinician should specifically ask about the presence or absence of oral blisters when evaluating a patient with oral erosions and ulcerations.



▲ **Figure 38-8.** Vesiculobullous allergic contact reaction on lower lip.



▲ **Figure 38-9.** Primary herpetic gingivostomatitis. Small ulcers on the lower lip and tongue in association with erythematous and edematous gingiva.

Primary and Secondary Herpes Simplex (HSV)

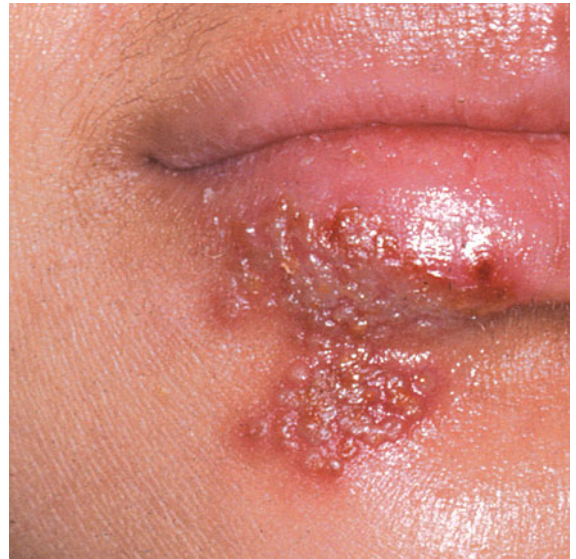► Introduction

Oral HSV is generally due to HSV type I.² In rare cases, HSV type II may be the cause due to orogenital sexual contact. Primary infection by herpes simplex presents as gingivostomatitis (Figure 38-9). Direct contact with an asymptomatic individual shedding the virus in saliva, or with a person with recurrent infection such as herpes labialis are modes of transmission. The vast majority of individuals without antibodies against HSV type I, when infected, do not have clinical symptoms or signs. After the primary infection, the virus is transported to sensory or autonomic ganglia where it remains in a latent state.

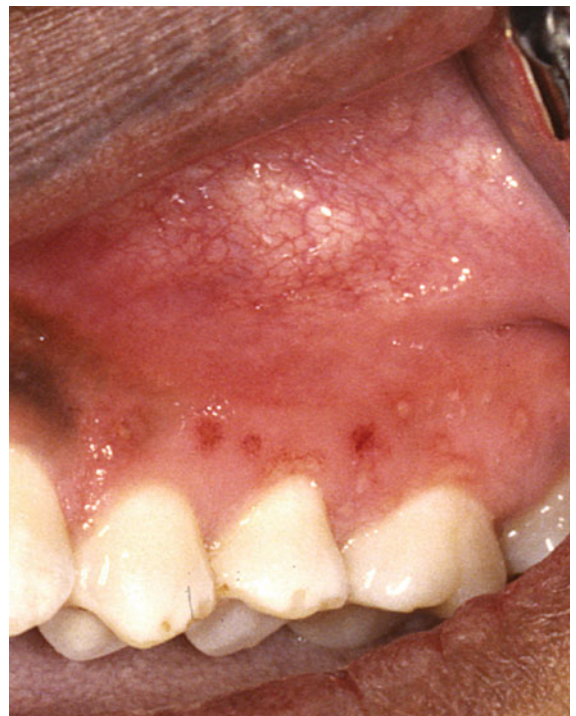Reactivation of the virus is responsible for recurrent disease which usually affects the lips (herpes labialis or cold sore) (Figure 38-10) or, intra-orally on the hard palate or gingiva (Figure 38-11). Perioral lesions may also occur on the skin of the nose, cheek, or chin. Triggering factors include immunosuppression, menstruation, stress, ultraviolet light, and local trauma. Prodromal symptoms (burning, itching, or tingling) occur in many patients.

► Clinical Presentation

Primary HSV infection may present as acute gingivostomatitis in children and adolescents with multiple, 1 to 2 mm vesicles that rapidly rupture to form multiple small red, white, or yellow ulcerations throughout the mouth (Figure 38-9). The lips of the patients become crusted with serum and blood, and the gingivae are edematous and erythematous and covered with small ulcers. Patients may also



▲ **Figure 38-10.** Herpes labialis. Grouped vesicles on an erythematous base.



▲ **Figure 38-11.** Recurrent intraoral herpes of the maxillary gingiva.

have anterior cervical lymphadenopathy, chills, high fever (103 to 105°F), nausea, and irritability. Self-inoculation to the fingers, eyes, and genitals can occur. Older patients with primary disease may have pharyngotonsillitis. Recurrent herpes labialis presents as coalescing vesicles that rupture and subsequently crust. Without treatment complete healing occurs after 1 to 2 weeks. Intraoral recurrent herpes presents as small shallow and coalescing yellowish-white or erythematous ulcers preceded by vesicles that heal within 1 to 2 weeks.

Reactivation in immunocompromised patients such as HIV-positive³ and transplant patients may lead to a chronic herpetic infection that is persistent and characterized by atypical lesions that can mimic major aphthae or necrotizing stomatitis. In some patients these atypical ulcers harbor also cytomegalovirus co-infection. These patients should be referred to specialists for evaluation to confirm the diagnosis and to infectious disease specialists for management.

► Management

Pediatric primary infections can be treated with palliative topical rinsing with 0.5% to 1% dyclonine hydrochloride and if needed with acyclovir suspension during the first 3 symptomatic days in a rinse-and-swallow mode (15 mg/kg or up to the adult dose of 200 mg daily for 5 days).

If needed, oral medications for primary and recurrent herpes simplex can be used. Table 38-1 lists selected treatment options for adolescents and adults. Topical medications are also available (Table 38-2).

Table 38-1. Oral medications for primary and recurrent oral-labial herpes simplex in adults and adolescents.

Medication	Brand Name Examples	Selected Dosing Options	Duration (Days)
Acyclovir	Zovirax	Primary: 400 mg 3 times a day	7-10
		Recurrent: 800 mg twice a day	5
Famciclovir	Famvir	Primary: 250 mg 3 times a day	7-10
		Recurrent: 1500 mg one dose	1
Valacyclovir	Valtrex	Primary: 1000 mg twice a day	7-10
		Recurrent: 2000 mg every 12 h	1

Table 38-2. Topical medications for recurrent herpes simplex.

Medication	Brand Name Examples	Dosing	Duration (Days)
Acyclovir 5% ointment	Zovirax	Apply every 3 h, 6 times a day	7
Docosanol 10% cream Nonprescription	Abreva	5 times a day	Up to 10
Penciclovir 1% cream	Denavir	Every 2 h while awake	4

Varicella (Chickenpox) and Herpes Zoster (Shingles)

► Introduction

Varicella and herpes zoster are caused by the varicella-zoster virus (VZV). Varicella is the primary infection and patients present primarily with cutaneous lesions; however, oral lesions are not uncommon and may precede the skin lesions. Vesicular lesions usually appear on the lips and the palate and in contrast to primary herpes are generally painless. VZV establishes latency in the dorsal spinal ganglia.

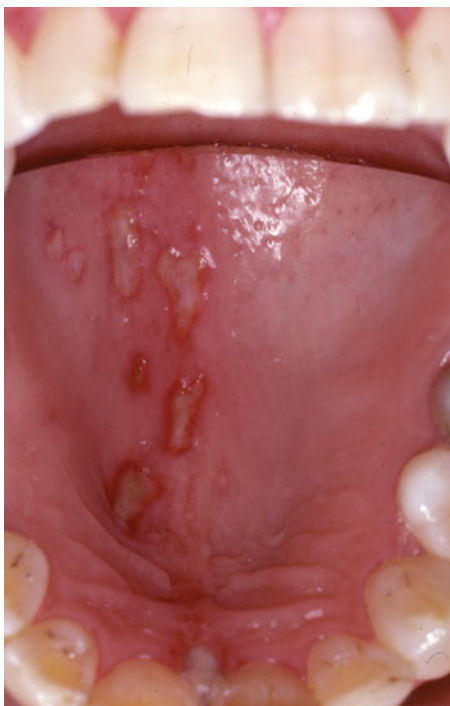Herpes zoster is the reactivation of VZV. The prevalence increases with age and occurs in 10% to 20% of infected individuals. Most affected patients have a single episode. Predisposing factors include stress, immunosuppression, treatment with cytotoxic medications, presence of malignancies, and older age. For head and neck cases, dental manipulation may be the trigger.

► Clinical Presentation

The lesions of herpes zoster can affect the face and oral mucosa unilaterally and follow the path of the involved nerve (Figure 38-12). Since affected nerve endings can cross the midline, a few lesions can be seen on the other side of the midline. Patients present with very small vesicles that rupture and leave behind shallow painful ulcerations. Occasionally if the maxilla is involved, tooth necrosis and in rare cases bone necrosis can occur.

► Management

Treatment for herpes zoster should begin as soon as the diagnosis is established. Valacyclovir 1 g 3 times a day for 7 days or famciclovir 500 mg 3 times a day for 7 days or acyclovir 800 mg 5 times a day for 7 days are the drugs of choice. Analgesics and antiepileptics (gabapentin and carbamazepine) and tricyclic antidepressants can be used for pain relief. Also oral corticosteroids are sometimes prescribed to older, immunocompetent patients (with no contraindications to steroids) to decrease the incidence of postherpetic neuralgia.

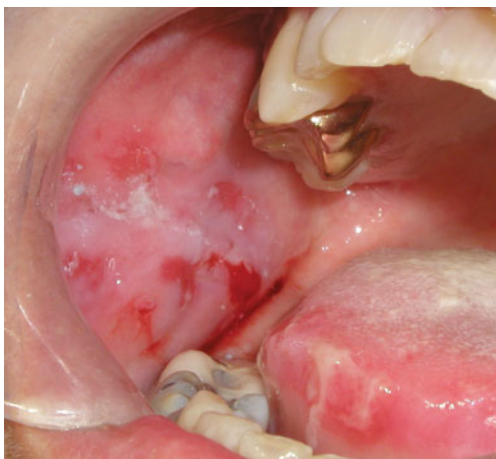

▲ **Figure 38-12.** Herpes zoster. Erosions in the mouth.

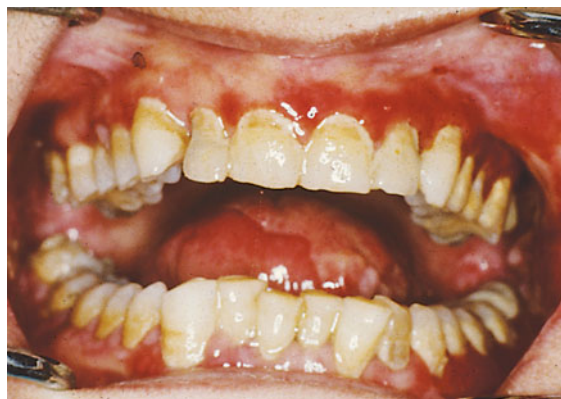Mucous Membrane Pemphigoid (MMP) and Pemphigus Vulgaris (PV)

► Introduction

Mucous membrane pemphigoid⁴ and pemphigus vulgaris⁵ are uncommon immunologic vesiculobullous diseases that can have oral manifestations. MMP (Figure 38-13), also



▲ **Figure 38-13.** Benign mucous membrane pemphigoid affecting the tongue, buccal mucosa, and palate.



▲ **Figure 38-14.** Pemphigus vulgaris. Widespread oral lesions.

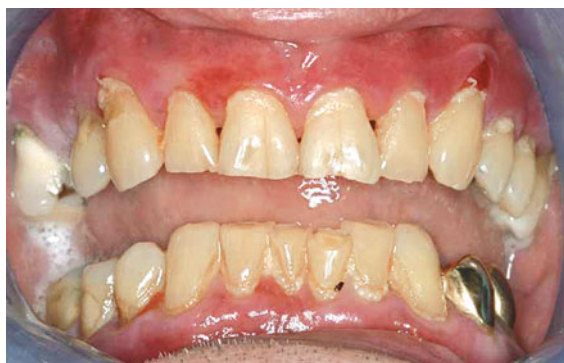known as cicatricial pemphigoid, generally involves only the mouth which is in contrast to bullous pemphigoid (the most common type of cutaneous pemphigoid) rarely presents with oral manifestations.

► Clinical Presentation

In PV (Figure 38-14), oral lesions may be the “first to show and last to go” and oral mucosal involvement is seen in almost all cases. Lesions present as painful erosions or ulcerations preceded by vesicles. If intact vesicles are seen, MMP is more likely the diagnosis. This is because the vesicles in MMP are subepithelial and thus more deeply seated, in contrast to the vesiculobullous process in PV that is intraepithelial. Patients with PV rarely present with intact vesicles. It is important for the clinician to question the patient about a history of vesicles or bullae when multiple shallow ulcerations are identified in the mouth. Also, in patients presenting with PV, but more importantly with MMP, synchronous or metachronous ocular involvement may occur leading to scarring of the conjunctiva.

When the gingiva is involved in MMP and PV, the clinical presentation is that of mucosal sloughing and erosions. This is referred to as desquamative gingivitis and diffuse erythematous lesions covering most, if not all of the gingiva can occur (Figure 38-15). Desquamative gingivitis is a clinical descriptive term and not a diagnosis. In order of frequency, the underlying condition can be erosive lichen planus, MMP or pemphigus.⁶ Patients with oral PV can present occasionally with multiple shallow ulcerations of the free gingiva (Figure 38-16). Such lesions can persist after successful treatment of all other mucocutaneous lesions and achieving resolution is difficult.

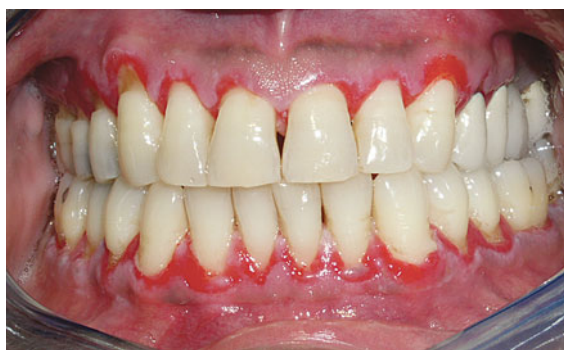In the differential diagnosis of immunologically mediated oral vesiculobullous and ulcerative processes one should include erythema multiforme, hypersensitivity reactions, angina bullosa hemorrhagica, linear IgA disease, and rarely, bullous lichen planus.



▲ **Figure 38-15.** Mucous membrane pemphigoid presenting as desquamative gingivitis.

► Management

Treatment for MMP depends on the severity of lesions and the areas affected. Topical steroids including fluocinonide, betamethasone dipropionate, or clobetasol propionate 0.05% gels may be used for mild disease. For widely distributed lesions, dexamethasone 0.5/5 mL rinse may be prescribed. Secondary candidiasis may develop as a side effect to topical corticosteroid treatment and can be treated with oral antifungal medications. Systemic therapy is typically required and is usually managed by a team approach with clinicians in clinical oral pathology, dermatology, and ophthalmology. These specialists often use systemic treatment with prednisone in more severe cases. Other systemic medications for the treatment of MMP include azathioprine, dapsone, and mycophenolate mofetil. Combination treatment for MMP with tetracycline 1 to 2 g/day and nicotinamide 1 to 2 g/day has been used as alternative to corticosteroids and the other immunosuppressive agents. For patients with gingival manifestations, excellent dental hygiene is important for good results. Also, the fabrication of customized trays by the patient's dentist as a vehicle for better delivery is recommended.



▲ **Figure 38-16.** Pemphigus vulgaris. Erosive lesions on the free gingiva.

Treatment for oral lesions of PV is more complicated since the disease is widespread. Systemic treatment should start immediately after the diagnosis is established. Ideally, a patient with pemphigus should be treated by a physician with expertise in immunosuppressive therapy. Combination of systemic corticosteroids and immunosuppressive drugs such as azathioprine is chosen in many cases. Topical steroids may be used for persistent oral lesions.

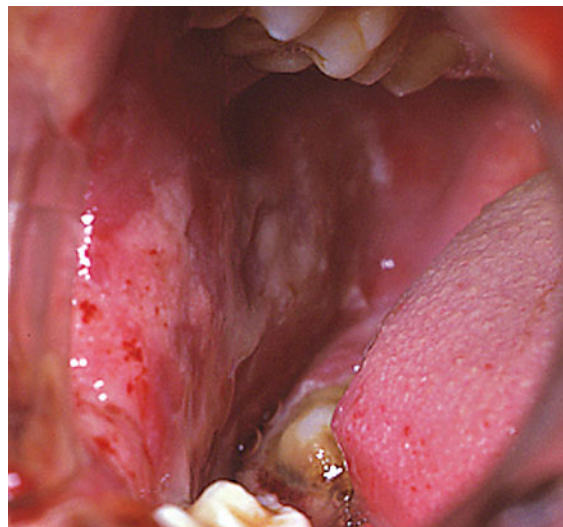
Erythema Multiforme (EM) and Stevens-Johnson Syndrome/Toxic Epidermal Necrolysis (SJS/TEN)

► Introduction

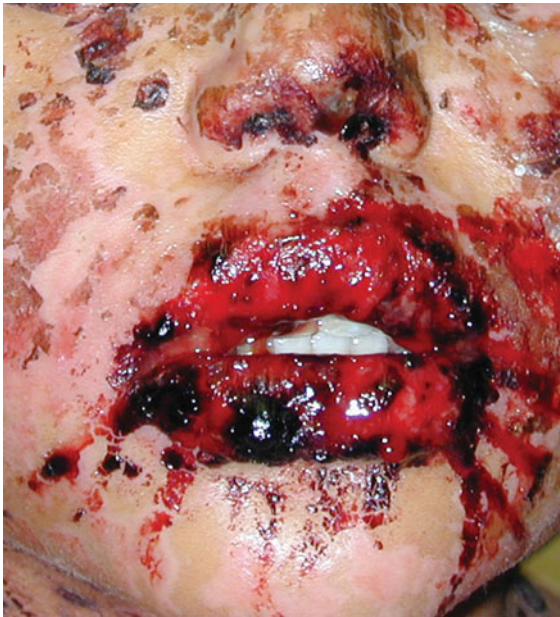EM and SJS/TEN present with oral and cutaneous lesions.⁷ EM usually affects teenagers and young adults and is typically triggered by a herpes simplex infection or it may be caused by medications including antibiotics or anticonvulsants. SJS/TEN is commonly caused by medications and less commonly by infections. Chapter 23 has detailed information about these conditions.

► Clinical Presentation

Oral lesions may precede or be concomitant with skin lesions, which present as erythematous papules and macules frequently having a target or targetoid appearance. EM and SJS/TEN have an acute onset and may be accompanied by malaise, fever, headache, and sore throat. In most patients the lesions usually occur in the nonmasticatory mucosa, the anterior part of the mouth with the gingiva, and hard palate being relatively spared. Oral lesions (Figure 38-17) usually start as erythematous patches, with



▲ **Figure 38-17.** Erythema multiforme. Oral ulcerations.



▲ **Figure 38-18.** Toxic epidermal necrolysis. Multiple erosions with blood-crusted lips.

or without vesicle formation, which ulcerate leaving extensive and painful erosions and ulcerations covered by pseudomembrane, as well as areas of necrosis. Many patients present with blood-crusted lips, which is a useful clinical sign (Figure 38-18). Besides oral and cutaneous lesions, patients can have genital, pharyngolaryngeal, esophageal, and bronchial lesions.

► Management

It is important to identify any potential medication causes and treat any infection that may have caused EM or SJS/TEN. Patients with EM usually need just supportive care similar to that for the ulcerative disorders in this chapter. More severe cases may need systemic prednisone. Patients with suspected SJS/TEN should be referred for specialty care. Extensive oral and cutaneous involvement should be managed in a hospital setting, preferable in a burn unit. Patients with EM can usually be managed as outpatients with supportive care. See Chapter 23 for further information on management.

▼ MACULOPAPULAR LESIONS

There is a wide variety of lesions that can present intra-orally as macules, papules, or a combination thereof. Lesions with such patterns include geographic tongue, candidiasis, lichen planus/lichenoid lesions, leukoplakia, erythroplakia, and squamous cell carcinoma.

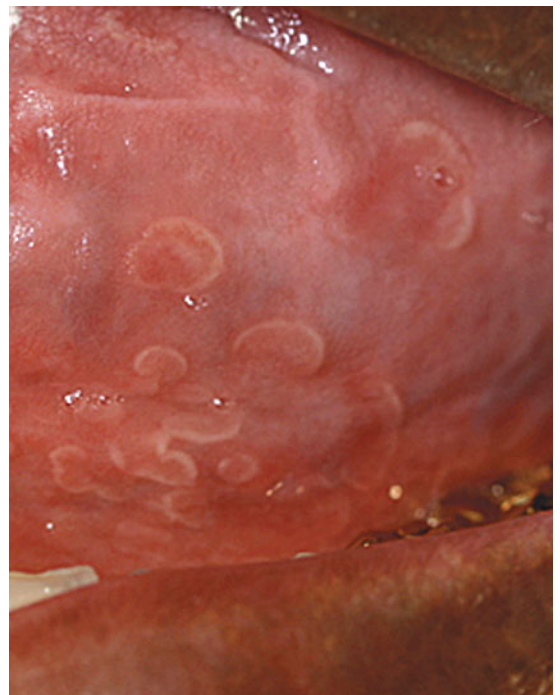Geographic Tongue (Migratory Glossitis and Migratory Stomatitis)

► Introduction

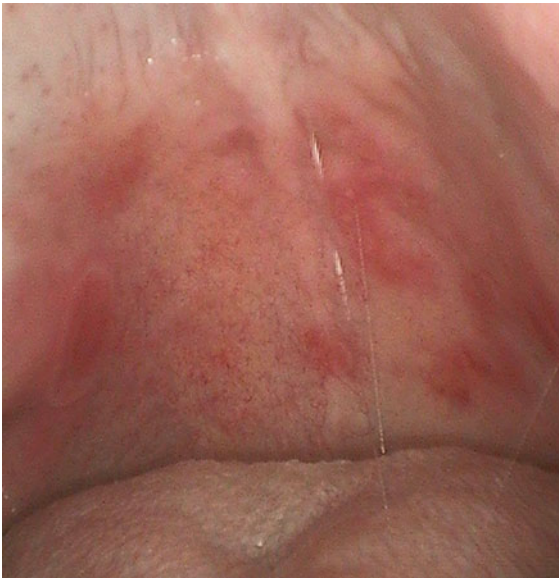Geographic tongue⁸ is a common inflammatory disorder of primarily the tongue occurring in approximately 1% to 3% of the population. Some studies have shown increased prevalence in women. There is apparently a genetic predisposition and in some patients there is a family history. Lesions of geographic tongue may be encountered in patients with psoriasis and, according to studies, patients with psoriasis are up to four times more frequently affected than otherwise healthy patients.⁹ However, this association is not confirmed but other investigators.¹⁰ Other conditions that have shown an increased prevalence of geographic tongue include diabetes mellitus, reactive arthritis (Reiter's syndrome), and Down syndrome. Allergies, hormonal disturbances, and stress have also been associated with an increased prevalence of geographic tongue.

► Clinical Presentation

Clinically, geographic tongue is characterized by a single or frequently several erythematous lesions occasionally surrounded by a white or yellow line representing epithelial hyperplasia (Figure 38-19). They vary in size and change



▲ **Figure 38-19.** Geographic tongue. Multiple areas of erythema with a white border on ventral tongue.



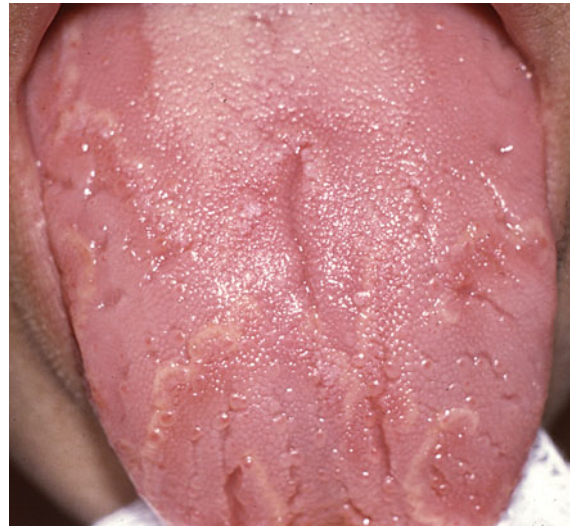▲ **Figure 38-20.** Migratory stomatitis. Erythematous lesions on the hard palate.

shape and size, sometimes within hours. Lesions typically occur on the dorsum and ventral surfaces of the tongue, extending occasionally to the lateral aspects. When the dorsum of the tongue is affected, there is loss of lingual papillae. Symptomatic depapillation of the tongue may also be seen in anemia (eg, iron deficiency, pernicious), candidiasis, or diabetes mellitus. Thus, such conditions should be excluded in symptomatic cases that have clinically the appearance of geographic tongue.

In rare occasions lesions can be found in other parts of the mouth such as the buccal mucosa and the palate (Figure 38-20). However, these patients almost always have lesions on the tongue. In addition, lesions of migratory glossitis are often seen in conjunction with deep fissures on the tongue dorsum (fissured tongue) (Figure 38-21). Occasionally, patients report lesion-free periods.

► Management

The lesions of geographic tongue are generally asymptomatic; however, tingling or burning sensation may be reported in association with spicy or acidic foods or brushing of the tongue with toothpaste. Other than reassuring the patient on the benign nature of geographic tongue, treatment is not necessary. For symptomatic patients, especially those who complain of burning sensation or pain, topical fluocinonide 0.05% gel may be used. Also there are case reports advocating the use of zinc sulfate 200 mg 3 times/day or vitamin B complex supplementations. A diagnostic biopsy may be performed in cases of inability to exclude geographic tongue from other conditions that may share similar clinical features including erythroleukoplakia.



▲ **Figure 38-21.** Geographic and fissured tongue. Multiple areas of erythematous plaques with white border.

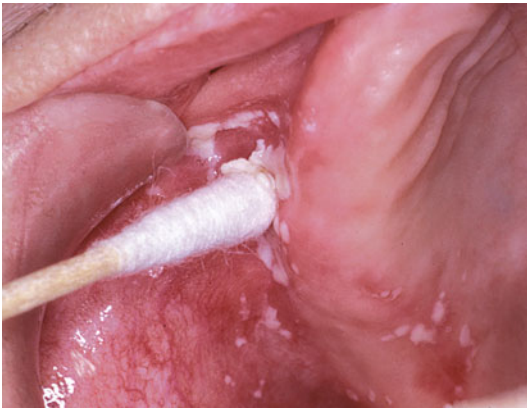Candidiasis

► Introduction

Candidiasis of the oral mucosa is caused by *C. albicans* which presents in two forms, yeast and hyphae, the former being generally innocuous while the latter can invade the host tissue.¹¹ Other forms of *Candida* that can be identified in the mouth, however, far less frequently, include *C. glabrata*, *C. tropicalis*, *C. krusei*, *C. parapsilosis*, and *C. dubliniensis*. Among all fungal infections, oral candidiasis is by far the most common. The organism is present in the mouth of 30% to 50% of individuals without causing disease and its presence in the mouth increases with age. Factors that have been associated with the development of clinical disease include the immune status of the host, the strain of *Candida*, and the environment of the mouth. For example, patients with iron deficiency or pernicious anemia, on long-term antibiotics and steroids (topical, inhaled, or systemic), those with HIV infection or AIDS, and dry mouth can develop candidiasis. Smoking has also been related to the hyperplastic form of candidiasis. However, healthy individuals can also be affected.

Clinically, there are four forms of candidiasis: pseudomembranous, erythematous, hyperplastic, and mucocutaneous.

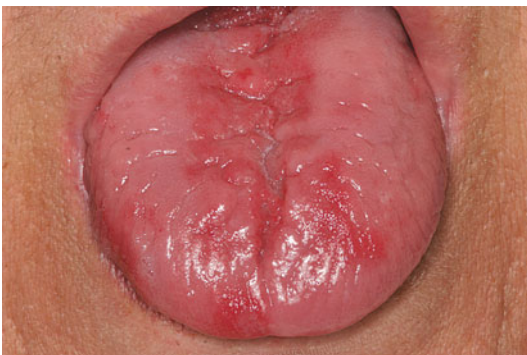- *Pseudomembranous candidiasis (thrush)* is a common form and it is usually acute. It affects approximately 5% of infants and 10% of debilitated older adults as well as patients on long-term antibiotics or those with dry mouth or immunocompromised patients. The term pseudomembranous is misleading since there is no



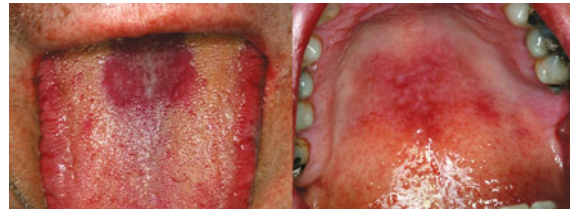▲ **Figure 38-22.** Pseudomembranous candidiasis (thrush). Thick white plaques easily removed by a cotton-tipped applicator.

pseudomembrane present. Instead, creamy white or yellow, easily detached aggregates of yeast and desquamated epithelial cells are seen on the oral soft tissues (Figure 38-22) of the palate, buccal mucosa, and tongue. They are easily removed with a tongue blade, dry gauze or a cotton-tipped applicator leaving behind normal or erythematous oral mucosa. If bleeding occurs during this procedure, an underlying disease, such as lichen planus/lichenoid mucositis or a neoplastic epithelial process, should be suspected and excluded by biopsy. In most cases of thrush there are no symptoms; however, burning sensations and altered taste have been reported.

- *Erythematous candidiasis* is characterized by red patchy areas with minimal or no white plaques of fungal aggregates. Erythematous candidiasis can have several clinical presentations that include acute atrophic candidiasis, central papillary atrophy of the tongue (median rhomboid glossitis), angular cheilitis, and denture stomatitis.
 - Acute atrophic candidiasis (Figure 38-23) is usually seen in patients on long-term antibiotic treatment,



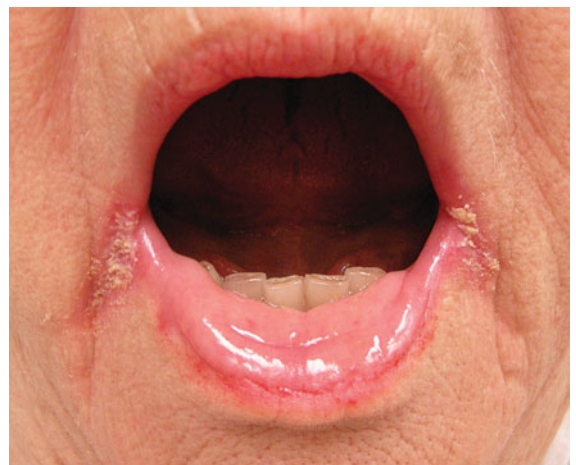▲ **Figure 38-23.** Atrophic candidiasis. Atrophy of the papillae in a patient with pernicious anemia.



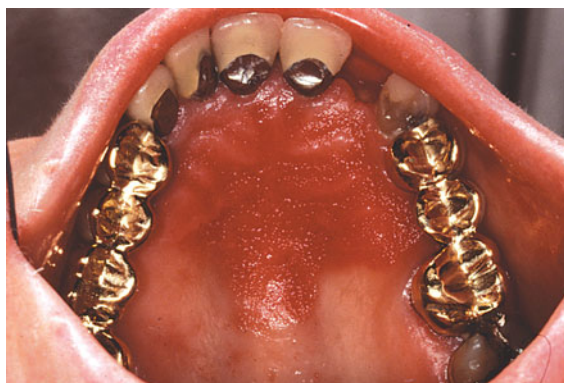▲ **Figure 38-24.** Central papillary atrophy of the tongue and candidiasis of the palate ("kissing effect").

with xerostomia, blood dyscrasias, or immunosuppression. Patients usually complain of a burning sensation (scalded mouth). When the tongue is affected, there is loss of the filiform papillae ("bald tongue").

- Central papillary atrophy of the tongue, also referred to as rhomboid glossitis, is a mostly asymptomatic, chronic form of candidiasis, presenting as a depapillated, usually symmetrical area on the middle and posterior central aspect of the tongue that appears smooth or less frequently lobulated. Lesions may also occur on the palate ("kissing" effect) or the buccal mucosa (Figure 38-24). This is referred to as chronic multifocal candidiasis.
- Angular cheilitis (perlèche) presents with fissures and cracks in the commissures of the lip (Figure 38-25). Typically it is seen in older patients with reduced vertical occlusal dimension (superior-inferior relationship of the maxilla to the mandible when the teeth are fully occluded), usually denture wearers, as well as patients with multifocal candidiasis. While in some instances only *Candida* is



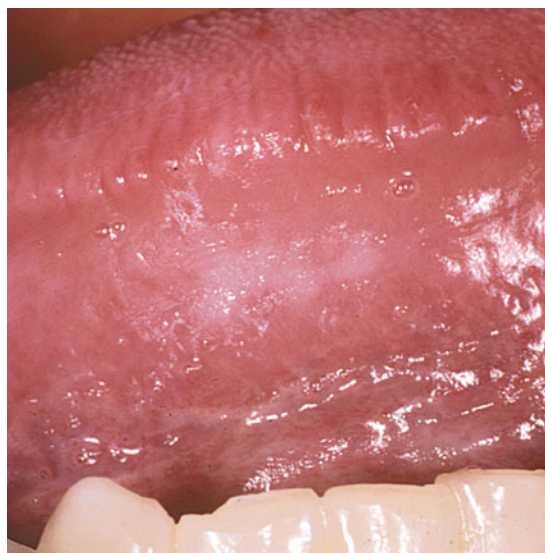
▲ **Figure 38-25.** Angular cheilitis (perlèche). *Candida* infection of oral commissures with erythematous fissures with white surface.



▲ **Figure 38-26.** Denture stomatitis caused by candida in a patient wearing a “flipper” (temporary removable denture to replace a missing tooth).

present, the majority of lesions harbor also *Staphylococcus aureus*, while some are caused only by this bacterium. Candida in angular cheilitis can spread to lips and perioral tissues.

- Denture stomatitis refers to erythematous lesions in the areas covered by the dentures, or other removable dental prosthetic appliances, especially if they are continuously worn (Figure 38-26). These lesions are generally asymptomatic. Interestingly, a biopsy most often does not feature any evidence of fungus. In such cases candida is found in the pores of the dentures; however, similar lesions can be caused by bacteria.
- Hyperplastic candidiasis is an unusual form seen primarily in smokers. It is most commonly seen on the buccal mucosa (Figure 38-27) or the tongue. In this form of candidiasis, nonremovable white plaques are present. Although it is known that candida can induce epithelial proliferation, it is not entirely clear if some lesions of hyperplastic candidiasis represent leukoplakias superinfected by candida. Occasionally, lesions disappear after antifungal treatment thus confirming the cause and effect role of candida in their development. Leukoplakias superinfected with candida can also have a speckled appearance, that is, speckled mixed white and red lesions (speckled leukoplakia). In such instances, antifungal treatment may improve the appearance of the leukoplakia to a smoother, more homogenous white lesion.
- Mucocutaneous candidiasis¹² is a relatively rare immunologic disorder in which patients develop lesions affecting the mouth (hyperplastic candidiasis and other forms), nails, skin, and other mucosal surfaces. In some patients, mutations in the autoimmune regulator (AIRE) gene have been identified. Lesions appear early in life and persist. However, they are not invasive and they can be controlled with continuous antifungal



▲ **Figure 38-27.** Hyperplastic candidiasis. Nonremovable white lesion diagnosed on cytologic smear. The patient was a heavy smoker.

treatment. There is also association of mucocutaneous candidiasis with endocrinopathies and rarely there is associated ectodermal dysplasia. Associated endocrinopathies include hypothyroidism, primary Addison's disease, diabetes mellitus, and hypoparathyroidism. In these patients there is increased risk for the development of oral or esophageal carcinoma.

► Management

The treatment of oral candidiasis involves elimination of factors, if possible, that contribute to persistent infection. It is important for patients to maintain a high level oral hygiene. Topical treatments for adults include the following.

- Clotrimazole troches (imidazole agent) one 10 mg troche slowly dissolved in the mouth 5 times per day for 10 to 14 days.
- Nystatin oral (polyene agent) 1 or 2 lozenges (pastilles) 200,000 to 400,000 IU dissolved slowly in the mouth 4 to 5 times per day for 10 to 14 days.
- Itraconazole oral solution (triazole agent) 10 mL vigorously swished and swallowed twice daily for 1 to 2 weeks.

When systemic treatment is needed for adults, fluconazole (triazole agent) 200 mg tablets the first day and then 100 mg per day for 1 to 2 weeks should be the first choice. Depending on the form of the disease and in patients with resistant candida species, ketoconazole capsules (imidazole agent) 200 mg once or twice a day for 1 to 4 weeks or for 3 to 5 days after lesions resolve. Ketoconazole should not be used as initial therapy.

Oral Lichen Planus

► Introduction

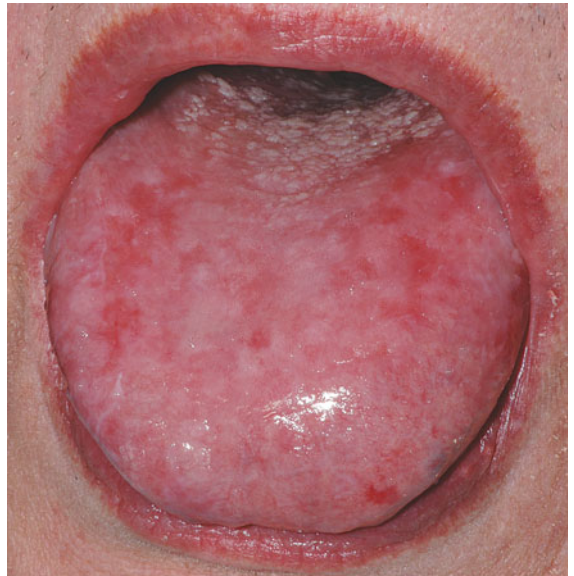Oral lichen planus (OLP) is a relatively common chronic T-cell-mediated autoimmune disease affecting 1% to 2% of the population.¹³ In contrast to cutaneous lichen planus that is usually self-limiting, OLP is generally a chronic disease, which may be difficult to palliate and rarely spontaneously resolves. Also and more importantly, lesions of OLP may infrequently undergo neoplastic transformation thus causing morbidity and mortality. The premalignant potential has varies in studies between 0.4% and over 5%.

Patients with OLP may have concomitant extraoral manifestations and 15% of patients with OLP develop subsequently extraoral disease. The severity of OLP does not, in general, correlate with the extent of cutaneous disease. Also known is the association of OLP of the gingiva with vulvovaginal or penile LP.

OLP is seen primarily in the 5th and 6th decades of life and it is twice as common in females as in males. Lesions of OLP can also be seen in children and adolescents. Patients with OLP have higher levels of anxiety and those with erosive forms have higher depression scores. Also an association of OLP with hepatitis C has been reported.¹³

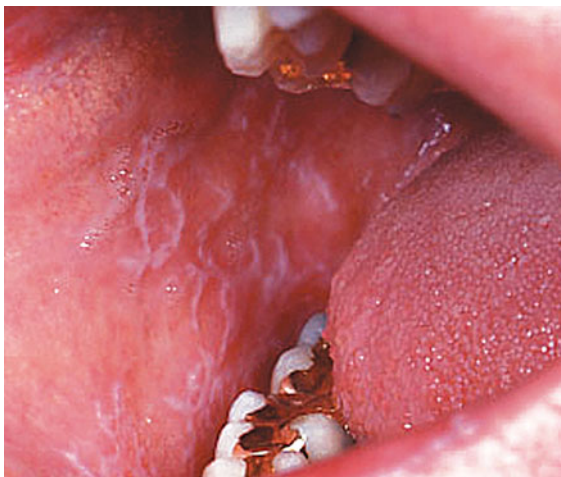► Clinical Presentation

There are three well-recognized forms: reticular, atrophic, and erosive. Reticular OLP (Figure 38-28) is the most common form and is characterized by multiple papules or plaques that coalesce forming striations (Wickham striae). Interestingly, lesions of reticular OLP rarely cause symptoms and frequently patients are unaware of their existence. Atrophic and erosive forms (Figure 38-29) are less

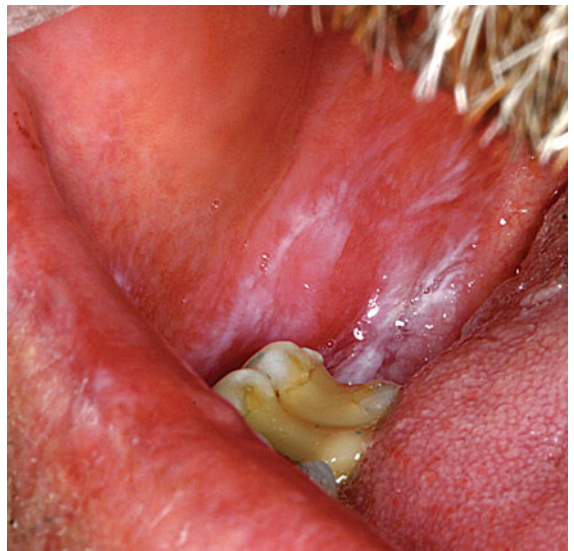

▲ **Figure 38-29.** Lichen planus. Atrophic and ulcerated areas on the tongue.

common. However, these forms are the most frequently encountered in clinical practice because they cause varying degrees of discomfort. The erosive form is mostly used as a clinical term when ulcerated lesions are encountered. Histopathologically, true erosions are infrequently encountered. These forms may be associated with reticular lesions (Figure 38-30) and occasionally erythematous, atrophic,



▲ **Figure 38-28.** Lichen planus. Reticular form (Wickham striae) on the buccal mucosa.

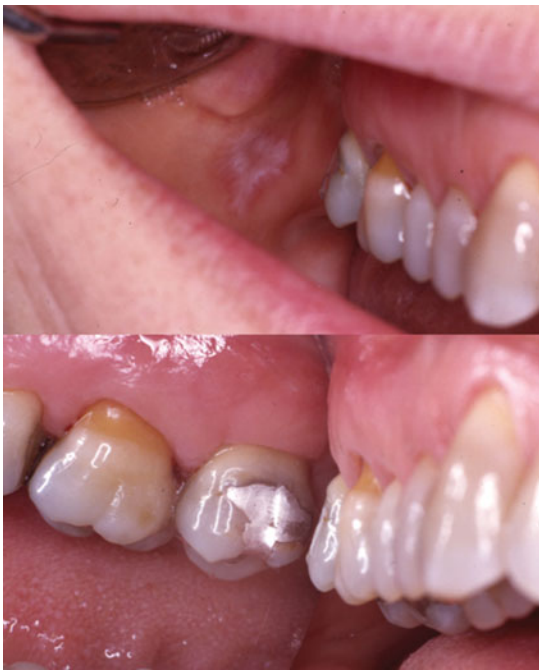

▲ **Figure 38-30.** Lichen planus. Erosive form with areas of Wickham striations.

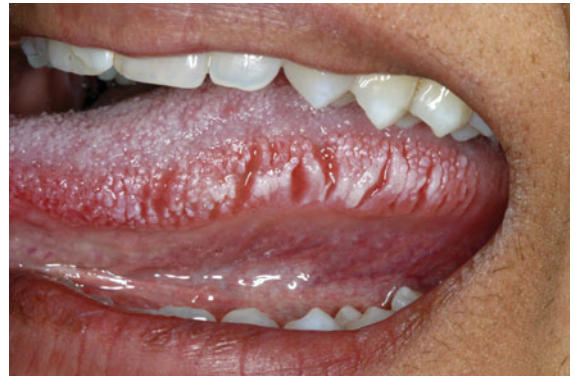and ulcerated lesions feature radiating white striations. Rarely, vesicles and bullae (bullous LP) may be seen. The most frequent sites of OLP are the posterior buccal mucosa bilaterally, dorsolateral tongue, gingiva, palate, and lip vermillion. Occasionally, lesions of OLP are associated with candidiasis which alters their clinical appearance especially those of the reticular form. In cases of reticular OLP with candida superinfection, patients may complain of burning sensation. The characteristic striations of OLP are seen after the candida infection is treated.

The diagnosis of lichen planus is established clinically and histopathologically. The differential diagnosis includes the following.

- Contact hypersensitivity reaction to dental materials, flavoring food agents such as cinnamon or mints (Figures 38-31 and 38-32). In the later, characteristic Wickham striae are not encountered.
- Lichenoid drug reaction (Figure 38-33), graft versus host disease (GVHD), and oral lesions of lupus erythematosus may have similar or indistinguishable clinicopathologic features with lichen planus. Therefore the clinician should exclude such possibilities prior to establishing the diagnosis of OLP.
- Chronic ulcerative stomatitis and vesiculobullous diseases.



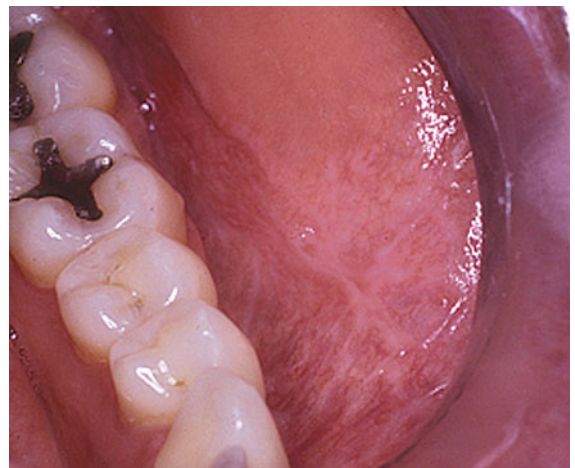▲ **Figure 38-31.** Lichenoid lesions due to contact allergy on the buccal mucosa (upper part) due to dental restoration (lower part).



▲ **Figure 38-32.** Lichenoid lesions on tongue due to cinnamon-related contact hypersensitivity.

► Management

Treatment of OLP is needed for the symptomatic forms. Patients with reticular OLP may be followed every 6 to 12 months. If patients are symptomatic, they may have a candida infection and antifungal medications should resolve the symptoms. Because of the autoimmune nature of LP and depending on the severity of lesions, topical and/or systemic corticosteroids may be indicated. Topical steroids including fluocinonide, betamethasone dipropionate, or clobetasol propionate 0.05% gels may be used. For widely distributed lesions, dexamethasone 0.5 mg/5 mL rinse may be used. Secondary candidiasis that may develop as a side effect to topical corticosteroid treatment can be eliminated by antifungal agents as described above. Topical tacrolimus ointment has been used in recalcitrant cases. Systemic treatment with prednisone may be needed in severe cases of erosive OLP. Other systemic medications that have been



▲ **Figure 38-33.** Lichenoid lesions on buccal mucosa due to medication.

used for the treatment of OLP include azathioprine, dapsone, levamisole, and thalidomide.

Leukoplakia

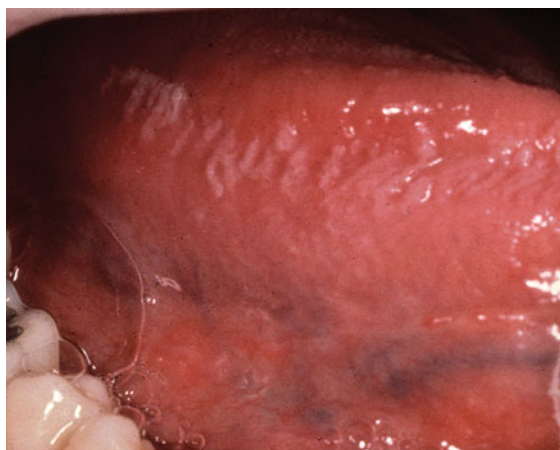
► Introduction

Leukoplakia is defined by the World Health Organization (WHO) as “a white patch or plaque that cannot be characterized clinically or pathologically as any other disease.” It is a term that does not define a specific entity, but excludes a wide variety of white lesions that present distinct clinical and/or histopathologic characteristics. It is a strictly clinical term that should be used by clinicians to communicate the presence of a white lesion, are unaware of. Table 38-3 lists lesions that should be included and excluded from the term leukoplakia.

Note among those lesions, the entity referred to as hairy leukoplakia (Figure 38-34). This is a type of white lesion exhibiting specific clinicopathologic features, caused by Epstein–Barr virus (EBV). It is frequently suprainfected by candida and seen mostly in immunosuppressed patients and those with HIV/AIDS. This is but an example of the confusion that the term leukoplakia can cause.

Etiologic factors for the development of leukoplakic lesions include all forms of tobacco, alcohol abuse, ultraviolet light (for labial lesions), *Candida albicans*, sanguinaria (bloodroot, a plant used in some nonprescription products). Of these factors, tobacco is most frequently associated with the development of leukoplakias. It is known that around 80% of patients with leukoplakia are smokers and that heavier smokers have greater numbers of lesions and larger lesions compared to light smokers. Also, smoking cessation leads to a decrease in size or disappearance of leukoplakias in many patients. However, one should note that some patients with leukoplakias never smoked and that nonsmokers with leukoplakia have higher risk for the development of squamous cell carcinoma compared to smokers.

Leukoplakia is considered a premalignant lesion. However only 5% to 25% of the cases have definitive histopathologic criteria to support premalignancy (intraepithelial neoplasia). The premalignant nature of leukoplakia has been established by clinical investigations and long-term monitoring of lesions. These studies have confirmed a malignant transformation potential of about 4% to 5%,



▲ **Figure 38-34.** Hairy leukoplakia. Vertical white papular lesions on the lateral border of the tongue in an HIV+ patient.

which increases in certain subtypes of leukoplakia (erythroleukoplakia, proliferative verrucous leukoplakia) to up to 47%. The progression and time of the development of histologically recognizable dysplasia in leukoplakic lesions are uncertain and occasionally invasive squamous cell carcinoma can occur without evidence of recognizable dysplasia.

The estimated prevalence of leukoplakia is between 1% and 4% and, recently, there appears to be gender parity, although in last years approximately 70% of the patients were males. The most frequent sites of occurrence are the vestibule and buccal mucosa followed by the palate, alveolar ridge, lower lip, tongue, and floor of mouth. The sites in the mouth in which leukoplakias present high risk for the development of dysplasia and squamous cell carcinoma are, in descending order the floor of mouth, ventrolateral tongue, lower lip, palate, buccal mucosa, vestibule, and retromolar mucosa.

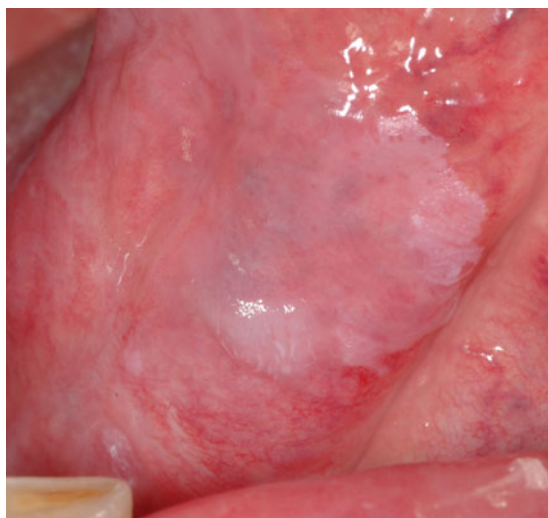
► Clinical Presentation

Clinically, leukoplakic lesions vary in clinical appearance from thin and homogeneous to thick irregular, leathery patches that may have distinct borders or blend with the surrounding tissues (Figures 38-35 to 38-37). Variations within the same lesion also occur. Occasionally, an erythematous component is present (erythroleukoplakia) (Figure 38-38). Such lesions have a higher risk for being dysplastic or invasive squamous cell carcinoma at the time of diagnosis. Proliferative verrucous leukoplakia (PVL),¹⁴ a subtype of leukoplakia, is characterized by the development of more than one lesions that exhibit various patterns of maturation even within the same patient (Figures 38-39A and B). Lesions of PVL have a very high risk for the development of verrucous or squamous cell carcinoma. They

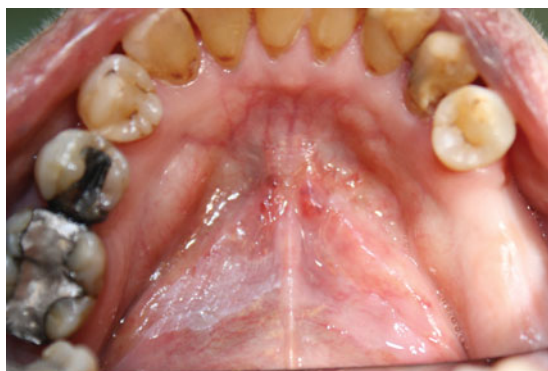Table 38-3. Lesions included and excluded from the term leukoplakia.

Includes: Erythroleukoplakia and proliferative verrucous leukoplakia.

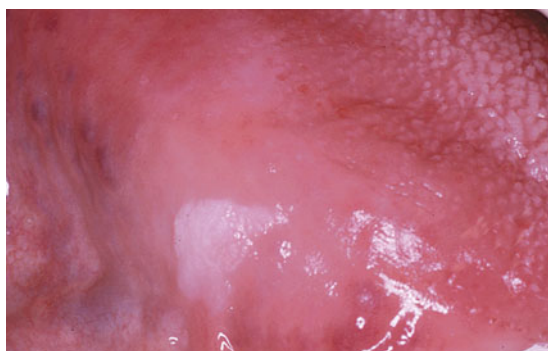
Excludes: Lichen planus, frictional keratosis, tobacco pouch keratosis, nicotine stomatitis, linea alba, leukoedema, actinic cheilitis, hypertrophic candidiasis, hairy leukoplakia, white sponge nevus, and squamous cell carcinoma.



▲ **Figure 38-35.** Leukoplakia. Homogeneous white plaque on the ventral surface of the tongue.



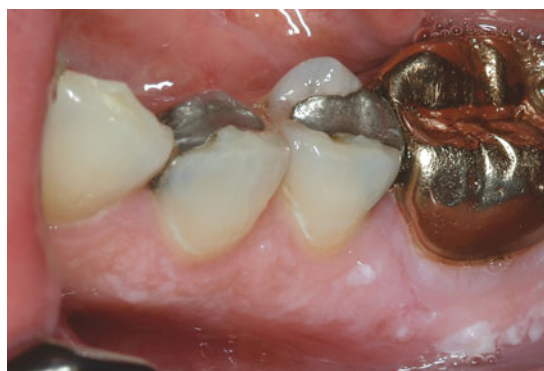▲ **Figure 38-36.** Leukoplakia. White plaque on floor of the mouth. The right side of the lesion is thin and homogeneous, the left side is thickened.



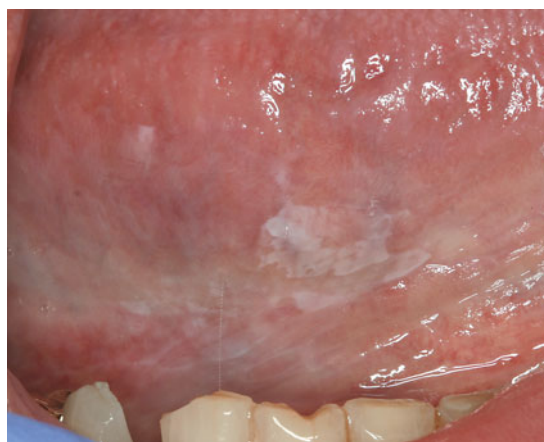▲ **Figure 38-37.** Leukoplakia of the tongue. Diffuse, thin, homogenous plaque on tongue.



▲ **Figure 38-38.** Erythroleukoplakia of the tongue.

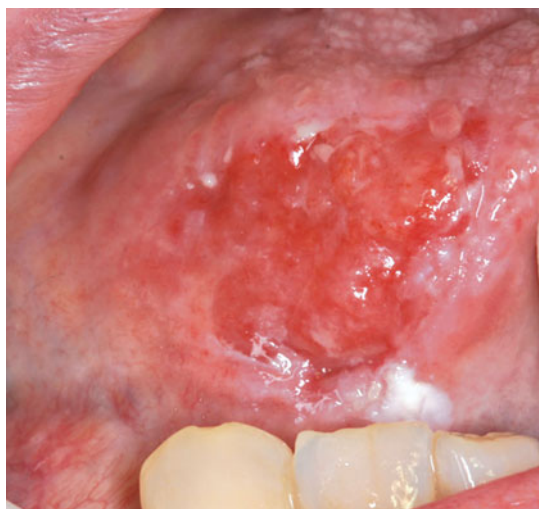

A



B

▲ **Figure 38-39.** A: Proliferative verrucous leukoplakia. Leukoplakic lesion on the mandibular alveolus. B: Proliferative verrucous leukoplakia on the tongue. Same patient as shown in (A).



▲ **Figure 38-40.** Erythroplakic lesion of the lateral border of the tongue. The diagnosis was squamous cell carcinoma. Small area of leukoplakia in the inferior aspect of the lesion. The biopsy showed hyperkeratosis with premalignant epithelial dysplasia.

occur more frequently in women and less than one-third of the patients are smokers.

In the concept of oral premalignancy/squamous cell carcinoma one should include **erythroplakia**.²¹ This is defined as a red patch that cannot be clinically or pathologically diagnosed as any other condition (Figure 38-40). However, this definition is misleading because at the time of biopsy lesions of erythroplakia show severe dysplasia, carcinoma in situ, or invasive squamous cell carcinoma. Erythroplakia is less common than leukoplakia. It occurs in middle aged to older adults and the sites of predilection are the floor of mouth, tongue, and soft palate.

The gold standard for the diagnosis of clinically identified suspicious oral lesions is surgical biopsy.

► Management

Surgical excision is the treatment of choice for leukoplakic lesions. Laser ablation is also used. Photodynamic therapy¹⁵ using 5-aminolevulinic acid is a promising alternative for treatment of dysplastic lesions. Cryosurgery and administration of 13-*cis*-retinoic acid have been used with limited results.

Oral Squamous Cell Carcinoma

► Introduction

Oral cancer accounts for less than 3% of all cancers in the United States. Over 20,000 cases are diagnosed per year with more than 5000 patients dying of this disease

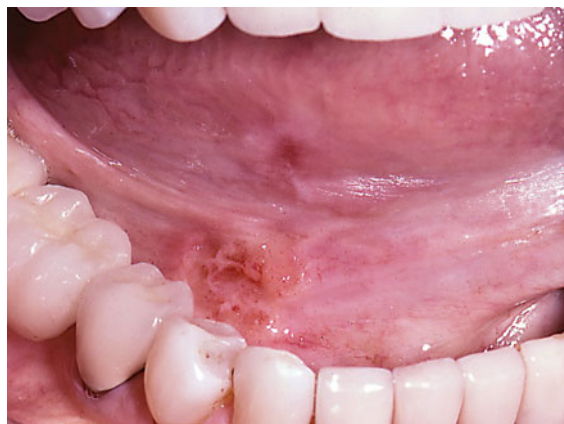annually. Oral squamous cell carcinoma (OSCC) represents approximately 95% of all types of malignancy affecting the oral cavity. Most patients are older than 60 years. However, there is an alarming increase in the number of younger patients without the traditional risk factors. Based on incidence rates less than 1% of men and women will be diagnosed with OSCC during their lifetime. The male-to-female ratio is approximately 2.5:1.

The major etiologic factors include tobacco and alcohol. All forms of smoked tobacco have been associated with increased risk. However, in smokeless tobacco, the association with the development of OSCC remains weak and controversial. In contrast, chewing of betel quid (paan, pan supari; combination of tobacco, areca nut, and slake lime) is a major cause for OSCC in the Indian subcontinent. Also, combination of heavy smoking and alcohol abuse results in a synergistic effect and increases the risk further.

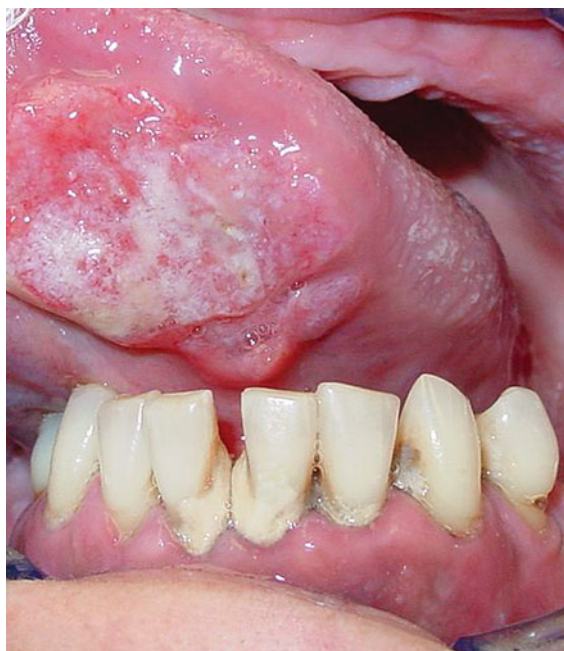Besides smoking and alcohol abuse, human papillomavirus (HPV) has been implicated in cases of tonsillar (oropharyngeal). However, association of HPV with the development of OSCC of the oral mucosa proper has not been determined. Squamous cell carcinoma with tumors is associated with HPV having a better prognosis.¹⁶ Patients with severe iron deficiency (Plummer–Vinson syndrome) have an elevated risk for development of esophageal and oropharyngeal squamous cell carcinoma.

► Clinical Presentation

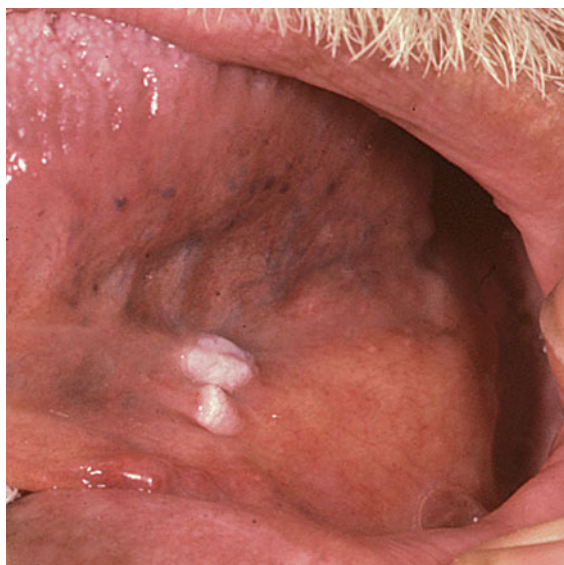There is a variety of clinical appearances of OSCC. Tumors can be ulcerated, endophytic, exophytic, leukoplakic, or erythroleukoplakic (Figures 38-41 and 38-42). While some tumors are clinically obvious, there are occasions where lesions are small (Figure 38-43), painless, and mimicking inflammatory processes (Figure 38-44). Such is the case of lesions seen in association with dental prostheses or



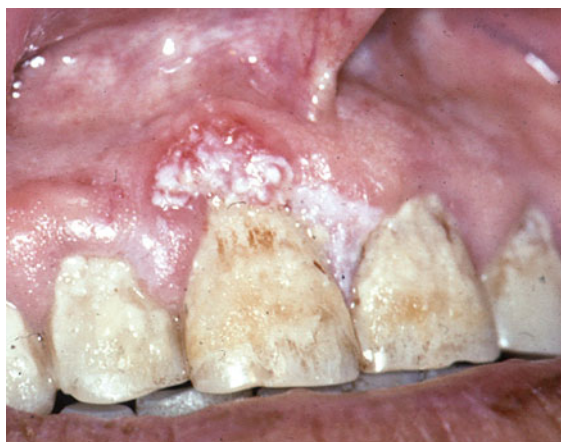▲ **Figure 38-41.** Ulcerated squamous cell carcinoma of the floor of the mouth.



▲ **Figure 38-42.** Exophytic squamous cell carcinoma of the ventral surface of the tongue.



▲ **Figure 38-43.** Squamous cell carcinoma. Small white plaque on ventral tongue.



▲ **Figure 38-44.** Squamous cell carcinoma of the gingiva mimicking an inflammatory lesion.

presenting as “inflamed” gingiva. In such cases, consultation with dental professionals may be necessary.

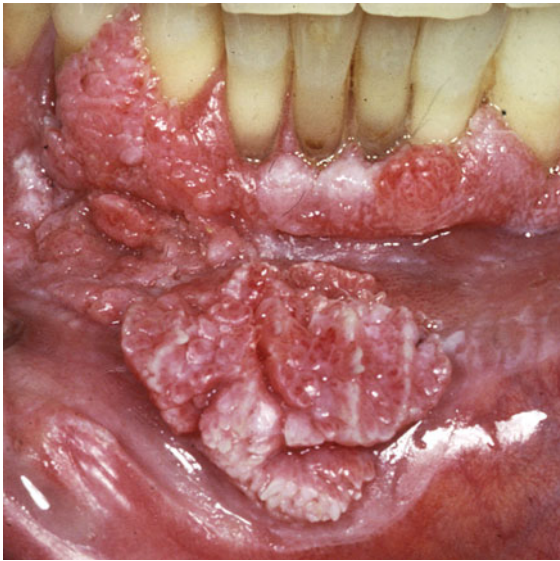► Management

Diagnostic biopsies should be obtained of all lesions that present with the aforementioned characteristics. Treatment of oral cancer involves a team of physicians that include ear, nose, and throat/oral surgery and maxillofacial specialists, oncologists, and prosthodontists.

▼ PAPILLARY, EXOPHYTIC, OR FUNGATING LESIONS

Papillary, exophytic, or fungating lesions occurring in the oral mucosa include papillomas, verrucae vulgaris, condylomata accuminatum, lesions of multifocal epithelial hyperplasia (focal epithelial hyperplasia; Heck’s disease), premalignant papillary, and verrucoid lesions as seen in proliferative verrucous leukoplakia, and papillary, verrucoid, or fungating variants of squamous cell carcinoma (Figure 38-45).

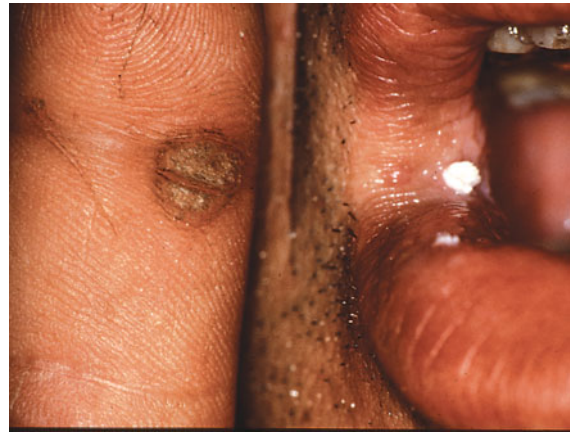Oral papilloma is a common benign epithelial proliferation similar to common warts of the skin. It is presumed that most if not all of papillomas are induced by HPV. HPV 6 and 11 have been identified in almost half of oral papillomas. Children and young adults are most frequently affected and there is no gender predilection. Generally, they present as solitary epithelial proliferations exhibiting finger-like projections (Figure 38-46) or a cauliflower-like pattern. The most frequent sites are the tongue, palate, and lips. Occasionally, more than one site can be simultaneously affected (papillomatosis) especially in the immunocompromised patients.



▲ **Figure 38-45.** Squamous cell carcinoma. Large papillary lesion.

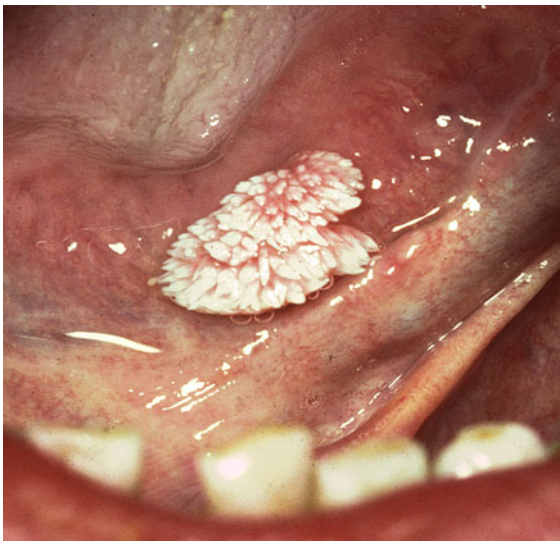Intraoral verruca vulgaris is uncommon. Occasionally, patients with cutaneous lesions also develop oral lesions (Figure 38-47).

Condyloma acuminatum can occur in the oral mucosa and has similar clinical and histopathologic characteristics of genital lesions. When identified in the mouth of children, sexual abuse is a concern and should be investigated.

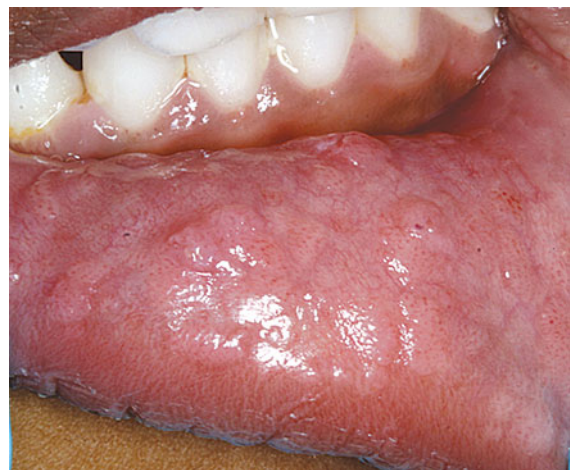

▲ **Figure 38-47.** Verruca vulgaris on the finger and the commissure.

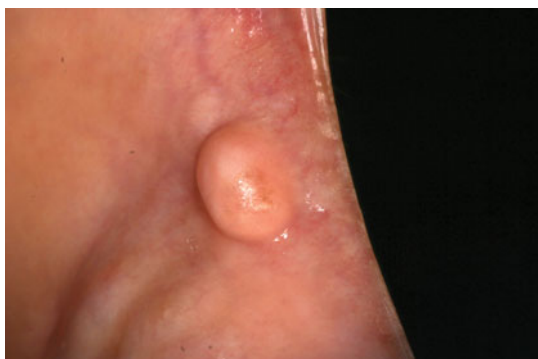Multifocal epithelial hyperplasia is an HPV-related proliferation (HPV 13 and 32) characterized by multiple papular or nodular epithelial proliferations that occasionally coalesce forming a cobblestone pattern (Figure 38-48). Patients may have 20 to 100 lesions that rarely reach 1.0 cm in size. Lesions are seen more frequently in children. However, adults can also develop lesions also, especially if there is contact with affected children. Frequent sites of involvement include the lips, tongue, and buccal mucosa. The diagnosis can be made clinically and microscopically.



▲ **Figure 38-46.** Papilloma. White plaque with finger-like projections often caused by human papillomavirus (HPV).



▲ **Figure 38-48.** Multifocal epithelial hyperplasia (Heck's disease). Multiple papules forming cobblestone pattern on the inner lower lip caused by human papillomavirus (HPV).



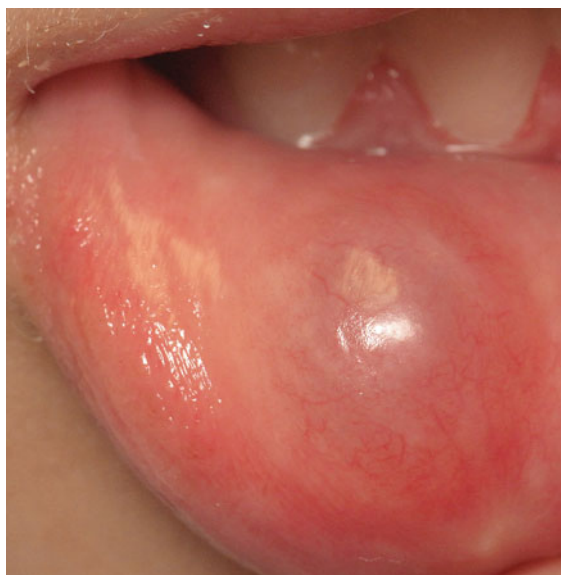▲ **Figure 38-49.** Fibroma. Smooth papule on the buccal mucosa.

▼ NODULAR OR POLYPOID LESIONS

The most common nodular or polypoid lesions of the oral mucosa are fibrous polyps (fibromas), mucoceles, and epulides.

Fibromas (fibrous hyperplastic lesions) present as sessile or pedunculated, rubbery, solitary tumors covered by normal-colored or hyperkeratotic (white) mucosa (Figure 38-49). Although trauma has been traditionally regarded as the cause of oral fibrous overgrowths, the etiology is unknown. Most lesions arise on the buccal mucosa, tongue, and lips, and their size rarely exceeds 1.5 cm. Most fibromas are asymptomatic, unless there is ulceration due to trauma. Most cases are seen in the 4th to 6th decades of life and females are twice as frequently affected as males. The observed higher frequency in females may be due to the fact that women are more concerned about their esthetics or oral health compared to males. Also, fibrous hyperplastic lesions may be seen on the alveolus of patients with ill-fitting dentures. Surgical excisional biopsy to confirm the diagnosis and to exclude other soft tissue tumors is recommended.

Mucocele¹⁷ refers to a clinically fluctuant nodular mass containing salivary mucus. It is either of extravasation type due to severing of a salivary gland excretory duct and spillage of mucus in the connective tissue, or retention type, resulting from obstruction of a salivary duct, the latter being less common. Extravasation-type mucoceles (Figure 38-50) are most frequently seen on the lower lip and less frequently the ventral surface of the tongue of children or young adults, or the palate and retromolar mucosa of older individuals. Retention-type mucoceles are seen in older adults on the upper lip, floor of mouth, and buccal mucosa. Thus, for a fluctuant lesion on the lower lip of a child or young adult, the diagnosis is most likely that of a mucocele until proven histopathologically otherwise. However, a fluctuant lesion of the upper lip in an adult is not an extravasation mucocele until proven otherwise. These lesions are typically retention mucoceles, or benign or malignant cystic salivary gland tumors.



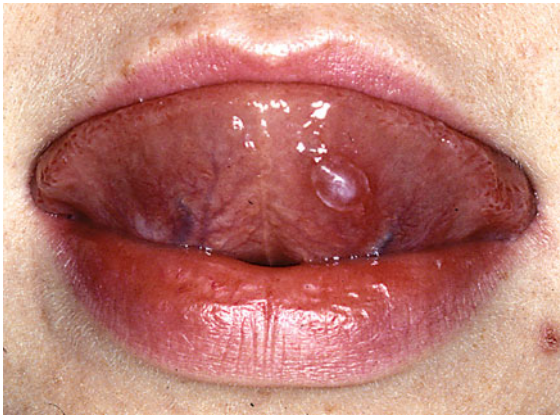▲ **Figure 38-50.** Mucocele. Clear fluctuant cyst on the lower lip.

There is an uncommon variant referred to as superficial mucocele seen on the posterior palate and buccal mucosa. They appear as single or multiple small translucent vesicles filled with clear saliva. The collection of mucus occurs in the surface epithelium. Multiple lesions, clustered or not, may be encountered in association with lichenoid disorders. In such cases, the differential diagnosis includes an immunologically mediated vesiculobullous disorder such as MMP. Rarely lymphangiectatic lesions may clinically mimic superficial mucoceles.¹⁸

Although they are indolent lesions, all mucoceles excised should be submitted for histopathologic evaluation to exclude the possibility of a cystic salivary gland tumor. Recurrence is infrequent, except those occurring on the ventral surface of the tongue (Figure 38-51) that have an approximately 20% to 25%.

Epulides are nodular soft tissue lesions typically on the gingiva and the alveolar mucosa. They include the following.

- Fibrous hyperplasia (fibromas)
- Fibrovascular inflammatory hyperplasia (usually but erroneously referred to as pyogenic granulomas, but they are neither pus-containing nor granulomatous) (Figure 38-52).
- Fibroblastic proliferation with ossification (peripheral ossifying fibromas) (Figure 38-53).
- Collection of multinucleated giant cells in association with proliferating mesenchymal cells in a hemorrhagic stroma (peripheral giant cell granuloma) (Figure 38-54). Combination of the last two can occur.

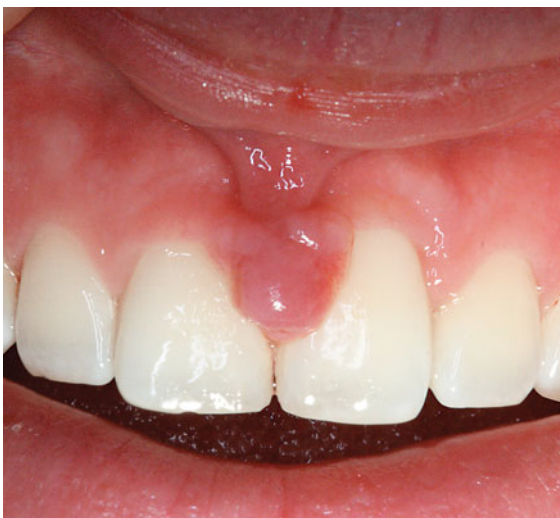

▲ **Figure 38-51.** Mucocele. Transparent fluctuant cyst on ventral tongue.

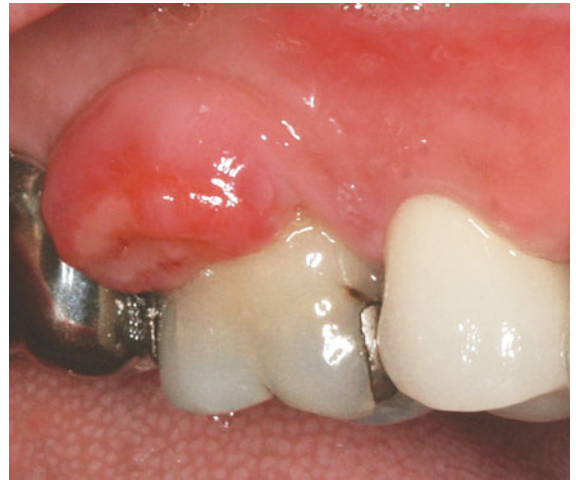As a rule, fibrovascular inflammatory hyperplasias and peripheral giant cell granulomas are usually erythematous and hemorrhagic. Fibrous proliferations and peripheral ossifying fibromas are normal mucosa colored, except if they are traumatized and ulcerated. Excision of epulides is recommended and recurrence is not uncommon in peripheral ossifying fibromas (about 15%)¹⁹ and peripheral giant cell granulomas (10%).²⁰

PIGMENTED LESIONS

Pigmented lesions of the oral mucosa²¹ are of two types: those related to melanin and those caused by other pigments, endogenous or exogenous, the latter mostly



▲ **Figure 38-52.** Pyogenic granuloma. Erythematous smooth papule (epulide) on gingiva.

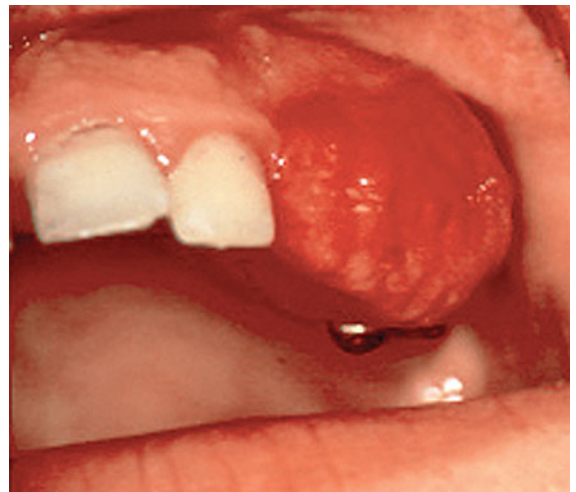


▲ **Figure 38-53.** Peripheral ossifying fibroma.

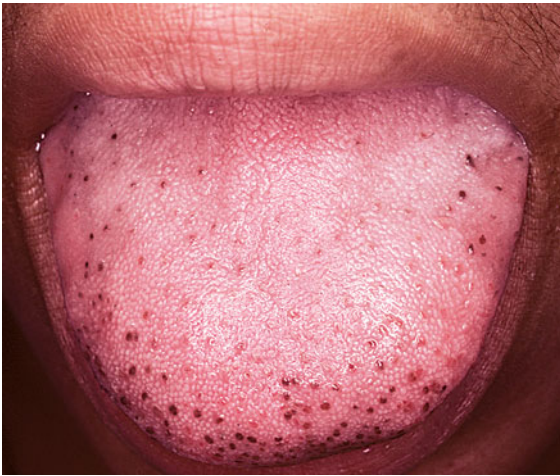metallic in origin. Also, certain systemic medications may cause pigmented lesions in the oral mucosa by either an increase in melanin pigment or deposition of medication metabolites in the soft tissues. All oral pigmented lesions that cannot be related to a specific cause should be biopsied for diagnosis.

Melanin-Associated Hyperpigmented Lesions

- **Oral (or ethnic) pigmentation**, seen in darker-skinned individuals, varies in pattern, but is usually diffuse and bilateral with the color ranging from light to dark brown. The lesions are generally seen on the gingiva,



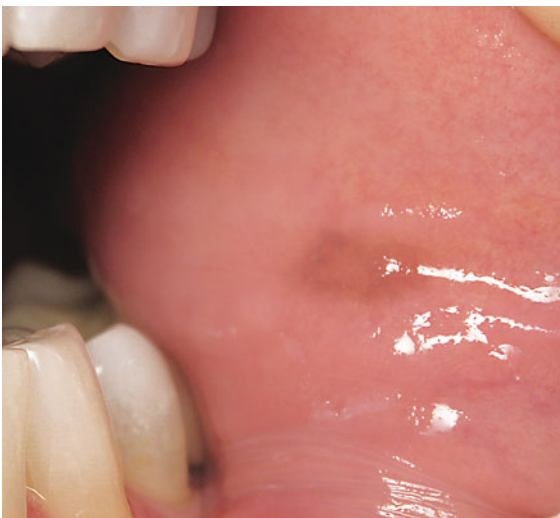▲ **Figure 38-54.** Peripheral giant cell granuloma.



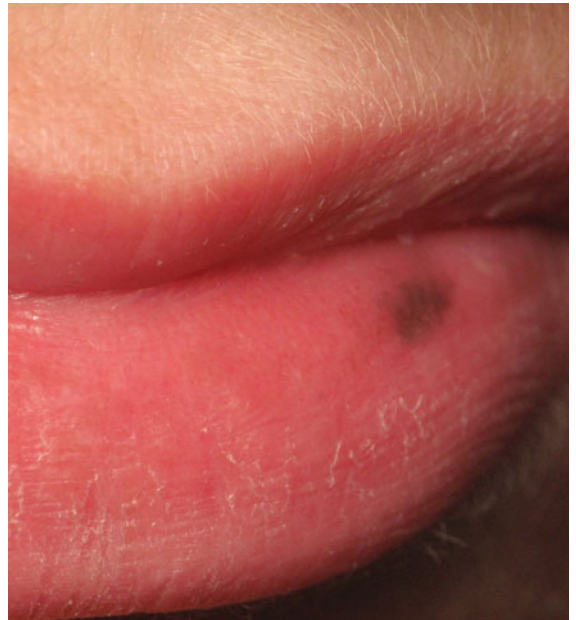▲ **Figure 38-55.** Melanin pigmentation presenting as hyperpigmentation on the tips of the fungiform papillae in African American individual.

buccal mucosa, lips, and tongue. Pinhead brown discolorations can be seen on the tips of the lingual fungiform papillae (Figure 38-55).

- **Oral Melanocytic macules** are the most common melanocytic lesions. They usually appear as single or multiple, well-demarcated, less than 1 cm, light or dark brown lesions usually on the buccal (Figure 38-56) and masticatory mucosa or on sun-exposed areas vermillion border of the lower lip (Figure 38-57). There is a female predilection.

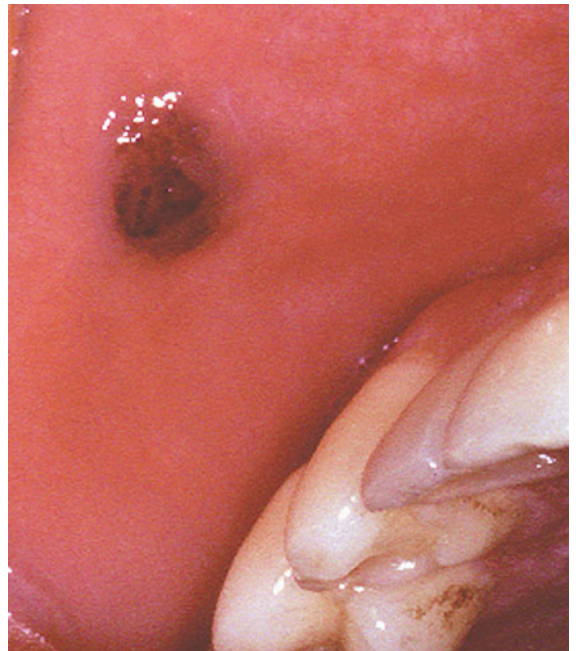


▲ **Figure 38-56.** Melanotic macule on the buccal mucosa.

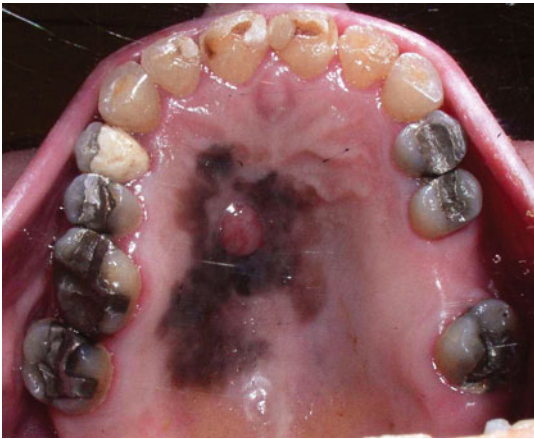

▲ **Figure 38-57.** Ephelis (freckle) on the lower lip.

- **Intraoral melanocytic nevi** are uncommon. They are usually acquired, and present as pigmented and less frequently as nonpigmented macular or papular or, rarely, nodular or polypoid lesions (Figure 38-58). They are



▲ **Figure 38-58.** Melanocytic nevus on oral mucosa.



▲ **Figure 38-59.** Melanoma. Black plaque with irregular borders with central pink nodule on the palate.

generally small with most lesions being less than 1 cm. Two-thirds of the patients are women and the average age is 35 years. Most lesions occur on the hard palate, buccal mucosa, and gingiva. As is the case on the skin, there are three common histologic types, junctional, compound, and intramucosal, the latter being the most frequent type. Intraoral blue nevi have been also described, predominantly in the palate. Other rare forms, for example, Spitz, halo, combined, and congenital nevi have also been reported. Although there is demographic epidemiologic correlation between oral nevi and oral melanoma, there is no proof that intraoral nevi are a marker for the development of oral melanoma.

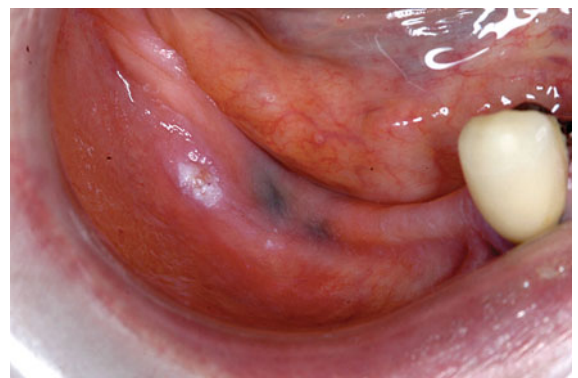
- **Oral melanomas** are very rare. They are usually macular, papular, or nodular and are most frequently pigmented, black, brown, or gray (Figure 38-59). Rarely red or non-pigmented melanomas are seen. The most frequent site is the masticatory mucosa and most patients are men. Most oral melanomas are clinically and histologically similar to acral lentiginous or nodular melanomas of the skin or a combination of the two.
- **Melanoacanthoma** is a rare, apparently reactive and, in most instances, self-limiting solitary or less frequently bilateral or multifocal process seen predominantly on the buccal mucosa of almost exclusively black individuals, primarily women.
- **Smoker's, postinflammatory, and medication-related melanoses** are reactive lesions. Smoker's melanosis is seen in heavy smokers and is considered a protective response by the epithelium to the harmful substances of tobacco. Postinflammatory melanosis is seen in chronic inflammatory diseases such as lichen planus, lichenoid mucositis, MMP, or PV. Hyperpigmentation occurs because of disruption of the basal cell layer leading to

melanin accumulation in the connective tissue and within macrophages or stimulation of the epithelial melanocytes by inflammatory products (prostaglandins, leukotrienes, etc.) leading to an increase in melanin synthesis. Lastly, medication-related melanin hyperpigmentation (chloroquine and other quinine derivatives, phenolphthalein, estrogen, and AIDS-related medications) can present with oral manifestations. Females are more frequently affected probably due to interaction with sex hormones. Any site of the oral mucosa may be involved.

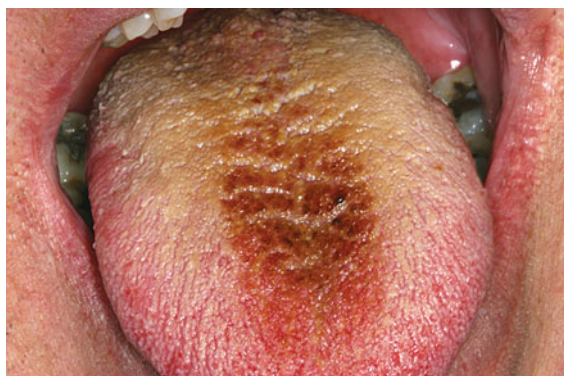- **Systemic conditions** such as Peutz-Jeghers syndrome, PTEN hamartoma tumor syndromes, and Addison's disease may have oral and/or perioral melanin hyperpigmented lesions. In most instances the patients are aware of their condition and its clinical manifestations. Among such conditions one should include Laugier-Hunziker (Laugier-Hunziker-Baran) syndrome seen more frequently in females, in which patients develop multiple oral melanocytic macules and less frequently nail and vaginal lesions.

Non-melanin-Related Hyperpigmentations

These lesions are caused by either exogenous or endogenous pigments. Exogenous hyperpigmentations are mostly related to amalgam restorations (Figure 38-60). Lesions are usually located on the gingiva, alveolar mucosa, buccal mucosa, floor of mouth, and less often the tongue. The color is light to dark gray or even black depending on the amount and depth of the metal within the tissues. The size varies from few millimeters to 2 cm. The cause can be iatrogenic or traumatic. Particles of amalgam may be imbedded within the tissues during restorative procedures. Occasionally, metallic particles can be identified in dental radiographs as small radiopaque particles. Similar discolorations can occur from incidental or voluntary introduction of other metals such as graphite from pencil tips, tattoo ink, and chronic contact with charcoal toothpaste.



▲ **Figure 38-60.** Amalgam tattoo. Exogenous metallic pigmentation on the alveolus.

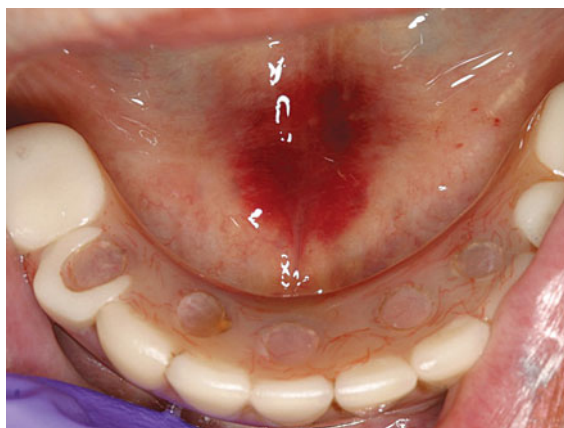

▲ **Figure 38-61.** Brown-black discoloration of the tongue in a heavy smoker and coffee drinker.

Extrinsic staining of the oral tissues may also occur in smokers or coffee or tea drinkers (Figure 38-61). Lastly, breakdown products of bacteria may stain the gingiva. This usually occurs in children.

Chronic exposure to heavy metals such as bismuth, lead, gold, or silver can cause oral hyperpigmented lesions, but these days, such cases are rare. Finally metabolites of certain medications, the most frequent being minocycline, may cause diffuse discoloration of teeth, oral soft tissues, and bone. In most instances in minocycline-related hyperpigmentation the lesions are related to iron-chelated metabolites.

Lesions caused by endogenous pigments are usually related to blood extravasation (petechiae, ecchymoses, and hematomas) and products of hemoglobin degradation, that is, bilirubin and biliverdin. Trauma is the most common cause (Figure 38-62). The most frequently affected sites include the buccal mucosa, tongue, and palate. Direct trauma to a tooth or teeth may lead to pulpal necrosis and discoloration of affected teeth. Also, patients with hemorrhagic diathesis may develop multiple hemorrhagic lesions



▲ **Figure 38-62.** Hematoma on floor of mouth.

throughout the mouth. In such cases, thrombocytopenia is a frequent cause and should be excluded. Rare systemic conditions associated with non-melanin-associated hyperpigmented lesions of teeth and soft tissues include hemo-chromatosis, erythroblastosis fetalis and biliary atresia associated hyperbilirubinemia, beta thalassemia, and congenital erythropoietic porphyria.

The online learning center at www.LangeClinicalDermatology.com has clinical self-assessment questions for this chapter.

REFERENCES

1. Junge S, Kuffer R, Scully C, Porter SR. Mucosal disease series. Number VI. Recurrent aphthous stomatitis. *Oral Dis.* 2006;12:1–21. PMID: 16390463.
2. Kolokotronis A, Doumas S. Herpes simplex virus infection, with particular reference to the progression and complications of primary herpetic gingivostomatitis. *Clin Microbiol Infect.* 2006;12:202–211. PMID: 16451405.
3. Eversole LR. Viral infections of the head and neck among HIV-seropositive patients. *Oral Surg Oral Med Oral Pathol.* 1992;73:155–163. PMID: 1312690.
4. Bagan J, Lo Muzio L, Scully C. Mucosal disease series. Number III. Mucous membrane pemphigoid. *Oral Dis.* 2005;11:197–218. PMID: 15984952.
5. Black M, Mignogna MD, Scully C. Number II. Pemphigus vulgaris. *Oral Dis.* 2005;11:119–130. PMID: 15888101.
6. Sklavounou A, Laskaris G. Frequency of desquamative gingivitis in skin diseases. *Oral Surg Oral Med Oral Pathol Oral Radiol Endod.* 1983;56:141–144. PMID: 6578475.
7. Farthing P, Bagan JV, Scully C. Mucosal disease series. Number IV. Erythema multiforme. *Oral Dis.* 2005;11:261–267. PMID: 16120111.
8. Assimakopoulos D, Patrinos G, Fotika C, Elisaf M. Benign migratory glossitis or geographic tongue: an enigmatic oral lesion. *Am J Med.* 2002;15:751–755. PMID: 12517366.
9. Zargari O. The prevalence and significance of fissured tongue and geographical tongue in psoriatic patients. *Clin Exp Dermatol.* 2006;31:192–195. PMID: 16487088.
10. Hietanen J, Salo OP, Kanerva L, Juvakoski T. Study of the oral mucosa in 200 consecutive patients with psoriasis. *Scand J Dent Res.* 1984;92:50–54. PMID: 6585911.
11. Giannini PJ, Shetty KV. Diagnosis and management of oral candidiasis. *Otolaryngol Clin North Am.* 2011;44(1):231–240, vii. PMID: 21093632.
12. Eyerich K, Eyerich S, Hiller J, Behrendt H, Traidl-Hoffmann C. Chronic mucocutaneous candidiasis, from bench to bedside. *Eur J Dermatol.* 2010;20:260–265. PMID: 20133219.
13. Eisen D, Carrozzo M, Bagan Sebastian J-V, Thongprasom K. Mucosal disease series. Number V. Oral lichen planus: clinical features and management. *Oral Dis.* 2005;11:338–349. PMID: 1626902.
14. Hansen LS, Olson JA, Silverman S Jr. Proliferative verrucous leukoplakia. A long-term study of thirty patients. *Oral Surg Oral Med Oral Pathol.* 1985;60(3):285–298. PMID: 3862042.
15. Jerjes W, Upile T, Hamdoo Z, et al. Photodynamic therapy outcome for oral dysplasia. *Lasers Surg Med.* 2011;43(1):192–199. PMID: 21494890.
16. Ang KK, Harris J, Wheeler R, et al. Human papillomavirus and survival of patients with oropharyngeal cancer. *N Engl J Med.* 2010;363(1):24–35. PMID: 20530316.

17. Chi AC, Lambert PR 3rd, Richardson MS, Neville BW. Oral mucocoeles: a clinicopathologic review of 1,824 cases, including unusual variants. *J Oral Maxillofac Surg.* 2011;69(4):1086–1093. PMID: 20708324.
18. Koutlas IG, Dace B. Multifocal intraoral acquired lymphangiectases after surgical and radiation treatment for oral squamous cell carcinoma. *J Oral Maxillofac Surg.* 2006;64(3):528–530. PMID: 16487819.
19. Buchner A, Hansen LS. The histomorphologic spectrum of peripheral ossifying fibroma. *Oral Surg Oral Med Oral Pathol Oral Radiol Endod.* 1987;63(4):452–461. PMID: 3472146.
20. Katsikeris N, Kakarantza-Angelopoulou E, Angelopoulos AP. Peripheral giant cell granuloma. clinicopathologic study of 224 new cases and review of 956 reported cases. *Int J Oral Maxillofac Surg.* 1988;17(2):94–99. PMID: 3133432.
21. Meleti M, Vescovi P, Mooi WJ, van der Waal I. Pigmented lesions of the oral mucosa and perioral tissues: a flow chart for the diagnosis and some recommendations for the management. *Oral Surg Oral Med Oral Pathol Oral Radiol Endod.* 2008;105(5):606–616. PMID: 18206403.

Diseases of the Genitals and Perineum

Phoebe Koch

39

Introduction to Chapter / 315
Anatomy / 315
Approach to Diagnosis / 316

Evaluation / 320
References / 322

INTRODUCTION TO CHAPTER

A stroll down the pharmacy aisle is proof enough that genital symptoms plague our population. The sheer number of products such as cleaning wipes, douches, anti-itch sprays, and antifungal preparations is overwhelming. Many patients will go to great lengths to solve genital symptoms on their own, whether motivated by embarrassment, lack of access to medical care, or uncertainty as to which medical professional is best suited to treat the problem. Indeed, many clinicians also share this uncertainty. On the other hand, patients can be too certain of a diagnosis, for example ascribing any vulvar itching, burning, or discomfort to a yeast infection. Diseases are often diagnosed via telephone, and medications (especially antifungal treatments) are often prescribed without a physical examination.

ANATOMY

Knowledge of normal genital anatomy, as well as normal variants of the male and female genitalia, must form the basis for any approach to diagnosing genital disease.

- Keratinized, hair-bearing skin is present on the scrotum and penile shaft in males and on the labia majora in females.
- Modified mucous membranes with a minimal keratin layer are present on the glans in males and medial labia majora and labia minora in females.

- True mucous membranes with no keratin layer are present on the urethral meatus in males and the vagina and introitus beginning at Hart's line in females.

In males, surgical removal of the prepuce (foreskin) decreases the incidence of penile cancers, genital warts, psoriasis, erosive lichen planus, lichen sclerosus, and several sexually transmitted infections including herpes simplex and human immunodeficiency virus (HIV).¹

Knowledge of anatomic boundaries, and the typical locations of certain conditions, may aid the clinician in distinguishing diseases with similar morphologic features. For example, involvement of the mucous membranes favors lichen planus over lichen sclerosus. Involvement of the intertriginous regions favors a candida infection, whereas sparing of the creases may implicate a contact dermatitis. A well-defined, scaly red plaque involving the scrotum may suggest lichen simplex chronicus, while tinea cruris, which is also red, scaly, and itchy, tends to spare the scrotum and favor the skin folds.

Normal variations of the genitalia commonly lead patients to seek medical attention, often in the setting of new-onset symptoms, or at the initiation of sexual activity. In the latter situation, these variants may be mistaken for sexually transmitted infections. This is often the case with pearly penile papules and vulvar papillae, which are present in more than one-third of uncircumcised males and premenopausal women, respectively; both are frequently misdiagnosed as genital warts.² Unlike warts, these papules

are usually symmetric, exhibit domed rather than filiform tips, and have a discrete base. Prominent sebaceous glands (Fordyce spots) are also commonly mistaken for genital warts. These 1 to 2 mm yellowish papules occur on the modified mucous membranes, including the labia minora and distal shaft of the penis, and may coalesce to form thin plaques.³

APPROACH TO DIAGNOSIS

Skin diseases of the genitals and perineum can be classified into four broad categories (see Table 39-1).

- Dermatitis
- Papulosquamous disorders

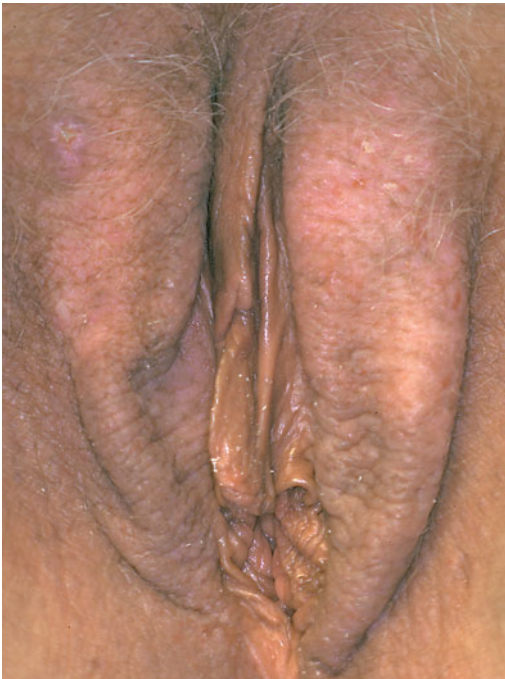Table 39-1. Differential diagnosis for diseases of the genitals and perineum.

Disease	Notes	History	Physical Examination
Dermatitis			
Irritant contact dermatitis (ICD)	Common F > M No previous sensitization needed	Irritation, pain, soreness, burning, stinging occurring weeks after exposure to weak irritants (soaps) and immediately after exposure to strong irritants (bleach) ^{3,4}	Chronic ICD: ill-defined pink patch or thin plaque. May have slight scale Acute ICD: red edematous plaques, may be vesicular
Allergic contact dermatitis	Common F > M Delayed-type hypersensitivity reaction; requires prior sensitization	Pruritic. Often history of exposure to prescription or over-the-counter medications (eg, benzocaine, topical antibiotics, and spermicides) ^{3,5}	Red, edematous plaques, may be vesicular, on labia majora in females and penis and scrotum in males, perianal involvement in both sexes
Lichen simplex chronicus	Common F > M Often prior history of atopy	Severe, paroxysmal pruritus, worse at bedtime ³	Pink, poorly margined papules and plaques with epidermal thickening, hypo- or hyperpigmentation, prominent skin markings, scale on labia majora in females (Figure 39-1), scrotum in males
Papulosquamous			
Lichen planus	Uncommon F > M Onset between ages 50 and 60. Most common noninfectious erosive condition of vulva. Almost nonexistent in circumcised men Rare association with hepatitis C	May be pruritic, burning, or painful. Possible dyspareunia or dysuria if vagina involved. Elicits rubbing, not scratching	White, lacy patches, flat-topped papules forming plaques, or glossy red vulvar erosions. ³ May have loss of architecture with scarring. Annular lesions on penile shaft. May involve nongenital skin, vaginal, or oral mucosa
Lichen sclerosus	Common F > M Prevalence between 1/300 and 1/1000. ⁴ Bimodal peaks: childhood and later life (postmenopausal)	Pruritic. Painful if secondary ulceration/erosions present	White papules/plaques. Shiny, wrinkled cigarette-paper appearance. ³ Ecchymoses and purpura are pathognomonic (Figure 39-2). Scarring or loss of architecture (Figure 39-3). Spares vagina (unlike lichen planus). Perianal involvement in females only. Phimosis in young boys
Fungal			
Candidiasis	Common F > M. Obesity, incontinence, diabetes, immunosuppression, corticosteroid therapy, pregnancy, infected sexual partner, and antibiotics use predispose	Irritation, pruritus, and burning	Red plaques with scale and satellite pustules (Figure 39-4) ³ Women may have vaginal discharge. In uncircumcised men, penis is often involved
Tinea cruris	Common M > F	Pruritic or asymptomatic	Well-defined pink plaques with peripheral scale in inguinal folds and upper medial thighs, scrotum is spared (Figure 39-5)

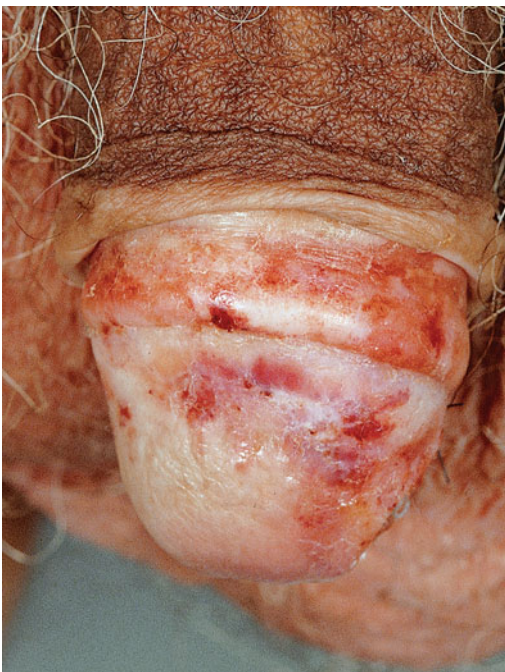
(continued)

Table 39-1. Differential diagnosis for diseases of the genitals and perineum (Continued).

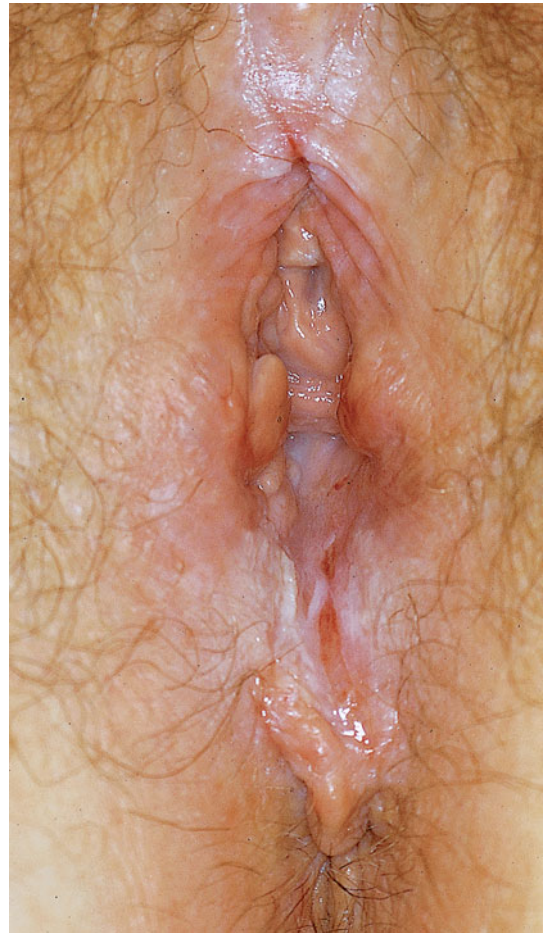
Disease	Notes	History	Physical Examination
Viral			
Herpes simplex (HSV)	Common. Most common cause of genital ulcers. 80% of genital HSV caused by HSV-2. ¹¹ 90% of HSV-2 carriers unaware of infection. 70% of HSV-2 infections transmitted during asymptomatic shedding ^{3,6}	Prodrome: tingling, burning Acute onset of painful ulcers. Primary episode occurs 2-7 days after exposure	Small 1-3 mm vesicles on erythematous base (Figure 39-6). May rupture, forming shallow erosions. Most common on the genitals, perianal area, or buttocks
Genital warts Human papillomavirus (HPV)	Common. Risk proportional to number of lifetime sexual partners, increased in immunosuppressed individuals. ⁷ Peak age: mid teens to early 30s	Onset after sexual activity. Often asymptomatic. May cause pruritus, pain, bleeding, and burning	Pink, brown, red, black, or skin-colored papules and plaques (Figure 39-7A and B). Women may have cervical warts; men may have perianal warts ⁷
Molluscum	Common. Bimodal distribution: children <15 years, young adults 15-29 years (as STI). ⁸ Immunosuppression and atopic dermatitis predispose	Incubation period weeks to months. Lesions often asymptomatic. Secondary eczematization may cause itch and pain	Firm, smooth, umbilicated papules. May exhibit Koebner phenomenon
Bacterial			
Erythrasma	Uncommon M > F More common in humid climates	Usually asymptomatic	Well-defined plaques in inguinal folds and upper medial thigh. Coral red color with Wood's light (Figure 39-8A and B)
Hidradenitis suppurativa	Uncommon F > M. Prevalence is 1%. Obesity is risk factor. Onset after puberty	Chronic painful and tender lesions which only partially respond to antibiotics ⁹	Red cysts and nodules in inguinal, perianal, and genital areas. Axilla and inframammary areas may also be involved (Figures 15-11 and 15-12)
Perianal streptococcal disease	Uncommon Children > adults. Incidence unknown	Persistent perianal itch or pain. May have pain with defecation. Satellite pustules may indicate staphylococcal infection	Sharply demarcated perianal erythema (Figure 39-9), may have fissures, characteristic foul odor. ¹⁰ May involve vulva, scrotum, and penis
Syphilis	Uncommon M > F Incidence in the United States increasing. Most new cases in men who have sex with men, ages 15-40 years ¹¹	Primary ulcer: 3 weeks after exposure Secondary: 2-10 weeks after primary ulcer Tertiary: 3-10 years after primary Primary and secondary lesions resolve without treatment	Primary: painless ulcer (chancre) appears within 3 weeks of transmission, usually single, often glans penis in males, vulva (Figure 39-10) or cervix in females Secondary: condylomata lata (soft pink papules and nodules in perineum)
Precancerous tumors and cancer			
HPV-related squamous cell carcinoma in situ	Uncommon F > M Younger patients with history of genital warts	Indolent asymptomatic course. Less likely to be invasive	Multifocal red, brown, or skin-colored papules or plaques on penis or perianal area in males and females and in vestibule, labia majora, and perivulvar area in females ⁷
Non-HPV related squamous cell carcinoma in situ	Uncommon F > M Older patients. May have history of lichen sclerosis/planus	May be pruritic	Unifocal red, white, or skin-colored papules typically on penis, and perianal area in males and vestibule and labia minora in females (Figure 39-11A and B)
Invasive squamous cell carcinoma	Uncommon F > M Peak age of onset is 60-70 years. May have history of genital warts or lichen sclerosis/planus ^{3,12}	May be tender or pruritic	May present as an ulcer, plaque or exophytic nodule (Figure 39-12) typically on the labia minora or majora or clitoris in females ¹³ and on the penis in males
Melanoma	Uncommon M > F Rare <1% of all melanomas. May be amelanotic ¹⁴	Usually asymptomatic	Tan to black papule or plaque with asymmetry, irregular color, and indistinct borders. May be ulcerated
Extramammary Paget's disease	Uncommon F > M Onset after 50 years of age. 15-30% are associated with malignancy ¹⁵	Asymptomatic, indolent	Well-demarcated pink scaly plaque with white epithelium on vulva or perineum (Figure 39-13)



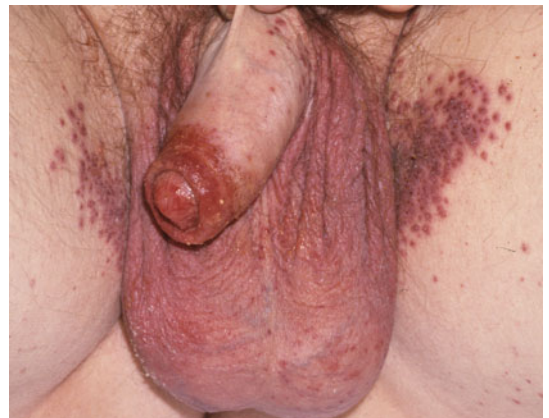▲ **Figure 39-1.** Lichen simplex chronicus. Hypopigmented, pruritic plaques with epidermal thickening due to chronic rubbing and scratching.



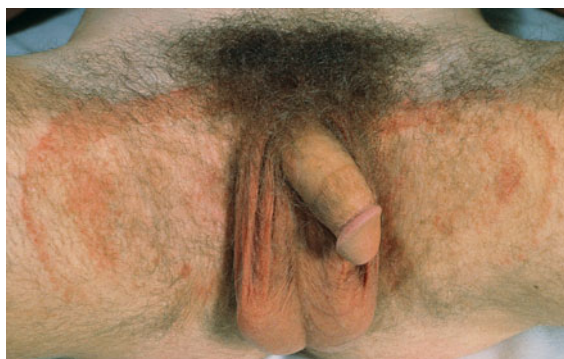▲ **Figure 39-2.** Lichen sclerosus. White plaque with scarring and purpura on penis.



▲ **Figure 39-3.** Lichen sclerosus. White atrophic plaque with scarring and loss of labia minora.



▲ **Figure 39-4.** Candidiasis. Red plaques with satellite pustules on inner thighs, scrotum, and penis.

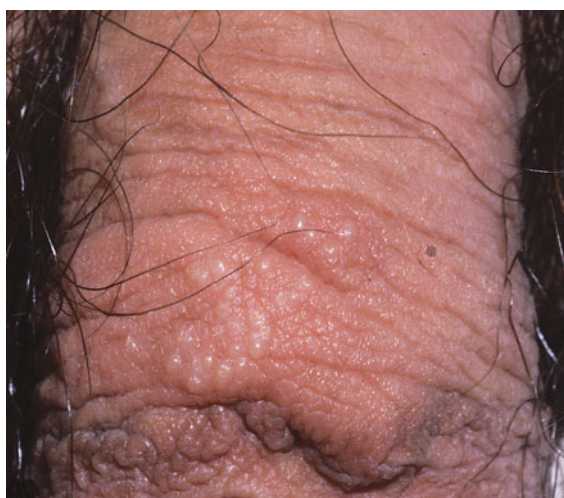

▲ **Figure 39-5.** Tinea cruris. Annular plaques with advancing scaly borders on upper medial thigh, scrotum is spared.

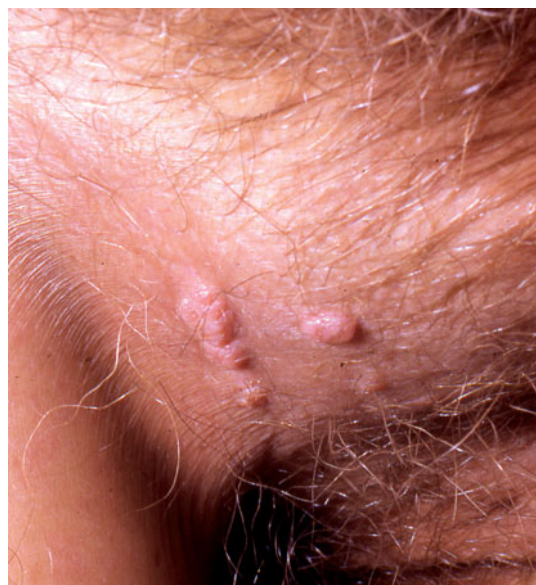- Infection
- Cancerous and precancerous tumors

The diagnosis of genital disorders is made more challenging by the frequent coexistence of multiple disease processes. When a rash is noted elsewhere on the body, a unifying diagnosis is often sought. However, in the genital region, two separate disease processes may be present. As an example, use of an over-the-counter cream to relieve itch due to lichen sclerosus may lead to a superimposed contact dermatitis.⁴

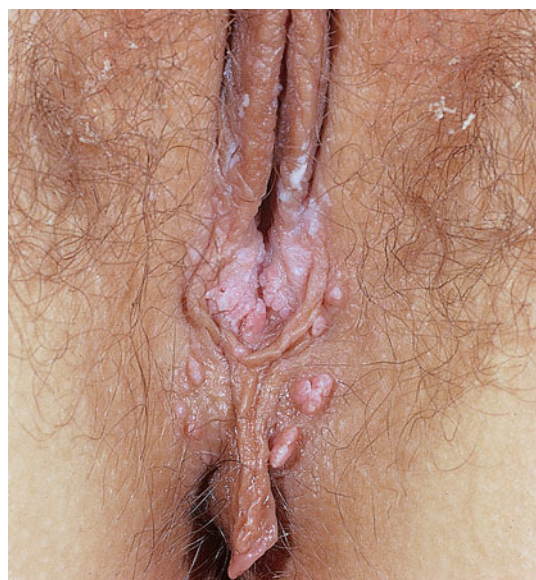
Yet another factor complicating the diagnosis of genital disease is the fact that few clinicians examine the asymptomatic external genitalia during routine examinations.³ Primary care clinicians often pay only passing attention to the external genitalia before proceeding to the internal exam, while dermatologists often leave this examination to



▲ **Figure 39-6.** Herpes simplex. Grouped vesicles on penile shaft.



A

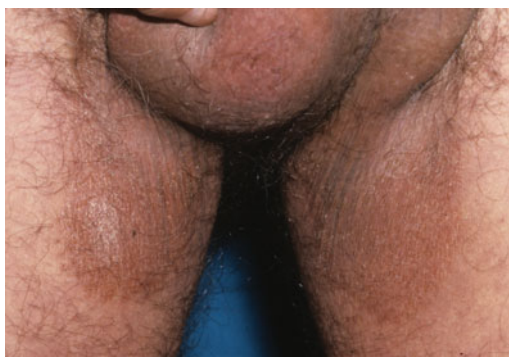

B

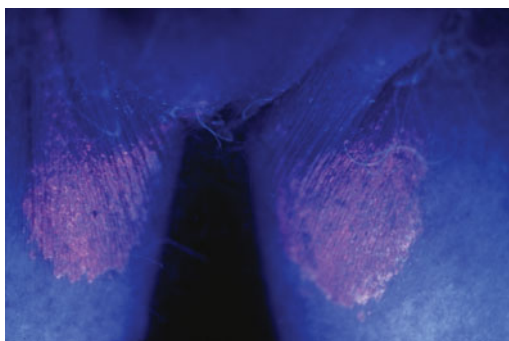
▲ **Figure 39-7.** (A, B) Genital warts. Skin-colored verrucous papules on the side of scrotum and on posterior fourchette and perineal body.

the primary care clinician. Therefore, when a patient develops symptoms such as itch or pain, physiologic redness and normal variants may be perceived as abnormal.

Skin disease affecting the genitalia often presents differently than disease on nongenital skin. This is exemplified

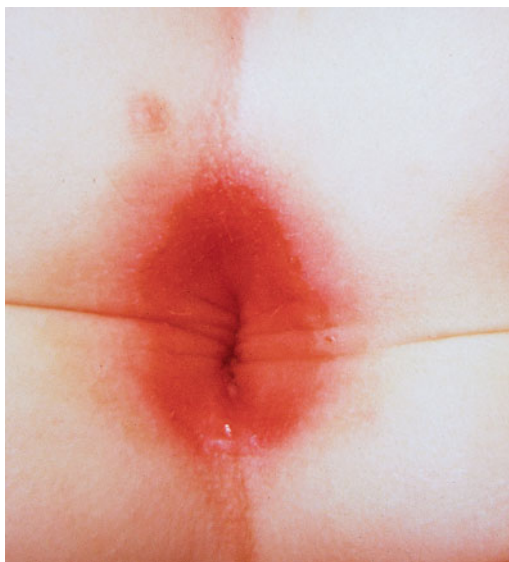

A

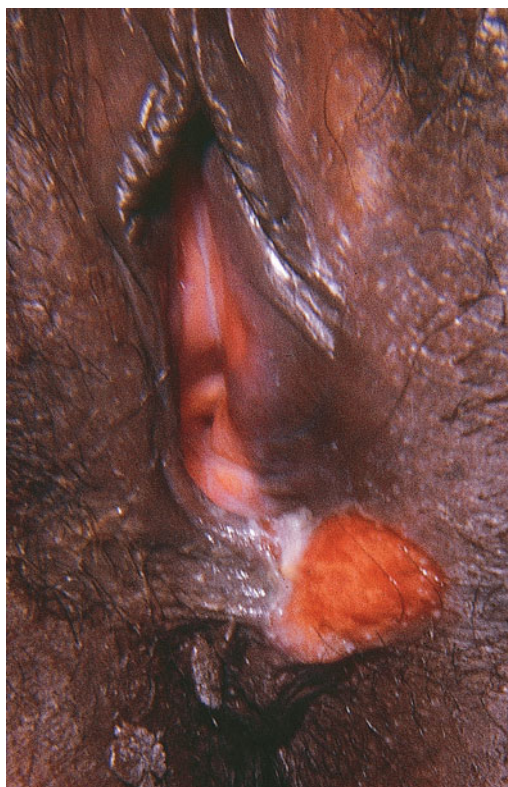

B

▲ **Figure 39-8.** Erythrasma. (A, B) Well-defined, rust-colored thin plaques on medial thighs that have a coral red color with Wood's light examination.



▲ **Figure 39-9.** Perianal streptococcal disease. Sharply demarcated perianal erythema in a child.

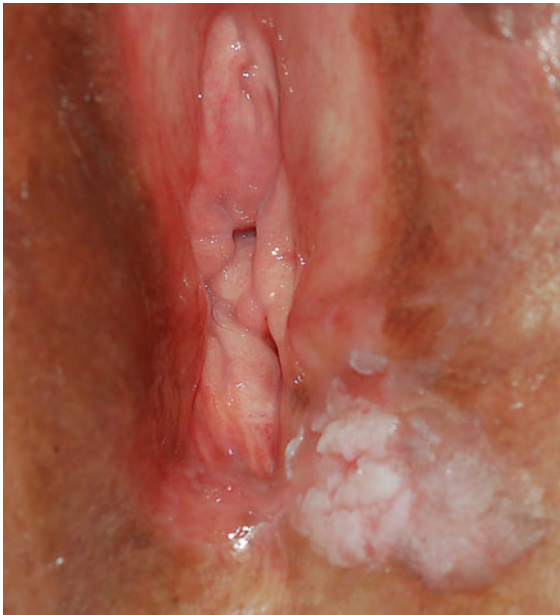

▲ **Figure 39-10.** Primary syphilis. Chancre presenting as an asymptomatic ulcer on the perineal body.

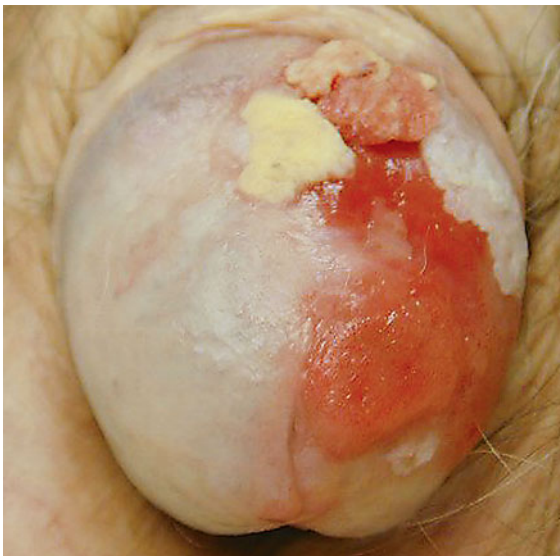
in psoriasis on the genitals, which lacks the classic silvery scale seen on dry, keratinized skin elsewhere. Lichen planus involving the genitals may manifest the characteristic purple, polygonal, pruritic papules. However, it may also present as pale annular plaques on the glans in men, or as shallow vulvar or vaginal erosions in women. A careful examination of the genitals and the rest of the skin and nails may reveal characteristic skin findings, such as nail pitting in psoriasis or oral mucosal involvement in lichen planus, thereby leading to the correct diagnosis.

EVALUATION

- A thorough physical examination of genital and non-genital skin is important as many genital diseases such as lichen planus and psoriasis may have involvement elsewhere.
- Most genital disorders are usually diagnosed on the basis of the history and physical findings. However, laboratory confirmation is often needed to confirm the diagnosis of other diseases such as herpes simplex, perianal streptococcal disease, syphilis, and all suspected skin cancers.



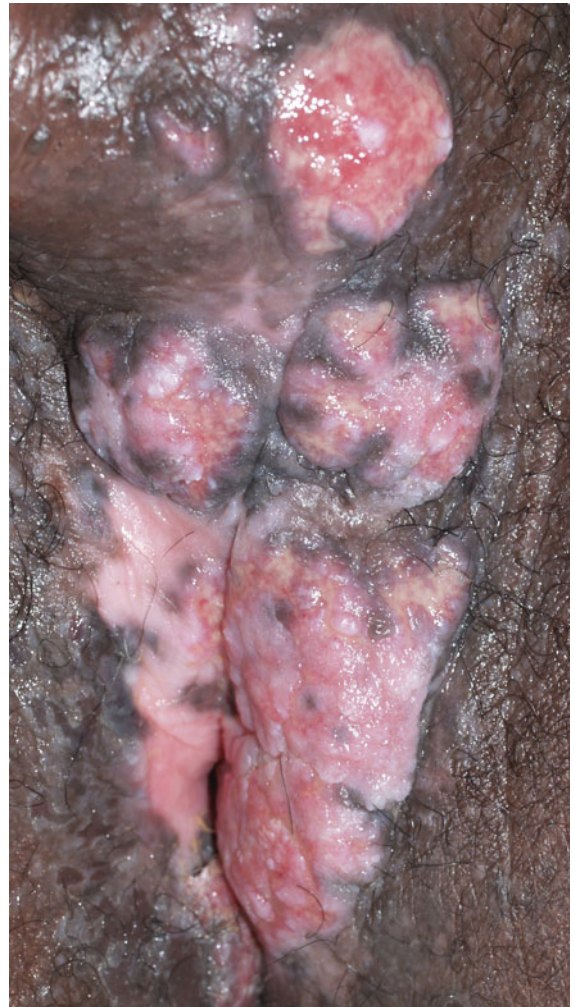A



B

▲ **Figure 39-11.** (A, B) In situ squamous cell carcinoma. White hyperkeratotic plaque on labia majora and red and white hyperkeratotic plaque on the head of penis.

- Potassium hydroxide (KOH) examination and/or fungal cultures should be performed for any rash in the inguinal fold areas or rashes with satellite pustules.
- A viral culture, polymerase chain reaction (PCR), viral culture, Tzanck smear, or a skin biopsy can be done to verify the diagnosis of herpes simplex. If these tests are



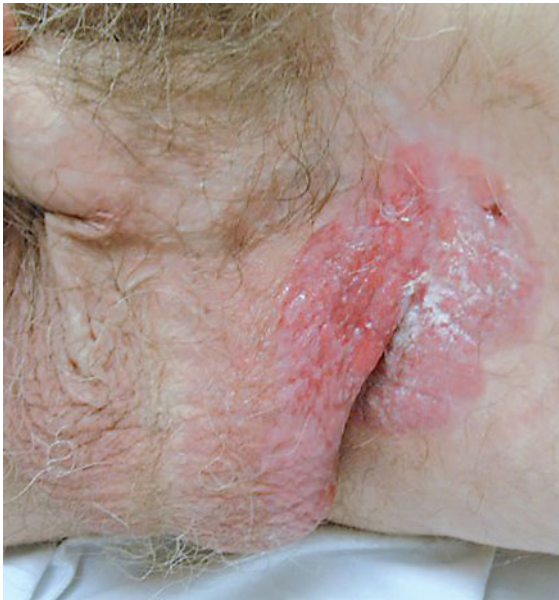▲ **Figure 39-12.** Invasive squamous cell carcinoma. Pink, hypopigmented indurated plaque with superficial erosion on perineum.

negative consider ordering a mono spot test for mononucleosis which may present with genital ulcers.

- A skin biopsy should be done of tan to black pigmented lesions and lesions suspicious for in situ or invasive carcinomas. A biopsy may also be needed to confirm the diagnosis of papulosquamous disorders and warts.
- Patch testing can be considered for any rash in which allergic contact dermatitis is suspected.

Management

One of the primary, and most basic, management strategies is simplifying the treatment regimen. As mentioned above, many patients experiment with various over-the-counter



▲ **Figure 39-13.** Extramammary Paget's disease. Well-demarcated pink-white plaque on scrotum extending into the inguinal fold.

remedies before presenting to a clinician, and develop extensive hygienic routines, which often do more harm than good. The patient should be instructed to wash with warm water, using the fingers, and refrain from applying anything to the genital region other than the prescribed treatments. Pure petrolatum jelly may be used for lubrication. If there is chronic irritation due to incontinence, or skin fold occlusion due to obesity, a barrier ointment may be indicated. When possible, ointments should be used in lieu of creams or gels, which have greater potential to irritate the skin.⁴ Preservatives and additives in the latter can also elicit contact dermatitis.

When prescribing a potent topical corticosteroid, such as clobetasol ointment, a clinician may preemptively treat fungal and yeast overgrowth with an agent such as oral fluconazole. A single oral dose of 150 to 200 mg fluconazole is often preferred over topical azole treatments due to the high incidence of irritation caused by the latter.⁴ The mucosal surfaces are relatively resistant to the adverse effects of topical steroid medications, whereas the keratinized skin, especially the skin folds and medial thighs, are prone to develop steroid atrophy and striae. When possible, the patient should be asked to demonstrate correct application of topical treatments, using a handheld mirror. This will insure that treatments are applied to the correct region, and in proper amounts.

It is important to address quality of life issues related to genital disorders, which can include, depression,

dyspareunia, chronic pain or pruritus, and the many concerns related to sexually transmitted diseases.⁴

Patient Information

- Centers for Disease Control and Prevention (CDC) Sexually Transmitted Diseases: www.cdc.gov/std/
- International Society for the Study of Vulvovaginal Disease (patient education section): www.issvd.org
- The National Vulvodynia Association: www.nva.org
- American Cancer Society (penile cancer): www.cancer.org

The online learning center at www.LangeClinicalDermatology.com has clinical self-assessment questions for this chapter.

REFERENCES

1. Morris BJ. Why circumcision is a biomedical imperative for the 21(st) century. *Bioessays*. 2007;29:1147–1158. PMID: 17935209.
2. Edwards L, Lynch P. *Genital Dermatology Atlas*, 2nd ed. Philadelphia: Lippincott Williams & Wilkins, 2011:20.
3. Margesson LJ. Vulvar disease pearls. *Dermatol Clin*. 2006;24(2):145–55, v. PMID: 16677963.
4. Beecker J. Therapeutic principles in vulvovaginal dermatology. *Dermatol Clin*. 2010;28(4):639–648. PMID: 20883909.
5. Warshaw EM, Furda LM, Maibach HI, et al. Anogenital dermatitis in patients referred for patch testing. *Arch Dermatol*. 2008;144(6):749–755. PMID: 18559763.
6. Fatahzadeh M, Schwartz RA. Human herpes simplex virus infections: epidemiology, pathogenesis, symptomatology, diagnosis, and management. *J Am Acad Dermatol*. 2007;57(5):737–763. PMID: 17939933.
7. Ahmed AM, Madkan V, Tyring SK. Human papillomaviruses and genital disease. *Dermatol Clin*. 2006;24(2):157–165, vi. PMID: 16677964.
8. Becker TM, Blount JH, Douglas J, Judson FN. Trends in molluscum contagiosum in the United States, 1966–1983. *Sex Transm Dis*. 1986;13(2):88–92. PMID: 3715678.
9. Alikhan A, Lynch PJ, Eisen DB. Hidradenitis suppurativa: a comprehensive review. *J Am Acad Dermatol*. 2009;60(4):539–561. PMID: 19293006.
10. Bugatti L, Filosa G, Ciattaglia G. Perianal dermatitis in a child. Perianal streptococcal dermatitis (PSD). *Arch Dermatol*. 1998;134(9):1147, 1150–1147, 1150. PMID: 9762032.
11. Centers for Disease Control and Prevention. Sexually Transmitted Disease Surveillance 2010 Supplement, Syphilis Surveillance Report. Centers for Disease Control and Prevention. Available at <http://www.cdc.gov/std/Syphilis2010/>
12. Dillner J, von Krogh G, Horenblas S, Meijer CJ. Etiology of squamous cell carcinoma of the penis. *Scand J Urol Nephrol Suppl*. 2000;205:189–193. PMID: 11144896.
13. Edwards L, Lynch PJ. *Genital Dermatology Atlas*, 2nd ed. Philadelphia, PA: Lippincott Williams & Wilkins; 2011:216–219.
14. De Simone P, Silipo V, Buccini P, et al. Vulvar melanoma: a report of 10 cases and review of the literature. *Melanoma Res*. 2008;18:127–133. PMID: 18337649.
15. Lam C, Funaro D. Extramammary Paget's disease: summary of current knowledge. *Dermatol Clin*. 2010;28(4):807–826. PMID: 20883922.

Cosmetic Concerns

Khaled M. Hassan
Christopher B. Zachary

40

Introduction to Chapter / 323
Approach to Treatment / 323

References / 328

INTRODUCTION TO CHAPTER

Dermatologists have an important role in guiding their patients with regard to cosmetic and aesthetic issues and can offer a wide variety of treatment modalities for skin rejuvenation and restoration. Many patients with diseases of the skin are understandably concerned about the potential long-lasting adverse effects on their appearance. Understanding the range of options available and the potential treatment outcomes is an important component of helping these patients reach a desired outcome. Moreover, cosmetic treatments can improve a person's self-image and, by extension, quality of life. When our patients feel comfortable with their bodies, they project self-confidence that others pick up on, which may lead to social and economic benefits.

Although many treatments are available, in this chapter we present favored treatment strategies. A comprehensive list of treatment options for specific conditions is summarized in Tables 40-1 and 40-2.

APPROACH TO TREATMENT

Evaluation of the Cosmetic Patient

The patient seeking advice and treatment for cosmetic concerns generally has a desired outcome in mind. The experienced clinician will help the patient identify these goals and accordingly choose an appropriate procedure. As part of this process, the astute physician will be realistic about the potential to achieve the patient's primary cosmetic goals.

Every cosmetic surgeon will, at some point, be confronted with a patient who has unreasonable expectations. That is, the patient will have an outcome in mind that cannot realistically be achieved with any of the physician's treatment modalities. While it is true that cosmetic surgery can often improve a person's self-image and quality of life, patients with unrealistic expectations are unlikely to benefit in this manner, and they are more likely to be dissatisfied with their treatment and, by extension, their provider.^{1,2}

Patients with body dysmorphic disorder (BDD) represent a special subset of cosmetic patients with unreasonable expectations. BDD, a psychiatric condition that manifests as an unhealthy preoccupation with minor or imagined defects in one's appearance, may be exacerbated by cosmetic surgery as the underlying issue is primarily psychiatric. While it may be difficult to diagnose mild cases of BDD based solely on an initial consultation, ultimately the cosmetic dermatologist is responsible for his patients' health and should develop a sense of when a procedure is unlikely to satisfy the patients' needs or lead to poor outcomes.

Fine and Deep Wrinkles

Fine wrinkles (rhytides), particularly around the eyes and mouth, are a common patient concern. They are related to natural aging and chronic sun exposure within the superficial dermis and epidermis. Chemical peels, lasers and light devices, and long-term use of topical retinoids as mono-therapy or in combination, can redress some of

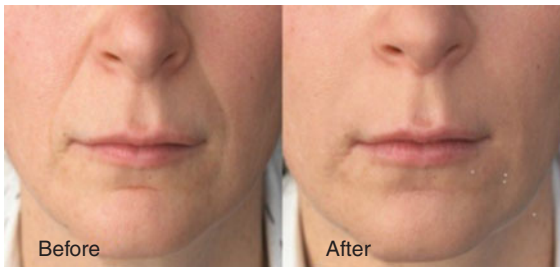Table 40-1. Non-surgical and minimally invasive treatment modalities for cosmetic disorders.

Modality	Cosmetic Disorders	Potential Adverse Effects
Topical products		
Retinoids	Fine and deep wrinkles, lax skin, lentigines, melasma, and depressed scars	Irritation
Sunscreen	Facial erythema, facial telangiectasias, lentigines, and melasma	None
Tyrosinase inhibitors	Lentigines, melasma	Irritation
Silicone gel sheeting	Elevated scars	None
Eflornithine	Hair removal	Irritation
Minoxidil	Hair restoration	Irritation and hypertrichosis
Bimatoprost	Eyelash growth	Irritation and hypertrichosis
Oral medication		
5- α reductase inhibitors	Hair restoration	Sexual dysfunction, gynecomastia, and teratogenic (hypospadias)
Minimally invasive		
Botulinum toxin	Fine and deep wrinkles, ptosis, and hyperhidrosis	Asymmetry and brow/lid ptosis
Fillers	Fine and deep wrinkles, lax skin, depressed scars, and volumetric reduction	Asymmetry, allergy, granulomatous reaction, bruising, and vascular occlusion
Autologous fat transfer	Fine and deep wrinkles, lax skin, depressed scars, and volumetric reduction	Asymmetry and variable results
Mesotherapy (ATX101)	Excess body fat	Bruising and discomfort
Subcision	Depressed scars	Pain and bruising
Sclerotherapy	Spider and varicose veins	Postinflammatory hyperpigmentation, and coagulum
Intralesional 5-fluorouracil	Elevated scars and keloids	Necrosis and postinflammatory hyper- or hypopigmentation
Intralesional corticosteroid	Elevated scars and keloids	Atrophy, hypopigmentation
Physical treatments		
Chemical peels	Fine and deep wrinkles, lentigines, melasma, and depressed scars	Irritation, erythema, scar, and postinflammatory hyper- or hypopigmentation
Dermabrasion	Fine and deep wrinkles, lentigines, melasma, and depressed scars	Irritation, erythema, scar, and postinflammatory hyper- or hypopigmentation
Cryotherapy	Lentigines and elevated scars	Blister, scar, and postinflammatory hyper- or hypopigmentation
TCA CROSS technique	Depressed scars	Scar and postinflammatory hyper- or hypopigmentation
Pressure	Elevated scars	None
Compression stockings	Spider veins	None

Table 40-2. Surgical and devices/laser treatment modalities for cosmetic disorders.

Modality	Cosmetic Disorders	Potential Adverse Effects
Surgical		
Facelift	Deeper wrinkles, lax skin	^a
Suture suspension lift	Deep wrinkles, lax skin	^a
Blepharoplasty	Lax skin	^a
Liposuction	Excess body fat	^a
Abdominoplasty	Lax skin	^a
Punch excision	Depressed scars	Scar
Surgical excision	Elevated scars and tattoo removal	^a
Hair transplantation	Hair restoration	Infection
Devices/lasers		
KTP ^b	Facial erythema and telangiectasia, spider veins, lentigines, melasma, and tattoo removal	Blister, scar, postinflammatory hyper- or hypopigmentation
Pulsed-dye laser	Facial erythema and telangiectasia, spider veins, lentigines, elevated scars, and facial rejuvenation	Blister, scar, and postinflammatory hyper- or hypo-pigmentation
Ruby ^b	Lentigines, melasma, hair removal, and tattoo removal	Blister, scar, and postinflammatory hyper- or hypopigmentation
Alexandrite ^b	Facial erythema and telangiectasia, spider veins, lentigines, hair removal, and tattoo removal	Blister, scar, and postinflammatory hyper- or hypopigmentation
Diode	Facial erythema and telangiectasia, spider veins, and hair removal	Blister, scar, and postinflammatory hyper- or hypopigmentation
Nd:YAG ^b	Facial erythema and telangiectasia, spider veins, lentigines, melasma, hair removal, and tattoo removal	Blister, scar, and postinflammatory hyper- or hypopigmentation
Intense-pulsed light	Facial erythema and telangiectasia, lentigines, melasma, and hair removal	Blister, scar, and postinflammatory hyper- or hypopigmentation
Non-ablative lasers (fractionated)	Lentigines, melasma, depressed scars, elevated scars, and facial rejuvenation	Erythema, blister, scar, and postinflammatory hyper- or hypopigmentation
Ablative resurfacing lasers	Fine and deep wrinkles, lax skin, lentigines, melasma, depressed scars, elevated scars, and facial rejuvenation	Erythema, blister, scar, and postinflammatory hyper- or hypopigmentation
Plasmakinetic energy	Fine and deep wrinkles, lax skin, lentigines, depressed scars, elevated scars, and facial rejuvenation	Erythema, blister, scar, and postinflammatory hyper- or hypopigmentation
Cryolipolysis	Excess body fat	Asymmetry and pain
Low-level light	Hair restoration	None
Radiofrequency	Lax skin and excess body fat	Asymmetry and pain
High-intensity ultrasound	Lax skin and excess body fat	Asymmetry and pain
Electrolysis	Hair removal	Scar and postinflammatory hyper- or hypopigmentation

^aCommon surgical adverse events: scar, infection, hematoma, asymmetry, and nerve damage.^bContinuous wave versus Q-switched.



▲ **Figure 40-1.** Filler before and after. The nasolabial folds and pre-jowl sulcus before (left) and after (right) injection of a hyaluronic acid filler. Note how the profile of the folds is significantly reduced, giving the central and lower face a rejuvenated, more youthful appearance.

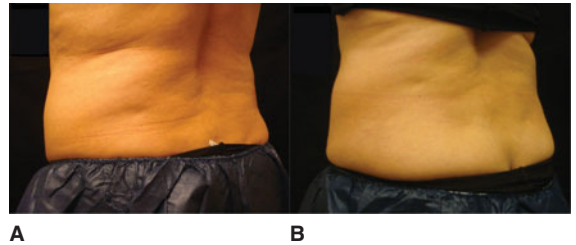
this structural damage and treat fine rhytides.³ Deep rhytides, both dynamic and static, are multifactorial and caused by years of underlying muscle movement, age-related soft-tissue volume loss, and deeper structural changes due to facial bone resorption. Botulinum toxin and dermal fillers can be used to treat periorbital, glabella, and perioral rhytides.⁴ Deeper rhytides, particularly in the nasolabial folds, and the prejowl sulcus, can be softened to become less prominent with fillers alone (Figure 40-1). A combination of botulinum toxin, dermal fillers, and rejuvenating lasers can be effective in treating patients with both fine and deep rhytides.^{3,5,6}

Lax Skin

The appearance of lax skin is a manifestation of aging, particularly on the face and neck due to age-related loss of elastic tissues, fat, muscle, and bone. Treatment options include filling the underlying tissue, tightening the lax skin, or surgical excision.³⁻⁸ Topical agents can serve as adjuncts, but the combination of dermal fillers and devices that induce neocollagenesis and new elastin (resurfacing and/or fractionated lasers) can provide excellent cosmetic rejuvenation.^{3-6,9,10}

Excess Body Fat

Liposuction has traditionally been the procedure of choice for the treatment of excess body fat.¹¹ Recently, noninvasive devices have been developed that target fat and induce lipolysis. These modalities include cryolipolysis (Figure 40-2), radiofrequency, and high-intensity focused ultrasound.¹² Mesotherapy is an injectable approach to treating medical and aesthetic problems, but has a checkered history. Current mesotherapy agents are imprecise and fraught with complications, but newer agents such as Kythera's ATX-101 are being developed which are safe, predictable, and efficacious in reducing submental fat.¹³



▲ **Figure 40-2.** Cryolipolysis. Before (A) and after (B) photographs of a patient who had undergone cryolipolysis. With this modality, the superficial fat layers can be induced to apoptose. Commonly treated areas include the upper and lower abdomen and flanks, as in this patient.

Facial Erythema and Facial Telangiectasia

There are numerous causes for facial erythema, from inflammatory to neoplastic and actinic. Because this chapter is focused mainly on cosmetic concerns, we will address the cosmetic treatment of port-wine stains, rosacea, and photodamage with associated telangiectases. Sunscreen use can mitigate the erythema associated with photoaging and rosacea, and is also an adjunct to the vascular lasers. A variety of vascular lasers can be used, although the 595 nm pulsed-dye laser (PDL) and the 532 nm KTP laser are very effective and commonly used.^{14,15} Intense-pulsed light (IPL) is also very effective when treating large areas of pigmentation, atrophy, and telangiectases on the face, neck, and chest, generally referred to as poikiloderma.¹⁴

Spider Veins

Commonly found on the legs, these superficial dilated veins are best removed by direct injection of a sclerosing agent (sclerotherapy) or very occasionally by destruction with a deeply penetrating vascular laser such as the 755 nm Alexandrite or the 1064 nm Nd:YAG.¹⁶⁻¹⁸ Compression stockings are an adjunct treatment and may be used for secondary prevention.

Lentigines

Lentigines are epidermal cutaneous lesions indicative of photodamage. They can be treated with a variety of agents. Common topical regimens include a tyrosinase inhibitor (eg, hydroquinone), with or without a topical retinoid, and sunscreen to mitigate recurrence and repigmentation.¹⁹ Superficial and medium-depth peels are sufficient to treat these superficial lesions, although repeat treatments may be needed.^{20,21} Q-switched lasers (eg, QS 532 nm KTP, QS 694 nm Ruby, and the QS 755 nm Alexandrite), the normal-mode 532 nm KTP, the IPL, and the 1927-nm

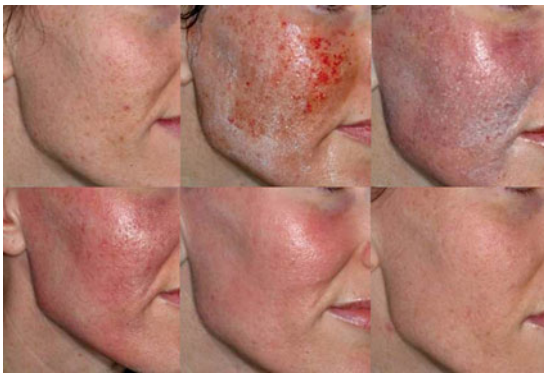Thulium fractionated laser are devices that can effectively be used for the treatment of lentigines.²²

Melasma

Treatment of melasma can be very difficult, particularly due to the frustrating ease with which repigmentation occurs. Epidermal melasma can be treated in a similar manner as lentigines, with topical sunscreens, tyrosinase inhibitors, retinoids, and lasers or chemical peels.^{22,23} Dermal melasma is much more difficult to treat, although fractionated lasers may enhance the efficacy of topically applied tyrosinase inhibitors.^{22,23} Avoidance of all pigmentary triggers should be stressed, including regular sunscreen use and sun avoidance.²³

Depressed Scars

Multiple modalities exist for treatment of depressed scars. Topical retinoids may improve the superficial texture of scars. Treatments that induce new collagen and improve the texture and tone of scars include chemical peels, resurfacing and/or fractionated lasers, and subcision.^{3,5,9,21,24} Individual scars can be improved with dermal fillers, treated with a pinpoint trichloroacetic acid (TCA) application (CROSS technique), or excised with small punch excisions.²⁴ Fractional resurfacing can achieve excellent results in a safe and predictable manner (Figure 40-3).^{3,5,9,25}



▲ **Figure 40-3.** Predictable wound healing and treatment response of a fractionated ablative laser. A patient with acne scarring and lentigines. Six consecutive images are shown, demonstrating the predictable healing sequence of the fractionated CO₂ ablative laser. From left to right (top row) are preoperative, postoperative, and 3-day follow-up pictures. Note the pinpoint bleeding immediately after the procedure and how the skin has healed with only residual erythema by day 3. At 1 week (lower left), most of the erythema has resolved. At 1 month (lower middle), the patient has notable improvement in texture, tone, and color, which is maintained 3 months postprocedure (lower right).

Elevated Scars

Intralesional triamcinolone is the mainstay of treatment for elevated scars. Combination treatments that include intralesional 5-fluorouracil, the PDL, and resurfacing and/or fractionated lasers can also be effective for larger or recalcitrant lesions.^{5,24} Silicone gel sheets are also favored by many dermatologists as a painless adjunct but have limited benefits.

Hair Removal

Permanent hair removal can be achieved with various lasers and is most efficacious in fair-skinned patients with dark coarse hairs. The 810 nm diode and 755 nm Alexandrite lasers are most commonly used, although the 1064 nm Nd:YAG laser may be safer to use in patients with darker skin tones.²⁶ Multiple treatments are commonly needed. Eflornithine (Vaniqa) cream may be a useful adjunct but is not a permanent solution as it simply slows hair growth.

Hair Restoration

Treatment of hair loss depends on a number of factors, most of which address the specific cause of hair loss. For inflammatory alopecias, control of the inciting inflammation is paramount to treating the alopecia. If there is any residual scarring, hair transplants may repopulate the cicatricial patches if the underlying inflammation is quiescent. Inhibitors of 5- α reductase such as finasteride can be used in androgenic alopecia. Hair transplantation may yield the best natural-appearing outcome, although not all patients may be eligible candidates.²⁷

Tattoo Removal

The mainstay of tattoo removal is laser therapy, and a variety of lasers can be used for this purpose.²⁸ Multicolored tattoos may require treatment with more than 1 laser. Successful treatment, in general, requires multiple treatments. Extreme caution should be taken, however, in the treatment of white, red, orange, yellow, turquoise, lavender, pink, tan, and brown tattoos as they may contain either titanium dioxide or ferric oxide.²⁸ Laser treatment of these 2 metal oxides can result in immediate pigment darkening. Fractionated ablative lasers are nonselective but may allow transepidermal elimination of pigment, particularly after treatment with a Q-switched laser.²⁹ A new technique is the Dora Q4 protocol, which calls for 4 sequential laser passes at 20-minute intervals, resulting in more rapid and effective clearing of tattoos compared to traditional therapies.³⁰ Finally, traditional laser ablation (with the CO₂ or Er:YAG lasers) or surgical excision may be used to physically remove the tattoo. These latter two treatments are the mainstay of tattoo removal when concerned about hypersensitivity to tattoo particles, as treatment with the q-switched lasers can result in anaphylaxis in a sensitized

individual.^{28,29} Chrysiasis (cutaneous gold deposition) can be difficult to treat, and paradoxical darkening does occur with some lasers.³¹ However, laser treatment of argyria (cutaneous silver deposition) has recently been reported to be safe and efficacious, though quite painful.³²

The on-line learning center at www.LangeClinicalDermatology.com has a self assessment quiz for this chapter.

REFERENCES

- Ericksen WL, Billick SB. Psychiatric issues in cosmetic surgery. *Psychiatr Q*. 2012;83(3):343–352. PMID: 22252848.
- Napolean A. The presentation of personalities in plastic surgery. *Ann Plast Surg*. 1993;31:193–208. PMID: 8239409.
- Rahman Z, MacFalls H, Jiang K, et al. Fractional deep dermal ablation induces tissue tightening. *Lasers Surg Med*. 2009;41(2):78–86. PMID: 19226572.
- Romagnoli M, Belmontesi M. Hyaluronic acid-based fillers: theory and practice. *Clin Dermatol*. 2008;26(2):123–159. PMID: 18472056.
- Hunzeker CM, Weiss ET, Geronemus RG. Fractionated CO₂ laser resurfacing: our experience with more than 2000 treatments. *Aesthet Surg J*. 2009;29(4):317–322. PMID: 19717066.
- Tierney EP, Hanke CW, Watkins L. Treatment of lower eyelid rhytids and laxity with ablative fractionated carbon-dioxide laser resurfacing: case series and review of the literature. *J Am Acad Dermatol*. 2011;64(4):730–740. PMID: 2141449.
- De Assis Montenegro Cido Carvalho F, Vieira da Silva V Jr, Moreira AA, Viana FO. Definitive treatment for crow's feet wrinkles by total myectomy of the lateral orbicularis oculi. *Aesthet Plast Surg*. 2008;32(5):779–782. PMID: 18600373.
- Castello MF, Lazzeri D, Silvestri A, et al. Modified superficial musculoaponeurotic system face-lift: a review of 327 consecutive procedures and a patient satisfaction assessment. *Aesthet Plast Surg*. 2011;35(2):147–155. PMID: 20871998.
- Hantash BM, Bedi VP, Kapadia B, et al. In vivo histological evaluation of a novel ablative fractional resurfacing device. *Lasers Surg Med*. 2007;39(2):96–107. PMID: 17311274.
- Sapijaszko MJ, Zachary CB. Er:YAG laser skin resurfacing. *Dermatol Clin*. 2002;20(1):87–96. PMID: 11859597.
- Tierney EP, Kouba DJ, Hanke CW. Safety of tumescent and laser-assisted liposuction: review of the literature. *J Drugs Dermatol*. 2011;10(12):1363–1369. PMID: 22134559.
- Mulholland RD, Paul MD, Chalfoun C. Noninvasive body contouring with radiofrequency, ultrasound, cryolipolysis, and low-level laser therapy. *Clin Plast Surg*. 2011;38(3):503–520. PMID: 21824546.
- Duncan D, Rotunda AM. Injectable therapies for localized fat loss: state of the art. *Clin Plast Surg*. 2011;38(3):489–501. PMID: 21824545.
- Neuhaus IM, Zane LT, Tope WD. Comparative efficacy of nonpurpuragenic pulsed dye laser and intense pulsed light for erythematotelangiectatic rosacea. *Dermatol Surg*. 2009;35(6):920–928. PMID: 19397667.
- Tierney E, Hanke CW. Randomized controlled trial: comparative efficacy for the treatment of facial telangiectasias with 532 nm versus 940 nm diode laser. *Lasers Surg Med*. 2009;41(8):555–562. PMID: 19746429.
- Mann MW. Sclerotherapy: it is back and better. *Clin Plast Surg*. 2011;38(3):475–487. PMID: 21824544.
- Duffy DM. Sclerosants: a comparative review. *Dermatol Surg*. 2010;36(suppl 2):1010–1025. PMID: 20590708.
- McCoppin HH, Hovenic WW, Wheeland RG. Laser treatment of superficial leg veins: a review. *Dermatol Surg*. 2011;37(6):729–741. PMID: 21605232.
- Ortonne JP, Pandya AG, Lui H, Hexsel D. Treatment of solar lentigines. *J Am Acad Dermatol*. 2006; 54 (5 suppl 2): S262–S271. PMID: 16631967.
- Rendon MI, Berson DS, Cohen JL, Roberts WE, Starker I, Wang B. Evidence and considerations in the application of chemical peels in skin disorders and aesthetic resurfacing. *J Clin Aesthet Dermatol*. 2010;3(7):32–43. PMID: 20725555.
- Landau M. Chemical peels. *Clin Dermatol*. 2008;26(2):200–208.
- Folger KD, Landau JM, Vergilis-Kalner IJ, Goldberg LH, Friedman PM, Bruce S. Laser eradication of pigmented lesions: a review. *Dermatol Surg*. 2011;37(5):572–595. PMID: 21492309.
- Gupta AK, Gover MD, Nouri K, Taylor S. The treatment of melasma: a review of clinical trials. *J Am Acad Dermatol*. 2006;55(6):1048–1065. PMID: 17097400.
- Cooper JS, Lee BT. Treatment of facial scarring: lasers, filler, and nonoperative techniques. *Facial Plast Surg*. 2009;25(5):311–315. PMID: 20024872.
- Ortize AE, Tremaine AM, Zachary CB. Long-term efficacy of a fractional resurfacing device. *Lasers Surg Med*. 2010;42(2):168–170. PMID: 20166157.
- Ibrahimi OA, Avram MM, Hanke CW, Kilmer SL, Anderson RR. Laser hair removal. *Dermatol Ther*. 2011;24(1):94–107. PMID: 21276162.
- Barrera A. The use of micrografts and minigrafts in the aesthetic reconstruction of the face and scalp. *Plast Reconstr Surg*. 2003;112(3):883–890. PMID: 12960872.
- Choudhary S, Elsaie ML, Leiva A, Nouri K. Lasers for tattoo removal: a review. *Lasers Med Sci*. 2010;25(5):619–627. PMID: 20549279.
- Ibrahimi OA, Syed Z, Sakamoto FH, Avram MM, Anderson RR. Treatment of tattoo allergy with ablative fractional resurfacing: a novel paradigm for tattoo removal. *J Am Acad Dermatol*. 2011;64(6):1111–1114. PMID: 21571169.
- Dora Q4 Technique. <http://www.drzachary.net/2010/09/22/laserinnsbruck-2010/>.
- Wu JJ, Papajohn NG, Murase JE, Verkruysse W, Kelly KM. Generalized chrysiasis improved with pulsed dye laser. *Dermatol Surg*. 2009;35(3):538–542. PMID: 19292841.
- Rhee DY, Chang SE, Lee MW, Choi JH, Moon KC, Koh JK. Treatment of argyria after colloidal silver ingestion using Q-switched 1064-nm Nd:YAG laser. *Dermatol Surg*. 2008;34(10):1427–1430. PMID: 18657163.

Index

Note: Page numbers followed by *f* and *t* indicate figures and tables, respectively.

- A**
- Acanthosis nigricans**, 201, 223*f*
- Acne**, 35, 128–133, 129*f*
- acne vulgaris, face, 269*t*
 - in adolescents, 128
 - clinical presentation
 - history, 129
 - laboratory findings, 130
 - physical examination, 129–130
 - comedonal (*See* Comedonal acne)
 - differential diagnosis, 130, 145
 - indications for consultation, 133
 - lesions, 129
 - management
 - general guidelines for use of medications, 133
 - treatment, medication for, 130–131, 131*t*
 - treatment options, 132–133
 - mild, 130
 - moderate, 130
 - nodular, 129, 133
 - oral antibiotics, 132*t*
 - papular/pustular, 129 (*See* Papular/pustular acne)
 - pathophysiology, 128
 - patient information, 133
 - severe, 130
 - trunk, 279*t*
- Acquired melanocytic nevi**
- clinical presentation
 - history, 163
 - laboratory findings, 165
 - physical examination, 163–165
 - diagnosis, 165–166
 - differential, 166
 - indications for consultation, 166
 - management, 166
 - pathophysiology, 163
 - patient information, 166
- Acquired vascular lesions**
- (cherry hemangioma, venous lake, spider angioma), 149
 - clinical presentation
 - differential diagnosis, 149
 - history and physical examination, 149
 - laboratory findings, 149
 - indications for consultation, 149
 - management, 149
 - patient information, 149
- Acral lentiginous melanoma**, 171, 171*f*
- Actinic keratoses**, 154, 155*f*
- clinical presentation
 - history, 154
 - laboratory findings, 155
 - physical examination, 154–155
 - diagnosis, differential, 155
 - faces, 270*t*
 - hands, 276*t*
 - indication for consultation, 156
 - management, 155–156
 - pathophysiology, 154
 - patient information, 156
 - scalp, 267*t*
- Acute generalized exanthematous pustulosis**, 122, 123
- Acyclovir**
- in herpes zoster, 295
 - recurrent oral-labial herpes simplex, 294–295, 295*t*
 - suspension, 295
- Addison's disease**, 195, 201
- Adverse drug reactions**, 121–127, 122*t*
- clinical presentation
 - history, 122
 - laboratory findings, 123–124
 - physical examination, 122–123
 - coumadin necrosis, 125*f*
 - cutaneous adverse drug reactions, 124*t*–125*t*
 - diagnosis, 124–126
 - differential, 125–126
 - drug rash, 121, 123, 123*f*
 - exfoliative erythroderma, 124*t*, 126*f*
 - fixed drug eruption, 123, 124*f*
 - hyperpigmentation, 126*f*
 - indications for consultation, 126
 - management, 126
 - morbilloform drug eruption, 123*f*
 - pathophysiology, 122
 - patient information, 127
 - Sweet's syndrome, 125*f*
- Aldolase**, 222
- Alexandrite lasers**, 327
- Allergic contact dermatitis**, 18, 23, 28*t*, 45, 47–49, 51, 131, 136, 265, 275*t*, 284*t*, 316*t*
- acute, 50*f*, 51*f*
 - arms, 273*t*
 - clinical presentation, 50
 - diagnosis, 50
 - differential diagnosis, 286*t*, 316*t*
 - feet diseases, 284*t*
 - multiple body regions, 286*t*
 - due to nickel, 51*f*
 - face, 269*t*
 - feet, 284*t*
 - hands, 275*t*
 - indications for consultation, 52
 - management, 51–52
 - pathophysiology, 49–50
 - patient information sites, 52
 - scalp, 266*t*
 - skin allergens, 51*t*
 - topical steroids for treatment, 50*t*
 - trunk, 278*t*
- Allergies**
- and medication intolerances, 16
- Alopecia areata**, 73, 192, 192*f*
- Amalgam tattoo**, 312*f*
- Amelanotic melanoma**, 171, 171*f*
- Anaphylaxis-type reaction**, 117, 118
- Angioedema**, 117, 119, 119*f*, 120, 121, 125–126
- Angiotensin-converting enzyme (ACE) inhibitors**, 117, 120
- Angular cheilitis**, 86
- clinical presentation, 86
 - diagnosis, 86
 - management, 86
 - patient information, 86
- Ankle-brachial index**, 262
- Antifungal medications**, 35, 315
- Antihistaminics (H1 and H2)**, 222
- Antinuclear antibody (ANA)**, 219
- Antiviral medications**, 35
- Aphthous stomatitis**, 90
- Argyria**, laser treatment of, 328
- Arms**, skin diseases, 272–273
- diagnosis, approach, 272
 - differential diagnosis for, 273*t*
 - evaluation, 272
- Arterial ulcers**, 262–263, 262*f*
- clinical presentation, 262
 - diagnosis/differential diagnosis, 262–263
 - indications for consultation, 263
 - management, 263
 - pathophysiology, 262
 - therapy of, 263
- Arthropod bites**, 107, 115
- Ash leaf spots**, 197
- Asteatotic dermatitis**, legs, 281*t*

- Atopic dermatitis, 7*f*, 9*f*, 18, 33, 49, 50, 52, 53*f*, 55, 63, 98, 107, 272, 284*t*, 285
 arms, 273*t*
 clinical presentation, 53–54
 diagnosis, 54
 diagnostic guidelines, 52
 differential diagnosis, 286*t*
 face, 269*t*
 feet, 284*t*
 hands, 275*t*
 indications for consultation, 56
 management, 54–56
 multiple body regions, 286*t*
 pathophysiology, 52–53
 patient information sites, 56
 scalp, 266*t*
- Atypical nevi, 167*f*
 characteristics, 167*t*
 clinical presentation
 history, 167
 laboratory findings, 167
 physical examination, 167
 diagnosis differential, 167
 indications for consultation, 167–168
 management, 167
 pathophysiology, 166–167
 patient information, 168
- Autoimmune disease, 196
- Azelaic acid, 132
- B**
- Basal cell carcinoma, 14*f*, 17*f*, 29*t*, 45, 145, 154, 156, 157*f*, 159
 clinical presentation
 history and physical examination, 156
 laboratory findings, 157
 diagnosis, 157–158
 differential, 145, 158, 161
 indications for consultation, 159
 management, 158–159
 electrodessication and curettage, 158
 Mohs micrographic surgery, 158
 photodynamic therapy, 158
 standard excision, 158
 systemic therapy, 159
 topical treatments, 158
 pathophysiology, 156
 patient information, 159
 treatment of, 158
- Beau's lines, 191, 191*f*
- Bed bug, 114–116
 bites on back, 115*f*
Cimex lectularius, 114–115, 114*f*
 clinical presentation, 115
 history, 115
 laboratory findings, 115
 physical examination, 115
 consultation, 115
- diagnosis, 115
 differential, 115
 feces, and molted skin, 114*f*
 management, 115
 pathophysiology, 114–115
 patient information, 116
- Behçet's disease, 292
- Benign mucous membrane pemphigoid, 296, 296*f*
 tongue, affecting, 296
- Benign nevus, dermoscopic image, 165*f*
- Benign tumors, and vascular lesions, 141–152
 acquired vascular lesions (cherry hemangioma, venous lake, spider angioma), 149
 congenital hemangioma, 152
 dermatofibroma (histiocytoma), 143–144
 digital mucous cyst, 148–149
 epidermal (epidermoid) cyst, 146–147
 infantile hemangioma (superficial, mixed or deep), 151–152
 keloid/hypertrophic scar, 145–146
 lentigo, 142–143
 lipoma, 145
 milia, 147–148
 pilar cyst, 147
 pyogenic granuloma, 149–150
 sebaceous hyperplasia, 144–145, 144*f*
 seborrheic keratoses, 141–142
 skin tag (acrochordon, cutaneous papilloma), 144
 vascular lesions in infants, 150
 vascular malformation (port-wine stain, stork bite, angel kiss), 150–151
- Benzoyl peroxide, 131, 133
- Bleeding, 45
- Blue nevus, 164, 165*f*
- Body dysmorphic disorder, 323
- Body fat, 326
- Body louse, 108
 management, 110
- Boils, 27*t*, 47, 98, 99, 138
 and acne cyst, differential diagnosis, 147
 clinical presentation, 99
 diagnosis, 99
 management, 99
 pathophysiology, 98
 patient information, 99
 staphylococcal, 99*f*
- Borrelia burgdorferi*, 110
- Bowen's disease, 159, 160*f*
- BRAF mutation, 169
- Brown-black discoloration, of tongue, 312, 313*f*
- Bug bites
 differential diagnosis, 289*t*
 multiple body regions, 289*t*
- Bullous pemphigoid, 26*f*, 98, 105, 124*t*, 204–206, 208, 254, 267*t*, 288*t*, 296
 clinical presentation, 204
 differential diagnosis, 205, 288*t*
 indications for consultation, 206
 laboratory findings, 204, 205, 206*t*
 management, 205
 multiple body regions, 288*t*
 pathophysiology, 204
 patient information, 206
 physical examination, 204
 scalp, 267*t*
- Bullous scabies, 105
- C**
- Café au lait spots, 201
- C. albicans*, 299
- Calcineurin-inhibiting agents, 63
- Calcineurin inhibitors, 219
- Calciphylaxis, 236
- Calcipotriol (calcipotriene), 63
- Calcitonin gene-related peptide (CGRP), 5
- Calciotriol, 63
- Candidiasis, 83, 84, 85*f*, 86*f*, 299–301, 304, 318*f*
 clinical presentations, 85–86
 denture stomatitis, 301*f*
 differential diagnosis, 316*t*
 erythematous, 300–301
 hyperplastic, 301
 mucocutaneous, 301
 oral mucosa, 299
 pathophysiology, 84
 pseudomembranous, 299–300
 trunk, 278*t*
- Canker sores, 290, 292
- Cellulitis, 28*f*, 99, 100*f*
 clinical presentation, 100
 differential diagnosis, 100
 feet, 284*t*
 indications for consultation, 101
 legs, 281*t*
 management, 101
 patient information, 101
 types of, 101*t*
- Cephalexin, 45
- Chemical leukoderma, 197
- Chemotherapy, 253
- Cherry angiomas, 149, 149*f*
- Chicago sky blue, 21*f*
- Chickenpox. *See* Varicella
- Chronic sun damage, 135
- Chrysiasis, 328
- Cicatricial alopecias, 266*t*
- Cimex lectularius*, 114, 114*f*
- Closed comedones, 148
- Clotrimazole, 76*t*, 84, 301
- Collagen, 5
- Comedonal acne, 129, 132
- Comedone extractors, 133
- Common acquired melanocytic nevi, 168

- Condylomata accuminata, 94, 308
- Congenital nevi, categories and size, 168*t*
- Congenital hemangioma, 152
- clinical presentation
 - differential diagnosis, 152
 - history and physical examination, 152
 - laboratory findings, 152
 - indications for consultation, 152
 - management, 152
- Congenital melanocytic nevi, 168–169
- clinical presentation
 - history, 168
 - laboratory findings, 168
 - physical examination, 168
 - diagnosis differential, 168
 - indications for consultation, 169
 - management, 169
 - patient information, 169
- Congenital melanocytic nevus, 168, 168*f*
- Connective tissues diseases, 219, 288*t*
- Contact dermatitis, 47
- Contact hypersensitivity reaction, 303
- Coomb's type II and III reactions, 122
- Corticosteroid, 59
- Cosmetic disorders
- non-surgical and minimally invasive treatment modalities, 324*t*
 - surgical and devices/laser treatment modalities, 325*t*
- Cosmetic patient. *See also* Cosmetic disorders
- cryolipolysis, 326*f*
 - depressed scars, 327
 - elevated scars, 327
 - evaluation of, 323
 - excess body fat, 326
 - facial erythema/telangiectasia, 326
 - filler, 326*f*
 - fine wrinkles, 323–326
 - hair removal, 327
 - hair restoration, 327
 - lax skin, 326
 - lentigines, 326–327
 - melasma, 327
 - spider veins, 326
 - tattoo removal, 327–328
- Coumadin necrosis, 125*f*
- Crab lice, 108, 109*f*
- management, 110
- Creatine phosphokinase, 222
- Cross-polarizing filters, 165
- CROSS technique, 327
- Cryoglobulinemia, 231
- Cryolipolysis, 326*f*
- Cryosurgical devices, 43
- Cryotherapy, 44, 95, 144
- management, 155
- Curettage, 44
- Cutaneous adverse drug reactions, 121
- diagnosis of, 124
 - management of, 126
 - type of, 124
- Cutaneous disorders, 15
- benign tumors and dermatoses, and malignant mimics, 39*t*
 - clinical presentations, 30*t*
 - diagnosis, 25
 - analytic method, 25
 - identification of primary lesions, 26
 - laboratory confirmation of, 28–29
 - pattern recognition, 25 - family history, 16
 - with high morbidity, 29
 - history of present illness (HPI), 15–16
 - medications, 16
 - past medical history, 16
 - patch testing, 23
 - review of systems, 16
 - social history, 16
 - Wood's light findings, 23*t*
- Cutaneous lupus erythematosus, 276*t*.
- See also* Systemic lupus erythematosus (SLE)
- Cutaneous sarcoidosis, 226*f*
- Cutaneous T-cell lymphoma, 267*t*
- D**
- Deep vein thrombosis, 100, 259
- Dehydroepiandrosterone sulfate (DHEA-S), 130
- Demodex folliculorum*, 133, 137
- Demodex/pityrosporum*, 138
- Dendritic cells, 1
- Depigmentation, 195
- Depressed scars, 327
- Dermal melasma, 327
- Dermatitis, 158, 161. *See also* Irritant
- contact dermatitis; Nummular dermatitis
- Dermatitis herpetiformis, 28*t*, 29, 39, 51, 98, 107, 205, 206, 208–209, 208*f*, 238, 288*t*
- clinical presentation, 208
 - differential diagnosis, 209, 288*t*
 - indications for consultation, 209
 - laboratory findings, 208, 208*f*, 209
 - management, 209
 - multiple body regions, 288*t*
 - pathophysiology, 208
 - patient information, 209
 - physical examination, 208
- Dermatofibroma (histiocytoma), 143–144, 143*f*
- clinical presentation
 - differential diagnosis, 143
 - history and physical examination, 143
 - laboratory findings, 143
- indications for consultation, 144
 - management, 144
 - patient information, 144
- Dermatofibrosarcoma protuberans, 143, 146
- Dermatographism, 119, 119*f*
- Dermatomyositis, 221
- clinical presentation, 221–222
 - differential diagnosis, 222
 - hands, 276*t*
 - history and physical examination, 221–222
 - indications for consultation, 222
 - laboratory findings, 222
 - management, 222
 - patient information, 222
 - scalp, 267*t*
- Dermatophytes, 71
- Dermatophyte test media (DTM), 20, 22*f*, 72
- Dermatoses, and morbidity, 28*t*
- Dermatosis papularis nigra, 142*f*
- Dermoscopy, 24, 106, 172
- adoption of, 165
- Desmoplastic melanomas, 172
- Diabetes mellitus, 222
- clinical presentation, 222
 - history and physical examination, 222
 - management, 223
- Diabetic dermopathy, legs, 282*t*
- Dichlorodiphenyltrichloroethane (DDT), 114
- Diffuse erythematous patchy, 285
- Digital mucous cyst, 148–149
- clinical presentation
 - differential diagnosis, 148
 - history and physical examination, 148
 - laboratory findings, 148
 - indications for consultation, 149
 - management, 148
 - patient information, 149
- Dihydroxyacetone (DHA), 36
- Discoid lupus erythematosus, 219, 220*f*
- clinical presentation, 219
 - differential diagnosis, 219
 - face, 270*t*
 - laboratory findings, 219
 - management, 219
- Dissecting cellulitis, scalp, 266*t*
- Dora Q4 protocol, 327
- Doxepin, 222
- Drug eruption, trunk, 279*t*
- Drug–protein complexes, 122
- Drug rash with eosinophilia and systemic symptoms (DRESS), 120, 122, 123
- DTM. *See* Dermatophyte test media (DTM)
- DVT. *See* Deep vein thrombosis (DVT)

- Dyshidrotic dermatitis, 27*t*, 28, 57, 58,
107, 275*t*, 283, 284*t*
acute, 57*f*
clinical presentation, 57
diagnosis, 57–58
feet, 284*t*
hands, 275*t*
management, 58
pathophysiology, 57
patient information sites, 58
Dysplastic nevi. *See* Atypical nevi
- E**
Ecchymosis, 229, 232*f*
causes, 232*t*
Ecthyma, 98
Eczema, 156
Eczema herpeticum (HSV), 54
Efloornithine cream, 327
Ehlers–Danlos syndrome, 5
Elastic fibers, 5
Electrocautery, 39, 40*f*
Electrodesiccation, 39
EM. *See* Erythema multiforme (EM)
Endocrine disorders, 222
Enzymatic/proteolytic agents, 260
Eosinophilic folliculitis, 137
Ephelis, on lower lip, 311*f*
Epidermal (epidermoid) cyst,
146–147
clinical presentation
differential diagnosis, 147
history and physical
examination, 146
laboratory findings, 146
indications for consultation, 147
management, 147
patient information, 147
Epidermal cyst, differential diagnosis,
145, 147
Epidermal nerve fibers, 5*f*
Epidermophyton floccosum, 72
Epstein–Barr virus (EBV), 121, 304
Epulides, 309–310
Eruptive xanthomas, 223, 223*f*
Er:YAG lasers, 327
Erythema, 10
Erythema multiforme (EM), 10*t*, 11*f*, 76,
98, 103, 113, 201, 210–213, 211*f*,
212*f*, 243, 247*t*–248*t*, 285, 286*t*,
296, 297*f*
clinical presentation, 211
differential diagnosis, 212, 286*t*
indications for consultation, 213
infections implicated, 211*t*
laboratory findings, 212
management, 212–213
multiple body regions, 286*t*
pathophysiology, 210–211
physical examination, 211
Erythema nodosum, 225, 226*f*
legs, 281*t*
Erythematotelangiectatic rosacea,
134, 134*f*
management, 135
physical examination, 134
Erythematous, 243
plaques, 27*f*
Erythrasma, 23*f*
differential diagnosis, 317*t*
Erythrodermic psoriasis, 62
Erythroleukoplakia, 304
of tongue, 305
Erythroplakia, 306
Erythroplakic lesion, of tongue, 306, 306*f*
Erythroplasia of Queyrat, 159, 160*f*
Evidence-based medicine, 132
Exfoliative erythroderma, 124*t*, 126*f*
Exophytic squamous cell carcinoma, 307*f*
- F**
Face, skin diseases
diagnosis, approach, 268
differential diagnosis, 269*t*–271*t*
evaluation, 268
ultraviolet (UV) light-induced
dermatoses, 268
Facial erythema/telangiectasia, 326
Famciclovir
herpes zoster, 295
recurrent oral-labial herpes
simplex, 295*t*
Familial melanoma, 172
Feet diseases
approach to diagnosis, 283
differential diagnosis, 284*t*
potassium hydroxide (KOH)
examination, 283
skin diseases, 283–284
Feet, skin diseases
diagnosis, approach, 283
differential diagnosis, 284*t*
evaluation, 283
Fever, 243
differential diagnosis, 244*t*–248*t*
evaluation, 243–244
Fiberglass dermatitis, 107
Fibroma, 309, 309*f*
Field therapy management, 155–156
Fissure, 9*f*
Fissured tongue, 299*f*
Fitzpatrick skin types, 15, 16*t*
Fixed drug eruptions, 123–124
Fluconazole
genital disease, 322
oral cavity diseases, 301
Folliculitis, 136–138, 137*f*
clinical presentation, 138
history, 138
laboratory findings, 138
physical examination, 138
diagnosis, differential, 138
indications for consultation, 138
management, 138
by microbes/noninfectious
processes, 137
pathophysiology, 137
patient information, 138
scalp, 266*t*
trunk, 278*t*
Fomite transmission, 108
Fordyce granules/spots, 290
Foreign body granuloma, 146
Fungal cultures, 20
Furuncle. *See* Boils
- G**
Genital anatomy, 315
Genital disease
candidiasis, 316*t*, 318*f*
diagnosis, 315, 316–320
differential, 316*f*–317*f*, 316*t*
erythrasma, 317*t*, 320*f*
evaluation of, 320–321
foreskin, 315
genital warts, 317*t*, 319*f*
herpes simplex, 317*t*, 319*f*
invasive squamous cell carcinoma,
317*t*, 321*f*
lichen sclerosus, 317*t*, 318*f*
lichen simplex chronicus, 316*t*, 318*f*
management of, 321–322
Paget's disease, 317*t*, 322*f*
perianal streptococcal disease, 317*t*, 320*f*
potassium hydroxide (KOH)
examination, 321
primary syphilis, 320*f*
in situ squamous cell carcinoma,
317*t*, 321*f*
tinea cruris, 316*t*, 319*f*
Genital warts human papillomavirus
(HPV), 246*t*, 317*t*
Geographic tongue, 298, 299*f*
vitamin B complex
supplementations, 299
zinc sulfate, 299
Gianotti–Crosti syndrome, 250*f*
Glomus tumor, 148
Gorlin's syndrome, 156
Graft *versus* host disease, 303
Gram-negative folliculitis, 138
Granuloma annulare, 222, 223*f*
differential diagnosis, 289*t*
multiple body regions, 289*t*
Grover's disease, 279*t*
Guttate hypomelanosis, 197
Guttate psoriasis, 61, 62*f*, 103
- H**
Habit tic, 192, 192*f*
Hair
physical examination, 16–17
steps, 17–19
removal, 327
restoration, 327
transplantation, 327

- Hairy leukoplakia, 304, 304f
Halo nevus, 164, 164f
Hand, foot, and mouth disease, 245t, 250f
Hands, skin diseases, 274–276
 diagnosis, approach, 274
 differential diagnosis for, 275t–276t
 evaluation, 274
Head lice, scalp, 266t
Head louse, 108, 108f
 management, 110
Health-related quality of life, 238
Heck's disease, 308f
Hematoma, mouth, 313f
Hematoxylin and eosin (H&E)
 staining, 161
Hemophilus influenza, 100
Hemostasis, 41
Henoch–Schönlein purpura, 231, 243, 251f
Hepatic disorders, 224
 differential diagnosis, 225
 history and physical examination, 224
 laboratory findings, 225
 management, 225
Herpes labialis, 294f
Herpes simplex. *See also* Herpes simplex viruses
 differential diagnosis, 317t
 primary and secondary, 294–295
 clinical presentation, 294–295
 management, 295
Herpes simplex labialis, face, 269t
Herpes simplex viruses (HSV), 52, 88, 253
 clinical presentation, 88–89
 differential diagnosis, 90
 indications for consultation, 90
 laboratory findings, 89–90
 management, 90
 oral medications, 90t
 pathophysiology, 88
 patient information, 90
 physical examination, 89
 recurrent, 89
 topical medications, 90t
Herpes zoster, 27f, 88, 295–296, 296f
 clinical presentation, 91
 differential diagnosis, 91, 287t
 face, 270t
 indications for consultation, 92
 management, 92
 multiple body regions, 287t
 pathophysiology, 91
 patient information, 92
 scalp, 266t
 trunk, 279t
Herpetic whitlow hands, 275t
Hidradenitis suppurativa, 138–140, 139f
 clinical presentation, 138
 history, 138–139
 laboratory findings, 139
 physical examination, 139
 differential diagnosis, 139, 317t
 indications for consultation, 139
 management, 139
 pathophysiology, 138
 patient information, 140
Hives. *See* Urticaria
Horn pseudocysts, 142
Hospital-acquired rashes, 253–258
 adverse drug reactions, 254
 common infections, 256t–257t
 differential diagnosis, 254t–255t
 uncommon dermatoses, 257t–258t
HPV vaccine, 95
Human herpes virus-1 (HSV-1), 88
Human herpes virus (HHV)-6 and -7, 67, 88
Human immunodeficiency virus (HIV), 121, 137, 315
Human papillomavirus (HPV), 159
Hydroquinone, 142
Hydroxychloroquine, 219
Hyperpigmentation, 125t, 126, 126f. *See also* Postinflammatory hyperpigmentation
Hyperproliferation, 128
Hypersensitivity, 292
Hypertrophic scar, 145, 146f
Hyponychium/onychodermal band, 188
Hypopigmentation, 43. *See also* Postinflammatory hypopigmentation
- I**
IgA deficiency, 292, 296
Imiquimod, 95
Immunobullous diseases, 204
Impetigo, 90, 97, 98f
 clinical presentation, 97–98
 differential diagnosis, 98
 face, 270t
 management, 98
 pathophysiology, 97
 patient information, 98
Infantile hemangioma, 151f
 clinical presentation
 differential diagnosis, 150, 152
 history and physical examination, 151
 indications for consultation, 152
 laboratory findings, 151–152
 management, 152
 patient information, 152
Infantile hemangioma (superficial, mixed or deep), 151–152
Infectious exanthems trunk, 279t
Infestations, and bites, 104–116
 bed bug, 114–116
 lice (pediculosis), 108–110
 Lyme disease, 110–114
 scabies, 104–108
Inflamed seborrheic keratosis, 158
Inflammatory, and infectious skin diseases, 27t
Insect bites, 120
Intense-pulsed light (IPL), 326
Intradermal nevi, 164f
Intradermal nevus, 158
Intraoral melanocytic nevi, 311–312
Intravenous immunoglobulin (IVIG), 120
Invasive melanoma, 172
Invasive squamous cell carcinoma, 159–160, 160f
Inverse psoriasis, 61
iPLEDGE program, 132
Iron deficiency, 299
Irritant contact dermatitis, 47, 48f, 136, 316t
 clinical presentation, 48
 diagnosis, 48
 face, 269t
 hands, 275t
 indications for consultation, 49
 management, 49
 pathophysiology, 47
 patient information, 49
Ixodes scapularis, 112f
- J**
Junctional nevi, 164f
- K**
Keloid/hypertrophic scar, 145–146
 clinical presentation
 differential diagnosis, 146
 history and physical examination, 145–146
 laboratory findings, 146
 indications for consultation, 146
 management, 146
 patient information, 146
Keloid scars, 146
Keratinization, 290. *See also* Oral cavity diseases
Keratinized, 315
Keratinocytes, 1
Keratoacanthomas, 160–161, 161f
Keratosis pilaris, 53f, 130, 138
 arms, 273t
Kerion scalp, 267t
Ketoconazole, 74, 76t, 84
 oral cavity diseases, 301
Klippel–Trenaunay syndromes, 151
Kythera's ATX-101, 326
- L**
Lactic acid, 34
Large actinic keratosis, 154, 155, 158, 159, 267t
Lax skin, 326
Legs, skin diseases
 diagnosis, approach, 280
 differential diagnosis, 281t–282t
 evaluation, 280–281

- Leg ulcers, 259–264
arterial insufficiency, 260
arterial ulcers, 262–263, 262f
clinical presentation, 262
diagnosis/differential diagnosis, 262–263
indications for consultation, 263
management, 263
pathophysiology, 262
therapy of, 263
complete blood count (CBC), 260
deep vein thrombosis (DVT), 259
differential diagnosis, 261t
hydrocolloid dressings, 260
neuropathic ulcers, 263–264, 263f
clinical presentation, 263
diagnosis/differential diagnosis, 263–264
indications for consultation, 264
management, 264
pathophysiology, 263
pyoderma gangrenosum, 261f
squamous cell carcinoma, 261f
venous ulcers, 259–262, 260f
clinical presentation, 259–260
diagnosis, 260
differential diagnosis, 260
indications for consultation, 262
management, 260–262
pathophysiology, 259
- Lentigines, 143f, 326–327
- Lentigo, 142–143
clinical presentation
differential diagnosis, 143
history and physical examination, 142–143
laboratory findings, 143
differential diagnosis, 142
indications for consultation, 143
management, 143
- Lentigo maligna melanoma, 169, 170f
- LEOPARD (Moynahan) syndrome, 142
- Leukocytoclastic vasculitis, 282t
- Leukoplakia, 304–306, 305, 305f
of tongue, 305f
- Lice (pediculosis), 108–110
body lice in, 109f
clinical presentation, 109
history, 109
laboratory findings, 109
physical examination, 109
crab louse, 109f
diagnosis, 109
differential diagnosis, 109
head louse, 108f
indications for consultation, 110
management, 110
nits attached to hair, 109f
pathophysiology, 108–109
patient information, 110
treatment, medications for, 111f
- Lichenification, 9f, 238
- Lichenoid drug reaction, 303
- Lichenoid lesions, 303f
on buccal mucosa, 303f
on tongue, 303f
- Lichen planus, 60, 68, 189–191, 191f, 302f
arms, 273t
clinical presentation, 68–69
diagnosis of, 303
differential diagnosis, 286t, 316t
hands, 275t
hyperpigmented lesions of, 201
indications for consultation, 69
management, 69
multiple body regions, 286t
pathophysiology, 68
patient information, 69
- Lichen sclerosis, 8t, 9f
- Lichen simplex chronicus, 58, 58f
arms, 273t
clinical presentation, 58
diagnosis, 58–59
differential, 316t
management, 59
pathophysiology, 58
patient information sites, 59
- Lidocaine toxicity, 40
- Lipoma, 145, 145f
clinical presentation
differential diagnosis, 145
history and physical examination, 145
laboratory findings, 145
indications for consultation, 145
management, 145
- Liposarcoma, 145
- Liposuction, 326
- Livedo reticularis (LR) legs, 282t
- Lupus erythematosus, 15, 222
- Luteinizing hormone/follicle stimulating hormone (LH/FSH), 130
- Lyme disease, 110–114
clinical presentation, 112
history, 112
laboratory findings, 112
physical examination, 112
diagnosis, 112–113
differential, 113
erythema migrans on trunk, 112f
indications for consultation, 114
instructions for prevention, 114
Ixodes scapularis, 112f
management, 113–114
pathophysiology, 110–112
patient information, 114
recommended treatment of, 113t
serological testing, CDC
recommendations for, 113f
- M**
- Malassezia* genus, 83
- Malignant melanoma, dermatoscopic image, 165f
- Measles, 249f
- Mechanical folliculitis, 137
- Melanin, 1, 2
pigmentation, 311f
production, 2
role, 2
- Melanoacanthoma, 312
- Melanocortin-1 receptor (MC1-R), 163
- Melanocytes, 2, 4, 196, 198
- Melanocytic lesion, 149
- Melanocytic nevi, 168
on oral mucosa, 311f
- Melanocytorrhagy, 196
- Melanoma, 16, 17f, 41, 170f, 142, 149, 158, 163, 165, 166, 169, 170f, 171–173, 188, 312f, 317t
clinical presentation
history, 169
physical examination, 169
differential diagnosis, 142, 143, 172
features, ABCDE rule for, 165t
indications for consultation, 173
laboratory findings, 172
management
asymptomatic melanoma, monitoring of patients with, 173
primary prevention and detection, 173
surgical management, 172–173
pathophysiology, 169
patient information, 173
presentations of, 171–172
primary surgical management, 173t
types of
acral lentiginous (See Acral lentiginous melanoma)
lentigo maligna (See Lentigo maligna melanoma)
nodular (See Nodular melanoma)
superficial spreading (See Superficial spreading melanoma)
- Melanoma/dysplastic nevus, 158
- Melanoma *in situ*, surgical management, 171, 172
- Melanophages, 200
- Melanosomes, 2
- Melasma, 198, 201, 327
in centofacial pattern, 198f
clinical presentation, 198
differential diagnosis, 199
etiology, 198
face, 270t
indications for consultation, 200
laboratory findings, 199
management, 199, 200
patient information, 200
physical examination, 198
topical mediators for the treatment, 199t
- Meningococemia, 251f
- Methicillinresistant *Staphylococcus aureus* (MRSA), 97, 98, 101

- Methotrexate, 219
Miconazole, 76*t*, 79, 81, 84, 86
Microgranulomas, 231
Microsporum audouinii, 72
Microsporum canis, 72
Microsporum gypseum, 72
Migratory glossitis. *See* Geographic tongue
Migratory stomatitis. *See* Geographic tongue
Milia, 130, 147–148
 clinical presentation, 147
 differential diagnosis, 148
 history and physical examination, 147–148
 laboratory findings, 148
 differential diagnosis, 145
 indications for consultation, 148
 management, 148
 patient information, 148
Mohs micrographic surgery, indications, 159*t*
Moisturizers, 34
Moles. *See* Melanocytic nevi
Molluscum, 317*t*
Molluscum contagiosum, 28, 43, 54, 88, 92, 92*f*, 93, 161
 clinical presentation, 92–93
 differential diagnosis, 93
 indications for consultation, 93
 management, 93
 pathophysiology, 92
 patient information, 93
Mononucleosis, 249*f*
Morbilloform drug eruption, 122, 126
 multiple body regions, 287*t*
Mosaic warts, 94
Mucocele, 309, 309*f*, 310*f*
Mucous membrane pemphigoid, 297*f*
Multifocal epithelial hyperplasia, 308, 308*f*. *See also* Sebaceous hyperplasia
Munro abscesses, 63
- N**
Nail
 anatomy, 188–189, 189*f*
 bed, 188
 folds, 188
 matrix, 188
 20-nail dystrophy (*See* Trachyonychia)
 plate, 188
Nail disorders, 188–193
 clinical presentation, 189–193
 differential diagnosis, 190*t*
 indications for consultation, 193
 infectious
 bacterial, 189
 fungal, 189
 nail anatomy, 188–189, 189*f*
 differential diagnosis, 188–189
 papulosquamous
 lichen planus, 189–191, 191*f*
 psoriasis, 189, 191*f*
 patient information, 193
 physical examination, 16–17
 steps, 17–19
 systemic
 alopecia areata, 192, 192*f*
 Beau's lines, 191, 191*f*
 trachyonychia, 192
 yellow nail syndrome, 191–192
 traumatic
 habit tic, 192, 192*f*
 onycholysis, 191*f*, 192–193, 193*f*
Nd:YAG lasers, 139
Necrobiosis lipoidica, 223, 223*f*
 legs, 282*t*
Neurofibroma, 144, 145
Neurofibromatosis, 226, 227*f*
 clinical presentation, 226
 diagnosis, 226–227
 history and physical examination, 226
 indications for consultation, 227
 laboratory findings, 226
 management, 227
 pathophysiology, 226
Neurotized nevus, 144
Neutrophilic dermatosis, acute, 292
Nevus
 common presentations of, 164
 differential diagnosis, 142, 143
Nicotinamide, mucous membrane pemphigoid, 297
Nitric oxide synthase, 2
Nodular basal cell carcinoma, 157*f*
Nodular melanoma, 169, 170*f*
Nodular scabies, 105
Non-Hodgkin lymphoma, 209
Noninvoluting congenital hemangiomas (NICH), 152
Nonspecific viral exanthem, 250*f*
Nonsteroidal anti-inflammatory drugs (NSAIDs), 120, 292
Norwegian scabies, 105
Notalgia paresthetica, 241*f*
Nummular dermatitis, 56
 clinical presentation, 56
 diagnosis, 56
 management, 57
 pathophysiology, 56
 patient information sites, 57
Nummular eczema
 arms, 273*t*
 differential diagnosis, 286*t*
 legs, 281*t*
 multiple body regions, 286*t*
Nystatin, 301
- O**
Ocular rosacea, 135
 management, 135
 physical examination, 135
Onycholysis, 191*f*, 192–193, 193*f*
Onychomycosis. *See also* Tinea unguium
 clinical presentation, 81–82
 indications for consultation, 83
 management, 82–83
 pathophysiology, 81
 patient information, 83
 treatments, 82*t*
Oral antiandrogens, 132
Oral antibiotics, 132
 for skin infections, 35
Oral antihistamines, 35
Oral antioxidants, 197
Oral candidiasis. *See also* Candidiasis
 clotrimazole troches, 301
 nystatin oral, 301
 traconazole oral solution, 301
Oral cavity diseases, 290
 anatomy of, 290
 candidiasis, 299–301
 categories of, 290
 erythema multiforme, 297–298
 herpes simplex (HSV)
 primary and secondary, 294–295
 herpes zoster, 295–296
 intraoral sebaceous glands, 291*f*
 leukoplakia, 304–306
 maculopapular lesions, 298–307
 mucous membrane pemphigoid, 296–297
 nodular/polypoid lesions, 309–310
 oral lichen planus, 302–304
 oral squamous cell carcinoma, 306–307
 papillary, exophytic/fungating lesions, 307–309
 pemphigus vulgaris, 7*f*, 8*f*, 206, 208, 265, 293, 296–297
 pigmented lesions, 310–313
 melanin-associated hyperpigmented lesions, 310–312
 non-melanin-related hyperpigmentations, 312–313
 recurrent aphthous stomatitis, 292
 clinical presentation, 292
 management, 292–293
Stevens–Johnson syndrome/toxic epidermal necrolysis (SJS/TEN), 297–298
traumatic ulcers
 clinical presentation, 291
 on lower lip, 291*f*
 management, 291–292
 varicella, 295–296
 vesiculobullous lesions, 293–298
Oral contraceptive pills, 132, 198
Oral isotretinoin, 132
Oral lesions, 297, 297*f*
Oral lichen planus, 302–304
 with hepatitis C, 302
Oral melanocytic macules, 311
Oral melanomas, 312

- Oral papilloma, 307
 Oral pigmentation, 310–311
 Oral squamous cell carcinoma, 306
 Orolabial herpes, 90
 Osteoma, 148
- P**
- Paget's disease, 317*t*, 322*f*
 Palmoplantar pustulosis
 feet, 284*t*
 hands, 275*t*
 Palpable purpura, 229
 Papilloma, 308
 Papillomatosis, 307
 Papular/pustular acne, 129, 133
 Papulopustular rosacea, 134, 134*f*
 physical examination, 134
 Papulosquamous lesions, 60
 Parasitosis, delusions, 115
 Parkes Weber syndromes, 151
 Partial biopsies, 172
 Parvovirus B19 infection, 245*t*, 249*f*
 Patch testing, 23–24, 286
 Patient adherence/compliance issues, 133
 Pediatric melanoma, 171
 Pemphigus foliaceus, 215, 267*t*
 Pemphigus vulgaris, 7*f*, 8*f*, 124*t*, 206, 207*f*,
 215, 296*f*, 288*t*, 296*f*, 297*f*
 clinical presentation, 206
 differential diagnosis, 207, 288*t*
 indications for consultation, 207
 laboratory findings, 206, 207
 management, 207
 multiple body regions, 288*t*
 Nikolsky sign, 207
 pathophysiology, 206
 patient information, 207
 physical examination, 206
 scalp, 267*t*
 pemphigoid, 26*f*, 28*t*, 29, 30, 105, 205*f*,
 207, 296, 297*f*. *See also* Bullous
 pemphigoid
 Perianal streptococcal disease, 317*t*
 Perioral dermatitis, 135–136, 136*f*
 clinical presentation
 history, 136
 laboratory findings, 136
 physical examination, 136
 diagnosis, differential, 136
 face, 269*t*
 indications for consultation, 136
 management, 136
 pathophysiology, 136
 patient information, 136
 Peripheral ossifying fibroma, 310*f*
 Petechiae, 229, 230
 causes of, 230*t*, 231*t*
 Peutz–Jeghers syndrome, 142, 312
 Photoaging face, 270*t*
 Photodynamic therapy (PDT)
 management, 156
 Phototoxicity face, 270*t*
- Phymatous rosacea, 134–135, 134*f*
 management, 135
 physical examination, 134–135
 Physiologic livedo legs, 282*t*
 Pigmented congenital lesions, 168
 Pigmented nodular basal cell carcinoma,
 156, 157*f*
 Pigmented purpuric dermatosis legs,
 280, 282*t*
 Pigmented tumors, 166*t*
 Pilar cyst, 147
 clinical presentation
 differential diagnosis, 147
 history and physical examination, 147
 laboratory findings, 147
 differential diagnosis, 147
 indications for consultation, 147
 management, 147
 Pilosebaceous disorders, 130*t*
 Pimecrolimus, 34
 Pityriasis alba, 197
 face, 270*t*
 Pityriasis rosea, 11*f*, 27*t*, 28*t*, 60, 61, 63*t*,
 67–68, 84, 103, 277, 278*t*
 clinical presentation, 67
 diagnosis, 67–68
 indications for consultation, 68
 management, 68
 pathophysiology, 67
 patient information, 68
 trunk, 278*t*
 Plaque-type psoriasis vulgaris, 61
 Podophyllin, 95
 Podophyllotoxin, 95
 Polyarteritis nodosa, 231
 Polymerase chain reaction (PCR), 20, 268
 Porphyria cutanea tarda, 225*f*
 hands, 276*t*
 Port-wine stain, 151, 151*f*
 Positive Tzanck smear, 22*f*
 Postinflammatory hyperpigmentation,
 126, 200
 clinical presentation, 200
 differential diagnosis, 201
 laboratory findings, 200
 management, 201
 pathophysiology, 200
 physical examination, 200
 Postinflammatory hypopigmentation,
 197, 201
 clinical presentation, 202
 differential diagnosis, 202
 laboratory findings, 202
 management, 202
 pathophysiology, 201, 202
 patient information, 202
 physical examination, 202
 Potassium hydroxide (KOH), for
 examinations, 20, 189, 272, 274,
 283, 285
 preparation, 21*f*
 for superficial fungal infections, 21*t*
- Prednisone, 219
 Pretibial myxedema, 224*f*
 Primary herpetic gingivostomatitis,
 294*f*, 295
 Primary mucosal melanoma, 171
 Primary ocular melanoma, 171
 Primary syphilis, 319, 320*f*
 Proliferative verrucous leukoplakia,
 304, 305*f*
Propionibacterium acnes, 128
 Prurigo nodularis, 238, 239*f*
 differential diagnosis, 286*t*
 multiple body regions, 286*t*
 Pruritus, 26, 30*t*, 35, 50, 61, 68, 91,
 105, 125*t*, 169, 209, 221, 238,
 240*t*, 242, 270, 281*t*, 284*t*, 288*t*,
 316*t*, 322
 approach to diagnosis, 238
 chronic, 238
 clinical classification, 238
 differential diagnosis, 239*f*–241*f*
 evaluation, 241*f*
 excoriations, 239
 management, 238
 Pseudofolliculitis barbae, 137*f*, 138
 face, 269*t*
Pseudomonas folliculitis, 137*f*, 138
 Psoralen plus ultraviolet light
 A(PUVA), 120
 Psoriasis, 7*f*, 8*f*, 14*f*, 26*f*, 28*t*, 33*t*, 50,
 60–65, 80, 189, 191*f*, 274, 283,
 286, 298, 315, 320
 clinical presentation, 61–63
 comorbidities in patient with, 65
 diagnosis, 63
 differential, 286*t*
 flares, potential causes of, 65
 indications for consultation, 65
 management, 63–64
 multiple body regions, 286*t*
 pathophysiology, 60
 patient information, 65
 pediatric, 64
 psoriatic arthritis, 65
 pustular psoriasis, 62
 scalp, 266*t*
 with striae caused by chronic use of
 steroid ointment, 34*f*
 topical medications, 64*t*
 trunk, 278*t*
 Psoriasis vulgaris
 arms, 273*t*
 feet, 284*t*
 hands, 275*t*
 legs, 281*t*
 Psoriatic nails, 62
 Pulmonary diseases, 225
 Pulsed-dye laser (PDL), 149, 152, 326
 Purpura, 26, 30*t*, 124*t*, 229, 231, 232*t*,
 235*t*, 245*t*, 255*t*, 258*t*, 316*t*
 differential diagnosis, 229, 237*f*
 evaluation, 229

- palpable purpura, 233*f*
 causes, 233*t*, 234*t*
 petechiae, 230*f*
 retiform purpura, 233*f*
 causes, 234*t*–236*t*
 Pustular psoriasis, 61, 126
 Pyoderma gangrenosum, 8, 9*f*, 237*t*, 258*t*, 261*f*, 261*t*, 280
 legs, 281*t*
 Pyogenic granuloma, 149–150, 150*f*, 310*f*
 clinical presentation
 differential diagnosis, 150
 history and physical examination, 149
 laboratory findings, 150
 indications for consultation, 150
 patient information, 150
 treatment, 150
- Q**
 Q-switched lasers, 326, 327
- R**
 Rapidly involuting congenital hemangiomas (RICH), 152
 Rapid plasma regain (RPR), 102
 RAS. *See* Recurrent aphthous stomatitis (RAS)
 Rashes, 243. *See also* Fever
 differential diagnosis, 244*t*–248*t*
 evaluation, 243–244
 Recurrent aphthous stomatitis (RAS), 292
 clinical presentation, 292
 herpetiform, 292, 293*f*
 major aphtha, 293*f*
 management, 292–293
 minor aphtha, 293*f*
 treatment for, 292
 Recurrent herpes simplex, topical medications, 295*t*
 Recurrent intraoral herpes, of maxillary gingiva, 294*f*
 Recurrent oral-labial herpes simplex, oral medications, 295*t*
 Reiter syndrome, 292
 Reticular vasculitis, 13*f*
 Retiform purpura, 229
 Rheumatic vasculitides, 231
 Rhytides. *See* Wrinkles, fine
 Rosacea, 35, 133–135
 clinical presentation
 history, 134
 laboratory findings, 135
 physical examination, 134–135
 diagnosis, differential, 135
 face, 269*t*
 indications for consultation, 135
 management, 135
 medications for treatment, 135*t*
 pathophysiology, 133–134
 patient information, 135
 recommendations for patients, 135
- S**
 Salicylic acid, 64, 95, 131
 Sandpaper-like nails, 192
 Sarcoidosis, 225
 clinical presentation, 225
 differential diagnosis, 226
 history and physical examination, 225
 laboratory findings, 226
 management, 226
Sarcoptes scabiei, 104
 Scabies, 104–108, 242*f*
 in axillae of child, 106*f*
 bullous (*See* Bullous scabies)
 burrow in finger web, 105*f*
 on child's foot, 106*f*
 clinical presentation, 104–106
 history, 104
 laboratory findings, 105–106
 physical examination, 104–105
 crusted (*See* Norwegian scabies)
 diagnosis, 106–107, 106107
 differential, 107, 289*t*
 eggs and scybala, 106*f*
 female *Sarcoptes scabiei* mite, 106*f*
 in finger webs, 105*f*
 indications for consultation, 108
 management, 107–108
 multiple body regions, 289*t*
 nodular (*See* Nodular scabies)
 pathophysiology, 104
 patient information, 108
 treatment, medications for, 107*t*
 volar wrist, 105*f*
 Scabies burrow, 23*f*
 Scabies scraping, 22–23, 22*t*
 Scalp, skin diseases, 265–267
 diagnosis, approach, 265
 differential diagnosis, 266*t*–267*t*
 evaluation, 265
 Scarlet fever, 250*f*
 Scars, 158
 elevated, 327
 Schamberg's disease, 282*t*
 Sclerotherapy, 326
 Sclerotic basal cell carcinoma, 146, 158*f*
 Sebaceous hyperplasia, 144–145, 144*f*
 clinical presentation
 history and physical examination, 144
 differential diagnosis, 145
 laboratory findings, 145
 management, 145
 Seborrheic dermatitis, 27*t*, 28*t*, 54, 60, 63*t*, 66, 73, 84, 109, 219, 222, 266*t*, 268, 269*t*, 278*t*
 clinical presentation, 65–66
 diagnosis, 66
 face, 269*t*
 indications for consultation, 66
 management, 66
 pathophysiology, 65
 patient information, 67
- scalp, 266*t*
 trunk, 278*t*
 Seborrheic keratoses, 141–142, 142*f*
 clinical presentation
 differential diagnosis, 142
 history and physical examination, 141–142
 laboratory findings, 142
 differential diagnosis, 155, 161
 indications for consultation, 142
 management, 142
 patient information, 142
 Selenium sulfide, 74, 84
 Sentinel node biopsy, 172–173
 Shave biopsies, 161, 172
 Shingles. *See* Herpes zoster
 Signature nevus, 167
 Sincatechins, 95
- Skin**, 1
 barrier function, 1
 cross-section of skin, 2*f*
 epidermal nerve fibers, 5*f*
 identity and aesthetics, 5
 immunologic function, 1–2
 physical examination, 16–17
 steps, 17–19
 protection from trauma, 5
 sensation, 4
 major nerve types, 4
 structure and function, 3*t*
 temperature regulation, 4–5
 tumor features, 14
- Skin biopsy**, 38, 285
 anesthesia, 40
 anesthetic injection, pain management, 40
 biopsy techniques, types of, 38
 destructive techniques, 42
 cryotherapy, 42–44, 43*t*, 44*f*
 curettage, 44–45
 electrodesiccation, 44–45
 surgical complications, 45
 equipment for procedures, 39
 dermatology standard equipment tray, 39
 electrosurgery devices, 39
 excisions, 41–42
 lesion, site, and biopsy selection for, 39*f*
 patient preparation, 39–40
 punch biopsy, 41, 42*f*, 42*t*
 shave biopsy, 40–41
- Skin diseases**
 diagnosis, 285
 differential, 286*t*–289*t*
 evaluation, 285–286
- Skin lesions**, 6
 arrangement and distribution, 10–14, 12*t*
 selected colors, 10
 shape, 10, 10*t*
 surface changes in, 8–9, 8*t*
 types of lesions, 6–8

- Skin tag (acrochordon, cutaneous papilloma), 144, 144f
clinical presentation
differential diagnosis, 144
history and physical examination, 144
laboratory findings, 144
indications for consultation, 144
management, 144
patient information, 144
- SLE. *See* Systemic lupus erythematosus (SLE)
- Smoker's melanosis, 312
- Spider veins, 326
- Spiroonolactone, 132
- Squamous cell carcinoma, 17, 18, 29t, 41, 94, 154, 155, 158, 159, 160f, 161, 304, 306, 307f, 308, 317t, 321f
clinical presentation
history and physical examination, 159–161
laboratory findings, 161
diagnosis, differential, 161
differential diagnosis, 150
gingiva mimicking, 307f
indications for consultation, 161
management, 161
patient information, 161
ulcerated, 306f
- Staphylococcal boils, 139. *See also* Boils
- Staphylococcal scalded skin syndrome, 28t, 30t, 215t, 216f, 217f, 243, 246t, 251f
clinical presentation, 216
differential diagnosis, 217
erythema with superficial desquamation of skin, 217f
flaccid blisters, 216f
indications for consultation, 217
management, 217
pathophysiology, 216
physical examination, 216–217
vs. toxic epidermal necrolysis (TEN), 215
- Staphylococcus aureus*, 52, 86, 97, 216
coagulase-positive, 97–98
- Stasis dermatitis legs, 281t
- Stevens–Johnson syndrome, 28t, 30t, 120, 210, 213, 214f, 285, 286, 287t, 297
causes of, 213t
clinical presentation, 213
diagnosis and total body surface area involvement, 214t
differential diagnosis, 215
indications for consultation, 216
laboratory findings, 215
management, 215–216
multiple body regions, 287t
pathophysiology, 213
physical examination, 214
positive Nikolsky sign, 214f
toxic epidermal necrolysis, 214f, 215f
- Stevens–Johnson/toxic epidermal necrolysis, 211f
- Still's disease, 120
- Stucco keratoses, 141, 142f
legs, 281t
- Subacute cutaneous lupus erythematosus, 220, 221f
clinical presentation, 220
differential diagnosis, 220
laboratory findings, 220
management, 220
- Subungual melanoma, 171
- Sun protective clothing, 35–36
- Sunscreens, 35
FDA regulations, 36
ingredients, 36t
SPF rating, 35
- Superficial basal cell carcinoma, 14f, 157f
- Superficial spreading melanoma, 169, 170f
- Superficial thrombophlebitis, 282t
- Sweet's syndrome, 125f, 292
- Syphilis, 97, 101
clinical presentation, 102
latent stages, 102
primary stage, 102
secondary stage, 102
tertiary syphilis, 102
differential diagnosis, 287t, 317t
indications for consultation, 103
laboratory findings, 102–103
management, 103
multiple body regions, 287t
patient information, 103
primary syphilis
diagnosis, 103
secondary syphilis on palms, 102
trunk, 279t
- Syringoma, 148
- Systemic lupus erythematosus (SLE), 135, 219, 221, 221f
clinical presentation, 221
differential diagnosis, 221
history and physical examination, 221
indications for consultation, 221
laboratory findings, 221
management, 221
patient information, 221
- Systemic retinoids, 190
- T**
- Tacrolimus, 34
- Tattoo removal, 327–328
- Tazarotene, 63, 64, 189
- T-cells, 1, 195
activation, 122
- TEN. *See* Toxic epidermal necrolysis (TEN)
- Tetracycline, mucous membrane pemphigoid, 297
- Therapeutic baths, 34–35
- Thermoregulation, 5
- Thin-layer rapid use epicutaneous (TRUE) test, 23
- Thrombocytopenic purpura (TTP)
legs, 282t
- Thrombophlebitis, 100
- Thyroid disease, 224
differential diagnosis, 224
history and physical examination, 224
laboratory findings, 224
management, 224
- Tinea barbae, 71
- Tinea capitis, 23t, 66, 71–74, 180, 265, 267t
clinical presentation, 72–73
diagnosis, 73
indications for consultation, 74
management, 73–74
patient information, 74
pediatric dosing regimen, 74
scalp, 267t
- Tinea corporis, 10, 11f, 28f, 63t, 71, 74, 75f, 107, 273t, 278t, 281t, 287t
arms, 273t
clinical presentation, 75
diagnosis, 75–76
differential diagnosis, 287t
griseofulvin dosing regimen, 76t
legs, 281t
management, 76
multiple body regions, 287t
pathophysiology, 74–75
patient information, 77
trunk, 278t
- Tinea cruris, 35, 71, 78f, 79, 315, 316t, 319f
clinical presentation, 78
diagnosis, 78–79
differential diagnosis, 316t
management, 79
pathophysiology, 78
patient information, 79
- Tinea faciei, 71, 75f
face, 270t
- Tinea manuum, 71, 77f
hands, 275t
- Tinea pedis, 72, 79f, 80f
clinical presentation, 79–80
diagnosis, 80
feet, 284t
management, 80–81
pathophysiology, 79
patient information, 81
- Tinea unguium, 72, 81f
- Tinea versicolor, 7f, 21f, 75, 83, 83f, 197, 201, 202, 277, 278t
clinical presentation, 83–84
diagnosis, 84
management, 84
pathophysiology, 83
patient information, 84
trunk, 278t
- Toll-like receptors (TLRs), 1
- Tongue
fissured, 299f
traumatic ulcer, 291f, 292f

- Topical
 antibiotics, 131
 antipruritic medications, 35
 calcineurin inhibitors, 33
 retinoids, 130
- Topical medications
 for dermatophyte skin infections, 76*t*
 for lice, 35
 patient compliance/adherence
 issues, 36
 for psoriasis, 64*t*
 quality of life, and mental health
 issues, 36
 for scabies, 35
 web sites, 37
- Topical steroid medications
 class and potency rank, 33*t*
 factors in the usage and
 selection, 33*t*
 potential adverse effects, 34*t*
- Toxic epidermal necrolysis (TEN),
 28*t*, 30*t*, 122*t*, 124*t*, 210, 212*t*,
 213–216, 285, 287, 297, 298*f*
 clinical presentation, 213
 differential diagnosis, 215
 indications for consultation, 216
 laboratory findings, 215
 management, 215–216
 multiple body regions, 287*t*
 pathophysiology, 213
 physical examination, 214
- Trachyonychia, 192
- Traconazole oral solution, for oral
 candidiasis, 301
- Traumatic blister, 149
- Treponema pallidum* particle
 agglutination assay
 (TPPA), 103
- Trichloroacetic acid (TCA)
 application, 327
- Trichoepithelioma, 148
- Trichophyton mentagrophytes*, 72
- Trichophyton rubrum*, 53, 72
- Trichophyton schoenleinii*, 72
- Trichophyton tonsurans*, 72
- Trichophyton verrucosum*, 72
- Trunk, skin diseases
 diagnosis, approach, 277
 differential diagnosis, 278*t*–279*t*
 evaluation, 277
- Tuberous sclerosis, 23*t*, 197, 227, 227*f*
 clinical presentation, 227
 diagnosis, 228
 indications for consultation, 228
 laboratory findings, 227
 management, 228
 pathophysiology, 227
 patient information, 228
- Tumor necrosis factor α (TNF- α), 138
- Typical nevi, characteristics, 167*t*
- Tyrosinase deficiency, 4
- Tzanck test, 20, 22*t*
- U
- Ulcers, 211, 223, 234, 236, 257*t*, 259, 260,
 261*t*, 262*f*, 263*f*, 291, 292, 294,
 295, 298
- Ulcerative stomatitis, chronic, 303
- Ultraviolet (UV) light, 154
- Unilateral laterothoracic exanthema, 243,
 246*t*, 250*f*
- Urea, 34
- Urticaria, 115, 117–121, 125–126, 287*t*
 acute, causes of, 118*t*
 angioedema, 119*f*
 on back, 119*f*
 clinical presentation
 history, 117–118
 laboratory finding, 119–120
 physical examination, 118–119
 dermatographism, 119*f*
 diagnosis differential, 120
 on hand, 118*f*
 indications for consultation, 120–121
 management, 120
 mosquito bites, 120*f*
 multiforme, 251*f*
 multiple body regions, 287*t*
 oral antihistamines, 35
 pathophysiology, 117
 patient information, 121
 physical urticarias, 118*t*
 treatment, oral antihistamines
 for, 121*t*
 vasculitis, 120
- Urticaria/angioedema/anaphylaxis, 122
- V
- Vaccinations, 243
- Valacyclovir, 295, 295*t*
- Vaniqa cream, for hair removal, 327
- Varicella, 98, 249*f*, 295–296
- Vascular lesions, in infants, 150, 150*t*
- Vascular malformation (port-wine stain,
 stork bite, angel kiss), 150–151
 clinical presentation
 differential diagnosis, 151
 history and physical examination,
 150–151
 laboratory findings, 151
 indications for consultation, 151
 patient information, 151
 treatment, 151
- Vasculitis, 230
- Venereal disease research laboratory test
 (VDRL), 102
- Venous ulcers, 259–262, 260*f*
 clinical presentation, 259–260
 diagnosis, 260
 differential diagnosis, 260
 indications for consultation, 262
 management, 260–262
 pathophysiology, 259
- Verrucae plantaris, 93, 94
- Verrucae vulgaris, 88, 93, 94*f*, 307
 clinical presentation, 93–94
 differential diagnosis, 94–95
 on finger, 308*f*
 indications for consultation, 95
 management, 95
 genital warts, 95
 nongenital warts, 95
 pathophysiology, 93
 patient information, 95–96
 prevention, 95
- Verrucous carcinomas, 161
- Vesiculobullous allergic contact reaction,
 on lower lip, 293*f*
- Viral culture, 286
- Viral exanthem
 differential diagnosis, 287*t*
 multiple body regions, 287*t*
- Viral exanthems, 120, 125
- Viral wart, 155, 161
- Vitamin D, 1
 synthesis, 4
- Vitamin D₃, 4
- Vitiligo, 4, 10*t*, 23*t*, 164, 195–197, 202,
 270*t*, 285
 clinical presentation, 196
 differential diagnosis, 197
 face, 270*t*
 indications for consultation, 197
 laboratory findings, 196
 management, 197
 multiple body regions, 288*t*
 pathophysiology, 195
 patient information, 198
 physical examination, 196
- Vulvo/vaginal melanoma, 171
- W
- Warts. *See* Verrucae vulgaris
 feet, 284*t*
 hands, 275*t*
- Wegener's disease, 231
- Wet dressings, 35
- Wood's light, 23
- Wound healing, predictable
 treatments, 327
- Wrinkles, fine, 323–326
- Y
- Yellow nail syndrome, 191–192